

Ocular Pathologies in Children and Adolescents: Cataracts

Jennings Hernandez^{1*} and Anjali Kumar¹

¹*Washington University of Health and Science, USA.*

Original Research Article

ABSTRACT

Pediatric cataracts are one of the most common causes of visual impairment in children. A cataract is due to cloudiness in the crystalline lens. The lens is the part of the eye that helps focus light images onto the retina. The retina translates the information to nerve fibers and sends it to the brain for processing. If the lens is cloudy from a cataract, the image will be blurred and thus vision will be affected. The cloudiness in a cataract is due to the accumulation of protein crystals in the lens. The human lens consists of three main types of proteins that are very tightly packed together: α -, β -, and γ -crystalline [1]. The tight packaging of these proteins limits the amount of light scattering and thus creates a clear lens. If the proteins are altered it can increase space between the proteins and therefore increase light scattering, which causes cataracts.

Keywords: *Cataracts; crystalline lens; retina; nerve fibers; α -proteins; β -proteins; γ -crystalline.*

1. INTRODUCTION

According to the Journal of Pediatric Ophthalmology, "thorough ocular evaluation, including the onset, duration, and morphology of a cataract, is essential to determine the timing for surgical intervention. Detailed assessment of the general health of the child, preferably in conjunction with a pediatrician, is helpful to rule out any associated systemic condition" [2]. Pediatric cataracts can be classified depending on the onset of symptoms as well as their morphological appearance and location. Congenital Cataracts present during fetal life or shortly after birth. They are the most common

cause of leukocoria (white eye) in children. Nearly half of these cataracts are idiopathic whereas the other half are due to metabolic disorders, exposure infective organisms, chromosomal abnormalities, and skeletal and ocular diseases. If the cataract develops during the first year of life it is then defined as an Infantile Cataract. These cataracts are mainly from exposure to infective organisms early in life, hereditary predisposition, or traumatic injuries. If the child develops the cataract after the first year of life it is defined as an Acquired Cataract and is usually due to a systemic disease, an ocular disease, drugs, or trauma.

2. EPIDEMIOLOGY

10% of childhood blindness worldwide is accounted for by pediatric cataracts. The prevalence rate is approximately 6 cases per 10,000 in the United States and other developed

**Corresponding author: E-mail: anjalikumar731@gmail.com;*

countries. However, the prevalence rate is estimated to be 15/10,000 in underdeveloped countries. Currently, 200,000 children are blind worldwide due to cataracts and approximately 40,000 children per year are born with developmental bilateral cataract. Of the bilateral cataracts, 60% of them are also found to have a form of metabolic or systemic disease present.

In underdeveloped nations such as India, it accounts for 10% of childhood blindness and more than half of these pediatric cataracts are due to idiopathic causes. Very rarely is it associated to a genetic predisposition and is less than 20%. Approximately 12% of non-traumatic cataracts are accounted for by preventable

causes such as health education for childbearing women thereby reducing cataract incidence. Rubella is also a major preventable disease which is linked to cataracts. In underdeveloped nations, early detection is essential in reducing the incidence of pediatric cataracts [3].

3. PATHOLOGY

Pediatric cataracts often occur because of abnormal lens development during pregnancy. Genetic mutation is likely the most common cause. The inheritance is most often autosomal dominant although it can be X-linked or autosomal recessive. Systemic associations

Table 1. Common causes of pediatric cataracts

Common Causes of Pediatric Cataracts		
Congenital Cataract	Infantile Cataract	Acquired Cataracts
Autosomal Dominant	TORCHS	Diabetes Mellitus
<u>Galactosemia</u>	Organisms	Neurofibromatosis
Hyperparathyroidism	Autosomal	2
<u>Fabrys Disease</u>	Dominant	Atopic Dermatitis
Trisomy's (13, 18, 21)	Trauma	High Myopia
<u>Hallerman-Streiff</u>		Retinitis
<u>Aniridia</u>		Corticosteroids
TORCHs Organisms		Chlorpromazine
• Toxoplasmosis Gondi		Blunt/Sharp
• Rubella		Trauma
• Cytomegalovirus		
• Herpes Simplex Virus		
• HIV		
• Syphilis		

include metabolic disorders such as galactosemia, Wilson disease, hypocalcaemia and diabetes. Intrauterine infections including rubella, herpes simplex, toxoplasmosis, varicella and syphilis can also lead to pediatric cataract. Additionally, elevation in core body temperature by 5 degrees during developmental stages in pregnancy increases the odds of congenital cataracts by 51%. Morphologically, pediatric cataracts can be broadly classified into the cataracts involving the entire lens, central cataracts, anterior cataracts, posterior cataracts, punctate lens opacities, coralline cataracts, sutural cataracts, wedge-shaped cataract, and cataracts associated with PFV. Total cataracts can be sporadic or hereditary in nature. So, evaluation by a geneticist is helpful for determining the

inheritance pattern and to identify associated syndromes. More than 40 different genes and various loci have been identified with congenital cataracts. Mutations in the genes responsible for the maintenance of lens clarity, such as the crystalline and connexin genes, are the most commonly described in the etiology of non-syndromic inherited cataracts. Mutations in the genes coding for transcription factors, aquaporin (Maf), beaded filament structural protein, vimentin, and lens intrinsic membrane proteins have also been reported [2].

Mutations in the α -crystalline gene tend to cause nuclear, lamellar, zonular, and posterior polar cataracts. In addition to primary cataract, mutation in CRYAA has been associated with micro- cornea. Phenotypic variability is

commonly observed with mutations in the β -crystalline genes. Mutations in the developmental genes, such as PAX6, FOXE3, PITX3, and MAF have also been implicated with cataract as a part of anterior- segment developmental anomalies. Anterior polar cataracts are commonly seen with PAX6 mutations with or without aniridia, whereas PITX3 mutations predominantly cause posterior polar cataracts [1].

4. MANAGEMENT

“Over the past decade, advances in technology and refinements in surgical techniques have brought pediatric cataract surgery into the modern age. Automation and the use of intraocular lenses (IOLs) have facilitated better anatomical and functional outcomes” [6]. However, cataracts surgery is rarely performed on pediatric patients. If the cataract is size is

minimal or unobstructed, visual development may be unaffected. Surgery on pediatric patients are performed after 6 months of age or when the disease starts to interfere with eyesight. Pediatric cataracts are managed by observation and/or use of eye drops for pupil dilation which increases the amount of light entering the eye. Dilation may delay the need for surgery until eye development and growth has stabilized. The first 6 weeks of life are the most critical for visual development during with vision is resistant to amblyopia. Therefore, obstructive cataracts in children require prompt surgical intervention to provide and maintain visual axis and retinal focus [7].

According to the Indian Journal of Ophthalmology (2017), “if a child has a unilateral cataract, he or she is still likely to have a normal life as long as the unaffected eye remains

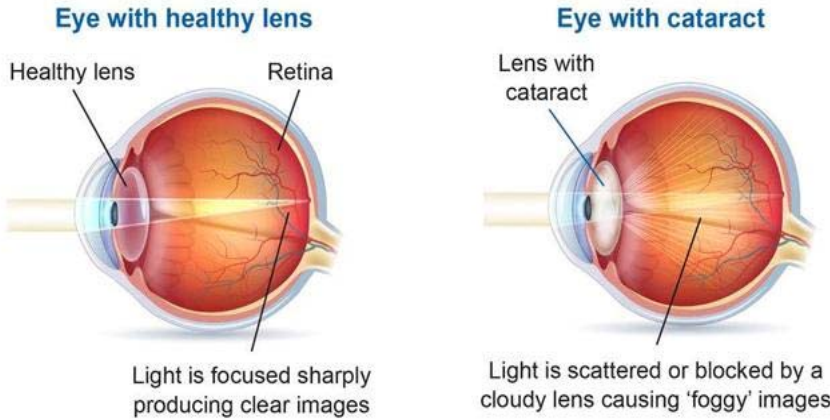




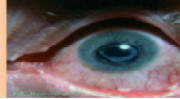
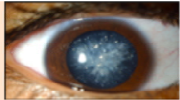




Fig. 1. Example of cataract [4].

Table 2. Types of pediatric cataracts [5]

Types of Pediatric Cataracts			
Cataract	Description	Common Causes	Images
Lamellar	Most Common Pediatric Cataract Bilateral Asymmetric or Symmetric Discrete, round (lenticular) shape affecting one or more of the “rings” in the developing lens cortex.	Hereditary <u>Hypovitaminosis D</u> Hypocalcaemia Maternal Malnutrition	
Polar	Anterior: Bilateral, Symmetric, small, non-progressive, does not affect vision. Posterior: Large, center of lens, Unilateral/Bilateral, affects vision.	Hereditary Due to delayed formation of the anterior chamber during lens development	
Capsular	<u>Opacification</u> of the lens capsule Rapid development Visual acuity not affected		
Complete	All transparent lens fibers <u>opacified</u> Unilateral/Bilateral Worse effect on vision	Infective Organism	 <small>© 2013 American Academy of Ophthalmology</small>
Membranous	Secondary Composed of remains of thickened lenticular capsule and degenerated lens	Trauma	
Cerulean (Blue Dot)	Multiple bluish and white opacities predominantly in the lens cortex with occasional radial central lesions are apparent. Visual acuity not affected	Hereditary	
Nuclear	Most common type <u>Opacification</u> of nucleus of lens Bilateral	Atopic Dermatitis Infectious Organisms	
Sutural (Stellate)	Longitudinal opacities w/ braches Bilateral Symmetric Visual acuity not affected	Genetically Inherited X linked	

healthy and normal. It is, in fact, the bilateral dense cataracts in children that are of greater developmental concern” [8]. Children with bilateral cataracts can undergo surgery as early as 6 weeks of age and the surgeries are scheduled 1 week apart for each eye. It is important to perform partial under-correction to balance postoperative myopic shifts. This is accomplished by immersion biometry to choose the appropriate intraocular lens power. The preferred type of intraocular lens (IOL) for children is the acrylic IOL due to lower rate of complications.

There are various surgical techniques that are used in pediatric cataracts. The most common technique used are superior incisions. This is the

most preferred method because unlike the alternative, there is lower risk of injury and postoperative endophthalmitis. To ensure safe lens implantation, anterior capsulotomy is performed, where manual continuous curvilinear capsulorhexis (CCC) is considered the gold standard technique. This incision technique has a minimal risk of extensions or tears. Cataract extraction is accomplished through an anterior approach by manual irrigation and aspiration or through the pars plana using a vitrector, especially the trans-conjunctival 25-gauge vitrectomy [9]. For successful pediatric cataract extraction, maintenance of a clear visual axis is critical. In order to avoid complications such as posterior- capsule opacification (PCO), it is

essential to combine primary posterior capsulotomy with anterior vitrectomy in infants and young children.

5. CONCLUSION

Pediatric cataracts are typically caused by a malformation of the lens during early intrauterine life. Pediatric cataracts are also hereditary in about 20% of cases however, often they present spontaneously. Most pediatric cataracts are not associated with other abnormalities. It is crucial that severe cataracts occurring near the time of birth be removed within weeks to prevent amblyopia. It is rare for complications to occur due to surgery. However, in some cases, a membrane can grow back in the middle of the eye despite cataract removal. This can be remedied by repeat operation. With current techniques, cataract surgery is considered safe and effective when performed by a pediatric ophthalmologist. Research is currently being done to provide reliable outcomes for infants younger than 6 months of age while preserving as much sight as possible. One important focus of this research is an effort to lower the postoperative prediction error. Identifying more factors that may affect postoperative axial growth, besides secondary glaucoma, will help ophthalmologists accurately predict refraction and therefore implant the proper intraocular lens for pediatric eyes.

COMPETING INTERESTS

Authors have declared that no competing interests exist.

REFERENCES

1. Hejtmancik F. Congenital cataracts and their molecular genetics. *Seminars in Cell & Developmental Biology*, U.S. National Library of Medicine; 2008.
Available: www.ncbi.nlm.nih.gov/pmc/articles/PMC2288487
2. Medsinge A, Nischal K. Pediatric cataracts: Challenges and future direction. *The Journal of Pediatric Cataracts*. 2015;15(9):77-90.
DOI: <https://doi.org/10.2147/OPTH.S59009>
3. Yi J, Chang T. Epidemiology and molecular genetics of congenital cataracts. NCBI. US National Library of Medicine. Available: <http://www.ncbi.nlm.nih.gov/pmc/articles/PMC3340856>.
4. Cataract and Macular Degeneration. Macular Disease Foundation Australia; 2017.
Available: https://mdfa-s3fs-prod.s3-ap-southeast-2.amazonaws.com/s3fs-public/MDFA_Cataracts-MD_Factsheet_web.pdf
5. American Association for Pediatric Ophthalmology and Strabismus. Cataract – AAPOS; 2017.
Available: aapos.org/terms/conditions/31
6. Vasavada A, Shah S, Vasavada V. Management options in pediatric cataracts. *US Ophthalmic Review*. 2012;5(1):44-7.
DOI: <http://doi.org/10.17925/USOR.2012.05.01.44>
7. Wilson E. Pediatric cataracts: Overview. *American Academy of Ophthalmology*. Vol 11.
Available: www.aao.org/disease-review/pediatric-cataracts-overview
8. Nischal K. Practice patterns in pediatric cataract management: Time for real world data. *Indian Journal of Ophthalmology*. 2017;65(9):779-781.
DOI: [10.4103/ijo.IJO_816_17](https://doi.org/10.4103/ijo.IJO_816_17).
9. Plager D. Pediatric cataract surgery, techniques complications, and management. *American Journal of Ophthalmology*. 2005;140(4):778.
DOI: <https://doi.org/10.1016/j.ajo.2005.08.076>