SPONTANEOUS EVOLUTION OF LAMELLAR MACULAR HOLE INTO FULL THICKNESS MACULAR HOLE, AND RESOLUTION OF THE SAME, FOLLOWED BY OPTICAL COHERENCE TOMOGRAPHY

ABSTRACT

AIM: Aim of this study is to, with the aid of optical coherence tomography, follow and evaluate spontaneous evolution of lamellar macular hole into full thickness macular hole, and vice versa.

METHOD: A 70-year-old female with metamorphopsia and decreased central vision was examined and followed both clinically and with the aid of high-resolution optical coherence tomography. Idiopathic lamellar macular hole on the right eye and epiretinal membrane on the left eye were noted. Both, evolution of lamellar macular hole and epiretinal membrane was followed over a 2 year period.

RESULTS: Over a period of 6 months lamellar macular hole had progressed into full thickness macular hole only to later 'close' and resolve into lamellar macular hole. High-definition optical coherence tomography confirmed that one of the mechanisms responsible for lamellar macular hole was opening of cystic spaces on the edges of lamellar macular hole. Loss of IS/OS juncture, or in other words, defects in the photoreceptor layer could be responsible for poor visual outcome. During the course of follow-up examinations of the left eye, there was partial separation of the epiretinal membrane without subsequent development of macular hole.

CONCLUSION: Lamellar macular hole slowly progresses and rarely evolves into a full thickness macular hole, and vice versa.

Keywords: full thickness macular hole; evolution; lamellar macular hole; idiopathic; optical coherence tomography

Introduction

Disruption of vitreomacular interface (VMI) consists of a group of macular disorders including pseudohole; lamellar hole; full thickness macular hole; pseudocyst; and myopic maculoschisis. There exists considerable overlap between these lesions and it is sometimes very difficult to distinguish between pseudocyst; pseudohole; and lamellar hole. [1] Upon funduscopic examination these changes seem like isolated, well-defined, lesions in the macula. While lamellar macular hole (LMH) and macular pseudohole (MPH) may result in a slight decrease of visual acuity (VA), full thickness macular hole (FTMH) may result in significantly decreased VA.

High-definition optical coherence tomography (HD–OCT) is a precise method that allows one to analyse ultrastructural changes of the vitreomacular interface (VMI) and make a distinction between them. [2; 3; 4; 5; 6]

Data obtained in this way can aid in explaining various mechanisms of occurrence and in monitoring individual states that belong to this group of disorders thus making it easier to form a decision regarding surgical intervention [7; 8]. On the other hand, besides an OCT,

histological examination of epiretinal membranes (ERM) obtained through vitrectomy may also aid in detecting certain VMI disorders.

Mechanisms of VMI occurrence, which have been obtained via an OCT, indicate that MPH occurs as consequence of ERMs centripetal traction. [9] In 1975 Gass described LMH as opening of the cystic roof (abortive process) of persistent cystoid macular edema (CME). [9] There are several possible ways of development of LMH however such as progressive contraction of ERM; disruption of foveal cysts; and front–rear traction. [10; 11]

LMH slowly progresses and can be one of the evolutive stages of development of FTMH. On an OCT, LMH appears as an intraretinal split (cleft) with layered inner retinal layers; where there exists irregular retinal contour and thinning. On the other hand outer retinal layers cover retinal pigment epithelium (RPE) and there are no defects in the photoreceptor layer. [11; 12; 13; 14; 15; 16]

FTMH is full thickness macular tissue defect described for the first time by both Hee and Takahashi [17; 18] Besides FTMH, HD–OCT also shows defects of the inner/outer segment (IS/OS) with persistent foveal detachment.

Patients that have FTMH generally present with considerably decreased visual acuity.

Tears in the photoreceptor layer and/ persistent foveal detachment may be the reason for significant visual decrease. Spontaneous closure of LMH and FTMH is relatively rare, and that of LMH can result in visual recovery whereas spontaneous closure of FTMH generally has poor visual outcome. [19; 20; 21; 22]

Results obtained via an OCT indicate that Müller cells and astrocytes participate in spontaneous closing of FTMH. [23; 24; 25]

Aim of this study is to show both evolution of LMH into FTMH and resolution of FTMH into LMH.

Materials and methods

Patient was followed over a period of two years, and before and during each follow-up examination patients' VA and intraocular pressure (IOP) were taken. Biomicroscopic and high-definition spectral domain OCT (SOCT Copernicus) performed.

During research, principles outlined in the Declaration of Helsinki (2008) were followed. Patient provided informed consent. Neither the patient nor researchers received any financial compensation.

Case report

Initial examination, September 2013

An ophthalmologist assessed a 70-year-old female as she experienced decreased visual acuity on the right eye, together with associated distortion of horizontal and vertical lines around the central fixation point that worsened over the course of the preceding three months. Patient stated that, to the best of her knowledge, she had no additional ophthalmic diseases or illnesses, and that she was not on any medication. Upon examination, best-corrected visual acuity (BCVA) was 0.4 on the right and 0.7 on the left eye. Intraocular pressure (IOP) was 15mmHg on the right and 16mmHg on the left eye. Examination of the posterior segment of the right eye revealed reduced macular reflex; cystic change; as well as macular ERM, and

discrete macular ERM on the left eye. OCT was performed in order to provide complete, in-depth, precise, diagnostic assessment of various macular changes (Fig. 1A; 2A).
In conjunction with oral antioxidants and vitamins, topical non-steroidal anti-inflammatory drug (NSAID) was administered to the right eye.

Second examination, November 2013

At a three month follow-up examination patient stated that her vision on the right eye had worsened considerably and it was noted that her BCVA had decreased from 0.4 to 5/60 (Snellen chart). Left eye BCVA remained unchanged i.e. there were no significant changes (Fig. 1B; 2B). Clinical assessment and right eye OCT revealed presence of FTMH and macular ERM. There were no bilateral variations of IOP.

Third examination, August 2014

Follow-up examination performed less than a year later revealed that right eye BCVA increased, whilst left eye BCVA decreased (0.3 and 0.1, Snellen chart; respectively). On the other hand, there was no change of IOP on either eye. Clinical examination of the posterior segment of the right eye revealed that there was spontaneous resolution of FTMH into LMH and progression of ERM on the left eye, findings which were then confirmed via an OCT (Fig. 1C, 2C). Left eye OCT examination revealed nasally detached ERM and retinal layering in the central region.

Fourth and final examination, October 2015

Final examination revealed bilateral improvement (0.5 and 0.3, Snellen chart; right and left eye respectively). Clinical examination via an OCT showed that there exists right eye LMH as well as persistent ERM on the left eye (Fig. 1D; 2D). Previously mentioned findings were confirmed via an OCT, which also revealed decreased retinal layering. There was no bilateral change of IOP.

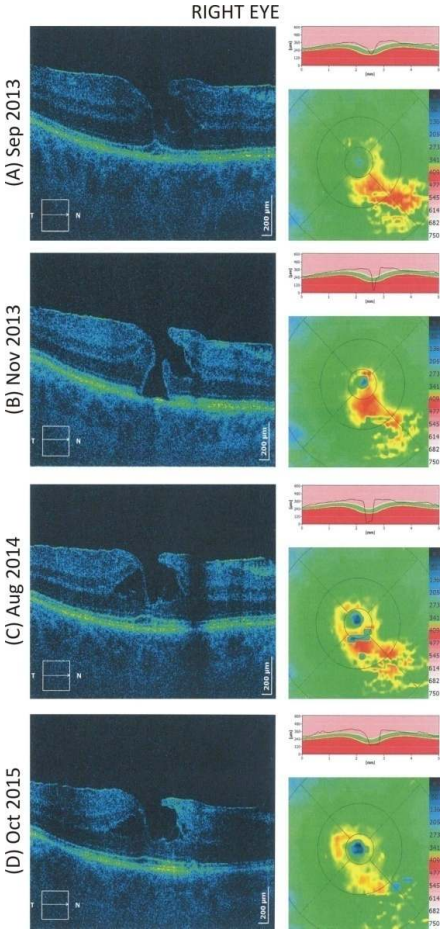

Figure 1 Evolution of macular hole; OCT follow-up; right eye

(A – Sep 2013) Right eye OCT findings taken at initial examination showed nasally, changed foveal contours seemed to have markedly deepened and to have steep, nearly vertical, wall appearance. On the inner surface of the retina, one can see a thin, highly reflective, line that corresponds to ERM and forms a retinal break in the fovea. Retina was thicker and of nasally modified layer configuration. There exist several small and a single large, optically empty, fluid filled cystic space, formed as consequence of ERM contraction. Outer foveal layers were still present beneath LMH. One can clearly see elevated layers and their shift to the centre of the fovea. Highly reflective layers are continual in nature.

(B – Nov 2013) Right eye OCT findings taken at second examination showed distinct foveal features confirmed presence of FTMH with base diameter of 525µm; minimal inner diameter of 175µm; edge height of 333µm; and opening diameter of 451µm. Nasal edge of the break pointed toward intra-retinal disruption. Temporal edge was thick and micro-cystically layered. At the base of the break there was a disrupted photoreceptor layer, whereas RPE layer was of varying reflective intensity. ERM had, through nasal contraction, opened and thus elevated lip of the hole.

(C – Aug 2014) Right eye OCT findings taken at third examination showed that retinal tear had closed. Macular contour had deepened but the external layers below had remained intact. Edges of this lamellar hole were thicker, and had optically empty spaces which had coincided with split cystic spaces. Inner retinal surface had highly reflective line that coincided with ERM and that had both unchanged thickness and retinal adhesion. Subfoveally, there was discrete optically empty space that contained sub-retinal fluid. Other highly reflective layers had no visible changes of continuity and/ reflectivity.

(D – Oct 2015) Right eye OCT findings taken at fourth examination revealed a presence of lamellar hole. Nasally there were inner retinal splits that were surrounded by micro-cystic spaces, whilst temporally there existed greater cystic spaces that had tended to unite. inner/outer segment (IS/OS) layer was partially, discretely, elevated, whilst RPE layer was continuous and of variable reflectivity.

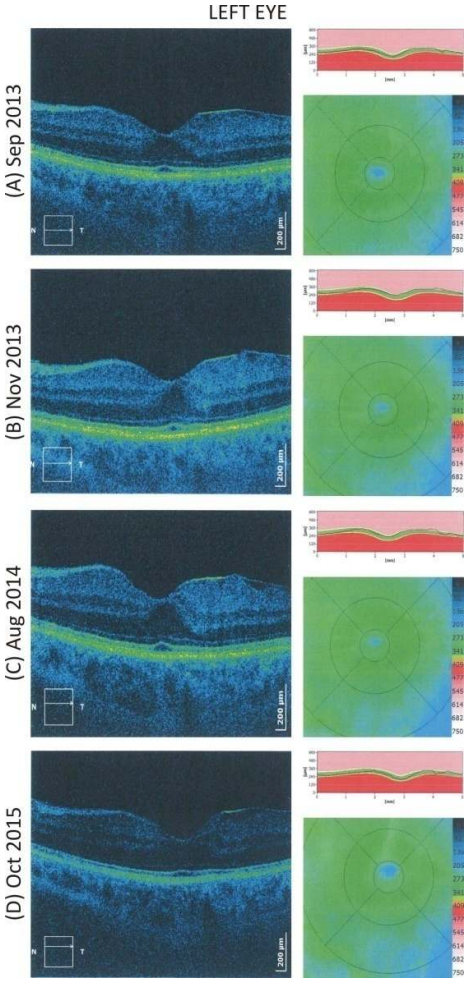

Figure 2. Evolution of macular micro-structural changes; OCT follow-up; left eye

(A – Sep 2013) Left eye OCT findings taken at initial examination showed discretely centrally elevated, flattened, foveal contour and a thin reflective line of inner surface ERM. On account of tractional ERM which bridged the fovea, foveal layers were centrally drawn. Even though there exists an elevated IS/OS photoreceptor layer, highly reflective layers made-up of retinal pigment epithelium (RPE) and IS/OS juncture, were continual and of stable reflective intensity.

(B – Nov 2013) Left eye OCT findings taken at second examination showed changed foveal contour, which due to tractional ERM, has temporally elevated slope. Foveal layers were more withdrawn temporally and, at the same time, retina was more layered centrally. IS/OS juncture elevation was more pronounced temporally. There was partial temporal detachment of ERM from the retina – which was both serrated and uneven.

(C – Aug 2014) Left eye OCT findings taken at third examination revealed that ERM was nasally more detached. Inner structure of the retina is nearly unchanged, but retina itself is still centrally layered. Elevated IS/OS juncture can no longer be seen. Highly reflective layers remain /are unchanged.

(D – Oct 2015) Left eye OCT findings taken at fourth, final, examination revealed presence of ERM as a discrete, highly reflective line on the surface of the retina. On the other hand, retina appeared to be less layered than before. Highly reflective layers remain /are unchanged.

Discussion

MHs belong to a group of disorders characterised by vitreoretinal surface changes that occurred due to incomplete or abnormal separation of vitreous and the retina from one another. HD–OCT allows for objective analysis of various mechanisms through which

abnormal or incomplete separation occurs. Presence of ERM, its' contraction and opening of cystic spaces in the retina, are deemed to be one of the possible mechanisms of disease progression. [26]

As consequence of tractional ERM both the inner retinal layers and the photoreceptor layer have been preserved and centrally elevated.

Evolution of LMH into FTMH; deepening of defects due to micro-cystic layering; disruption of photoreceptors; weakening of IS/OS junctures; all lead to decreased visual acuity. [27; 28]

A 70-year-old female patient was examined by an ophthalmologist and diagnosed with right eye LMH that had evolved into FTMH; loss of outer retinal layers; disruption of photoreceptor layer; and RPE layer that remained unchanged but of varying reflectivity.

Resolution of FTMH into LMH is **extremely rare** [23; 22], and there exist various mechanisms, such as reduction of pre-existing VMT; ERM contraction followed by retinal folding and development of retinal tissue bridges, that may participate in this process. [11]

Seeing that LMH may be seen as an abortive form of FTMH, it is possible that same mechanisms that participate in closing of LMH also participate in closing of FTMH. [14]

Results obtained as part of this study suggest that closing of LMH occurs as consequence of separation of ERM from the edges of the hole and complete posterior vitreous detachment (PVD), or in other words, as consequence of released retinal surface tension.

It is possible that tissue that covers base of the LMH, formed as a result of spontaneous closure of FTMH, originates from Müller cells which spread and proliferate from the external limiting membrane (ELM) to the internal limiting membrane (ILM). Anatomical recovery that follows leads to functional visual recovery. [27; 28]

Patient who was presented as part of this study had LMH resolve into FTMH on the right eye, which did not occur due to ERM contraction. HD-OCT shows thickened edges of MH; fewer cystic spaces; and presence of subretinal fluid.

For these reasons there was displacement of liquid from retinal to subretinal space thus separating edges of the hole and thus closing the previously separated layers. There appear to be no tissue bridges.

As seen via an OCT, improved visual acuity could be explained through the fact that the IS/OS line appears to be preserved and there exists only elevated photoreceptor layer.

Follow-up examinations of the paired, left, eye revealed that, besides folded ERM and elevated photoreceptor layer, there existed no macular defects.

Conclusion

Formation of certain forms of LMH and FTMH is multifactorial and depends on which one of the existing factors prevails in the particular phase of their formation. HD–OCT has proven to be useful and precise tool used to diagnose and monitor previously mentioned states.

LMH slowly progresses and can be seen as abortive form of FTMH while on the other hand opening of cystic spaces may be one of the mechanisms responsible for formation of FTMH.

Loss of full thickness retinal tissue and disruption of photoreceptor layer are responsible for considerable visual decrease.

So, decreased tractional ERM; formation of tissue bridges; and Müller cells can, through decrease of cystic spaces; fluid displacement into subretinal space; and convergence of edges, be responsible for a rare closing of FTMH and its' evolution towards LMH.

References

1. Chen JC & Lee LR (2008): Clinical spectrum of lamellar macular defects including pseudoholes and pseudocysts defined by optical coherence tomography. Br J Ophthalmol 92: 1342–1346.
2. Haouchine B, Massin P, Tadayoni R et al. (2004): Diagnosis of macular pseudoholes and lamellar macular holes by optical coherence tomography. Am J Ophthalmol 138: 732–739.
3. Witkin AJ, Ko TH, Fujumoto JG et al. (2006): Redefining lamellar holes and the vitreomacular interface: an ultrahigh-resolution optical coherence tomography study. Ophthalmology 113: 388–397.
4. Punjabi OS, Flynn HW Jr, Legarreta JE, Gregori G, Knighton RW, Puliafito CA (2007). Documentation by spectral domain OCT of spontaneous closure of idiopathic macular holes. Ophthalmic Surg Lasers Imaging; 38(4):330– 332.
5. Imai M, Ohshiro T, Gotoh T, Imasawa M, Iijima H (2003). Spontaneous closure of stage 2 macular hole observed with optical coherence tomography. Am J Ophthalmol; 136(1):187–188.
6. Ishida M, Takeuchi S, Okisaka S. (2004), Optical coherence tomography images of idiopathic macular holes with spontaneous closure. Retina; 24(4):625–628.
7. Bhatnagar P, Kaiser PK, Smith SD, Meisler DM, Lewis H, Sears JE: Reopening of previously closed macular holes after cataract extraction. Am J Ophthalmol 2007, 144:252-259.
8. Yoshida M, Kishi S: Pathogenesis of macular hole recurrence and its prevention by internal limiting membrane peeling. Retina 2007, 27:169-173.
9. Gass JD. Lamellar macular hole: a complication of cystoid macular edema after cataract extraction. Arch Ophthalmol. 1976; 94: 793-800.
10. Michalewski J, Michalewska Z, Dziegielewski K, Nawrocki J. Evolution from macular pseudohole to lamellar hole – spectral domain OCT study. Graefes Arch Clin Exp Ophthalmol. 2011;249:175-178.
11. Freud KB, Ciardella AP, Shah V, Yannuzzi LA & Fisher YA (2002): Optical coherence tomography documentation of spontaneous macular hole closure without posterior vitreous detachment. Retina 22: 506–509.
12. Takahashi H & Kishi S (2000): Tomographic features of a lamellar macular hole formation and a lamellar hole that progressed to a full-thickness macular hole. Am J Ophthalmol 130: 677–679.
13. Tanner V, Chauhan DS, Jackson TL & Williamson TH (2001): Optical coherence tomography of the vitreoretinal interface in macular hole formation. Br J Ophthalmol 85: 1092–1097.
14. Theodossiadis PG, Grigoropoulos VG, Emfietzoglou I et al. (2009): Evolution of lamellar macular hole studied by optical coherence tomography. Graefes Arch Clin Exp Ophthalmol 247: 13–20.
15. Inoue M, Arakawa A, Yamae S, Watanabe Y, Kadonosono K (2012): Long-term outcome of macular microstructure assessed by optical coherence tomography in eyes with spontaneous resolution of macular hole. Am J Ophthalmol, 153:687–691.

16. Michalewska Z, Michalewski J, Nawrocki J (2010). Continuous changes in macular morphology after macular hole closure visualized with spectral optical coherence tomography. Graefes Arch Clin Exp Ophthalmol; 248(9):1249– 1255.
17. Hee MR, Puliafito CA, Wong C, et al. Optical coherence tomography of macular holes. Ophthalmology. 1995; 102:748-756.
18. Takahashi H, Kishi S. Optical coherence tomography images of spontaneous macular hole closure. Am J Ophthalmol 1999;128(4):519–520.
19. Privat E, Tadayoni R, Gaucher D, Haouchine B, Massin P, Gaudric A (2007): Residual defect in the foveal photoreceptor layer detected by optical coherence tomography in eyes with spontaneously closed macular holes. Am J Ophthalmol, 143:814–819.
20. Aditya Shreekant Kelkar, Devanshi Ramji Bhanushali, Jai Aditya Kelkar, Rachana Bharat Shah, and Shreekant Bhaskar Kelkar (2013), Spontaneous Closure of a Full-Thickness Stage 2 Idiopathic Macular Hole without Posterior Vitreous Detachment, Case Rep Ophthalmol, 4(3): 188–191. doi: 10.1159/000356125
21. Scassa C, Bruno M, Ripandelli G, Giusti C, Scarinci E, Cupo G (2011): Spontaneous closure of bilateral full-thickness macular holes without surgery: an eleven-year follow-up. PubMed 15:717-720.
22. Moisseiev E, Goldenberg D, Barak A, Loewenstein A (2009); Complete Spontaneous Resolution of Full-thickness Macular Hole With OCT-documented Restoration of Normal Foveal Contour; Retinal Thysician; Therapeutic and Surgical Treatment of the Posterior Segment
23. Michalewska Z, Cisiecki S, Sikorski B et al. (2008): Spontaneous closure of stage III and IV idiopathic full-thickness macular holes – a two-case report. Graefe's Arch Clin Exp Ophthalmol 246: 99–104.
24. Sugiyama A, Imasawa M, Chiba T, Iijima H (2012): Reappraisal of spontaneous closure rate of idiopathic full-thickness macular holes. Open Ophthalmol J, 6:73–74.
25. Win PH, Young TA: Spontaneous macular hole closure in bilateral macular holes. Semin Ophthalmol 2007, 22:167-169.
26. Mirza RG, Johnson MW, Jampol LM (2007). Optical coherence tomography use in evaluation of the vitreoretinal interface: a review. Surv Ophthalmol, 52(4):397-421.
27. Akiko Okubo, Kazuhiko Unoki , Keita Yamakiri, Munefumi Sameshima and Taiji Sakamoto (2013); Early structural changes during spontaneous closure of idiopathic full-thickness macular hole determined by optical coherence tomography: a case report, BMC Research Notes, 6:396
28. Milani P, Seidenari P, Carmassi L, Bottoni F: Spontaneous resolution of a full thickness idiopathic macular hole: fundus autofluorescence and OCT imaging. Graefes Arch Clin Exp Ophthalmol 2007, 245:1229-1231.