Case study

Fuch's uveitis: A case report

ABSTRACT

Introduction: Fuchs' uveitis (FU) is a chronic nongranulomatous anterior uveitis that accounts for 3% of all uveitis cases. Usually is asymptomatic but occasionally can cause floaters and decrease in visual acuity secondary mainly to complications like vitreous opacities, cataract and glaucoma. The diagnosis is clinic and treatment includes correction of complications.

Presentation of Case: 40-year-old woman presented with a complaint of progressive decreased vision in the right eye (OD). Slit lamp evaluation revealed in OD multiple stellate keratic precipitates, slight iris atrophy and hypochromia, a white cataract and no anterior chamber inflammatory reaction. Intraocular pressure in OD was high and was controlled with timolol.

On the basis of these findings and after excluding other aetiologies, a diagnosis of Fuchs' uveitis was made. Cataract surgery was performed.

Conclusion: This clinical case enhances the need of integration of clinical signs to don't sub diagnosis Fuch's uveitis and not overvalue the presence of iris heterochromia. This cases also reflect the good results obtained with cataract surgery associated with few complications in this type of uveitis.

Keywords: Fuchs' uveitis; cataract; glaucoma; iris atrophy

1. INTRODUCTION

Fuchs' uveitis (FU) is a chronic, nongranulomatous anterior uveitis that accounts for 3% of all uveitis cases [1].

The eponym 'Fuchs' heterochromic iridocyclitis' (FHI) has long been used and emphasizes the most obvious features. However, recently, the term 'Fuchs' uveitis' (FU) has been introduced to avoid overemphasizing heterochromia, which is striking when present but not disease-defining. For these reasons, the term FU will be used in this review from this point on [2].

The aetiology of FU is unknown but several theories have been proposed, including immune dysfunction and infection by *Toxoplasma gondii*, *Herpes simplex* and rubeola virus [3,4,5,6,7]. FHI occurs more commonly in the third and fourth decades of life with an equal gender distribution.

Patients with FU are often asymptomatic, experiencing no pain, redness or photophobia. When patients are symptomatic, they usually complain of floaters or decreased vision, secondary to ocular complications such as vitreous opacities, cataract and glaucoma. Although FU typically presents as a unilateral condition, 10% of patients have bilateral disease.

The diagnosis of FU is clinical and based on the following classic findings [1,3,4,8,9]:

- Iris atrophy with or without heterochromia: iris atrophy is a diagnostic criterion but heterochromia per se is not, being present in around 75% of cases. In darker irises, hypochromia can be very subtle or absent and in patients with lightly coloured irises, loss of pale anterior stroma leads to exposure of darker iris pigment epithelium resulting in hyperchromia (inverse heterochromia).
- Slight iridocyclitis: anterior chamber cells and flare are a result of blood-aqueous barrier breakdown rather than active inflammation, and this fact contributes to the poor response of FU to steroid therapy. Prognosis is generally good despite the

persistent inflammation and posterior synechiae and cystoid macular oedema are rare.

- Fine, diffuse and stellate keratic precipitates on the corneal endothelium. However, all types and distributions have been described.
- Fine vessels on the iris surface and crossing the trabecular meshwork.
- Vitreous disorders such as floaters, debris or cells.

Cataract and glaucoma are the most common and important complication.
Cataract is reported in 15%-75% of cases, and it is usually posterior subscapular but can rapidly progress to maturation [3,4]. In any young person with unilateral cataract and no history of trauma or steroid use, FU should be considered.
Glaucoma is present in 20%-60% of cases, and it is the most sight-threatening and challenging complication. The pathogenesis of glaucoma in FU is still poorly understood.
The differential diagnosis includes Posner-Schlossman syndrome, infection by *Herpes simplex* and other causes of heterochromia, such as congenital Horner's syndrome and diffuse iris melanoma.

2. CASE REPORT

A 40-year-old woman presented with a complaint of progressive decreased vision in the right eye (OD). Her previous medical and ophthalmologic history were unremarkable.
Best corrected visual acuity was hand motion at 50 centimeters in OD and 20/20 in left eye (OS). Slit lamp evaluation was normal in OS and revealed in OD multiple stellate and white keratic precipitates (Fig 1), iris atrophy with slight hypochromia, a white cataract (Fig 2) and no anterior chamber inflammatory reaction.

Fig 1: Keratic precipitates diffusely scattered on the entire corneal endothelial

Fig 2: Iris atrophy and cataract in the OD

Fundus examination was impossible in OD due to medial opacities and normal in OS. Ocular ultrasound revealed mobile hiperecogenic points in vitreous without retinal detachment in OD (Fig 3). Intraocular pressures were 29 mmHg in OD and 15 mmHg in OS.
Gonioscopy revealed an open-angle (IV Shaffer) with vessels crossing the trabecular meshwork in OD (Fig 4).

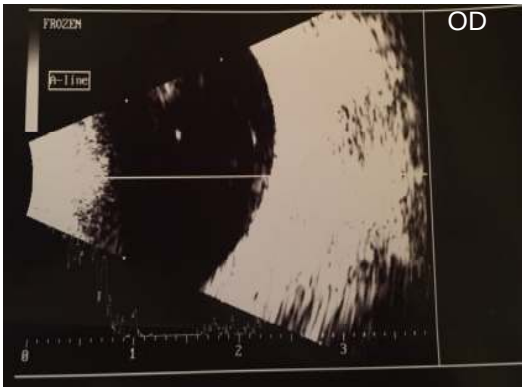

Fig 3: Vitreous debris



Fig 4: Gonioscopy revealing vases

On the basis of these clinical findings and after excluding other aetiologies, a diagnosis of Fuchs' uveitis was made and intraocular pressure was controlled with timolol 0.1%. Cataract surgery was planned and topical dexamethasone 1% and systemic steroid agents (40 mg/day) were started two days preoperatively. The phacoemulsification with posterior chamber intraocular lens implantation was performed. The only intraoperative complication to report was hyphema that resolved spontaneously (Fig 5). After surgery, the dose of steroid was gradually reduced over four weeks and on the 10th day after surgery, the best visual acuity in OD was 20/20.
Fundoscopy in OD was normal. Intraocular pressure was 16 mmHg under timolol treatment. Pachymetry was 580 µm in OD and 579 µm in OS. OCT of the optic nerve did not show loss of nerve fibre layer. However we decided to continue treatment with timolol to control ocular hypertension. After 8 months the ophthalmological examination was similar.

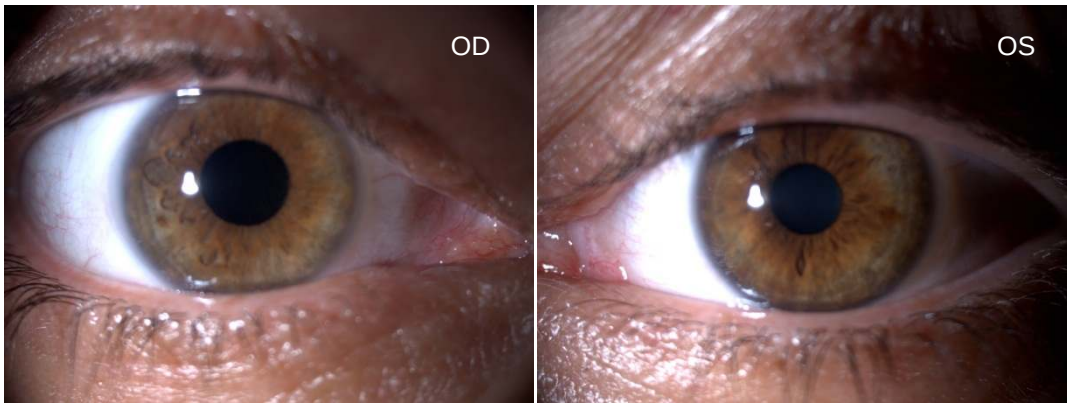

Fig 5: After phacoemulsification with posterior chamber intraocular lens implantation

3. DISCUSSION AND CONCLUSION

Fuchs' uveitis is sometimes misdiagnosed for two important reasons [7]: heterochromia is often mistakenly considered to be a hallmark of FU diagnosis and vitreous opacities that can be the first symptom is generally not considered as part of the diagnosis.

Unlike most uveitis, FU responds poorly to steroid therapy. For this reason, an accurate and timely diagnosis is important because continued steroid treatment is troublesome and can accelerate the development of cataract and glaucoma. Therefore, treatment is only needed for complications such as cataract, secondary open angle glaucoma and vitreous opacities.

A number of studies have shown that phacoemulsification with posterior chamber acrylic intraocular lens implantation is a safe and effective procedure in patients with FU [3]. The use of preoperative topical steroids and systemic steroids is controversial but can be used to prevent inflammatory exacerbations and produced a better recovery of the blood-aqueous barrier [10]. Although not pathognomonic for FU, a hyphema can occur after paracentesis during cataract surgery by rupturing the abnormal vessels crossing the trabecular meshwork (Amsler's sign), a complication that occurred in our case.
During the cataract surgery could have been taken aqueous humor and made the virus research in genome, PCR or ELISA. No post operative complications were reported like iridocyclitis exacerbation or macular edema.

Because of the excellent results obtained with cataract surgery, glaucoma has been considered the most serious complication and it is many times refractory to medical treatment. In our patient, we controlled the ocular hypertension with timolol and the patient maintains routine examinations.

In this case report the need for integration of clinical signs in order to avoid underdiagnosis of this pathology. Iris heterochromia is overvalued and iris atrophy is sometimes difficult to notice, for this reason, a recent paper describe near infrared autofluorescence as a promising objective technique to document precocious the iris changes in FU [11]. This case also strengthens that phacoemulsification cataract surgery is a safe and efficient procedure in this uveitis.

REFERENCES

1. You YA, Wu Y, Hu S. Surgical management of secondary glaucoma in Fuchs' heterochromic iridocyclitis. Graefes Arch Clin Exp Ophthalmol. 2013 Jul;251(7):1785-90.
2. Kreps, E. (2011). Fuchs' uveitis syndrome: No longer a syndrome? Master thesis, Univertiteit Gent, Belgium.
3. Tejwani S, Murthy S, Sangwan VS. Cataract extraction outcomes in patients with Fuchs' heterochromic cyclitis. J Cataract Refract Surg. 2006 Oct;32(10):1678-82.
4. Mohamed Q, Zamir E. Update of Fuchs' uveitis syndrome. Curr Opin Ophthalmol. 2005;16:356-63.
5. La Hey E, de Jong PT, Kijlstra A. Fuchs' heterochromic cyclitis: review of the literature on the pathogenetic mechanisms. Br J Ophthalmol. 1994;78:307-12.
6. Jones NP. Glaucoma in Fuchs' Heterochromic Uveitis: aetiology, management and outcome. Eye (Lond). 1991;5(Pt 6):662-7.
7. Norrsell K, Sjödell L. Fuchs' heterochromic uveitis: a longitudinal clinical study. Acta Ophthalmol. 2008 Feb;86(1):58-64.
8. Kimura, S.J., M.J. Hogan, and P. Thygeson, Fuchs Syndrome of Heterochromic Cyclitis. Archives of Ophthalmology, 1955. 54(2): p. 179-&.
9. Bouchenaki, N. and C.P. Herbort, Fluorescein angiographic findings and clinical features in Fuchs' uveitis. International ophthalmology, 2010. 30(5): p. 511-9.
10. Meacock WR, Spalton DJ, Bender L, Antcliff R, Heatley C, Stanford MR, Graham EM. Steroid prophylaxis in eyes with uveitis undergoing phacoemulsification. Br J Ophthalmol. 2004 Sep;88(9):1122-4.
11. Liu Q, Jia Y, Zhang S, Xie J, Chang X, Hou J, Li G, Koch DD, Wang L. Iris autofluorescence in Fuchs' heterochromic uveitis. Br J Ophthalmol. 2016 Jan 12.