Original Research Article

Visual acuity outcome in diabetic retinopathy after diode laser therapy.

Abstract

Background and objective:

Diabetic retinopathy as an important complication of diabetic mellitus is a common cause of blindness in diabetic people .The purpose of this study is to investigate the efficacy of the diode laser on visual acuity in patients with diabetic retinopathy.

Methods and material:

In this cross-sectional study, patients with diabetic retinopathy who were candidates for laser therapy in eye clinic enrolled in study. High-risk diabetic patients with retinopathy were being treated by a diode laser with wavelength of 810nm. The visual acuity was evaluated of 3, 6and 12 months after the intervention and compare with the patient data before of intervention. The data were collected with SPSS-15 and the distribution of descriptive data indeed of use of Nonparametric Test, Wilcoxon and Mann-Whitney compared the mean log Mar before and after laser photocoagulation on visual acuity.

Results:

This study was done on 50 patients (64 eyes) with diabetic retinopathy. The 27 (54%) of patients were male and 23 (46%) were female. The results of this trial showed clinically significant improvement of visual acuity from 1.21 log mar before laser therapy to 0.83 log mar 3 months after intervention. But this improvement decreased after 12 months of intervention that it does not show any statistically significant relation (p>0.0.5). The difference of visual acuity also before intervention and 12 month after that did not have any significant relation to gender also.

Conclusion:

According to these results, the patient's visual acuity recover 3 and 6 months after intervention but it did not have any significant difference at 12 months therafter. Retinal photocoagulations in patients with diabetic retinopathy have not causes to worsening patient's visual acuity long time.

Key words: Diabetic retinopathy, Visual acuity, Laser therapy

Introduction:

The high prevalence of diabetes increases its complications which damage the vascular system. This effect increased mortality and morbidity in diabetic patients, one of the vascular complications of diabetes is retinopathy. Diabetic retinopathy is one of the most serious health hazard. But development of diabetic control over the last 40 years reduced the risk of blindness. The higher prevalence of diabetes remained, the major problem of diabetic retinopathy. [2,1]

Diabetes is the leading cause of blindness in those aged 20 to 74 years. The risk of blindness in diabetics is 25 times more than other people. Blindness primarily occurs as a result of advanced diabetic retinopathy due to clinically significant macular edema. The proliferative diabetic retinopathy appear in more than 50% of patients with type 1 and more than 10% of type 2 patients who had passes from their diabetes 15 years. [1,3,4]

Diabetic retinopathy divided into two stages. The none proliferative diabetic retinopathy is the early stage and proliferative diabetic retinopathy is the advanced stage. None proliferative diabetic retinopathy usually appeared in the late first decade or early second decade of diabetes. The more severe non-proliferative stage had a more increasing chance of it to

convert to proliferative stage over 5 years [2]. This is an opportunity to provide early detection and treatment of retinopathy. Diabetic retinopathy is the most common chronic complication of diabetes, this complication is of the most important because it is the most destructive complication and it is the most common cause of blindness in those aged 25-74 years in America. [3]. Chronic hyperglycemia leads to increased secretion of vascular endothelial growth factor (VEGF) which change the resistance of tight junctions between cells and ultimately causes vascular leakage and creation of new blood vessels in the retina. [2] At the present time with improving the quality of health care, the chronic disease such as diabetes mellitus and its complications has become one of the most important public health problems [1]. Laser photocoagulation is recognized as one of known treatment in diabetic retinopathy. Laser treatment, found to reduces abnormal blood vessels in diabetic retinopathy. It is thought that the destruction of the peripheral parts of the retina by laser treatment reduces angiogenesis factors which generated from the parts of the ischemic retina. So, the macula is protected from damage caused by the diabetic proliferative retinopathy stage [5]. Retinal photocoagulation proposed over 50 years ago by "Mir Shvvyt Cross" which it was the first functional laser built in 1960 [6]. Since current therapies such as steroids and anti-neo-angiogenesis compounds (Anti-vascular endothelial growth factors) have temporary effect and require repeated injection into the vitreous fluid. The retinal photocoagulation also showed that 50% of patients who had retinopathy continued to progress despite retinal photocoagulation but its effect prevented the drastic reduction of visual acuity [7]. Because of the high prevalence of diabetes in some society [8,9], retinopathy have a major effect on quality of life in diabetes patients especially when visual acuity is less than 1/10 on the Snellen chart. Therefore, this study was done to determine the effect of diode laser treatment on visual acuity in patients with diabetic retinopathy.

Methods:

In this cross-sectional study 50 cases of diabetes who had needed laser photocoagulation enrolled In this study. The patients underwent complete eye examination and those who had high-risk proliferative retinopathy or clinically significant macular edema treated by diode laser with a wavelength of 810nm. Laser photocoagulation were done in focal or diffuse maculopathy just around the macula or directly on micro-aneurysms (The minimum distance from the macula to 500µm) and the number of points in each session 70-280, and the size of the laser spot was 50-100 µ. Pan-retinal photocoagulation also had the same wavelength of 810nm, the spot size were 300-500µ and the applied laser points were about 400-300 spot. Patients follow-up periods were 3,6, and 12 months after laser treatment and re-examination consist of , visual acuity by Snellen chart which converted to log mar. Visual improvement defines the reduction of Log mar. The data after collection enter to software SPSS 15 and distribution of descriptive data explained. Because of absence of normal distribution of data, to compare the mean Log mar visual acuity before of laser to Log mar visual acuity after laser photocoagulation the Wilkacson test was used. To compare between two groups the Man Witny test compared the average visual acuity after laser therapy during of 3,6 and 12 months of analysis which repeated variance at a different in the $\alpha \leq 0.05$were used. The laser photocoagulation in diabetic retinopathy is one of the management rules, but full explanation of treatment have done to the patients in comparison with other therapeutic approach and the patient have informed consent for this study.

Results:

In this study 50 patients (64 eye) attended, that 27 person of them (54%) were male and 23person (46%) Were female. The average age of patients was 61 ± 9.7 years. In table 1 the frequency of patients on the basis of sex and changes in Visual acuity before and after laser therapy shows. In this comparison, as it showed in table 1 the difference of visual acuity

before and after 12 months of intervention, increased in men and decreased in women, but this difference was not significant.

In comparison to the other depending variable on the amount of Visual acuity the patients visual acuity before the laser treatment was 1.21 Log mar (20/320 Snellen) that this, three months after intervention showed recovery of Visual acuity to 0.83 Log mar (20/135 snellen) $p<0.05$. The visual acuity after six months reached to 0.92 Log mar (20/166 snellen) that in the final follow up after 12 months it was 1.27 log mar (Figure .1) which it was not statistically different. $p>0.05$.

Table 1.Distribution of patients according of sex and visual acuity before and after laser photocoagulation

Variable	No	Mean Visual acuity (Log mar) ± SD	**Mann-Withney test**
Sex			**Wilkacson**
Male	34	0.15±0.54	**Z=1.25** **P= 0.23**
Female	30	- 0.34±0.82	
Visual acuity after 3 months	25	0.85±0.77	**Z=2.34** **P=0.02**
Visual acuity after 12 months	25	1.27±0.86	

The survey showed (Figure 1) that despite the improvement in Visual acuity before and after the laser treatment, but the long time differences was not statistically significant by using repeating ANOVA test. (P>0.05)

Figure 1. Comparative study of visual acuity before and after retinal photocoagulation

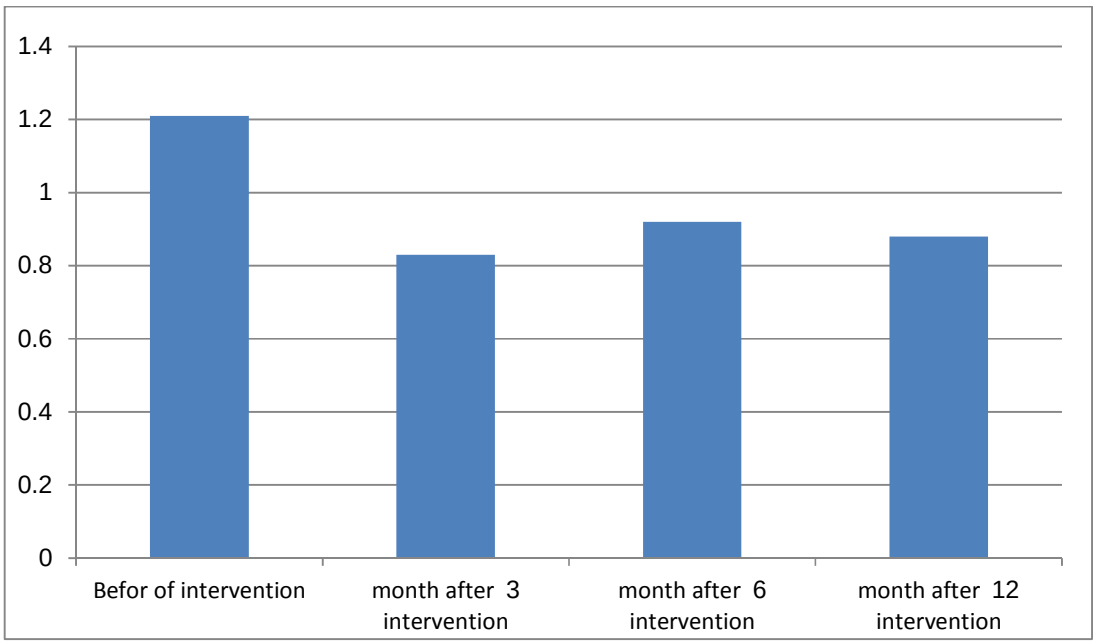

Discussion and conclusions

In our study, the Visual acuity of patients with diabetic retinopathy after 3 months and 6 months of laser treatment compared to baseline increased. In a study by Lima and his colleagues' Visual acuity of 48% of patients with diabetic retinopathy after 3 weeks laser photocoagulation improved [10]. Another review by Solaiman KA and his colleagues describe that visual acuity of patients with diabetic retinopathy after 6 months of laser therapy or after the intravitreal injections, or both regime have improvement. But, only in groups who had received combined treatments or only intravitreal injections it showed statistically significant difference. [11].

In these three groups [11] of Soliman and his colleagues as our study, the reduced Visual acuity after the intervention of laser photocoagulation could possibly be due to differences of

laser photocoagulation or lack of controlling the blood glucose, lipid and blood pressure. The other suggestion in this patient may be in advanced stage of retinopathy that the laser treatment alone has not impact on improvement of visual acuity. So, the above factors probably cause exacerbation of symptoms of retinopathy.

In a similar survey by the Jain and colleagues in diabetic macular edema, the visual acuity of patients from 20/45 before of retinal photocoagulation reached to 20/40 after 4 months that it was statistically significant [12]. Shimura.M and his colleagues found that visual acuity of 43% of diabetic patients with macular edema after 6 months of intervention had improvement [13].

In studies that evaluate the therapeutic methods in diabetic retinopathy for systematic meta-analysis, steroid injections and Anti-VEGF in the liquid inside the vitreous describe that only a small group which using these remedies obtain good vision and therefore it necessitate to investigate new therapies as part of the priorities of the therapy in diabetic retinopathy [14, 7].

In another study by Shrestha A and his colleagues invoked a comment that in less developed countries, laser therapy is now more available and it is the preferred treatment.[15] Our study result in short time was similar to this report, but current therapies including laser photocoagulation and intravitreal injection therapy have their treatment restriction. Therefore according to our study and other results [16] that emphasis in this paper, it is necessitated to do research to find an impressionable prevention and therapeutic manner in this common disease. The lack of timely lookup and accepting the initiation of treatment in the early stage of retinopathy indeed of small sample number of patients who were of two stage of retinopathy were the limitations of this research.

Conclusions:

Early visual improvement after laser treatment in patients with diabetic retinopathy and reduce the impact of laser treatment in the long term could be appearing due to progression or not controlling retinopathy risk factors. So, awareness to control the strengthening diabetic retinopathy risk factors as well as there is not a definite curing approach. Hence, while the patient experience of more effective therapies they already should know the next time visit to control their diseases.

Suggestions:

Due to the high incidence of diabetes and its debilitating effects, it is essential that precipitating or exacerbating factors such as hyper lipidemia and hypertension must be controlled. Obviously the information gained from this study is to carry out further investigation to provide the best approach of management to increasing the quality of life in diabetic retinopathy patients.

References:

1.Ghasemi H, Afshar R, Poor Farzam Sh, Frequency of diabetic retinopathy and related factors in ophthalmologic consults in shahid mostafa khomeini hospital between 1998-2002. Journal of Army University of Medical Sciences of the I.R. Iran (Jaums) 2005; 3(10): 584-579

2. Fletcher EC, Riordan-Eva P, Witcher J,Vaughan and Asbury's general ophthalmology.17th ed. philadelphia:MC Graw-Hill companies;2008.p.186-211

3. Longo D , Fauci A, Kasper D , Hauser S, Jameson J , Loscalzo J, Harrison's Principles of Internal Medicine. 17th Ed. New York: McGraw-Hill Medical; 2008.p.2275-2476

4. McKay R, McCarty CA, Taylor HR. Diabetic retinopathy in Victoria, Australia: the visual impairment project. Br J Ophtalmol 2000; 84(8):865-870

5. Boscia F, Current approaches to the management of diabetic retinopathy and diabetic macular edema. Drugs. 2010; 70(16):2171-200

6. Meyer-Schwickerath G. Light Coagulation. St Louis, MO: CV Mosby Company; 1960.

7.Raczyńska D, Zorena K, Urban B, Zalewski D, Skorek A, Malukiewicz G, Sikorski BL

Current trends in the monitoring and treatment of diabetic retinopathy in young adults. Mediators Inflamm. 2014;2014:492926. doi: 10.1155/2014/492926. Epub 2014 Feb 13.

8. Heydari B, Yaghoubi G, Yaghoubi MA, Miri MR. Prevalence and risk factors for diabetic retinopathy: an Iranian eye study. Eur J Ophthalmol 2012; 22: 393-7.

9.Javadi MA, Katibeh M, Rafati N, Dehghan MH, Zayeri F, Yaseri M, et al. Prevalence of diabetic retinopathy in Tehran province: a population-based study. BMC Ophthalmol. 2009 Oct 16;9:12. doi: 10.1186/1471-2415-9-12.

10.Lima GomesV ,Milaqros Razo-Blanco,Hernadez D. Charactristic associated with visual important after focal photocoagulation in diabetic macular edema.cir cir2012;80(4):311-9

11. Solaiman KA, Diab MM, Abo-Elenin M. Intravitreal bevacizumab and/or macular photocoagulation as a primary treatment for diffuse diabetic macular edem Retina 2010; 30(10):1638-45

12. Jain A, Collen J, Kaines A, Hubschman JP, Schwartz S. Short-duration focal pattern grid macular photocoagulation for diabetic macular edema: four-month outcomes. Retina 2010; 30(10):1622-6

13. Shimura M, Yasuda K, Nakazawa T, Ota S, Tamai MK. Effective treatment of diffuse diabetic macular edema by temporal grid pattern photocoagulation.Department of Ophthalmology, Tohoku University Graduate School of Medicine, Sendai, Miyagi ,japan. Ophthalmic Surg Lasers Imaging 2004; 35(4):270-80

14. Ford JA, Lois N, Royle P, Clar C, Shyangdan D, Waugh N. Current treatments in diabetic macular oedema: systematic review and meta –analysis. BMJ Open 2013 Mar 1; 3(3). pii: e002269. doi: 10.1136/bmjopen-2012-002269

15. Shrestha A, Khadka D, Karmacharya A, et al, Is laser photocoagulation still effective in diabetic macular edema? Assessment with optical coherence tomography in Nepal. Int J Ophthalmol 2012; 5(2):217-21.

16. Das A, McGuire PG, Rangasamy S. Diabetic Macular Edema: Pathophysiology and Novel Therapeutic Targets. Ophthalmology. 2015 Apr 30. pii: S0161-6420(15)00305-X. doi: 10.1016/j.ophtha.2015.03.024. [Epub ahead of print]