

ORIGINAL RESEARCH ARTICLE

Anti-hemorrhoid Evaluation of Selected Medicinal plants used in

Bali North-East Nigeria for the Treatment of Hemorrhoids (Pile)

ABSTRACT

A medicinal plant is any plant in which one or more of its organs contain substances that can be used for therapeutic purpose or which are precursors for the synthesis of useful drugs. In this research, five (5) selected plants were screened for antihemorrhoid activities in mice. The extracts were obtained from whole plant or parts of plants such as root, stem, leaves and seeds and include the following plants: *Khaya senegalensis*, *Euphorbia hirta*, *Parkia biglobosa*, *Newbouldia leavis* and *Prosopis africana*. Hemorrhoid (pile) was induced in a group of five mice of five animals per group using *Jatropha* oil (*Jatropha curcas*, *Euphorbiaceae*) (I.P) and using Pilex granule as the control drug. Group I received 10 mg/kg Pilex granule, and 100, 200, 400, and 600 mg/kg b.w of *A. leiocarpus*, *N. leavis*, *P. africana*, and KEP for groups II, III, IV and V respectively. *A. leiocarpus* and KEP (mixture of *K. senegalensis*, *E. hirta* and *P. africana*) showed the highest antihemorrhoidal activities in mice than the other plants and compared with the standard drug Pilex granule. However, all the plant extracts showed significant recto - anal coefficient at potent levels. The study showed that the extracts of the plants investigated possessed antihemorrhoid activities with *A. leiocarpus* and KEP demonstrating the highest activity in mice.

Keywords: Anti-hemorrhoid, medicinal plants, mice, pilex granule, *Jatropha* oil.

Introduction

Hemorrhoids are abnormal masses of dilated blood vessels in swollen tissue that occurs internally in the anal canal or externally around the anus which may be bleeding, pain or itching.

(the dilation of varicose of the vessel of the superior inferior rectal plexuses of veins)

It has (have) been a common and painful human disease for decades. The exact prevalence in most developing countries has not been determined in spite of the growing problems associated with this ailment especially among the local populace in North-east Nigeria States, which are majorly due to dietary habits. This disease is frequently encountered in

developing countries [1]. Various dilations of the internal hemorrhoids (;) as well as physiological dilations which exist at infancy, is presumed to have developed into varicosities under the influence of wide range of factors. The predisposing factors include heredity (hereditary), age, anal sex, and prolong labour at pregnancy . The precipitating factors comprise (comprises) cathartic abuse, diarrhoea, enemata, constipation, infection and spasms or ('a stony' – this usage may be cancelled) dietary intake which put (puts) extra pressure on the intestinal mucosa linings which may subsequently result in rupture of the mucosa linings of the small intestine [2].

There are two types of piles, internal piles and external piles. Internal piles expand inside, along the anal. The common symptom (symptoms) of internal piles is (are) the painless blood loss. The internal piles are totally prolapsed. External piles extend close to the anus. The colour of external piles is same as the skin. The outside piles forms thrombus. The outside piles are painful. When the external pile ruptures, it bleeds. The blood loss is more disturbing, and it is the major (typical) concern for considering a therapeutic measure by a medical practitioner. Prolapsed condition on the other hand, is an oral dysfunctional effect of piles [3].

This research was aimed at evaluating some selected medicinal plants used in North-east Nigeria for the treatment of hemorrhoids with a view to ascertain this claim in traditional medicine, thereby identifying (which of) the plants (has) having the best anti-hemorrhoids activity (property) in mice models.

MATERIALS AND METHODS

Plant Collection and Identification

The plants species (*Parkia biglobosa*, *Prosopis africana*, *Euphorbia hirta*, *Khaya senegalensis*, *Newbouldia leavis* and *Anogeissus leiocarpus*) were collected from Bali and

Takum forests in 2014 (4), and were identified by Mr. Cletus A. Ukwubile of Science Laboratory Technology Department, Federal Polytechnic, Bali, where voucher numbers were deposited for the plants.

Attempt has been made to expel scyballous masses from the rectum by traditional medical practitioners using different plant species using any one (of) or all the following preparations: concoction, decoction and maceration.

Preparation and Extraction of Plant Materials

The plants were air-dried for two weeks and then, plant parts were ground into powder, (and) weighed and stored for onward use. One of the plant(s) (*Newbouldia leavis*) extract was prepared (extracted) with water following the method of its preparation in traditional medicine while others were extracted with absolute ethanol 99.1% (v/v)(,) and were soaked for 24 hrs using cold maceration technique. The extracts were concentrated to dryness under reduced pressure in rotary evaporator and dried in (a) desiccators. Percentage yields for the extracts were as follows: *Parkia biglobosa* (5.1%), *Prosopis africana* (5.6%), *Euphorbia hirta* (4.2%), *Khaya senegalensis* (6.2%), *Newbouldia leavis* (8.2%) and *Anogeissus leiocarpus*(4.5%).

Grouping of Swiss albino rats

The animals were grouped into five (5) groups of 5 according to each plant extracts.

Experimental Animals

Inbred male and female Swiss albino mice (18-29 g in weight) that were housed in standard conditions of temperature ($22 \pm 3^{\circ}\text{C}$), relative humidity ($55 \pm 5\%$), and light (12h light-dark cycle) before and during the study were included in the experiment. They were fed with standard pellet diet (obtained from animal house of Department of Pharmacology and Clinical Therapeutics, Ahmadu Bello University Zaria) and water *ad libitum*. All the

experimental protocols were approved by the Institutional Animal Ethic Committee (IAEC) of the Ahmadu Bello University Zaria and Health Research Extension Act of 1985(Public Law November 20, page 99-158) USA. The animals received humane care as per the guidelines prescribed by Committee for the Purpose of Control and Supervision of Experiments on Animals (CPCSEA), Federal Ministry of Environment and Forestry, Nigeria.

Experimental Protocols

Two sets of experiments were carried out. The first set was used to improve an existing experimental model of hemorrhoids mentioned by [3], and to validate the same by using pilex granules (PG), *Newbouldia leavis* extract (NE) which was the plant used widely by traditional healers in North-east Nigeria to treat piles(,) and a combination of both extracts. The protocol was designed to quantify the extent of plasma exudation and to determine the levels of inflammatory cytokines such as TNF- α and IL-6, which are associated with hemorrhoids[3].

In the second set, the effect of PG, AL, and a combination of some plant extracts were further evaluated by determining the recto - anal coefficient (RAC), severity score, and the histopathological evaluation[4].

Evaluation of Anti-hemorrhoid property against *Jatropha* oil-induced hemorrhoid in mice

Mice of both sexes (20-29 g) were randomized based on their body weights and were divided into 5 groups (G-1 to G-5), with each group consisting of 5 animals (n=5). G-1 animals received PG (Pilex granule) (10 mg/kg) and served as positive control ; G-2 animals received AL (100 mg/kg),while G-3 , G-4, and G-5 animals received NL, PA and KEP (200, 400, and 600 mg/kg b.w; i.p , respectively). Haemorrhoids were induced in all the groups (.)except normal control group, by applying *Jatropha* oil preparation in five days . A day after induction, all the animals were subjected to respective treatment as assigned to the groups once daily for five days. On the fifth day, 1 h after the treatment, all the animals were

ethanized by exsanguinations under deep isoflurane anaesthesia and recto - anal tissues (20 mm in length) were isolated. They were evaluated for the severity score, weighed(,)and fixed in 10% formalin solution for histological examination.

The RAC was calculated using the formula,

$$\text{Rectoanal coefficient} = \frac{\text{Weight of recto - anal tissue (mg)}}{\text{Body weight (g)}}$$

Histological observation of the rectoanal tissue was carried out in order to determine the appearance of inflammatory cells, congestion, haemorrhage, vasodilatation, and medium to high degrees of necrosis [5].

RESULTS AND DISCUSSION

The study showed that the oil from *Jatropha* seeds was toxic at 1000 mg/kg body weight in the mice (tables).

Table 1: LD₅₀ Determination of *Jatropha* oil from *Jatropha curcas*

Dosage (mg/kg)	Animal died / Animal survived
10	0/5
100	0/5
1000*	1/4
1600	ND

LD₅₀ = 1118 mg/kg b.w , ND (not determine), * toxic dose

Hemorrhoid induction was on the increase as the dosage was increased, leading to weight loss in mice (table 2) [6]. The fact that oil from the seeds of *Jatropha* caused acute inflammation in the rectum of the mice and (as well as) mortality was witnessed at the dose 1000 mg/kg b.w suggest that at higher dose, the extract is toxic, making it a potential carcinogen (in cancer research)[7]. In this case, loss of weight in the animals after induction

is a symptom of hemorrhoids due to loss of blood and severe inflammation in the recto - anal region of the mice, coupled with anal itching as seen in the animal groups.

Table 2: Effect of Jatropha oil on the body weights of mice before and after induction

Test groups	Weight Before (g)	Weight After (g)
Group I Control 20 mg/kg	29.6	25.2
Group II 50 mg/kg	28.6	24.1
Group III 100 mg/kg	25.2	20.1
Group IV 150 mg/kg	28.0	22.2
Group V 200 mg/kg	26.6	20.2

Previous research had proved that hemorrhoids are pathological condition, which is characterized by severe vasodilation at the rectoanal region, which leads to inflammation of the surrounding tissues, (thus) further leading to secondary complications such as extravasations of fluid into interstitial space mainly due to increased vascular permeability and migration of large quantity of inflammatory white blood cells (granulocytes and monocytes)[8].

In the present study, Jatropha oil from seeds of *Jatropha curcas* (*Euphorbiaceae*) has been used as an inducer or a phlogistic agent to induce experimental hemorrhoids. In this study, it is possible that Jatropha oil causes inflammation due to the release of soluble factors involving inflammatory lipid metabolites. These factors, alone or in combination with other factors, regulate the activation of resident cells (Fibroblasts, endothelial cells, macrophages, and mast cells) and newly recruited inflammatory cells (Monocytes, lymphocytes,

neutrophils, and eosinophils) leading to systemic response to inflammation [8-9]. This mechanism explained here was not different from that of the present study (Figure 1d).

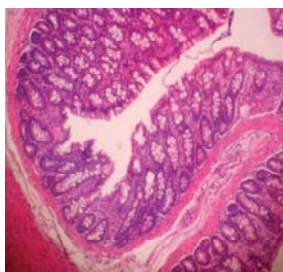
The normal control group showed normal cell architecture of the recto - anal region[10-11] (Figure 1a). However, intraperitoneal administration of plant extracts of AL, NL, PA, and KEP showed remarkable vasoconstriction of the rectum (table 3). The greatest healing of the rectum were shown by AL (*Anogeissus leiocarpus*) and KEP (*K. senegalensis*, *Euphorbia hirta*, *Parkia biglobosa*) mixed in 40:40:40 mg/kg ratios, which was evident in the reduction of tissue weights after treatment, and these also confirmed the healing of the mucosa linings of the small intestine of mice by the plant extracts (Figure 1 a-c). Plant extracts have (has) been used for healing wounds, correct disorders internally(,) and to promote(s) immune responses [11]. The extracts from these must have exerted the same effects on the experimental animals in dose-dependent fashion. These results were comparable with that of the standard control drug (Pilex) at $p \leq 0.05$ (one-way ANOVA). All the extracts produced better recto - anal coefficient values than the first line drug Pilex (table 3).

Table 3: Effect of extracts on rectum after drug administration (i.p)

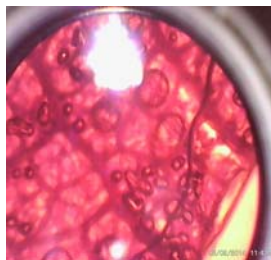
Extract dose (mg/kg b.w) (n=5)	Rectoanal coefficients (g)	Inference
Group I Control Pilex (10 mg)	0.6 ± 0.22*	Moderate healing
Group II AL 100	0.1 ± 0.20 TM	*Strong healing
Group III NL 200	0.4 ± 0.18	Moderate healing
Group IV PA 400	0.3 ± 0.15	Moderate healing
Group V KEP 600	0.2 ± 0.10 TM	*Strong healing

AL (*Anogeissus leiocarpus*), NL (*Newbouldia leavis*), PA (*Prosopis africana*), KEP (*Khaya senegalensis*, *Euphorbia hirta*, *Parkia biglobosa*), Results are means ± SEM. The lower the

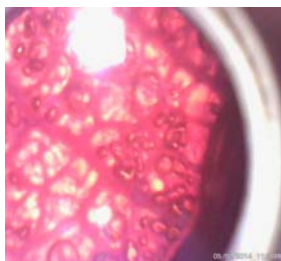
values, the more efficacy of the drug, TM More efficacy, * Statistical significant at $p \leq 0.05$ (One-way ANOVA).



a.



b.



c.



d.

Figure 1: Medicinal plants effects on rectoanal tissue in mice in Jatropha oil-induced hemorrhoids; a; hemorrhoid induced in recto anal tissue 40x, b-c 40x ; healing of tissue after drug administration with *Anogeissus leiocarpus*, d; mouse developed pile after five days of induction with Jatropha oil, indicates higher degrees of necrosis, medium necrosis.

CONCLUSION

Medicinal plants are a source of many biological ingredients which cannot be ignored. The study therefore showed that the extracts of *Anogeissus leiocarpus*, *Khaya senegalensis*, *Euphorbia hirta*, *Parkia biglobosa* and *Newbouldia leavis* possess antihemorrhoid properties

in mice. But from the study, extracts of *Anogeissus leiocarpus* and KEP (*Khaya senegalensis*, *Euphorbia hirta*, *Parkia biglobosa*) presented the strongest antihemorrhoid activity in mice than the rest of the plants. These plants can be used as medication for the treatment of hemorrhoids (pile) in traditional medicine, and justified their acclaimed use for treating (of) piles in North-east Nigeria.

The plants thus(,) represent sure sources for (towards)the development of conventional medicines for the treatment of piles other than surgery(,) which normally is very expensive with high risk. However, the precise molecular mechanism behind the antihemorrhoidal activities of these plant extracts and the compounds responsible for the observed activity (,) need to be explored in future studies.

ACKNOWLEDGMENT

The authors are grateful to Mr. Ibrahim of the Department of Pharmacology and Clinical Therapeutics, Ahmadu Bello University Zaria, for his help in this work (,) and also the traditional medical practitioners in Bali, Taraba State and beyond, who helped us during the ethnomedicinal survey of these plants especially Mama Daniya Bali (Age 102 years).

CONFLICT OF INTERESTS

We declare no competing interests.

REFERENCES

1. Abayomi S . Medicinal plant and Traditional Medicine in Africa. Spectrum Books, Ibadan,2006: 1-23.
2. Alma-Ata KF. Conference on plants in the Development of Modern Medicine. University College London, November 22-25th,2009, UK.
3. Elvin M . Traditional Medicine in Nigeria. (Ed.). Federal Ministry of Health, Nigeria Bulletin No 120,2014; Vol. 45: 56-59.
4. Evans WF and Trease, G.E . Naturally Occurring Phytol Esters. (Ed.) C.R.C Press.

London; 2004: 78.

5. Jaijjoy KL . Anti-inflammatory, activity of the water extract of *Terminalia chebula* Retz. in Rats. *Plant Medica*.2012; Vol. **78**:112.
6. Lorke D. A New Approach to Practical Acute toxicity Testing. *Achieves of Toxicology*, 1983; **54**, 275 – 287.
7. Sowemimo AA, Fakoya FA, Awopetu I, Omobuwajo OR, Adesanya SA. Toxicity and mutagenic activity of some selected Nigerian plants. *J Ethnopharmacol*, 2007, **113**:427–432.
8. Janju HM . African Traditional Medicine, A Case Study of Hausa. In: Medicinal Plant 1964, Ibadan Federal Department of Forestry Research, 2008; Vol. **I** and **II**.
9. Lestrangle R . A History of Herbal Plant (Eds.) Augurs and Robertson, London, 2013:90-98.
10. LewisWH, Evin – Lewis MF. Medical Botany: Plant Affecting Man’s Health. John Wiley and Son London 2nd edition; 2008:56-78.
11. Noto T . Melanogenesis inhibitory, anti-inflammatory, and chemo preventive effects of limonoids from the seeds of *Azadirachta indica* A. Juss. (Neem) *Journal of Oleo Science*,2009; Vol. **58** (11):581-594.

.....