UNDER PEER REVIEW

Case study

Metastatic tumor of the spermatic cord from pancreatic cancer: A case report

Abstract

This report describes a case of metastasis to the spermatic cord from pancreatic cancer. A 60-year-old patient complaining of pain and elevation of the right scrotal contents, who had been treated for pancreatic cancer, was suspected of having spermatic cord tumor. He underwent high orchiectomy for pain management and pathological diagnosis. The tumor was a metastatic adenocarcinoma from pancreatic cancer. Pancreatic cancer accompanied by spermatic cord metastasis is extremely rare. In patients with a mass in the spermatic cord and a history of neoplasm, the possibility of metastasis from the primary cancer should be considered.

Keywords: metastasis, pancreatic cancer, spermatic cord tumor

Introduction

Metastatic carcinoma of the spermatic cord from pancreatic cancer is extremely rare: even less common than primary tumors of the spermatic cord[1,2]. Accordingly, this condition's clinicopathological characteristics remain unknown. Advanced pancreatic cancer often metastasizes to lymph nodes, the lungs, or the liver, but they metastasize to the spermatic cord very rarely. We describe a case of adenocarcinoma of pancreas that metastasized to the spermatic cord.

Case presentation

From 2015, a 60-year-old man received chemotherapy every week at our hospital for pancreatic cancer: 125 mg/m^2 paclitaxel and 60 mg/m^2 gemcitabine. However, subsequent radiographic examination showed progressive disease with metastasis to multiple bone, liver, and lung. He was admitted to our department with the complaint of pain and elevation of the right scrotal contents. He had noticed it 2 months prior and had observed an increase of its size.

UNDER PEER REVIEW

Physical examination revealed that his vital signs were stable. A hard, fixed mass with a size of 5 × 3 cm, accompanied by oppressive pain, was felt in the right inguinal region. Ultrasonography revealed a mass-related lesion in the right spermatic cord. A contrast-enhanced computed tomography scan revealed a heterogeneous, slightly enhanced, 6-cm-diameter groin mass in the region of the right spermatic cord (Fig. 1). A spermatic cord tumor was suspected. Based on the clinical findings, we cannot deny that this tumor was potentially malignant.

We performed right high orchiectomy for pain management and pathological diagnosis. During the operation, the tumor was found in the spermatic cord, exhibiting invasive growth to the adjunct structures, but it did not invade the epididymis or testis. The resected specimen involved a solid mass, with a grayish-white tumor in the cut surface. It was located in the lower part of the spermatic cord (Fig. 2). Histopathological examination revealed a well to poorly differentiated adenocarcinoma that had infiltrated diffusely throughout the connective tissue surrounding the spermatic cord (Fig. 3). Histopathological findings show that the spermatic cord tumor was compatible with metastasis from the pancreatic cancer.

The postoperative course was uneventful. Pain subsided postoperatively. No analgesics were needed. The patient received no adjuvant chemotherapy. He received the best supportive care.

Discussion

The spermatic cord is an extremely rare site for distant metastasis from a neoplasm. The primary carcinomas reported in 1983 to metastasize to the spermatic cord and epididymis most frequently were those of the stomach (42.8%) and prostate (28.5%)[1,3]. Autopsy studies have revealed only two metastatic sites (0.01%) of the spermatic cord among 13,500 autopsy cases, both of which were from a primary gastric cancer[2,4]. Other reported primary sources of metastases to the spermatic cord include the colon (28.9%), the rectum (7.9%), the pancreas (15.8%), the bowel (13.2%), the bladder, lung, and brain[5].

Most patients with metastatic spermatic cord tumors have a painless scrotal mass, although a lower inguinal mass and enlargement of the testis can also occur. Metastatic spermatic cord tumors are most often misdiagnosed as inguinal hernia, hydrocele, or testis tumor. Spermatic cord tumors generally present as firm, nontender, and nontransluminant masses that are separable from the testis. The mechanisms of metastasis to the spermatic cord and paratesticular tissues from primary malignant neoplasms have not been elucidated precisely. However, several possibilities have been

UNDER PEER REVIEW

proposed. The main routes have been postulated as vascular and lymphatic routes. Other routes involving retrograde extension through the vessel, either along its lumen or by direct extension via the vessel wall, and transperitoneal seeding through the patent tunica vaginalis have been proposed[2,3]. In our case, hematogenous or lymphatic spread might have occurred, as inferred from evidence of multi-organ metastasis at the time of primary diagnosis.

Pancreatic cancer with spermatic cord metastasis is already an advanced disease. The prognosis of a metastatic tumor in the spermatic cord has been typically unfavorable, as reported previously [3,4]. The mean survival time after diagnosis was reported to be approximately 9 months[1,3]. Although curative resection of metastases might not improve survival, additional cases must be studied to evaluate the potential benefits of surgery in patients with spermatic cord metastasis.

Conclusion

Spermatic cord solid masses are usually not regarded as spermatic cord metastases from primary neoplasms such as pancreatic cancer or gastrointestinal tract cancers. We did not initially consider this case to be a metastasis from pancreatic cancer. However, in patients with solid mass of the spermatic cord and a history of neoplasm, the solid mass of the spermatic cord should be considered as possibly originating from metastasis of the primary tumor.

Conflict of interest

The authors declare that they have no conflict of interest.

References

1. Matsutani T, Nomura T, Hagiwara N, et al. Laparoscopic Diagnosis for Spermatic Cord Metastasis from Esophageal Squamous Cell Carcinoma. J Nippon Med Sch. 2015;82:304–307.
2. Dutt N, Bates AW, Baithun SI, et al. Secondary neoplasms of the male genital tract with different patterns of involvement in adults and children. Histopathology. 2000;37:323–331.
3. Algaba F, Santaularia JM, Villavicencio H, et al. Metastatic tumor of the epididymis and spermatic cord. Eur Urol. 1983;9:56–59.

UNDER PEER REVIEW

4. Hirano D, Ohkawa M, Hasegawa R, et al. Metastatic Tumor of the Spermatic Cord in Adults. Case Reports in Urology. 2015;747261:7.

5. Kaya C, Tanrikulu H, Yilmaz G, et al. Spermatic cord metastasis as an initial manifestation of non-small cell carcinoma of the lung. Int J Urol. 2006;13:846–848.

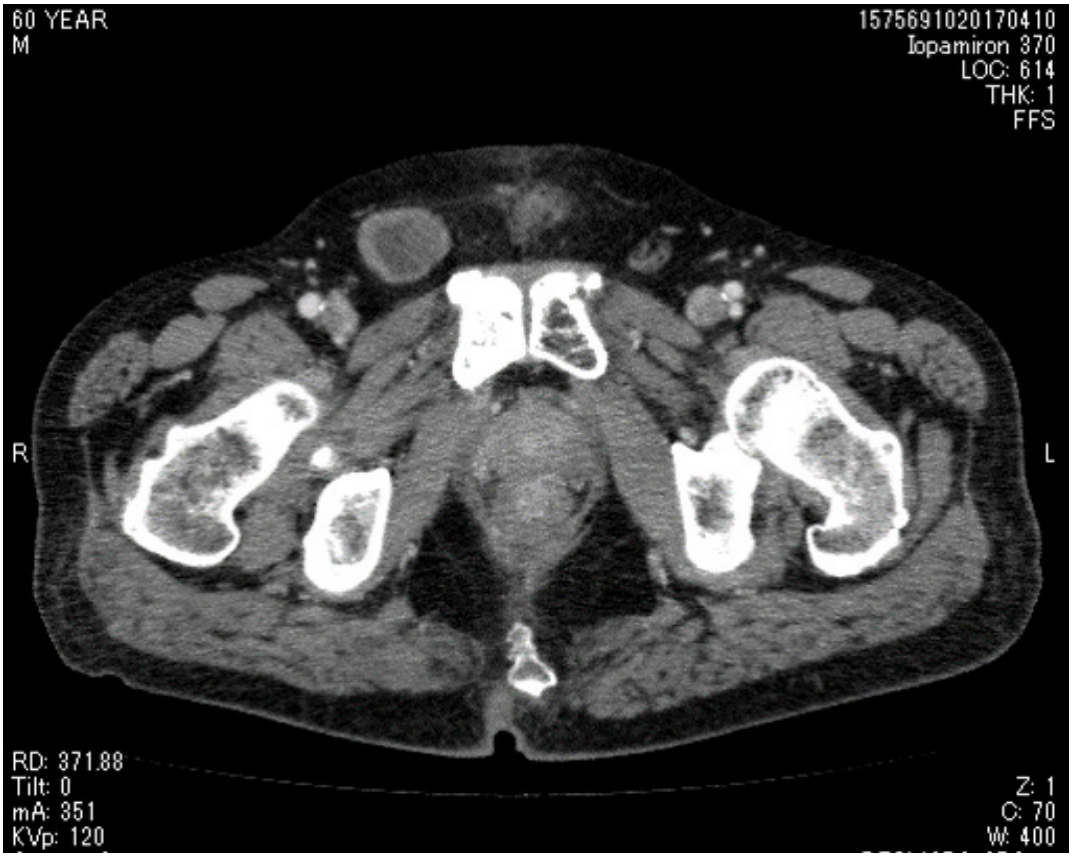

Figure 1.

Contrast-enhanced computed tomography scan showed a 6-cm-diameter heterogeneous, slightly enhanced groin mass in the region of the right spermatic cord.

UNDER PEER REVIEW

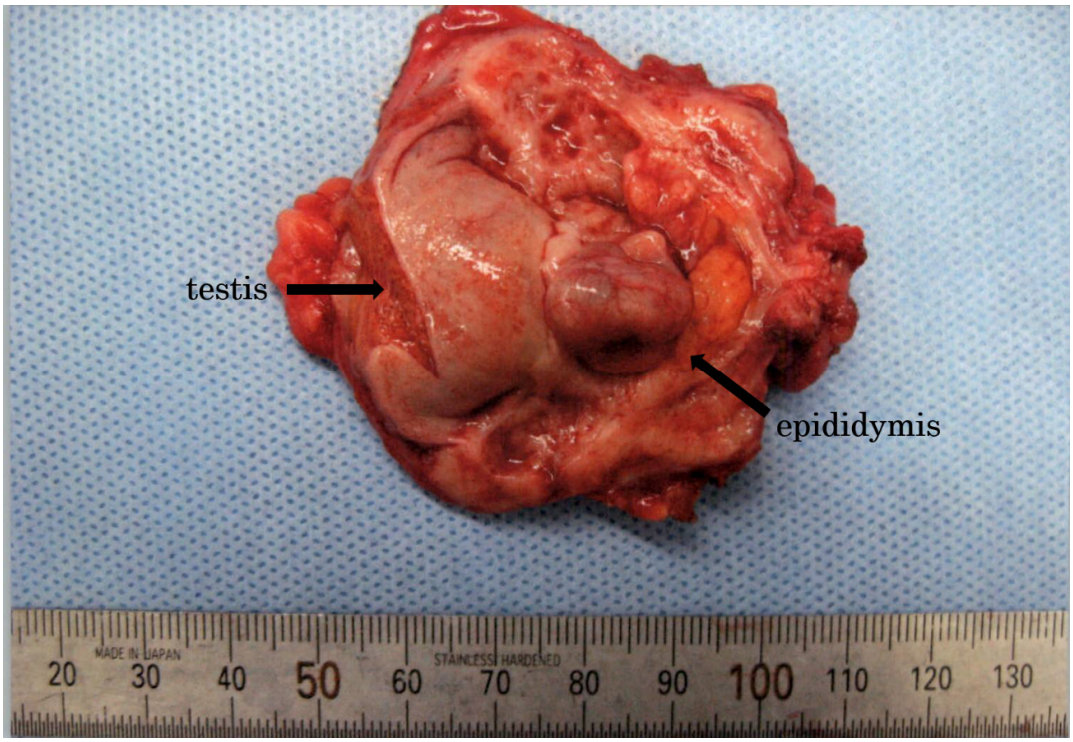

Figure 2.

The tumor, which was located in the spermatic cord and which showed invasive growth to the adjunct structures, did not invade the epididymis or testis. The resected specimen involved a solid mass with a grayish-white tumor in the cut surface.

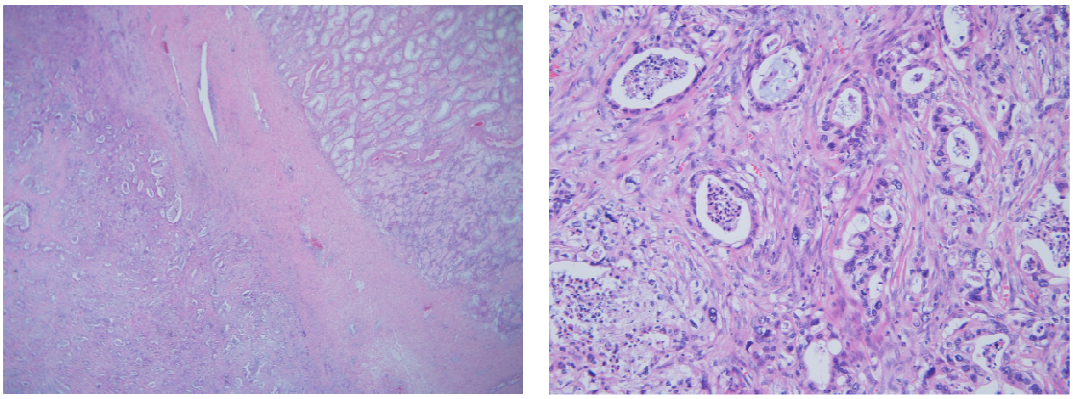

Figure 3.

Histopathological examination revealed a well to poorly differentiated adenocarcinoma that had infiltrated diffusely throughout the connective tissue surrounding the spermatic cord.