Case Report

Collision tumor at the gastroesophageal junction; coexistence of basaloid squamous cell carcinoma and small cell neuroendocrine carcinoma

Abstract: Basaloid squamous cell carcinoma (BSC) is a poorly differentiated and rare variant of squamous cell carcinoma. It is frequently seen in the upper respiratory and gastrointestinal systems. Neuroendocrine tumors originate from the neuroendocrine system and may be seen at any site of the body. Small cell neuroendocrine carcinoma (NEC) belongs to the poorly differentiated neuroendocrine tumor group, and tumors can be located at various sites, most commonly occurring in the lungs. In light of the current literature on these carcinomas, this case study reports a 61-year-old male in whom these poorly differentiated tumors were found to coexist. To the best of our knowledge, coexistence of BSC and small cell NEC at the gastro-esophageal junction is quite a rare condition and the first case report in the literature. In this case report, coexistence of two poor-differentiated tumors has been discussed under the light of the current literature.

Key words: Collision tumor, Basaloid squamous cell carcinoma, Small cell neuroendocrine carcinoma

1. INTRODUCTION

Collision tumor refers to the incidental coexistence of two different and independent tumors. This entity is very rare and has an obscure pathophysiology; real collision tumors of the gastro-esophageal junction are quite rare (1). BSC, first described by Wain et al. in 1986 as a laryngo-pharyngeal tumor and a poorly differentiated and rare variant of typical squamous cell carcinoma (2), comprises 0.3% to 4% of all esophageal carcinomas and is a biologically aggressive and malignant cancer (3). Neuroendocrine tumors originate from the neuroendocrine system at any site of the body. Tumors developing from these cells have a diverse clinical course and prognosis and are classified into two groups (well or poorly differentiated) according to the World Health Organization's 2000 neuroendocrine tumor classification. Small cell NEC is the most aggressive, poorly differentiated high-grade malignant tumor. Small cell NECs of the esophagus are seen quite rarely and constitute 0.8% to 2.4% of all esophageal carcinomas (4). First defined in 1952 (5), tumors representing small cell NEC is found in different locations throughout the body, but are most commonly observed in the lungs.

Coexistence of BSC and small cell NEC is quite rare in a case where a tumor is located in gastro-esophageal junction, and to the best of our knowledge, our case is the first in the literature. In this case report, coexistence of two poorly differentiated tumors has been discussed under the light of the current literature.

2. CASE

A 61-year-old male patient was admitted to our clinic due to epigastric pain, weight loss, and dysphagia. An ulcero-vegetant mass lesion that narrowed the lumen beginning from the 38th cm of the esophagus and extending to the cardia of the stomach was detected on endoscopy. Computed tomography of the thorax revealed an irregular wall thickening that began from the distal esophagus and extending to the cardia-major curvature of the stomach (Figure 1). The patient underwent total gastrectomy and distal esophagectomy due to a tumor located in the gastroesophageal junction. On macroscopic examination, an ulcero-vegetant mass lesion measuring 5 cm at a 1-cm distance to the proximal surgical margin was observed. The lesion was located in the gastro-esophageal junction and cardia of the stomach, and completely surrounded the lumen. Two different neighboring tumor foci were seen on histopathological examination (Figure 2). In one of the tumor foci, a field, which had a narrow cytoplasm, cells with hyper-chromatic nuclei, demonstrating a solid growing pattern, included focal necrosis fields, was observed (Figure 3). Another tumor focus, which had a narrow cytoplasm, hyperchromatic nucleus, displaying high mitotic activity and high-grade small cell NEC properties and the nucleoli of which could not be differentiated, was also observed next to the first tumor field (Figure 4).

On immunohistochemical examination, positive staining was seen with CK, CK19, and EMA at the BSC focus. Positive staining was observed with CD56 ; chromogranin A (Figure 5a,5b); and CK, CK19, and EMA in neoplastic cells at the small cell NEC focus. The Ki67 proliferation index was 22%; the mitotic index was evaluated to be higher than 25 in 10 high power fields for both BSC and NEC foci. The patient was diagnosed with BSC + high-grade small cell NEC.

3. DISCUSSION

Collision tumors are rare tumors originating from two different histo-genetic events. These tumors contain two different tumors, which grow very close to each other, although they appear as a single lesion. This entity is a very rare condition together with obscure

pathophysiology. Collision tumors should be discriminated from composite tumors, which are differentiated from two cell lines and contain a single neo-plastic clone. Coexistence of adenocarcinoma and lymphoma, adenocarcinoma and small cell carcinoma or adenocarcinoma and squamous cell carcinoma may be given as examples for collision tumors located at the gastro-esophageal junction (1,6,7,8). However, co-existence of squamous cell carcinoma and small cell carcinoma has been reported in only one case in the literature (9). These types of tumors are usually detected during surgery and diagnosed after pathological examination. We did not encounter reports of coexisting BSC and small cell NEC in the literature review.

Although it is accepted as a different form of squamous cell carcinoma, basaloid squamous cell carcinoma exhibits a different histopathological and clinical behavior. These tumors, which are usually at an advanced stage at the time of diagnosis, form large masses that show lymph node metastasis and hematogenic metastasis. Furthermore, BSC is characterized by poor differentiation, high proliferative activity, high biological malignancy, high incidence of distant metastasis, and a high spontaneous apoptosis rate. BSC is a histologically invasive carcinoma which has a narrow cytoplasm, is composed of cells with hyperchromatic nuclei, demonstrates a solid growth pattern, and which contains small cystic fields and focal necrosis fields (10).

Neuroendocrine tumors contain different tumor groups including slowly growing well-differentiated tumors, poorly differentiated high-grade NEC and mixed endocrine-exocrine tumors. Two-thirds of neuroendocrine tumors are observed in the gastrointestinal system, one-fourth in the lung, and the others in the other endocrine organs. Neuroendocrine tumors are characterized by intra-cytoplasmic neurosecretory granules bound to the membrane, which can be detected with electron microscopy (5). Small cell neuroendocrine carcinomas are most commonly located in the lower third of the esophagus (11), are very invasive and cause distant metastases in the early period of the development of cancer (12). They are composed of round or oval cells that form solid islands and nests that have a narrow cytoplasm and a small, dark nucleus. Chromogranin A, synaptophysin, CD56, and NSE are usually positive immunohistochemically. Synaptophysin is the most sensitive diagnostic marker (13,14). In our case study, positive staining was also observed with CD56, chromogranin A, and pancytokeratin at the small-cell NEC focus.

4. CONCLUSION

In conclusion, in this case study two different tumor components were observed as a result of histopathological examination, although there was a single tumor focus. BSC and small cell NEC may be rarely seen among collision tumors; to the best of our knowledge, our case is the first in the literature.

Figure 1. Irregular wall thickening is observed at the gastro-esophageal junction and cardia of the stomach on axial Computed tomography images (arrow).

Figure 2. BSC focus (Comedo necrosis-like pattern) (H&E x100)

Figure 3. Small cell NEC focus (H&E x200)

Figure 4. Chromogranin A positivity at the small cell NEC focus (Chromogranin x400)

Figure 5. Coexistence of BSC and small cell NEC (H&E x40)

CONSENT

All authors declare that written informed consent was obtained from the patient for publication of this case report and accompanying images.

REFERENCES

1.Spagnolo DV, Heenan PJ. Collision carcinoma at the esophagogastric junction: report of two cases. Cancer 1980; 46(12):2702-8.

2.Wain SL, Kier R, Vollmer RT, Bossen EH. Basaloid-squamous carcinoma of the tongue,hypopharynx, and larynx: report of 10 cases. Human pathology 1986; 17(11):1158-66.

3. Nishimura W, Naomoto Y, Hamaya K, Toda S, Miyagi K, Tanaka N. Basaloid-squamous cell carcinoma of the esophagus: diagnosis based on immunohistochemical analysis. J Gastroenterol Hepatol. 2001 May;16(5):586-90.

4. Bajetta E, Catena L, Procopio G, Bichisao E, Ferrari L, Della Torre S, et al. Is the new WHO classification of neuroendocrine tumours useful for selecting an appropriate treatment? AnnOncol.2005;16:1374-80

5. McKeown F. Oat-cell carcinoma of the oesophagus. J Pathol Bacteriol 1952; 64: 889–891.

6. Gonzalez LM, Sanz-Esponera J, Saez C, et al. Case report: esophageal collision tumor (oat cell carcinoma and adenocarcinoma) in Barrett's esophagus: immunohistochemical, electron microscopy and LOH analysis. Histology and histopathology 2003; 18(1):1-5.

127 7. Kaidar-Person O, Naroditsky I, Guralnik L, Kremer R, Bar-Sela G. Collision tumor of the
128 mediastinum: a rare entity. The Annals of thoracic surgery 2013; 95(1):330-2.
129 8. Klaase JM, Hulscher JB, Offerhaus GJ, et al. Surgery for unusual histopathologic variants
130 of esophageal neoplasms: a report of 23 cases with emphasis on histopathologic
131 characteristics. Annals of surgical oncology 2003; 10(3):261-7.
132 9. Makino H, Tajiri T, Onda M, et al. Effectiveness of preoperative chemotherapy using
133 carboplatin (CBDCA) and surgery against an esophageal small cell carcinoma. Diseases of
134 the esophagus : official journal of the International Society for Diseases of the Esophagus /
135 ISDE 2002; 15(3):237-41.
136 10. Akagi I, Miyashita M, Makino H, Nomura T, Ohkawa K, Tajiri T. Basaloid squamous
137 cell carcinoma of the esophagus: report of two cases. J Nippon Med Sch. 2008
138 Dec;75(6):354-60.
139 11. Lee RB, Miller JI. Esophagectomy for cancer. The Surgical clinics of North America
140 1997; 77(5):1169-96.
141 12. McFadden DW, Rudnicki M, Talamini MA. Primary small cell carcinoma of the
142 esophagus. The Annals of thoracic surgery 1989; 47(3):477-80.
143 13. Maru DM, Khurana H, Rashid A, et al. Retrospective study of clinicopathologic features
144 and prognosis of high-grade neuroendocrine carcinoma of the esophagus. The American
145 journal of surgical pathology 2008; 32(9):1404-11.
146 14. Yun JP, Zhang MF, Hou JH, et al. Primary small cell carcinoma of the esophagus:
147 clinicopathological and immunohistochemical features of 21 cases. BMC cancer 2007; 7:38.
148
149
150
151
152
153

Figure 1. Irregular wall thickening is observed at the gastro-esophageal junction and cardia of the stomach on axial Computed tomography images (arrow).

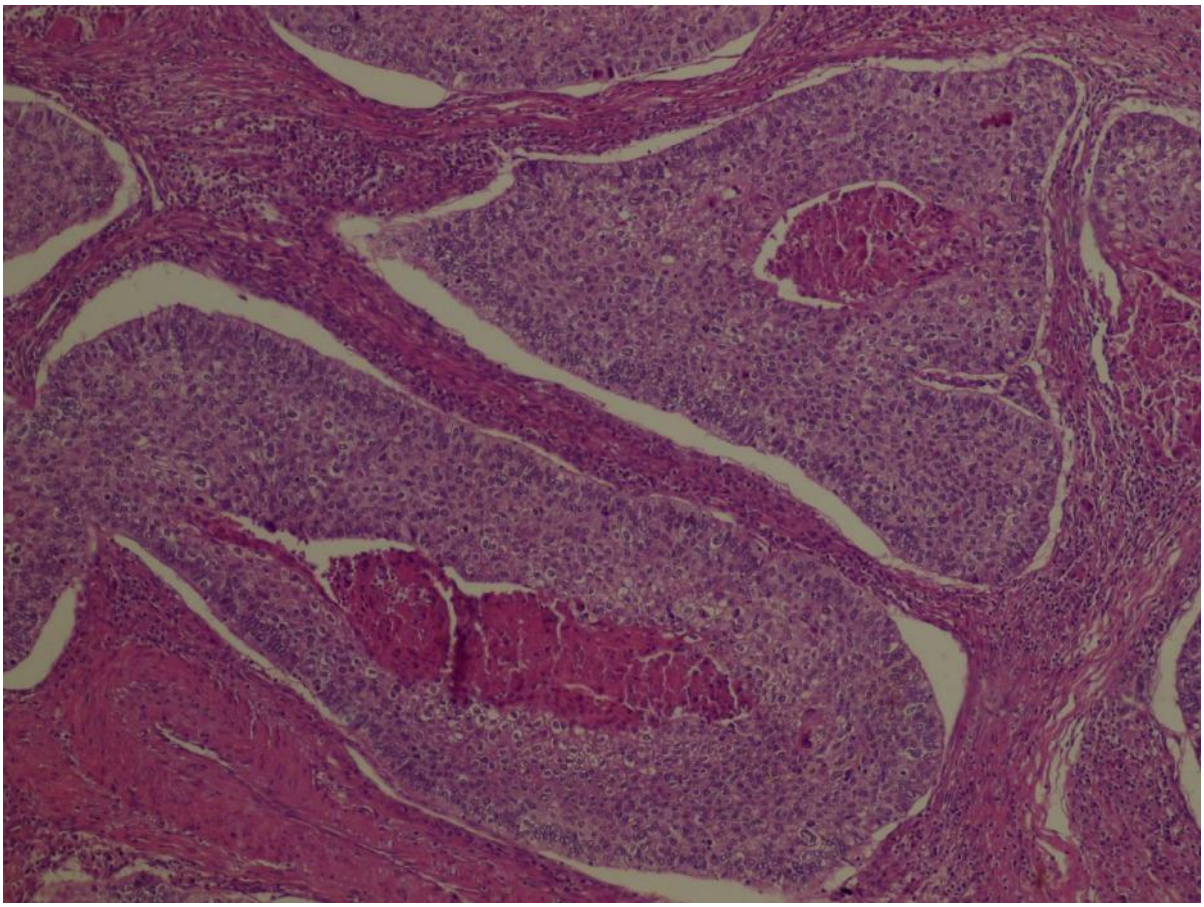

Figure 3. Basaloid squamous cell carcinoma focus (Comedo necrosis-like pattern) (H&E x100)

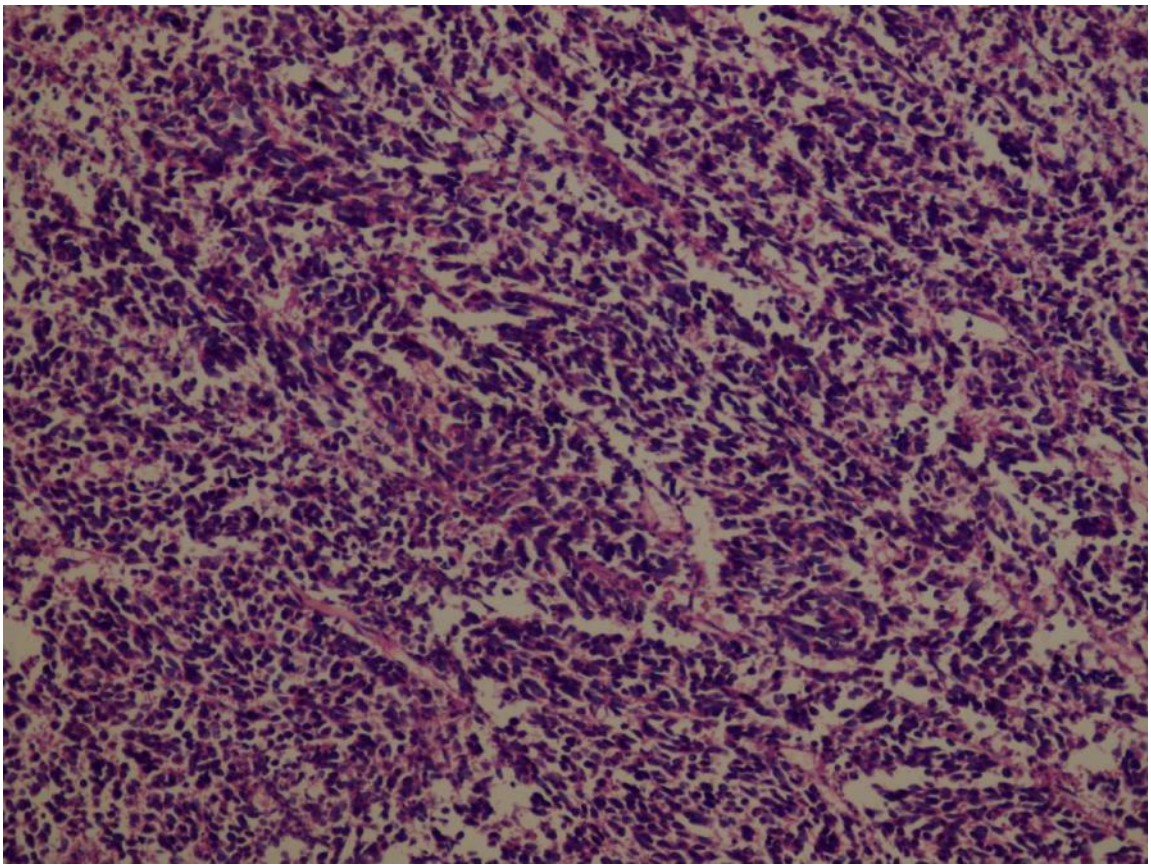

Figure 4. Small cell neuroendocrine carcinoma focus (H&E x200)

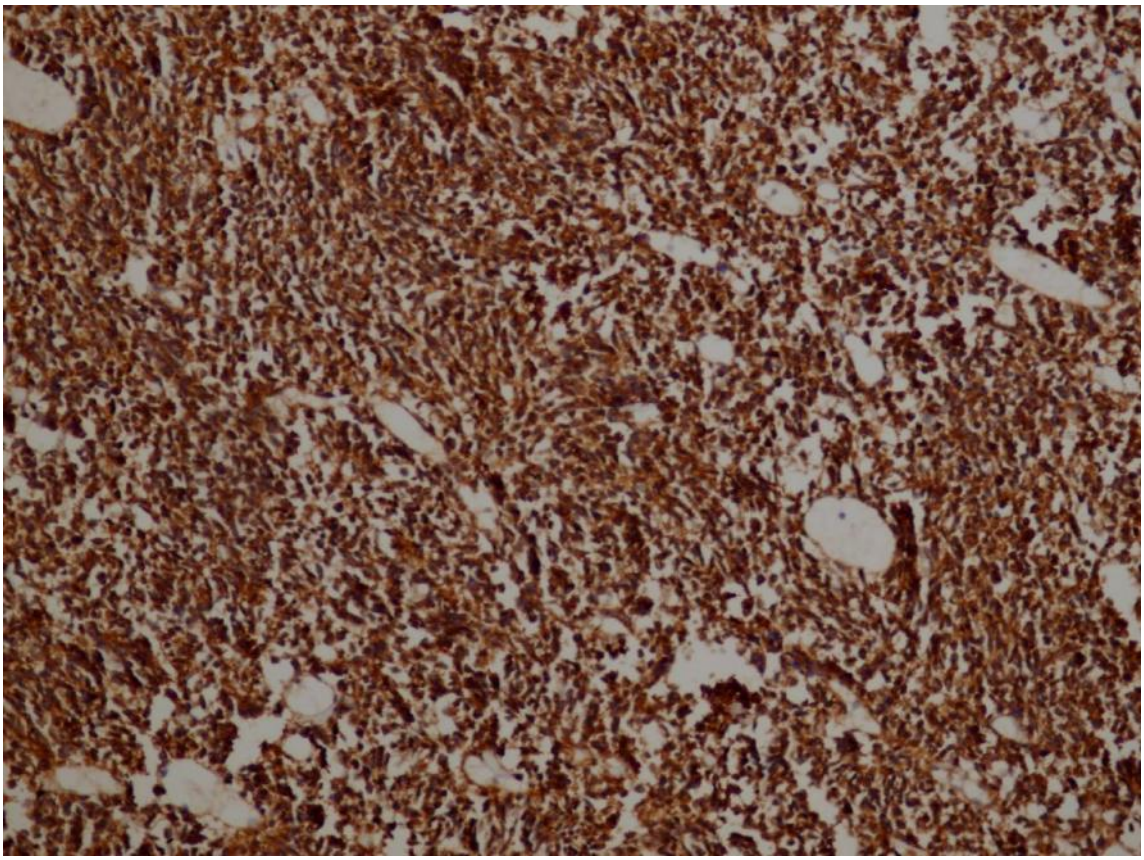

Figure 5a. Chromogranin A positivity at the small cell neuroendocrine carcinoma focus (Chromogranin x400)

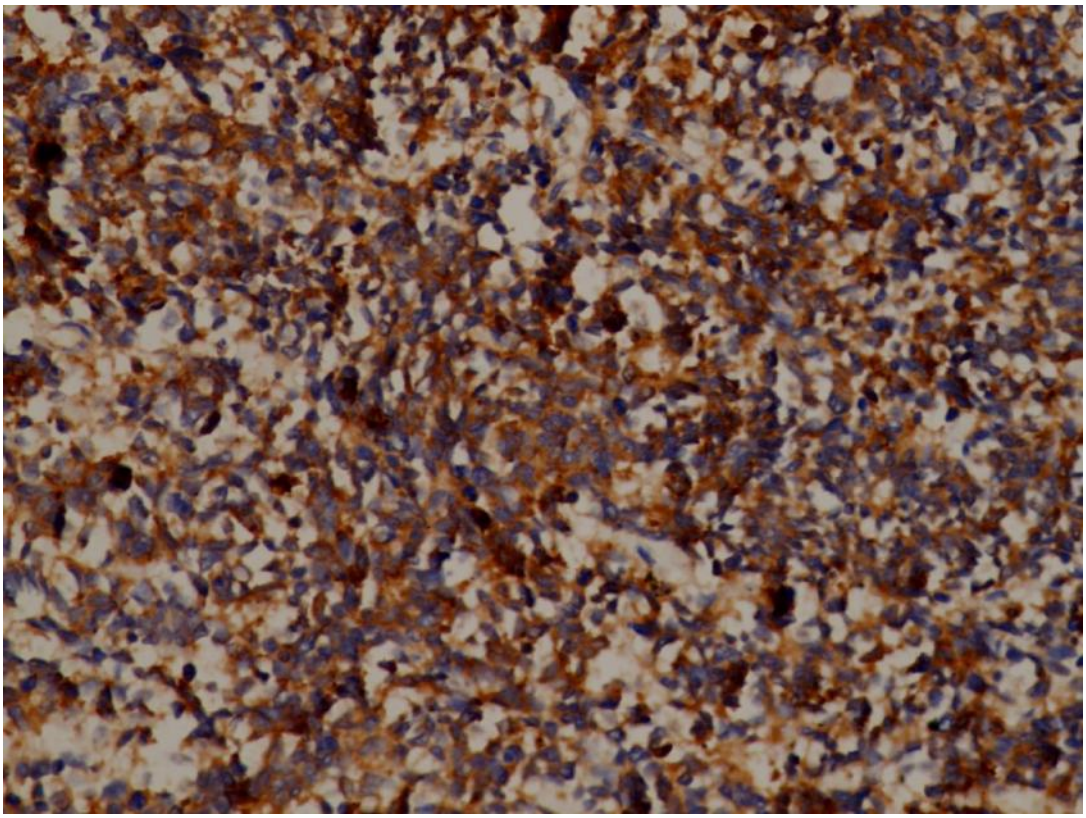

Figure 5 b. CD56 positivity at the small cell neuroendocrine carcinoma focus (CD56x200)

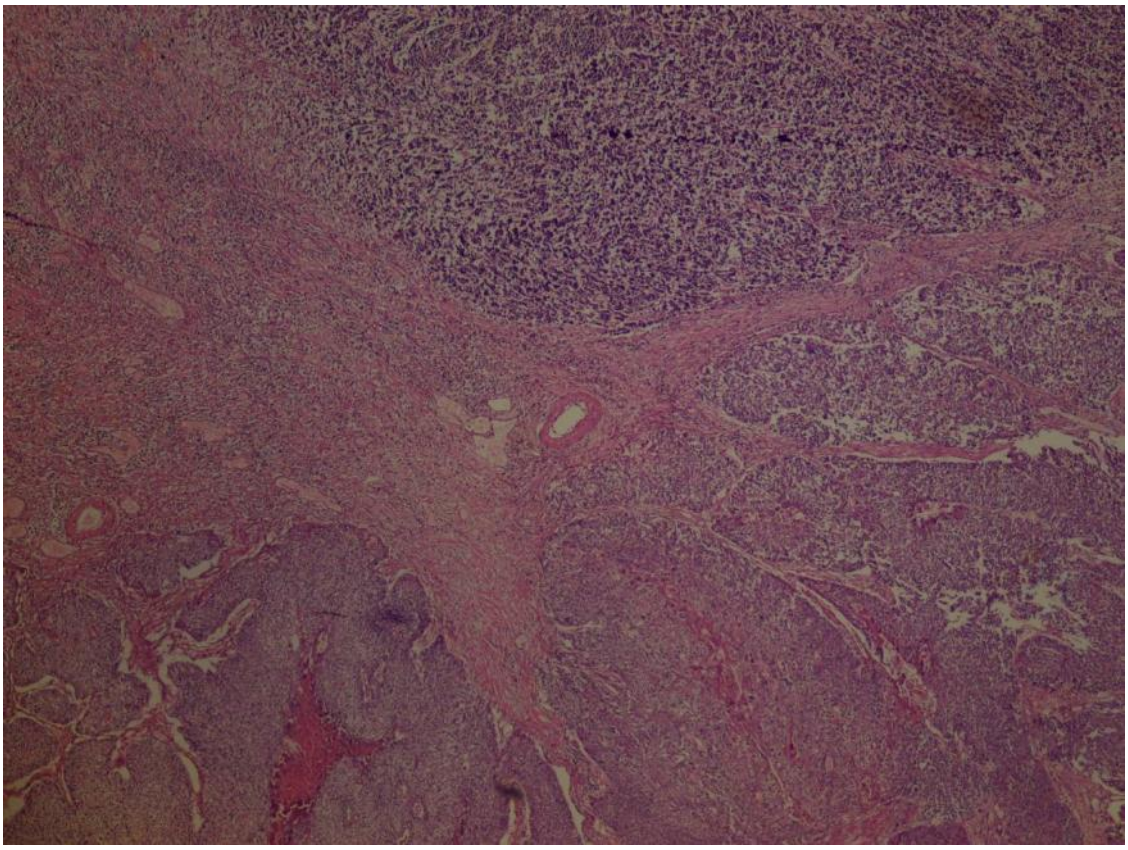

Figure 2. Coexistence of basaloid squamous cell carcinoma and small cell neuroendocrine carcinoma (H&E x40)