INCIDENCE of MULTIPLE MAMMARY TUMORS and FIBROADENOMA in PATHOLOGICAL STUDY of UDDER AFFECTIONS in CAMEL (*camelus dromedarius*)

Abstract:

Aims of the Study: To investigate the general histopathological pictures found in the udder tissue of camel (*Camelus dromedarius*) with emphasis to different types of tumors.

Place and Duration of Study: The study was undertaken in the Department of Pathology, Central Veterinary Research Laboratory, Ministry of Animal Resource and Fisheries, Khartoum, Sudan in 2009.

Study Design: **150** samples of camel udder tissues were obtained from Tumbool abattoir in Al-Gazeera State, gross and histopathological pictures were studies.

Methodology: The macroscopic pictures of samples were seen and described then histopathological lesions were studied using H&E stain. Lastly Immunohistochemical staining was done using estrogen and progesterone antibodies in one sample showed mixed tumors.

Result: Out of 150 samples were studied, 45(30%) tissue showed neoplastic masses, 23(51.11%) of them were benign and 22 (48.89%) were malignant. Different pathological pictures were reported, but only one showed multiple mammary neoplasms contain papillary carcinoma and fibroadenoma.

Conclusion: mammary tumors were detected for the first time in Sudanese camel and completely confirmed by using histopathological methods.

Keywords: Tumor, Udder, Histopathology, Immunohistochemistry, Papillary Carcinoma, Camel, Sudan.

1. Introduction:

Camels in Sudan are multipurpose animals representing an important source of food (milk and meat), clothing, shelter and transportation for Bedouin. Camels' milk and urine have proven to have therapeutic effects against certain diseases [1,2,3]. Mammary glands masses are common in bitch and cat, but rare in other domestic animal species [4].Such lesions were commonly detected in bitches and described as benign tumors, these were: adenoma, papillary adenoma and benign mixed tumors; or malignant tumors such as acinar or ductal adenocarcinoma, papillary adenocarcinoma, medullary adenocarcinoma, squamous cell carcinoma and malignant mixed tumors [5,6].

A mammary gland neoplasm was detected at necropsy in a 9-year-old ovariectomized Holstein cow with a history for one year of an enlarged left hindquarter that contained multiple cysts[7]. The histological diagnosis was multicentric papillary cystadenomawas reported [7, 8]it was also reported in ewes [9, 10],nanny goats [11] and in zoo animals [12].

Mammary neoplasia is rare in Camelids, it was reported as carcinoma in mixed mammary tumor for the first time in a 13-year-old female *llama*. In this case, histopathological examination revealed tubulopapillaryfacinar or solid nest-like clusters of neoplastic epithelial cells surrounded by whorls and sheets of proliferation of epithelial cells and classified as a mixed tumor. Positive confirmed diagnosis is by Immunohistochemical staining of neoplastic epithelial cells with anti-cytokeratin antibodies, metastasis to regional lymph nodes was not reported[13].
In Sudan choroid plexus papilloma was diagnosed during investigation in to dromedary herds owned by nomadic pastoralist, Northern Darfur State, western Sudan for neurological diseases in 2010 [14].
Four types of mammary neoplasia in the dromedary camel were reported. These include: fibrosclerosis, intraductal fibroma composed of papillary overgrowth protruding into the duct lumen, adenocarcinoma consisting of tubular arrangement as well as solid and/or squamous structure. Pleomorphism and mitotic activity were common. Plasma cells and lymphocytes were present in varying numbers around the tumor cells. The stroma was moderate and in some areas sclerotic [15].

2. Materials and methods:

Samples collections:

150 samples of affected udder tissues were collected from female camel with ages of 5-15 years old at Tumbool slaughter house from January to December 2009 for histopsthological study.Tumbool is a town in Al-Gazeera State in the middle of Sudan. It is about 130 km southeast of Khartoum. Different types of histopathological pictures and tumors were reported but only one sample showed mixed tumor, one that showed tumor masses was a 9-year-old Butana heavy weight ecotype, early pregnant, non-lactating female camel, and was slaughtered. For two types of tumor Immunohistochemistry using dextranepolymer_hrp for estrogen and progesterone receptor was done.

3. Results:

Out of 45 neoplastic masses, 23 (51.11%) were benign, and identify as fibroadenomatous mammary hyperplasia (fibroadenoma) (N=8) and cystic adenomatous hyperplasia (N=15). The other neoplastic masses, 22 (48.89%) were malignant and were classified as adenocarcinoma

(N=20), Intra-cystic papillary carcinoma (N=1) and one mammary gland that manifested multiple neoplastic masses was diagnosed as papillary carcinoma and as fibroadenoma (N=1). In this study 8 samples were identify as fibroadenoma and one found mixed mammary tumor (papillary carcinoma and fibroadenoma) for the first time in Sudan.

3.1 Gross lesions:

From 150 samples of udder examined grossly, 8 were slightly swollen, firm in consistency, and on section they were whitish gray and smooth. Only one was showing multiple mammary gland tumors. The udder of the this sample was slightly swollen and hard in consistency, one quarter of the udder was markedly distended approximately 2 cm above the base of the teat and two reddish fleshy masses were appeared as the udder surfaces were cut. The larger one was composed of hard non-encapsulated well circumscribed, hard on cut surface, bulging mass attached to the inner surface of the udder and communicated by stalk with other nodules at the base of teat which blocked the teat canal. The second mass was 1.6×2cm, cauliflower-like and loose in teat canal.

3.2 Histopathological lesions:

In mixed mammary tumors, the most striking change was complete distortion and destruction of normal udder architecture and the normal udder tissue was replaced by invasive of tumor tissue. Though, the microscopic pictures of two masses were variable, but the predominant change of the small nodule at the base of teat presented as arboriform papillary fronds, with a core of fibrovascular tissue having complex secondary and tertiary branches (Fig 1).

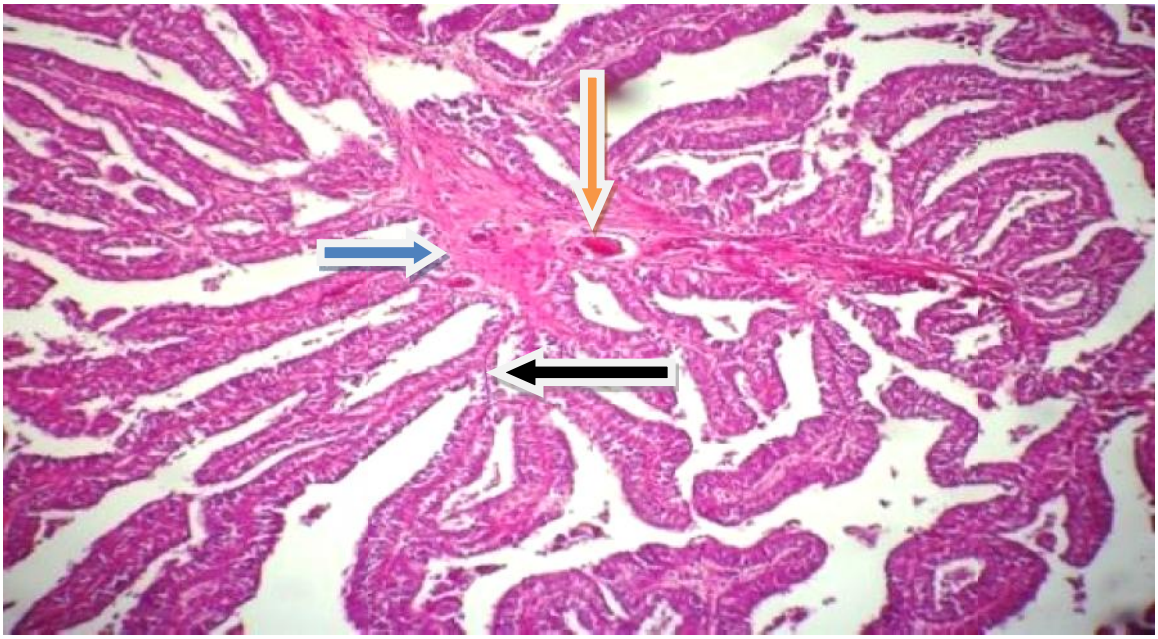

Fig 1: Section of an udder of she-camel affected with papillary carcinoma. Note, large complex fibrovascular core (blue arrow), congested blood vessels (orange arrow) and complex branches (black arrow) H&E x10.

The fronds were covered with single or multi-layers of pleomorphic poorly orientated overlapping cells that appeared as pseudostratification. Bullring and necrosis of the papilliferous growth stratification of the nuclei and leucocytes infiltration were frequently observed. The nuclei were vesicular forming the empty look appearance and some with marginated chromatin (Fig 2).

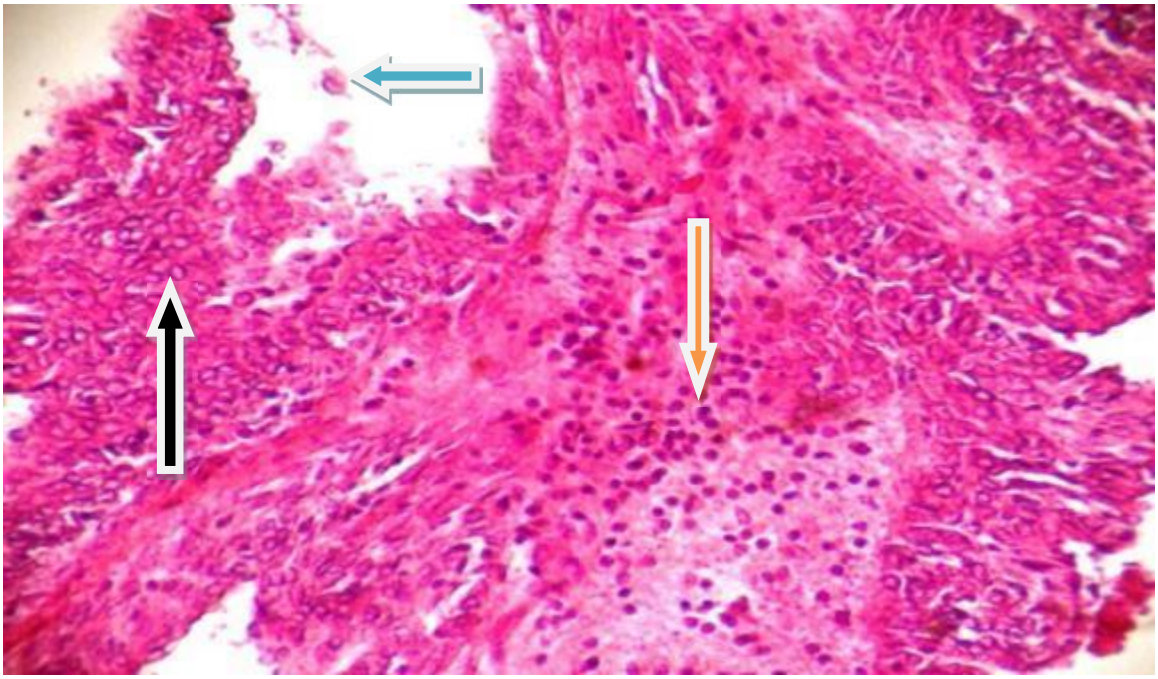

Fig 2: another area of papillary carcinoma. Note, the pleomorphic poorly orientated overlapping cells with vascular nuclei (black arrow), scattering and necrosis of neoplastic cells (blue arrow) and infiltration of leukocyte (orange arrow), (H&E x40).

Focally micropapillary pattern with prominent papillary tufts were often observed. In some areas the fibrovascular core was covered with single layer of flatten end epithelial and in other areas covered with cuboidal to low columnar cells. The stromal connective tissue was variable in some areas dense diffuse and in other showed myxomatous feature. The tumor displayed fibroadenomatous hyperplasia (fibroadenoma). These areas were composed of numerous irregular branching tubular or ducts embedded in fibrous tissue stroma which varied from myxcmatous with mild fibrotic reaction to extensive fibrosis (Fig 3).

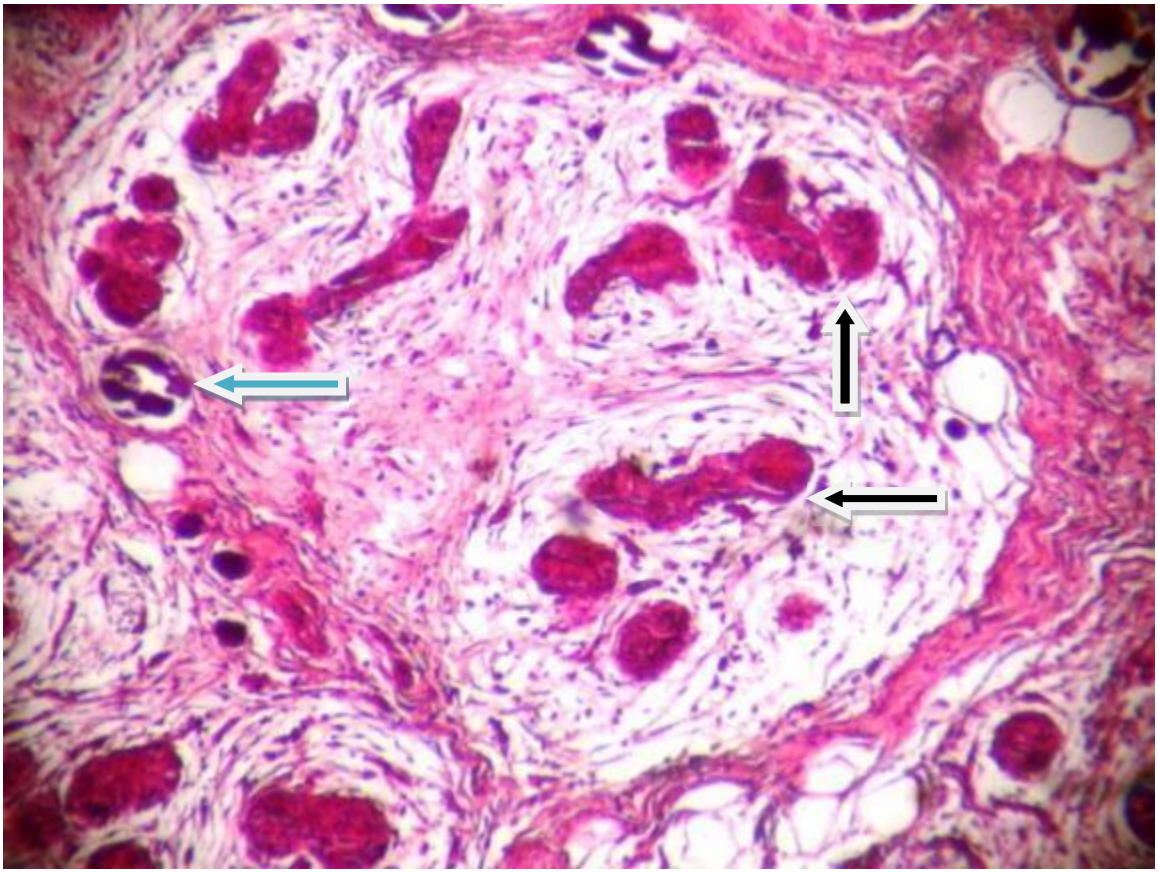

Fig 3: A section of an udder of she-camel affected with fibroadenoma. Note, irregular ducts entrapped in fibrous tissue (black arrow) and calcium deposition (blue arrow) H&E x10.

Eight samples showed typical fibroadenoma picture, in these samples the neoplastic tubules varied in size from narrow to moderately dilated and some contain homogenous pinkish material. These tubules were lined with single or multilayers of cuboidal epithelium cells. The arrangement of these layers was disorganized and appeared as pseudostratification. The basement membrane was not evident. The cell and nuclei were pleomorphes but no mitotic figures were seen (Fig 4).

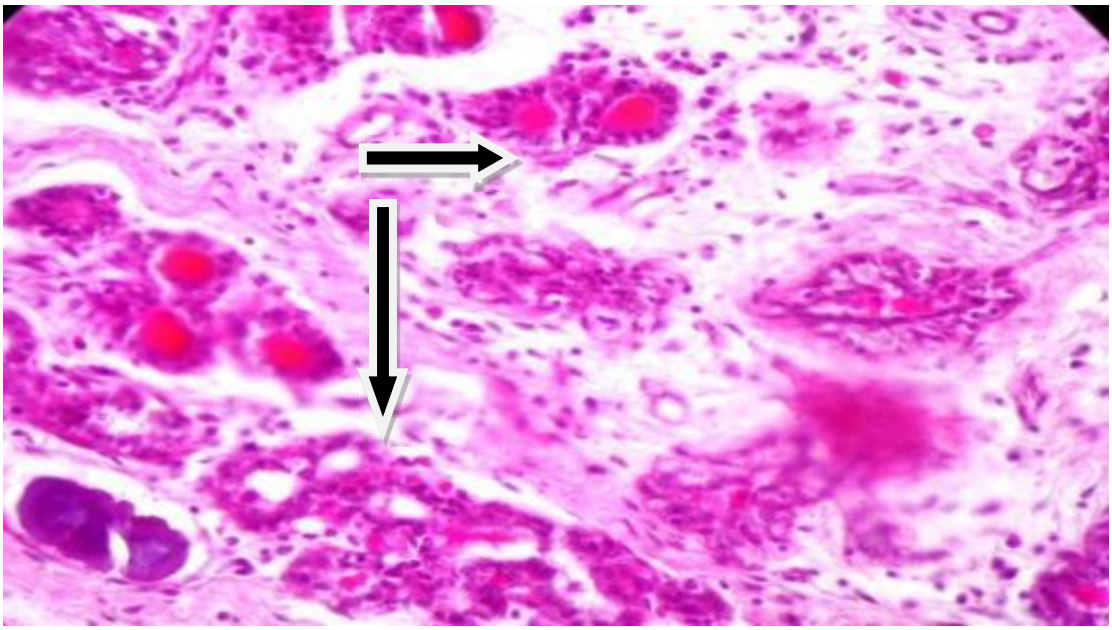

Fig 4: Another section of an udder of she-camel affected with fibroadenoma. Note, neoplastic tubules varied in sizes and some contain homogenous pinkish material (black arrow)) H&E x40.

These tubules were lined with multilayers of cuboidal epithelial cells (Fig 5).

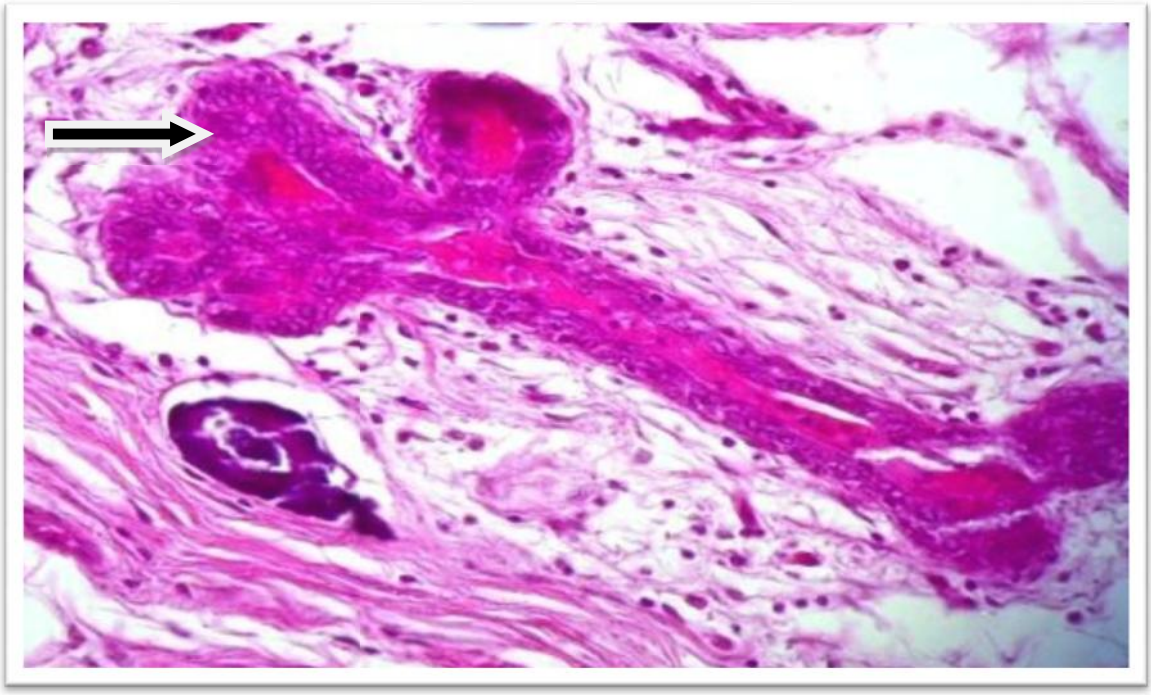

Fig 5: Another section of an udder of she-camel affected with fibroadenoma. Note, multilayers of epithelial cells (black arrow). H&E x40.

The arrangement of the layers was disorganized and revealed anisocytosis and anisokaryosis of cells and nuclei, respectively. In both the fibroadenoma and papillferous growth calcospherites was observed in tubular, papillary component, fibovascular core and epithelial lining. The tumor metastasis in lymphatic vessels (Fig 6).

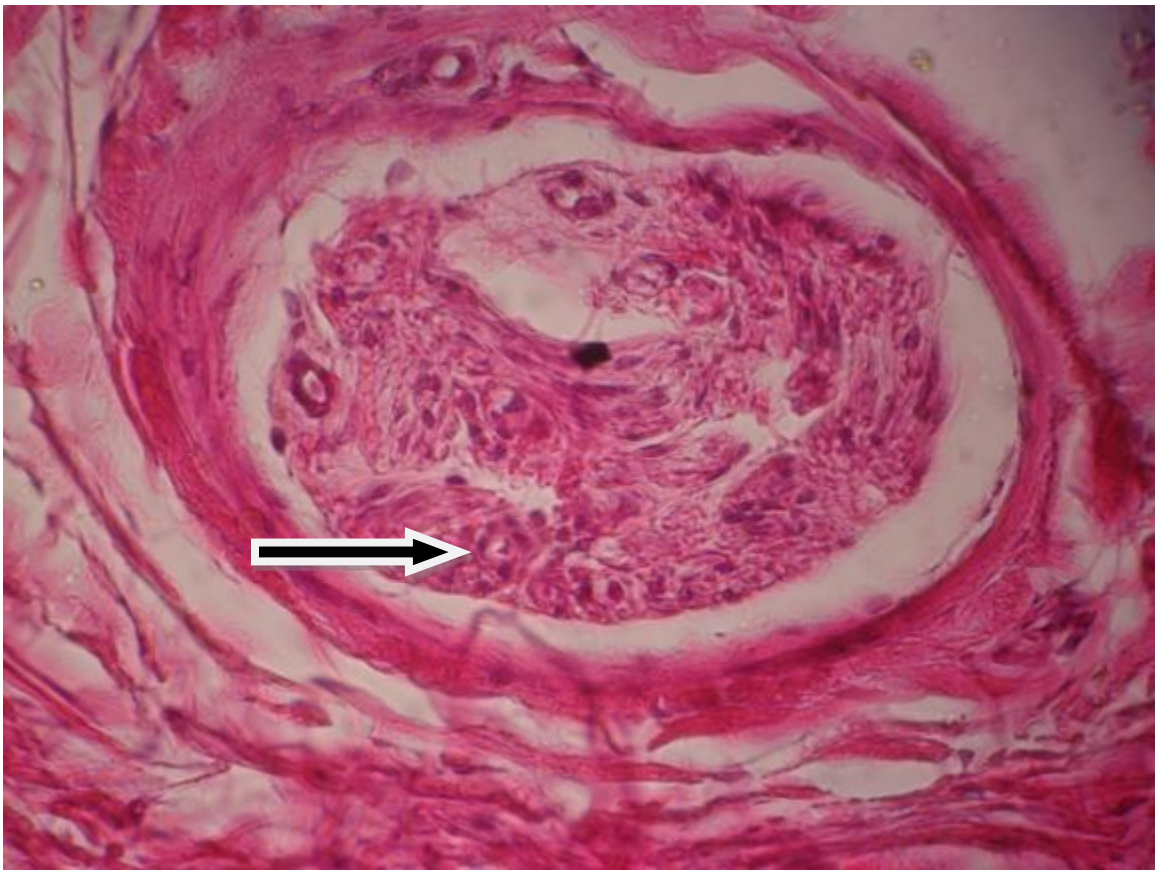

Fig 6: udder of she camel show metastasis, Note, tumor cell inside lymphatic vessel (black arrow) H&E x40.

3.3 Immunohistochemistry:

The papillary section showed moderate positive result for estrogen receptor and negative progesterone (fig 6, 7) while the fibroadenoma section was negative for both receptors.

130 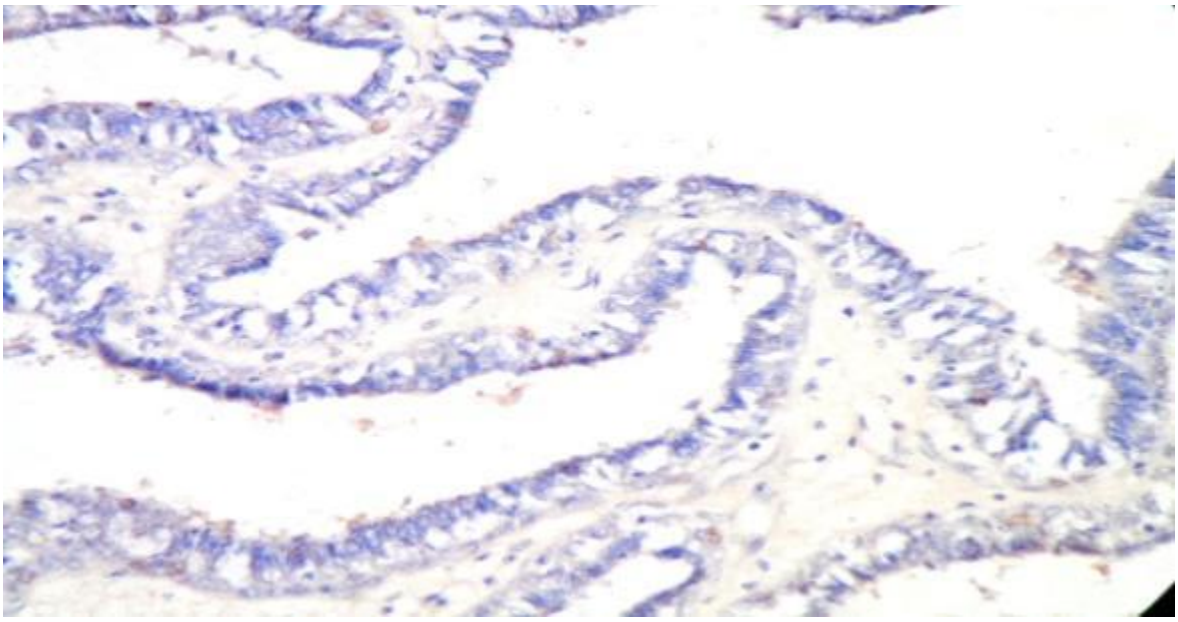

131 Fig 7: negative control of papillary carcinoma with negative estrogen receptor.Immunostain x40.

132 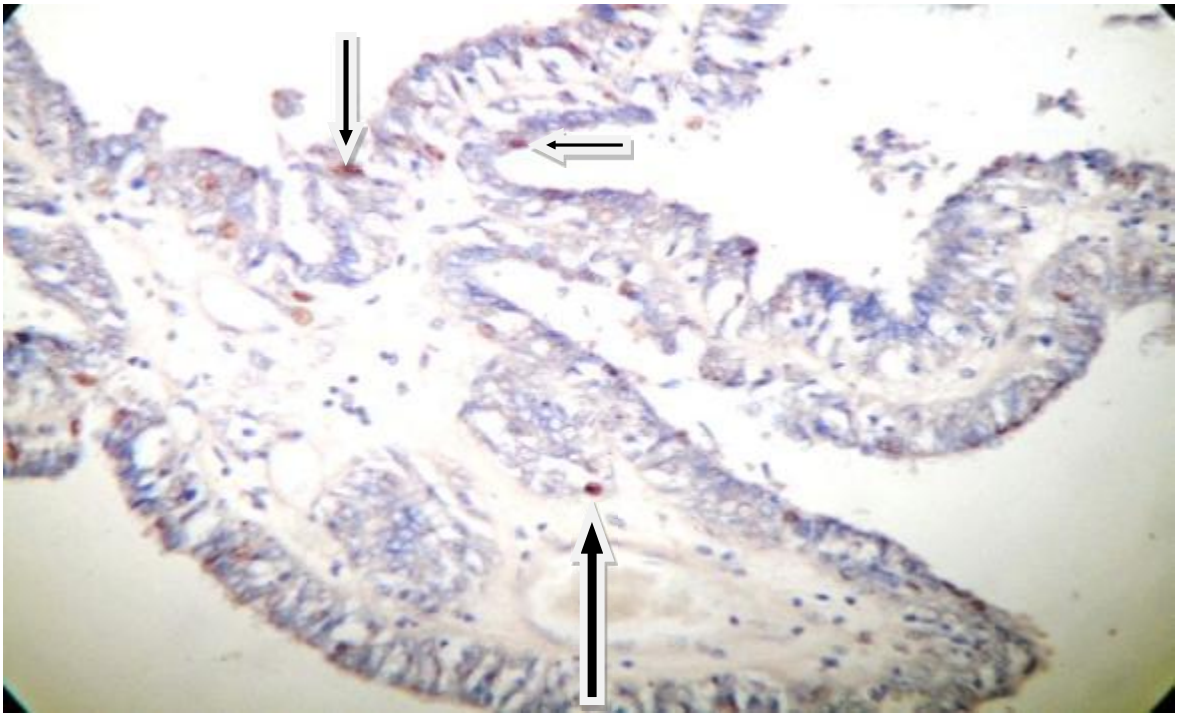

133 **Fig 8: Udder of she camel with papillary carcinoma and positive for estrogen receptor.**
134 **Note, variable brown nuclear stain (black arrow).immunostain x40.**

135

4. Discussion:

In this study multiple mammary neoplasms were detected in the udders of she-camel. One was diagnosed as a papillary carcinoma and the second as fibroadenomatous hyperplasia. The occurrence of multiple primary mammary tumors in an individual animal is common and well documented in bitches [16,17,18,19], This phenomenon is rare in other animal species and was even less frequent in camel. The available literature included a single report of simultaneous seminoma and cholangiocarcinoma in an 18-year-old male camel [20]. Camel papillary carcinoma of the mammary glands is meager [15]. This neoplasia, however, has been well documented in bitches and queens [16, 21] and in horse [22,23].

In this study Fibroadenomatous was identified in 8 samples, this agrees with those who reported it in feline and it was known as synonymous feline mammary hypertrophy or fibroepithelial hypertrophy. Also it was relatively common in dog and cat, but it is rare in herbivores [24]. A few individual cases, however, have been reported in a nanny goat [25]; a cow [26] and a lamb [27].

Hyper progesteronism has been suggested for the induction of fibroadenomatose mammary hyperplasia [28]. Other authors have associated if present of these lesions in feline mammary gland with pregnancy and progesterone therapy [29]. The effect of the hormone involvement in feline mammary gland has been documented [30]. The effect of hormone in canine mammary gland during estrous cycle has been reported [19]. [31] reported that the demonstration and localization of progestin-induced biosynthesis of growth hormone induced proliferation of canine mammary gland.

In this investigation benign neoplastic lesions were identified as fibroadenomatous mammary hyperplasia according to the histological feature and this agrees with [21,16]. The microscopic changes observed herein for fibroadenomatous hyperplasia were indistinguishable from those reported by other investigators [30,32,24,27].

In camel no previous report available in literature. The relationship between these two neoplasms was not established. Immunologic and low enzymatic defects predispose some breed of dogs to multiple tumors [33]. In human, irradiation or drugs used in the treatment of primary tumor may enhance the development of another neoplasm [34].

Negative immunostaining for the progesterone receptors and may have resulted from a lack of cross-reactivity to the camel species with antibodies used in this study, in addition to impregnation in formalin for long time and that agree with other researcher[27].

The benign and malignant mammary tumors are positive for estrogen, progesterone or prolactin receptors to varying degrees [4].

From a comparative perspective, canine mammary mixed tumors and human pleomorphic adenomas of the salivary gland exhibit morphological and molecular similarities, suggesting a similarity in the pathogenic mechanisms involved in malignant transformation and histogenesis [35].

The lack of sufficient report of multiple neoplasms particularly in dromedary camel, make it difficult to draw conclusion about the interaction of these tumors. It is probable that, multiple neoplasms such as in the present case may represent a coincidence.

Conclusions:

Mammary tumors were detected for the first time in Sudanese camel and completely confirmed by using histopathological methods

Histopathology represent an important tool to detect and confirm different types of tumors.

Immunohistochemistry consider confirmative methods when using suitable markers beside the histopathological picture.

The lack of sufficient report of multiple neoplasms particularly in dromedary camel, make it difficult to draw conclusion about the interaction of these tumors.

It is probable that multiple neoplasms such as in the present case may represent a coincidence.

Recommendation:

More studies are needed to check the availability of different types of tumors in camels.

References:

[1] Ohaj H M. Camel urine as medicament in the Sudan (B.Sc. Dissertation) University of Gezira, Medane Sudan. 1993.

[2] Salwa M E .Hepatoprotective and anti-parasitic effect dromedary female camel urine. Ph. D. Thesis. University of Khartoum.Khartoum Sudan.2004.

[3]Muna E A. Studies in Sudanese camel urine.Msc thesis. University of Khartoum Sudan.2003.

[4] Misdrop W. Tumors of the mammary glands. In: Tumors of Domestic Animals.ed. by Meuten D J. 4th edition, Blackwell publisher. 2002; Pp. 575-606.

[5] Schlafer DH and Miller R B. Pathology of mammary glands In Jobb, Kennedy and Palmer's Pathology of Domestic Animals, 5th ed. Vol 3, by Maxie M G, Saunders Elsever. Edimburgh, London U.K. 2007; Pp:550-564.

[6] Pawaiya R V andRamkumarc M. expression pattern in canine mammary and human breast cancer .Indian. Vet. Pathol.2009; 33: 46-51.

[7] Poveg R C and Osborne A D. Mammary neoplasm in the cows. Vet. Pathol.1969; 6:502-512.

[8] Reimer J M, Sweeney RW and Saik J. Multicentric papillary cystadenoma in the udder of a cow.J. A. V. M. A. 1988; 192:1297-1298.

[9] Paliwal O P and Parihor N S. Squamous cell carcinoma in udder of sheep. Indian Vet. J. 1971; 50: 703.

[10] Ali O A. An ovine mammary adenoma. Vet. Pathol.1986; 23: 217-218.

[11] Singh B and Lyer PK. Mammary intraductal carcinoma in goats (Capra hirci). Vet. Pathol.1972; 9: 441-446.

[12] McAloose D, Munson L and Naydan DK. Histologic features of mammary carcinomas in zoo field treated with Melengestrolacitate (MgA) contraceptive. Vet. Pathol.2007; 44:320-326.

[13] Bangari D S and Stevenson G.W. Carcinoma in a mixed mammary tumor in a llama (Lama glama). J. Vet. Diagno. Invest.2007; 19:450-453.

[14] Ahmed O M. Mohammed KB.ZakiaAM.and Halima MO.Choroid plexus papilloma in the one-humped camel (*Camelusdromedaries*) in Sudan. Veterinary pathology congress.Anand.India. 13-17 Nov. 2014.

[15] Hegazy AA, El Dughaym A, Alaknah M, Housawi F M and Hatem M. Studies on mastitis in female camel with special reference to brucellosis. J.Cam. Sc. 2004; 1:96-102.

[16] Misdrop W, Cotchin E, Hampe JF, Jabara A G and Sandersleben V. Canine malignant mammary tumor II. Adenocarcinoma, solid carcinoma and spinal cell carcinoma. Vet. Pathol.1972; 9: 447-470.

[17] Flower EH, Wilson GP and Koestner A. Biologic behavior of canine mammary neoplasms based on a histologic classification. Vet. Pathol.1974; 11:212-229.

[18] Brodey RS, Goldschmidt HM and Rozel JR. Canine mammary gland neoplasms. J. Am. Anim. Hosp.Assoc.1983; 19: 61-90.

[19] Benjamin S A, Lee AC and Saunders WJ. Classification and behavior of canine mammary epithelium neoplasms based on life-span observations in Beagles. Vet. Pathol. 1999;36: 423-436.

[20] Birincioglu SS, Hamdi AV and Aydogan A. Seminoma and cholangiocarcinoma in an 18-year-old male camel. Turk.J.Vet. Anim.Sci.2008; 32: 141-144.

[21] Hampe J F and Misdrop W. Tumors and dysplasia of the mammary glands. Bull. WHO.1974; 50:111-133.

231 [22] Reppas GP, Clintock SA, Canfield PG and Watson GF. Papillary ductal adenocarcinoma in
232 mammary gland of two horses. Vet. Rec. 1996; 138: 518-519.
233 [23] Brito M D, Seppa GS, Teixira LG, Rocha TG, Franca TN, Hess TM and Peixoto PV.
234 (Mammary adenocarcinoma in a mare. Ciencia, Rura.2008;38: 556-560.
235 [24] Misdrop W, Else R W, Hellman E, Lipscomb TP. In: WHO International Histologic
236 Classification of Mammary Tumors of the Dog and Cat, edited by Schulman, F.Y. Vol VII,
237 Armed Forces Institute of Pathology, Washington, DC. 1972; Pp: 1-59.
238 [25] Andreason CB, Huber M J and Mattoon J. S. Unilateral fibroepithelial hyperplasia of
239 mammary gland in a goat. JAVMA.1993; 202:1279-1280.
240 [26] Mina RE, Uchida K, Sakumia A, Tamaquchi R, Tatevama S, Oquwa H and Ofsuk H.
241 Mammary fibroadenoma of young holstein cow. J. Vet. Med. Sci. 1994; 50:1171-1172.
242 [27] Gulbahar M Y, Guvenc T, Yarim M, Kabak Y B and Sozgen Y. Mammary fibroadenoma in a
243 lamb. J. Vet. Sci. 2007; 8: 423-425.
244 [28] Allen H L, Feline mammary hyperplasia. Vet. Pathol.1973; 10: 501-508.
245 [29] Seifer R J, Kelly, W R, Menrath, V H and Barbero, R D Total fibroadenomatous changes of
246 mammary glands of two spayed cats. FelinePractices.1979; 9:25-29.
247 [30] Nimmo JS and Plummer JM.Ultrastructral studies of fibroadenomatous hyperplasia of
248 mammary glands of 2 cats.J. Comp. Pathol, 1981; 91: 41-50.
249 [31] Garderen E U Wit, M.D. Voorhout, W.F. Rutteman, G.R.Mol, J.A. Nederbragt, H. and
250 Misdrop, W. Expression of growth hormone in canine mammary tissue and mammary
251 tumors. Am.J.Pathol. 1997; 150:1037-1047.
252 [32] Curran RC and Crocker J. Curran's Atlas of Histopathology. 4th ed. Harvey Miller: Oxford
253 university press; 2000.
254 [33] Priester WA Goodman DD and Theilen EH. Nine sprumltanpous primary tumor.Poxer dog.
255 A J V A M 1977; 170: 823-826.
256 [34] Moertel CG. Multiple malignant neoplasm. *Recent Research in Cancer*.1966; 7:1-107.
257 [35] GeovanniDantasCassali, AngélicaCavalheiroBertagnolli, Enio Ferreira,
258 KarineAraújoDamasceno, Conrado de Oliveira Gamba, and CecíliaBonolo de
259 Campos.Canine Mammary Mixed Tumours: A Review, Veterinary Medicine International.
260 Volume 2012 http://dx.doi.org/10.1155/2012/274608.