Primary Synovial Sarcoma of the Prostate Gland: A Review of the Literature

Anthony Kodzo-Grey Venyo[1*]

[1]*Department of Urology, North Manchester General Hospital, Delaunays Road Manchester, United Kingdom.*

Author contribution

The sole author designed, analyzed and interpreted and prepared the manuscript.

:

ABSTRACT

Background: Primary synovial sarcoma of the prostate gland (PSSP) is rare and most clinicians would be unfamiliar with its biological behaviour.
Aim: To review the literature on PSSP
Method: Various internet data bases were searched.
Literature Review: PSSP is extremely rare with less than 10 cases reported; affects both young and older men; its diagnosis may be made incidentally following histological and cytogenetics examinations of prostate biopsy or prostatectomy specimens which show: A specific chromosomal translocation t(X; 18; p11; q11); Uniform spindle and oval cells which have formed interlacing fascicles that mimic fibrosarcoma. The compact fascicles of tumour cells focally alternate with hypo-cellular myxoid tissue which mimic peripheral nerve sheath tumours. Focal pericytomatous pattern of polygonal cells arranged around dilated, thin-walled blood vessels. PSSP tumour cells on immunohistochemical staining, stain positively with: Vimentin (most of the cells), EMA (focal positivity), Bcl-2 (strong positivity), CD99 (strong positivity), Ecadherin (strong positivity), cytokeratin (focal positivity), CD 56 and TLE/TLE1. There is no consensus opinion on treatment of PSSP which is an aggressive tumour with poor outcome. However, an aggressive radical surgical treatment by radical prostatectomy or pelvic exenteration plus or minus adjuvant therapy would appear to be the best treatment option with curative intent to help improve prognosis. Some patients with PSSP may need palliative and supportive treatment through a multi-disciplinary team approach.
Conclusions: PSSP is a rare aggressive tumour with poor prognosis. All cases of PSSP should be entered into a multi-centre trial to ascertain the best treatment option that would improve the prognosis and to further assess its biological behaviour.

Keywords: Primary synovial sarcoma of prostate; t(X, 18) (p11.2, q11.2); anterior exenteration; radical prostatectomy; vimentin; EMA; Bcl-2; CD99; ecadherin; Keratin reactivity.

1. INTRODUCTION

Synovial sarcoma (SS) is a mesenchymal spindle cell tumour which exhibits various types of epithelial differentiation including glandular formation and it has a specific chromosomal translocation t(X; 18; p11; q11) [1] and SS accounts for about 5% to 10% of all soft tissue

**Corresponding author: Email: akodzogrey@yahoo.co.uk;*

sarcomas [2]. The age of incidence of SS ranges from birth to 89 years. SS is often seen in adults with preponderance for men. The histogenesis of SS is not known and is not related to synovium [3] SS most commonly affects the deep soft tissues of the extremities but SS also affects many other organs. Four morphologic variants of synovial sarcoma have been described which include: The classic biphasic type, the monophasic fibrous type, the monophasic epithelial type, and the poorly differentiated (round cell) type [2]. Adenocarcinoma of the prostate gland is the most common malignant tumour which affects the prostate gland; nevertheless, other rare types of carcinoma affect the prostate gland and their biological behaviours differ from that of adenocarcinoma of the prostate. Synovial sarcoma of the prostate gland is very rare and a number of clinicians may not be familiar with its diagnosis and biological behaviour. The ensuing review of the literature on primary synovial sarcoma of the prostate gland (PSSP) is divided into two parts: (A) which contains an overview and (B) which contains miscellaneous narrations and discussions from some reported cases of PSSP

2. AIM

To review the literature on primary synovial sarcoma of the prostate gland

3. METHODS

Various internet data bases were searched including: PUB Med; Google; Google Scholar; Medline; and Educus. The following search terms were used: Primary synovial sarcoma of prostate; synovial cell sarcoma of prostate. Information obtained from 43 references was found relevant to PSSP which were used to write the literature review.

4. LITERATURE REVIEW

4.1 Overview

4.1.1 General comments

Synovial sarcoma has been reported in a variety of organs. Few cases of synovial sarcoma of the prostate have been reported. Synovial sarcoma, which has also been referred to as “malignant synovioma”, is an uncommon type of malignancy which quite often occurs around joints of the arms, neck or legs [4].

Synovial sarcoma also afflicts a variety of organs. The terminology of synovial sarcoma was coined in the earlier parts of the 20th century when some researchers came to the opinion that the similarity of microscopic features of some of these tumours to synovium and the tendency for these tumours to arise around joints would be suggestive of synovial origin of such tumours; nevertheless, the cells from which the tumours emanate remain unknown and they are considered not to have necessarily originated from the synovium [4,5]. Furthermore, synovial sarcoma can afflict a number of organs in the body including organs that are not in close proximity with joints [4].

With regards to synovial sarcoma, two cell types can be seen on microscopic examinations: A fibrous-type which is called a spindle or cell type which is relatively small and uniform and these tend to be found in sheets. The second type of synovial sarcoma exhibits epithelial appearance. Classical synovial sarcoma tends to have a biphasic appearance with both of the aforementioned types. Additionally, synovial sarcoma may also appear to be poorly differentiated or to be monophasic fibrous and consisting only of sheets of spindle cells [4,5]. It has been iterated that in very rare situations there could be a monophasic epithelial form of synovial sarcoma which could pose difficulties in relation to diagnosis [4,5].

It had been stated majority and probably all cases of synovial sarcoma are associated with reciprocal translocation to t(x; 18) (P1p11.2; q11.2) and there has been debate whether or not the molecular observation in itself should be definitional of synovial sarcoma [4,6-8]. On the whole the diagnosis of synovial sarcoma tends to be made upon the histological finding which is confirmed by the presence of t(x’ 18). This type of translocation between the SS18 gene on chromosome 18 and one of three SSX genes (SSX1, SSX2, and SSX4) on chromosome X causes the presence of a SS18 – SSX fusion gene. The fusion protein which results brings together the transcriptional activating domain of SS18 and the transcriptional repressor domains of SSX. The fusion also incorporates into the SW1/SNP chromatin remodelling complex, which is a known tumour suppressor [4,9]. It had been postulated that SS18-SSX underlies the pathogenesis of synovial sarcoma through dysregulation of gene expression [4,5].

4.1.2 Definition

- Synovial sarcoma is a tumour which could be biphasic or monophasic with a t(X; 18; p11; q11) translocation [10].

4.1.3 (General Diagnostic Criteria)

General Diagnostic criteria for synovial sarcoma Stanford University Surgical Pathology Diagnostic criteria [10].

4.1.3.1 (Difficulties in establishing diagnosis of synovial sarcoma)

Diagnosis of synovial sarcoma may be difficult; however, Kempson and Rouse of Stanford University have outlined strict Surgical Pathology Diagnostic Criteria of Stanford University, which could be used as a guide for the diagnosis of synovial sarcoma involving any organ as follows: [10].

4.1.3.2 General features of both patterns (biphasic and monophasic) [10]

- Keratin positivity

  1. Epithelial component either keratin of EMA positive in essentially 100% of cases
  2. Spindle cell component positive in 50% to 80% of cases.

- No more than mild pleomorphism

  1. Moderate pleomorphism may be present following radiotherapy

- May be circumscribed or infiltrative
- t(X; 18; p11; q11) is definitional

  1. All soft tissue tumours with this translocation are considered synovial sarcoma
  2. Because of this new definitional criterion, the histological features described may be expanded in the future.
  3. See poorly differentiated pattern description

4.1.3.3 Biphasic pattern most common [10]

- Contains both epithelial and spindle components

  1. Components may merge of may be distinctive
  2. Metastases may show different predominance of components

- Epithelial component usually large pale or columnar cells.

  1. Occasionally cuboidal, flat or spindled
  2. May form glands, tubules, or papillae (rare)
  3. May contain mucin, rarely rich in mucin
  4. Rare focal squamous differentiation may be seen.
  5. Round vesicular nuclei may be seen

- Spindle component usually uniform small elongate plump cells

  1. Dark even stippled chromatin
  2. Scant cytoplasm with indistinct cell margins
  3. Usually the spindle component in sheets or fascicles
  4. Occasionally with nodules or myxoid foci

- Characteristic stromal features tend to present

  1. Thick ropy collagen bundles
  2. Often surrounding cellular bundles
  3. Haemangiopericytoma-like vessels
  4. Calcification

4.1.3.4 Monophasic Pattern [10]

- Pure epithelial pattern tends to be rare to non-existent
- Pure spindle pattern tends to contain spindle cells with the above features
- Monophasic pattern requires at least one of the following:

  1. t(X; 18; p11; q11)
  2. Keratin reactivity
  3. One of the three stromal features above

4.1.3.5 Frequently seen non-specific features include [see 10]:

- Palisading
- Pseudo-rosettes
- Herringbone pattern
- Retiform or micro-cystic pattern
- Metaplastic bone or cartilage
- Areas with slightly larger cells

4.1.3.6 Poorly differentiated patterns may be seen which may be focal or pure [10]

Poorly differentiated pattern

- *T(x;18;p11;q11) is required for the identification of such tumours as synovial sarcoma*
- *2 of following in at least 2 low power fields proposed for designation by de Silva*
    - *Cellular areas with nuclear crowding*
    - *Nuclear irregularity*
    - *Prominent nucleoli*
    - *Irregular clumped chromatin*
- *Other frequently associated features*
    - *increased mitotic figures (>10/hpf)*
    - *Necrosis*
    - *Presence of hemangiopericytoma like vessels*
- *Cell types may be epithelioid, spindled, small round*
- *Occasional patterns*
    - *Herringbone*
    - *Desmoplastic stroma surrounding nodules of cells*
    - *Cords or strands of cells*
    - *Pseudo-rosettes*
    - *Rhabdoid cells*
    - *Clear cells*
- *Uniform, small round to spindle cells*
    - *solid closely packed cells*
    - *Resembles small round blue cell tumours of childhood*
- *May be focal or pure*
    - *May be seen focally in up to 46% of cases*
    - *Pure pattern requires cytogenetic confirmation for diagnosis*
- *Keratin and EMA reported 33-100% positive, frequently focal*
- *Presence of at least 2 low power fields or 20% by area indicates worse prognosis*
    - *increased recurrence, metastasis, death*
    - *Increased percentage associated with increasingly worse behaviour*

4..3.6 Supplemental Studies Immunohistochemistry

- *Keratin*
    - *Epithelial component of biphasic tumours 95%*
    - *Monophasic spindled tumours 50 – 80% focal*
    - *Keratins 7, 8, 18 and 19 are most widely expressed*
        - *CK7 100% if epithelial component present*
        - *Less frequent in spindled component*
        - *CK20 27%*
- *EMA similar to keratins, but generally less reactivity*
- *TLE1 85-97% - strong nuclei is most specific*
- *Vimentin > 80% in spindled areas, < 30% in epithelial areas*
- *S100 30%, focal*
- *CD99 60%*
- *Calretinin 71%*
- *BerEp4 90%*
- *CD15 rare*
- *WT1 negative*
- *cKit negative vs. positive conflicting reports*

- *Poorly differentiated tumours*
- *Broad spectrum anti-keratin 33-90%, variable*
    - *CK7 27%*
    - *CK 20 negative*
- *EMA > 90%*
- *S100 40 – 63%*
- *CD99 positive*
- *Bc12 postive*
- *CD57 90%*
- *CD56 100%*
- *Calretinin 56%*

4.2 Presentation

Patients with PSSP may present in a number of ways some of which are summarized below:

- PSSP may be diagnosed as an incidental finding following trans-rectal ultra-sound guided biopsy of an incidentally found

irregularity / nodule / mass in prostate on digital rectal examination

- PSSP may be diagnosed upon histological examination of a trans-urethral resection of prostate specimen or prostatectomy specimen obtained following treatment for lower urinary tract symptoms (LUTS) or urinary retention
- PSSP may be diagnosed on pathological examination of trans-rectal ultra-sound biopsy performed on an abnormal digital rectal examination finding when a patient presents with LUTS or retention of urine.
- Patients who have PSSP may present with lower urinary tract symptoms including diurnal frequency, nocturia, poor urinary flow, incomplete emptying of the urinary bladder.
- Other patients may present with urinary tract infection and may be found on digital rectal examination to have an abnormal digital rectal examination finding on the prostate.
- Young patients even in their 3rd decade of life as well as older men with LUTS and a normal serum PSA and abnormal digital rectal examination finding of the prostate.

4.3 Clinical Examination Findings

- The findings on clinical examination of a patient with PSSP would depend upon whether the patient has a localized disease or has metastatic or disseminated disease. But on the whole a suspicion of a prostatic carcinoma is made based upon an abnormal digital rectal examination which could reveal an irregularity in the contour of the prostate; a nodule in the prostate; a mass in the prostate; hardness of part of the prostate and these would alert the urologist to perform a biopsy of the prostate. When the serum PSA is normal and there is abnormal digital rectal examination then this should alert the clinician to the possibility of a rare carcinoma of the prostate different from adenocarcinoma (for example small cell carcinoma or synovial sarcoma). Young age and a mass in the prostate should alert the clinician to suspect an unusual malignancy of prostate.
- Some patients may have enlarged benign feeling prostate without clinical suspicion of a prostatic malignancy.
- Other clinical findings would depend upon whether or not there are metastases. If there is metastasis to the bone then there could be pain and tenderness in the area of the metastasis.

4.4 Laboratory Investigations

- Routine full blood count, coagulation screen, serum urea and electrolytes, liver function tests, and serum glucose are usual tests that are carried out in the overall assessment of the patient.
- Urinalysis, urine microscopy and urine culture are routinely done to exclude urine tract infection prior to the treatment of the patient with PSSP
- Serum PSA tends to be low in PSSP and if a patient has a prostatic lesion suspicious of carcinoma but the serum PSA is low then the possibility of an unusual malignancy or other pathology of the prostate should be considered.

4.5 Radiological Imaging

4.5.1 Ultra-sound scan of abdomen and renal tract and pelvis (see Fig. 5 for example)

- Ultra-sound scan of renal tract and pelvis undertaken for lower urinary tract symptoms or following an episode of urinary retention may occasionally show a lesion in the prostate and this could be a hypo-echoic lesion biopsy of which mat establish the diagnosis after histopathological examination [like in Olivetti]. Ultra-sound scan may also exclude or show hydronephrosis as well as indicate or exclude an obviously enlarged lymph node or metastatic lesion in the abdomen or pelvis.

4.5.2 Trans-rectal ultra-sound scan and biopsy

- Trans-rectal ultra-sound of prostate may show a hypo-echoic lesion in the prostate or it could perhaps be iso-echoic. Trans-rectal ultra-sound guided biopsy of the prostate is a means by which specimens of the prostate are obtained for histopathological examination to establish the diagnosis of synovial sarcoma of prostate. Trans-rectal ultrasound scan of the prostate could be used to assess the prostatic lesion, its size, location,

relationship with the seminal vesicle and capsule as well as extension beyond the prostate gland.

4.5.3 Computed tomography (CT) scan (see Figs. 1 and 6 for example)

- CT scan of abdomen, pelvis and thorax can be done assess the prostate in detail and to find out whether or not there are lymph node enlargement anywhere in the pelvis and abdomen and whether or not there are metastases in any organ in the abdomen, pelvis and thorax. CT scan can also be used to monitor the progress of a primary tumour or metastasis following radiotherapy or chemotherapy

4.5.4 Magnetic Resonance Imaging (MRI) scan (see Fig. 2, 7, and 10 for example)

- MRI scan of pelvis, abdomen and thorax can be performed to study the prostate gland and the lesion in the prostate as well as the extent of the tumour and its relationship with nearby organs. It can also show lymph node enlargement as well as metastasis anywhere (for example abdomen, pelvis, thorax and bones).
- MRI scan can also be used to follow the progress of a primary prostatic lesion or for progress of a metastatic lesion following treatment.

4.5.5 Positron Emission Tomography (PET) scan

PET scan may be used to determine whether or not there is tumour anywhere else in the body.

4.5.6 Isotope bone scan

Isotope bone scan can be used to establish whether or not there is bony metastasis.

4.5.7 Chest X-ray (see Fig. 3 for example)

- Chest X-ray can be performed to assess whether or not there are tumour metastases in the lungs, mediastinum or anywhere in the thorax.

4.6 Macroscopic Features

The gross appearance of the prostatic lesion is non-specific in that there is no specific macroscopic characteristics of the tumour that can be used to establish diagnosis of PSSP

4.7 Microscopic Features (See Fig. 4a for Example)

Microscopic examination of the prostatic lesion tends to reveal the following:

In cases of synovial sarcoma of the prostate, microscopic examination of the prostate tends to reveal:

- Uniform spindle and oval cells which are seen to have formed interlacing fascicles that mimic fibrosarcoma [11-13].
- The compact fascicles of tumour cells tend to focally alternate with hypo-cellular myxoid tissue which mimic peripheral nerve sheath tumours, focal pericytomatous pattern of polygonal cells that tend to be arranged around dilated, thin-walled blood vessels [11,12].

4.8 Immunohistochemistry (See Figs. 4b, 4c and 8 for Example)

4.8.1 Positive stains

Synovial sarcoma of prostate tumour cells on immunohistochemical staining, stain positively with:

- Vimentin (most of the cells) [11,12,14,15].
- EMA (focal positivity) [11,12]
- Bcl-2 (strong positivity) [13,15].
- CD99 (strong positivity) [13,14,16]
- Ecadherin (strong positivity) [13]
- Cytokeratin (focal positivity) [13,15,16]
- CD 56 [16]

4.8.2 Negative stains

Synovial sarcoma of prostate tumour cells exhibit negative staining for the following on immunohistochemistry:

- S100 [11-14,16]
- Keratin [11,12]
- Neurone-specific enolase [11,12]
- CD34 [11-13,16]
- Desmin [11-14,16]
- Muscle-specific actin [11-13]
- Alpha-smooth muscle actin [11,12,14].
- Prostate specific antigen (PSA) [13]
- CD117 [13]
- Calretinin [13]

4.9 Cytogenetic Features/ In Situ Hybridization (FISH) Test (See Fig. 9 for Example)

- T(X, 18)(p11.2,q11.2) [12,13]

Reverse transcriptase polymerase chain reaction tends to demonstrate the presence of an SYT-SSX gene fusion resulting from t(X, 18) [13].

4.10 Differential Diagnosis

A number of other carcinomas of the prostate do exist and PSSP needs to be differentiated from them. Some of these lesions include:

- Other sarcomas (leiomyosarcomas, rhabdomyosarcoma; fibrosarcoma; metastatic sarcomas with the primary malignancy elsewhere.)
- Adenocarcinoma of prostate. Careful examination of the prostatic biopsy specimen should be undertaken to exclude glandular elements in the tumour to ensure there are no adenocarcinomas admixed with the sarcoma
- Small cell carcinoma and other unusual carcinomas or carcinosarcoma (primary sarcomatoid carcinoma of prostate)

4.11 Treatment

- To the knowledge of the author, less than ten cases of PSSP have been reported in the literature but on the whole these tumours have been associated with poor outcome. There is no consensus opinion on the best management options. However, it would appear that unless the patient afflicted by PSSP presents late (with an inoperable / disseminated non localized disease) the aim of treatment should be an aggressive treatment with curative intent which could be any of the following: Anterior exenteration; radical prostatectomy; radical radiotherapy (external beam radiotherapy or brachytherapy); chemotherapy; a combination of radical surgery and radiotherapy; a combination of radical surgery and chemotherapy; a combination of radical surgery plus chemotherapy plus radiotherapy. These suggestions are conjectural in that the treatment to adopt would depend upon the fitness of the patient to undergo the treatment options as well as upon the choice of the patient. It is only after more cases of PSSP have been reported and after a multi-centre trial is undertaken that a consensus opinion regarding treatment options would be recommended.
- Patients with PSSP who are not fit to undergo aggressive radical treatment with curative intent when they develop bladder outlet obstruction or retention of urine who fail trial without catheter could be offered trans-urethral resection of prostate as an attempt to help them void but it should be explained to the patients the procedure is not curative.
- In cases of metastatic and advanced disease the best supportive and palliative care should be provided following assessment and in such situations a multi-disciplinary team approach would be required.

4.12 Outcome

In view of the fact that very few cases of primary synovial sarcoma of the prostate gland (PSSP) have been reported, one cannot be dogmatic about what the outcome of PSSP would be following treatment. Nevertheless, perhaps lessons learnt from the management of synovial sarcomas (SS) in general could be a helpful guide to what the outcome of PSSPs would be following treatment.

Mullen and Zagars, [17] undertook a review of 85 patients who had undergone treatment for synovial sarcomas with regard to prognostic factors and disease outcome for localized synovial synovial sarcoma (SS) which had been treated by means of conservative surgery and radiotherapy. Mullen and Zagars [17] reported that the SS tumours were located in the lower extremity in 48 patients, upper extremity in 20 patients, trunk in 1 patient, and head and neck in 6 patients. All the patients had undergone limited surgical excision of their tumours and radiotherapy. Sixty-seven of the patients had undergone surgery followed by radiotherapy and 18 patients had undergone pre-operative radiotherapy. Thirty-five patients, who mostly had tumours exceeding 5 cm, had received adjuvant Adriamycin-based chemotherapy. At a median follow-up of 8.4 years, the 5-, 10-, and 15-year survival rates were reported to be 76%, 63%, and 57%. Mullen and Zagars [17] further reported that the mortality was almost entirely

related to the development of metastatic disease. Thirty-six had developed metastases which yielded an actuarial 10-year rate of metastasis of 48%. Multivariate analysis had revealed that the size of the tumour was the dominant determining factor of metastases with a lesser contribution due to the age of the patient in that those patients who were aged less than equal to 20 years had fewer metastases. The size of the tumour and the histological features of the tumour were not independently significant. The ten-year rates of metastases according to the size of the tumour, s, were: s < or = 2 cm, 0%; 2 < s < or = 5 cm, 35%; 5 < s < or = 10 cm, 59%; 10 cm < s, 100%. Mullen and Zagars [17] stated that their retrospective data had failed to show any benefits for adjuvant chemotherapy either in univariate or multivariate analysis. Eight patients (9%) had developed local recurrence as the initial failure and 4 others had had local failure after the disease had appeared elsewhere which had yielded a 5-year actuarial local recurrence rate of 14%.

In a retrospective study of 271 patients of all ages with synovial sarcoma studied in one institution by Ferrari et al. [18] over a 30-years period, the reported ages of the patients had ranged between 5 years and 87 years. Ferrari et al. [new 18] had studied 271 patients of whom, 255 had localized disease, which had been macroscopically resected in 215 of the patients, and adjudged un-resectable in 40 patients. Forty-one percent of the patients received chemotherapy which had corresponded to 76% of patients, age or 16 years and less than 20% of older patients; 28% of patients who had macroscopically resected disease had received chemotherapy on adjuvant basis. Ferrari et al. [new 18] reported that the 5-year event-free survival rate for the study cohort on the whole was 37%, even though the rate had varied with regard to age as follows: 66%, 40%, and 31% for patients whose ages were less than or equal to 16 years, 17 to 30 years, and greater than 30 years respectively. Chemotherapy treatment was used more commonly in cases of children in comparison with adults. With regard to patients who had surgically resected disease, the 5-year metastases-free survival (FS) rate was 60% for those who had received chemotherapy and 48% for those who did not receive chemotherapy; the benefit which was associated with chemotherapy use did appear to be greatest for patients whose ages were greater than or equal to 17 years, whose tumours had measured greater than 5 cm (MFS, 47% [chemotherapy] versus 27% [no chemotherapy]. With regard to the sub-group of patients with measurable disease, the rate of tumour- response to chemotherapy was about 48%. Ferrari et al. [18] concluded that even though the authors were awaiting more convincing proof of the efficacy of adjuvant chemotherapy with regard to the treatment of adult soft tissue sarcomas, they would recommend that those patients who have high-risk synovial sarcomas (SSs), (those patients with tumours greater than 5 cm) should be the first to be considered for this type of treatment.

So far the outcome of PSSP with regard to the very few cases reported would indicate a poor prognosis; therefore if a patient is fit then perhaps early aggressive treatment with curative intent would appear to offer a chance of cure.

5. DISCUSSIONS AND MISCELLANEOUS NARRATIONS FROM SOME REPORTED CASES

Iwasaki et al. [12] reported a 37-year-old man who was diagnosed as having monophasic synovial sarcoma of prostate. They reported that histopathological examination of the prostate had shown that the tumour was mainly composed of uniform spindle and oval cells which had often formed interlacing fascicles which mimicked those of fibrosarcoma. In certain areas, the compact fascicles of tumour cells had alternated with hypo-cellular myxoid tissue which bore a superficial resemblance to peripheral nerve sheath tumours, whereas, small parts of the tumour had shown a pericytomatous pattern which comprised of polygonal cells, and which, were arranged surrounding dilated, thin-walled blood vessels. Immunohistochemistry of the tumour showed positivity for vimentin in most cells, and focal immunoreactivity for epithelial membrane antigen. On immunohistochemistry, the tumour cells were found to be negative for keratin, S-100 protein, neuron-specific enolase, CD34, desmin, muscle-specific-actin, and alpha-smooth-muscle-actin. Iwasaki et al. [6] also reported that the results of cytogenetic studies and fluorescence in situ hybridization (FISH) test they had undertaken using the patient's cultured tumour cells had revealed translocation t(X, 18) (p11.2,q11.2), an aberration which is specific for synovial sarcoma. Iwasaki et al. [6] further stated that their case was the first reported case of synovial sarcoma of prostate confirmed by cytogenetic analysis.

Jun et al. [13] in 2008 reported two cases of primary synovial sarcoma of the prostate which

had manifested as a mass in the prostate gland in patients who were aged 44 years and 46 years. They reported that histological examination of specimens of the prostate glands had shown that both tumours were mainly composed of uniform spindle cells which had formed interlacing fascicles. Clusters of immature epithelioid were also seen among the spindle cells in the first case. Immunohistochemistry studies of both tumours of the prostate had shown that the tumour cells of both cases were strongly positively stained for vimentin, bcl-2, CD99, and E-cadherin. Immunohistochemistry had also shown that both prostatic tumour cells were focally positively stained for cytokeratin. Furthermore, immunohistochemical studies had shown that both tumours were negatively stained for prostate-specific antigen (PSA), S-100 protein, CD34, CD117, muscle-specific-actin, desmin, and calretinin. Jun et al. [7] stated that they had also demonstrated from paraffin blocks by means of reverse transcriptase polymerase chain reaction tests in both cases the presence of SYT-SSX fusion by gene fusion resulting from t(X, 18). Jun et al. [13] stated that:

- To their knowledge, their two reported cases represent the fifth and sixth reported cases of synovial sarcoma of the prostate gland.
- Accurate diagnosis of synovial sarcoma of prostate depends upon morphologic and immunohistochemical studies, as well as proper molecular analysis.

Zhang et al. [14] in 2014 reported a 22-year-old man had presented with lower urinary tract symptoms which had culminated in him developing retention of urine. He had had dysuria, diurnal frequency, and nocturia (voiding five times in the night) before he developed retention of urine. He had a digital rectal examination which had shown a large prostatic mass with smooth surface. His serum prostate-specific antigen (PSA) level was 1.2 ng / ml (normal range 4 ng / ml or less). He had computed tomography (CT) scan of pelvis (see Fig. 1) and magnetic resonance imaging (MRI) scan (see Fig. 2) which had shown a 14 cm mass adjudged to have originated in the fascia of the prostate gland. The CT and MRI scans had also shown an 8.5 cm mass in the right groin. His CT scan of thorax and chest X-ray had shown evidence of liver and lung metastasis (see Fig. 3). The authors had commented the patient's age was too young with regard to the age range of patients who develop adenocarcinoma of prostate gland. He had trans-rectal ultrasound-guided biopsy of the prostate gland and pathological examination of the specimen had shown that the tumour was synovial sarcoma of the prostate. Zhang et al. [14] stated that the pathological features of the specimen were consistent with the diagnosis of synovial sarcoma which had arisen from the prostate gland (see Fig. 4). Zhang et al. [14] also reported that immunohistochemistry studies had shown that the tumour cells were positively stained for vimentin and CD 99; however, the tumour cells were negatively stained for alpha-smooth-muscle-actin, desmin and S-100 protein. Furthermore, Zhang et al. [14] reported that they had used RT- polymerase chain reaction (PCR) and genomic DNA from paraffin blocks of the prostatic specimen to confirm presence of SYT-SSX fusion transcript. The patient refused to be treated by means of radiotherapy, chemotherapy and radical prostatectomy which were recommended. The patient's disease progressed rapidly and at 3-months of follow-up, he had developed multiple pulmonary metastases and subsequently died of respiratory failure. Zhang et al. [14] stated that to their knowledge, prior to the publication of their case in 2014, only six cases of synovial sarcoma of the prostate had been reported in the literature.

Porter 2nd et al. [19] in 2001reported a case of synovial sarcoma which was initially found in the spine which subsequently metastasized to the testis and testis 6 years pursuant to his treatment. This case report would indicate that primary synovial sarcoma elsewhere can metastasize to the prostate gland and to the testis as well. Shirakawa et al. [20] in 2003 reported a case of complete resection of synovial sarcoma of prostatic fascia. Pan and Chang [21] reported in 2006 reported another case of synovial sarcoma of the prostate. Williams, et al. [22] also in 2004 also reported a case of synovial sarcoma of the prostate.

Table 1. Table of reported cases of synovial sarcoma of prostate (Please check table caption)

Authors & reference	Number of cases / Age / Immunohistochemistry of tumour	Treatment	Outcome
Iwasaki et al. [12] in 1999	1 (37 years) **Positive staining for:** Vimentin **Focally positive staining for**: Epithelial membrane antigen **Negative staining for :** Keratin, S-100 protein, Neuron-specific enolase CD 34 Desmin, Muscle-specific actin Alpha-smooth muscle actin	Details not available to author	Details not available to author
Shirakawa et al. [20] in 2003	Details not available to author	Complete resection of tumour localized in prostatic fascia	Details not available to author
Williams et al. [22] in 2004	Details not available to author	Details not available to author	Details not available to author
Pan & Chang [21] in 2005	Details not available to author	Details not available to author	Details not available to author
Jun et al. [13] in 2008	2 (44years & 46 years) prostate **Positive staining:** Both cases exhibited strong positive staining for: Vimentin, Bcl-2, CD99, E-cadherin **Focal positive staining:** Both tumours were focally positively stained for Cytokeratin **Negative staining** Both tumours were negatively stained for: PSA, S-100 protein, CD34, CD117, Muscle-specific Actin, Desmin, Calretinin.	Details not available to author	Details not available to author
Zhang et al. [14] in 2014	1 (22 years) prostate primary with liver and lung metastasis **Positive staining for:** Vimentin	He refused treatment	Died a little over 3 months later

Authors & reference	Number of cases / Age / Immunohistochemistry of tumour	Treatment	Outcome
	CD99 **Negative staining for:** Alpha-smooth muscle actin, Desmin, S-100 protein		
Olivetti et al. [16] in 2015	1 46 years **Positive staining:** Pancytokeratin focally positive for scattered individual spindle cells, CD 56 – diffusely positive, CD 99 – diffusely positive **Negative staining for:** S-100 protein, Muscle actin, Desmin, CD 34.	Debulking surgery+chemotherapy (refused radical surgery)	Tumour persisted after 6 cycles of chemotherapy after 3 months
Dhabalia et al. [15] in 2009	25 years **Positive staining for:** Vimentin, Bcl-2, Cytokeratin.	Radical surgery (total pelvic exenteration with sigmoid end colostomy and ileal conduit)	Alive and well after 18 months with no metastasis
Summary 7 single case reports And one report of 2 cases	9 patients reported so far in 8 reports		

Dhabalia et al. [15] in 2009 reported a 25 year old man in India who was referred who had undergone trans-rectal ultrasound scan guided biopsy of prostate, histological examination of which had shown a poorly differentiated sarcoma of the prostate gland. He had been catheterized because of retention of urine. He had had MRI scan which had shown a solid tumour of the prostate gland that measured 9.5 cm x 8 cm. The tumour had involved the rectum without any evidence of lymphatic or distant metastases. He underwent total pelvic exenteration and sigmoid end colostomy as well as ileal conduit. Dhabalia et al. [15] also reported that histopathological examination had revealed synovial sarcoma of the prostate gland and immunohistological examination of the tumour positive immunohistochemistry for vimentin, Bcl-2, and cytokeratin. The patient was also reported as doing well at his 18 months follow-up.

Olivetti et al. [16] reported a 46-year-old man who had developed urinary retention. He had a digital rectal examination which revealed a large prostatic mass. His serum PSA level was 1.03 ng / ml (normal range 0 to 4 ng / ml). He had an ultrasound scan of pelvis which had shown an 8.5 cm x 8 cm x 8.5 cm lesion which confined to the prostatic region and behind the urinary bladder with a heterogeneous mixed echogenicity (see Fig. 5). He had computed tomography (CT) scan which had shown a well-demarcated soft tissue tumour which appeared to have originated from the prostate gland and had extended to the retro-vesical soft tissue, with

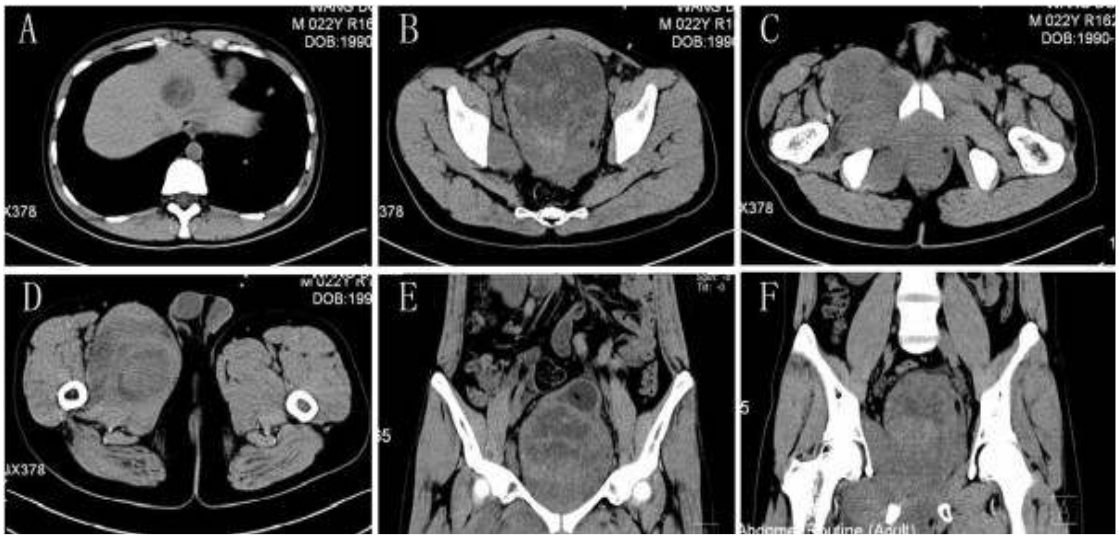

Fig. 1. Enhanced pelvic computed tomography

(A) Evidence of liver metastasis. (B-F), Enhanced pelvic computed tomography revealed a 14 cm mass that appeared to originate in the prostatic fascia, An 8.5 cm mass was found on pelvic magnetic resonance imaging. Zhang et al. [14]. Primary synovial sarcoma of prostate metastatic to the liver and lung: a case report. World Journal of Surgical Oncology 2014;12:194. DOI: 10.1186/1477-7819-12-194. Copy Right © 2014 Zhang et al., licensee Bio Med Central. This is an Open Access article distributed under the terms of the Creative Commons Attribution License (http://creativecommons.org/licenses/by/2.0), which permits unrestricted, distribution, and reproduction in any medium, provided the original work is properly credited. The original source and licensee still maintain the Copy Right

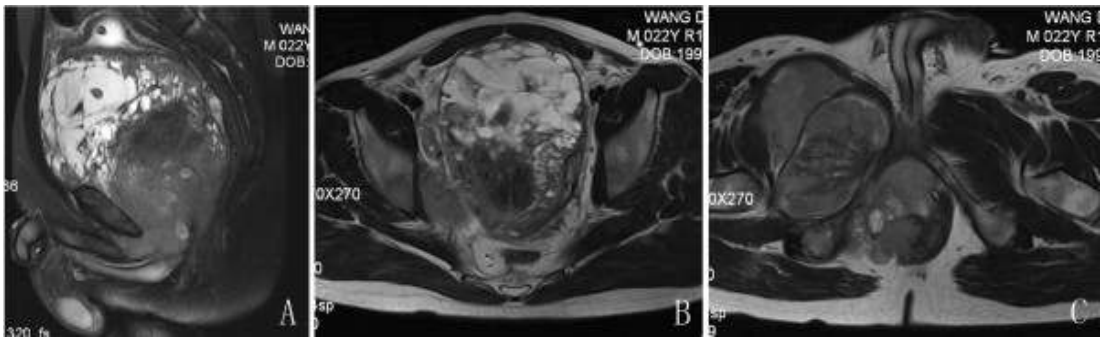

Fig. 2. Enhanced pelvic magnetic resonance imaging

(A-C) Enhanced T2 weighted MR revealed a high signal mass originating in the prostatic fascia and an 8.5 cm mass was found in the right groin area. Reproduced from: Zhang et al. [14]. Primary synovial sarcoma of prostate metastatic to the liver and lung: A case report. World Journal of Surgical Oncology 2014;12:194. DOI: 10.1186/1477-7819-12-194. Copy Right © 2014 Zhang et al., licensee Bio Med Central. This is an Open Access article distributed under the terms of the Creative Commons Attribution License (http://creativecommons.org/licenses/by/2.0), which permits unrestricted, distribution, and reproduction in any medium, provided the original work is properly credited. The original source and licensee still maintains the copy right

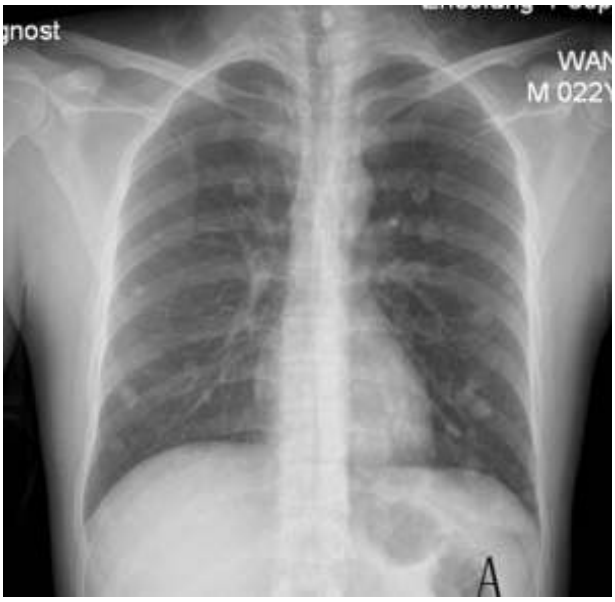

Fig. 3 Chest radiography Evidence of lung metastasis

Reproduced from: Zhang et al. [14]. Primary synovial sarcoma of prostate metastatic to the liver and lung: a case report. World Journal of Surgical Oncology. 2014;12:194. DOI: 10.1186/1477-7819-12-194.

Copy Right © 2014 Zhang et al., licensee Bio Med Central.
This is an Open Access article distributed under the terms of the Creative Commons Attribution License (http://creativecommons.org/licenses/by/2.0), which permits unrestricted, distribution, and reproduction in any medium, provided the original work is properly credited. The original source and licensee still maintain the Copy Right

fluid, cystic, and a solid structure (see Fig. 6). There was no evidence of metastasis. He also had magnetic resonance imaging (MRI) scan which had indicated that the mass had originated in the fascia of the right lobe of the prostate gland. The mass had a predominantly cystic myxoid component with septa with septa and irregular eccentric solid tissue which had homogeneously enhanced after godalinium injection. The right seminal vesicle was noted to be depressed. The posterior aspect of the lesion was noted to be in close approximation with the rectum, laterally right obturator internus muscle and inferiorly with the levator ani muscle (see Fig. 7). The patient had pre-operative trans-rectal ultra-sound guided biopsy of the lesion and histological examination the biopsy specimen was reported as having shown mesenchymal neoplastic tissue. He refused to undergo radical prostatectomy. He instead underwent a de-bulking surgical removal of the lesion but the excision was incomplete because the large extent of the tumour had prevented its complete excision. Olivetti et al. [16] reported that microscopic examination of the haematoxylin and eosin stained specimen of the tumour had shown a spindle cell neoplasm which consisted of small uniform spindle cells which had a high nuclear / cytoplasmic ratio, and finely stippled chromatin. The neoplastic cells were noted to be closely packed, in short interlacing and intersecting fascicles encompassing a branching “a hemangiopericytoma-like vasculature” (see Fig. 8a). The mitotic rate of the tumour was 1 to 2 mitoses per high power field. No glandular differentiation was found in the tumour and there was no evidence of tumour necrosis. The immunohistochemistry profile of the tumour was reported as follows: Pan-cytokeratin expression was confined to scattered, individual spindle cells (see Fig. 8b); diffuse expression of CD56 and CD99 (see Fig. 9c). However, S-100 protein, muscle actin, desmin, and CD34 were entirely negatively stained on immunohistochemistry. Olivetti et al. [16] further reported that fluorescence in situ hybridization test (FISH) test for t(X; 18) (p11q11) was positive and it did show splitting of fluorescent signal which was confirmative of a rearrangement with SYT (see Fig. 9). Based upon the aforementioned findings Olivetti et al. [16] established a diagnosis of monophasic synovial sarcoma with positive surgical margins. The patient received 6 cycles of post-operative chemotherapy (epirubicin and

ifosfamide). At his 3-month follow-up after he had received 6 cycles of chemotherapy he had MRI scan of the pelvis which had shown persistence of the tumour which had cystic and solid component confined to the prostatic loggia and invasion of the right lobe of the prostate (see Fig. 10). He had trans-rectal ultra-sound guided biopsy of the prostate histology of which had confirmed the presence of monophasic synovial sarcoma of prostate. He had Positron Emission Tomography (PET) scan which did not show any evidence of distant metastasis.



Fig. 4. Pathologic Analysis
(A)The pathologic findings of the tumour (H&E)
(B) Immunohistochemical staining for vimentin in tumor tissue
(C) Immunohistochemical staining for CD99 in tumor tissue

Reproduced from: Zhang et al [14].Primary synovial sarcoma of prostate metastatic to the liver and lung: a case report. World Journal of Surgical Oncology 2014; 12: 194 doi: 10.1186/1477-7819-12-194. Copy Right © 2014 Zhang et al., licensee Bio Med Central

This is an Open Access article distributed under the terms of the Creative Commons Attribution License (http://creativecommons.org/licenses/by/2.0), which permits unrestricted, distribution, and reproduction in any medium, provided the original work is properly credited. The original source and licensee still maintain the Copy Right

Fig. 5. Pelvic ultrasound: A large hypo-echoic mass (asterisk) is seen in the prostatic loggia.

The arrow indicates the urinary catheter. Reproduced from: [16] Olivetti L, Benecchi L, Corti S, Del Bocca C, Ferrari M, Sergio P, Bercich L, Tanzi G. Monophasic Synovial Sarcoma of Prostatic Fascia: Case Report and Literature Review. Case Reports in Urology Volume 2015 (2015), Article ID 419180 5 pages http://dx.doi.org/10.1155/2015/419180] Copy Right © 2015 Lucio Olvetti et al. This is an open access article distributed under the Creative Commons Attribution License, which permits unrestricted use, distribution, and reproduction in any medium provided the original work is properly cited. The original source and licensee still maintain the Copy Right

Olivetti et al. [16] stated that synovial sarcoma of the prostate is a rare disease and that prior to the report of their case in 2015, only seven cases [12-14,20-22] had been previously reported and to their knowledge their case was the 8th case of synovial sarcoma of the prostate to be reported.

Synovial sarcoma was first reported in 1893 and it had been said to represent a relatively common type of soft tissue malignancy. [1,23-35] Other terminologies had been used for SS and these include: tendosynovial sarcoma, synovial cell sarcoma, synovioma, synovial endothelioma, malignant synovioma, synovioblastic sarcoma. [1,24] Despite the terminology SS has not been found to arise in an “intra articular” location but it tends to occur near joints [27].

Considering the fact PSSP is very rare, it would be argued that perhaps the diagnosis of PSSP in small hospitals would be difficult for clinicians and pathologist especially for those working in non-tertiary centres where facilities do not exist for chromosomal analysis studies and in such situations the specimens obtained from the prostate gland would be to be sent to large well equipped centres where all the facilities are available to confirm t(X; 18; p11; q11) translocation in the tumour.

Furthermore, considering the fact that PSSP is rare, it would appear that there is no consensus opinion on its medical management; nevertheless, perhaps, lessons learnt from the management of synovial sarcomas of other organs could be used as a guide. Vargas and Gellman [36] stated the following:

- Adjuvant chemotherapy and neo-adjuvant chemotherapy had been suggested for patients who have metastatic soft tissue sarcomas. However, chemotherapy in the setting of synovial sarcoma is controversial.
- Ladenstein and associates [37] had documented improved survival rates with regard to the use of adjuvant doxorubicin and cyclophosphamide-based chemotherapy. A number of authors had recommended combinations of doxorubicin (75 g/m^2 via continuous infusion over 3 days), and bolus ifosfamide (2.5 g/m^2 daily for 4 days or ifosfamide with liposomal daunorubicin). Granulocyte colony stimulating factor (G-CSF) could stimulate the bone marrow. In cases of extremity tumours that are larger than 5 cms it had been recommended that chemotherapy should be considered [38-40,37]

Fig. 6. CT of the pelvis: enhanced axial image

The asterisk is on the cystic component of the mass. The arrow shows the solid part of the lesion. B = bladder
Reproduced from: [16] Olivetti L, Benecchi L, Corti S, Del Bocca C, Ferrari M, Sergio P, Bercich L, Tanzi G. Monophasic Synovial Sarcoma of Prostatic Fascia: Case Report and Literature Review. Case Reports in Urology Volume 2015 (2015), Article ID 419180 5 pages http://dx.doi.org/10.1155/2015/419180] Copy Right © 2015 Lucio Olvetti et al. This is an open access article distributed under the Creative Commons Attribution License, which permits unrestricted use, distribution, and reproduction in any medium provided the original work is properly cited. The original source and licensee still maintain the Copy Right

- It had been stated that Murine monoclonal antibody attacks a frizzled homologue which is called FZD10 (a cell surface receptor) which is found in cells of synovial sarcoma but which are absent in normal cells and that some studies had shown promising results in the treatment of synovial cell sarcoma xenografts with murine monoclonal antibody [41] Nevertheless, it had been stated that clinical applications of the aforementioned monoclonal antibodies are not available for use presently [42].
- Chemotherapy has so far not been proven to result in a significant survival rates in all series of synovial sarcoma.

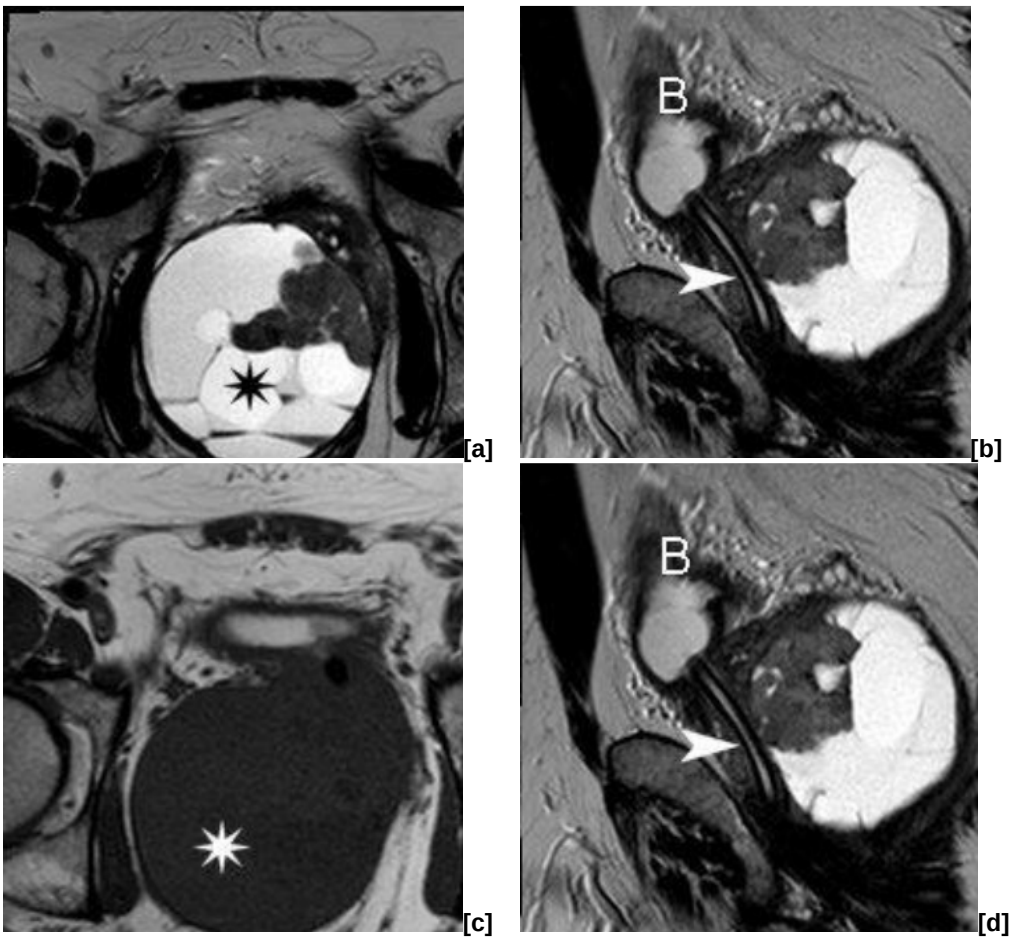

Fig. 7. MRI: Axial (a) and sagittal (b) T2-weighted images. Axial pre-contrast (C) and post-contrast (D) T1-weighted images; the asterisk is on the cystic component of the prostatic lesion; septa are evident

The arrow shows the solid component that improves the gadolinium injection. Note the presence of a urinary catheter (arrowhead). B = bladder; R = rectum. Reproduced from: [16] Olivetti L, Benecchi L, Corti S, Del Bocca C, Ferrari M, Sergio P, Bercich L, Tanzi G. Monophasic Synovial Sarcoma of Prostatic Fascia: Case Report and Literature Review. Case Reports in Urology Volume 2015 (2015), Article ID 419180 5 pages http://dx.doi.org/10.1155/2015/419180] Copy Right © 2015 Lucio Olvetti et al. This is an open access article distributed under the Creative Commons Attribution License, which permits unrestricted use, distribution, and reproduction in any medium provided the original work is properly cited. The original source and licensee still maintain the Copy Right

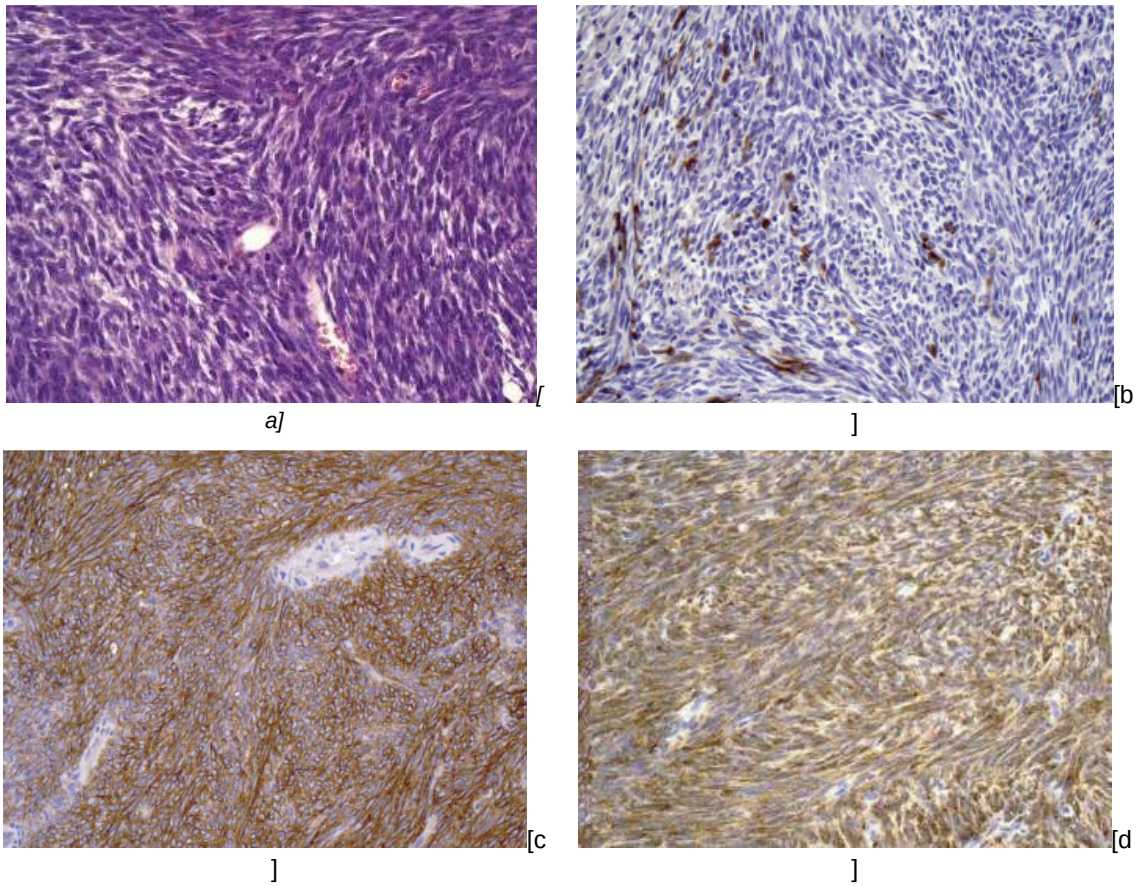

Fig. 8. The spindle cells are small, uniform, and closely packed and have a high nuclear-cytoplasmic ratio. (a) Immunohistochemical staining showing scattered spindle cells positive for CK AE1/AE3 (b). Diffuse expression of BCL-2 (c) and CD99 (d) in spindle *cells* *Reproduced from: [16] Olivetti L, Benecchi L, Corti S, Del Bocca C, Ferrari M, Sergio P, Bercich L, Tanzi G. Monophasic Synovial Sarcoma of Prostatic Fascia: Case Report and Literature Review. Case Reports in Urology Volume 2015 (2015), Article ID 419180 5 pages http://dx.doi.org/10.1155/2015/419180] Copy Right © 2015 Lucio Olvetti et al. This is an open access article distributed under the Creative Commons Attribution License, which permits unrestricted use, distribution, and reproduction in any medium provided the original work is properly cited. The original source and licensee still maintain the Copy Right*

Terry et al. [43] stated the following:

- Synovial sarcoma has been defined by the SYT-SSX fusion oncogene.
- The demonstration of t(X, 18) by means of cytogenetics studies, fluorescent in situ hybridization, or reverse-transcriptase polymerase chain reaction had become the gold standard for the diagnosis of synovial sarcoma; nevertheless, practical considerations have been a limiting factor for the availability of the aforementioned methods to establish a diagnosis of synovial sarcoma.
- Gene expression profiling studies which had been undertaken by a number of independent groups had consistently identified TLE1 as an excellent discriminator of synovial sarcoma from other types of sarcoma including tumours which on histological examinations simulate synovial sarcoma including peripheral nerve sheath tumour.
- TLE proteins (human homologues of Groucho) are transcriptional corepressors which inhibit wnt signalling as well as other cell fate determination signals, and thus have an established role in repressing differentiation.

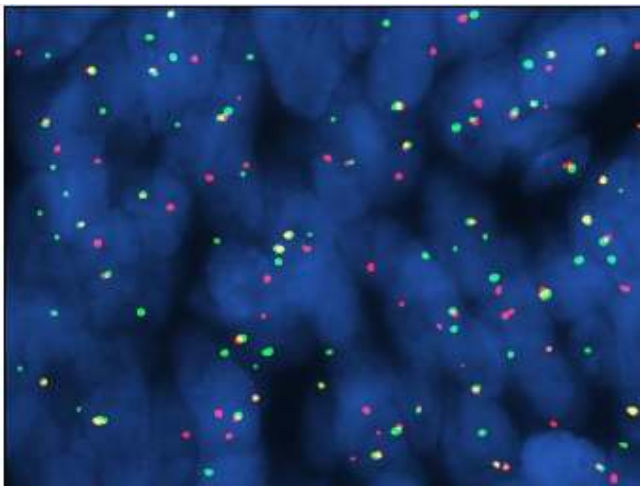

Fig. 9. Photomicrograph of FISH results showing splitting of the fluorescent signal revealing SYT rearrangement.

Reproduced from: [16] Olivetti L, Benecchi L, Corti S, Del Bocca C, Ferrari M, Sergio P, Bercich L, Tanzi G. Monophasic Synovial Sarcoma of Prostatic Fascia: Case Report and Literature Review. Case Reports in Urology Volume 2015 (2015), Article ID 419180 5 pages http://dx.doi.org/10.1155/2015/419180] Copy Right © 2015 Lucio Olvetti et al. This is an open access article distributed under the Creative Commons Attribution License, which permits unrestricted use, distribution, and reproduction in any medium provided the original work is properly cited. The original source and licensee still maintain the Copy Right

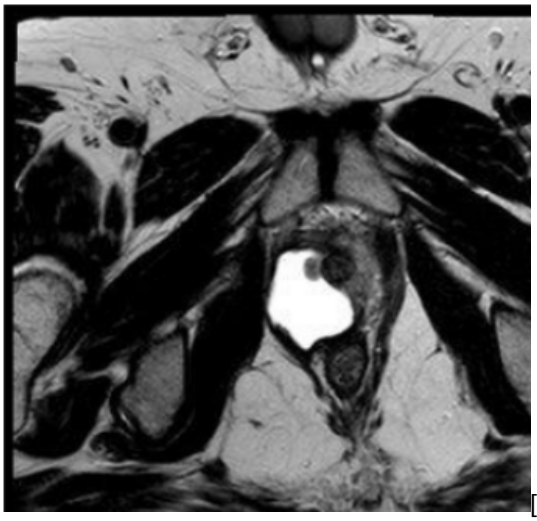

[a]

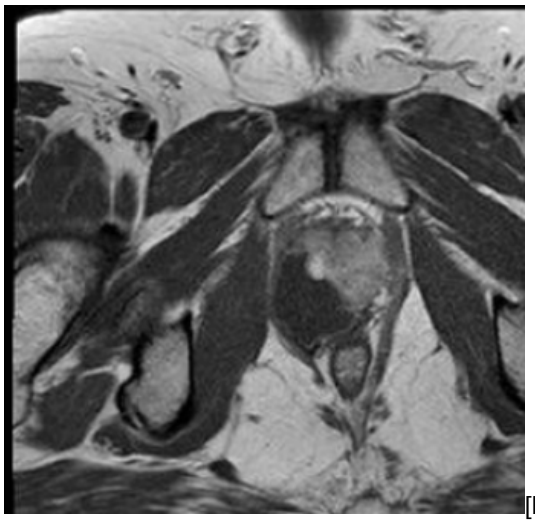

[b]

Fig. 10. MRI: Post-operative images. Axial T2-weighted (a) and T1-weighted after administration (b) images Persistence of synovial sarcoma in prostatic loggia.

Reproduced from: [16] Olivetti L, Benecchi L, Corti S, Del Bocca C, Ferrari M, Sergio P, Bercich L, Tanzi G. Monophasic Synovial Sarcoma of Prostatic Fascia: Case Report and Literature Review. Case Reports in Urology Volume 2015 (2015), Article ID 419180 5 pages http://dx.doi.org/10.1155/2015/419180] Copy Right © 2015 Lucio Olvetti et al. This is an open access article distributed under the Creative Commons Attribution License, which permits unrestricted use, distribution, and reproduction in any medium provided the original work is properly cited. The original source and licensee still maintain the Copy Right

Terry et al. [43] examined the expression of TLE proteins in synovial sarcoma as well as in a broad range of mesenchymal tumours by using tissue microarrays to assess the value of anti-TLE antibodies in the confirmation of synovial sarcoma by immunohistochemistry studies. Terry et al. [43] demonstrated that the expression of TLE is a consistent feature of synovial sarcoma with the use of both a well-characterized monoclonal antibody recognizing the TLE family of proteins and a commercially available polyclonal antibody which has been raised against TLE1. Terry et al. [43] reported the following results:

- Both antibodies had given intense and or diffuse nuclear staining in 91 out of 94 synovial sarcomas that had been confirmed by molecular studies. Moderate staining was occasionally seen in schwannoma and solitary fibrous/hemangiopericytoma.
- On the contrary, TLE staining was detected much less frequently, at lower levels, if at all in 40 other mesenchymal tumours.

Terry et al. [43] concluded that their findings had established that TLE is a robust immunohistochemical marker for the establishment of a diagnosis of synovial sarcoma and that TLE may have implications for the understanding of the biology of synovial sarcoma and for the development of experimental therapies for synovial sarcoma.

6. CONCLUSIONS

PSSP is an extremely rare aggressive tumour with poor prognosis. There is no consensus opinion regarding treatment PSSP because less than 10 cases have been reported in the literature to the knowledge of the authors. Confirmation of diagnosis of PPSP requires cytogenetics evidence of a specific chromosomal translocation t(X; 18; p11; q11). It may be conjectural but there is a slight possibility that PSSP may have been under-reported because the diagnosis could be missed due to the rarity of the disease and perhaps due to the non-availability of facilities for cytogenetic studies and if prostatectomy specimens or prostate biopsy specimens are not sent to tertiary centres where there facilities for cytogenetic studies the diagnosis might probably not have been confirmed. All cases of PSSP should be entered into a multi-centre trial to ascertain the best treatment option that would improve the prognosis and to further assess its biological behaviour.

CONSENT

It is not applicable in literature review.

ETHICAL APPROVAL

It is not applicable in literature review.

ACKNOWLEDGEMENTS

Acknowledgements to:

1. World Journal of Surgical Oncology and Bio Med Central for granting Copy Right Permission for contents of publications from their journal to be reproduced under the Creative Commons Attribution License as follows: Copy Right © 2014 Zhang et al., licensee Bio Med Central. This is an Open Access article distributed under the terms of the Creative Commons Attribution License (http://creativecommons.org/licenses/by/2.0), which permits unrestricted, distribution, and reproduction in any medium, provided the original work is properly credited.
2. Case Reports in Urology and Hindawi Journals Publications Limited for granting Copy Right permission for contents of publications from their journal to be reproduced under the Creative Commons Attribution License as follows: Case Reports in Urology Volume 2015 (2015), Article ID 419180 5 pages http://dx.doi.org/10.1155/2015/419180] Copy Right © 2015 Lucio Olvetti et al. This is an open access article distributed under the Creative Commons Attribution License, which permits unrestricted use, distribution, and reproduction in any medium provided the original work is properly cited.

COMPETING INTERESTS

Author has declared that no competing interests exist.

REFERENCES

1. Fischer C, De Bruijn DRH, Geurts Van Kessel A, Fletcher Christopher GM, Krishnan Unni K, Mertens Fredrik. Lyon IARC Press. Tumors of uncertain differentiation: In Pathology and Genetics of tumors of Soft Tissue and Bone. World Health Organization classification of Tumors. 2002;200–204
2. Kottu R, Prayaga AK. Synovial sarcoma with relevant immunohistochemistry and special emphasis on the monophasic fibrous type. J. Cytol. 2010;27(2):47–50. DOI: 10.4103/0970-9371.70736
3. Enzinger FM, Weiss SE. Synovial Sarcoma. In: Enzinger FM, Weiss SE, editors; soft tissue tumors. 4th ed. St Louis C. V. Mosby. 2006;1483-1502.
4. Synovial sarcoma-Wikipedia, the free encyclopedia. Available:https://en.wikipedia.org/wiki/Synovial_sarcoma
5. Raphael E, Pollock, ed. Soft Tissue Sarcomas American Cancer Society Atlas of Clinical Oncology; 2002; Decler BC. ISBN 155009128X
6. Pfeiffer JD, Hill DA, O'Sullivan MJ, Dehner LP. Diagnostic gold standard for soft tissue tumours: Morphology or molecular genetics? Histopathology. 2000;37(6):485–500.

   DOI:10.1046/j.1365.2559.2000.01107.X PMID 11122430.
7. O'Sullivan MJ, Kyriakos M, Zhu X, et al. Malignant peripheral nerve sheath tumors with t(X; 18): A pathological and molecular genetic study. Mod Pathol. 2000;13(12): 1336–1348.

   DOI: 10.1038/modpathol.3880247.

   PMID 11144931
8. Coindre J M, Hostein I, Benhatter J, Lussan C, Rivel J, Guillou L. Malignant peripheral nerve sheath tumors are t(X; 18) negative sarcomas. Molecular analysis of 25 cases occurring in neurofibromatosis type 1 patients using two different RT-PCR based methods of detection. Mod Pathol. 2002;15(6):589–592.

   DOI: 10.1038/modpathol.3880570.

   PMID 12065770.
9. Middeljans E, Wan X M, Jansen P W, Sharma V, Shunnenberg H G, Logie C. Freitag Michael, ed. SS18 together with animal-specific factors defined human BAF-type SW1/SNF complexes. Plos one. 2012;7(3):e33834.

   DOI: 10.1371/journal.pone.0033834.

   PMC. 3307773. PMID 22442726.
10. Kempson R L, Rouse R V last update Synovial Sarcoma – Surgical Pathology Criteria – Stanford surgpathcriteria.stanford.edu last updated 03/08/2012
11. Arora K. Prostate other malignancies synovial sarcoma. Pathology. Outlines.com. 2012;21.

    Available:www.pathologyoutlines.com/topic/prostatesynovialsarcoma.html
12. Iwasaki H, Ishiguro M, Ohjimi Y, Ikegami H, Takeuchi T, Kikuchi M, Kaneko Y, Anyoshi A. Synovial sarcoma of prostate with t(X, 18)(p11.2,q11.2). Am. J. Surg Pathol. 1999;23(2):220–224
13. Jun L, Ke S, Zhaoming W, Linjie X, Xinru Y. Primary synovial sarcoma of prostate: report of 2 cases and literature review. Int. J. Surg Pathol. 2008;16(3):329–334.

    DOI: 10.117/1066896907309575.

    Epub 2008 Apr 2
14. Zhang Q, Wang H, Ren L, Qi X, Liu F, Zhang D, Primary synoval sarcoma of prostate metastatic to the liver and lung: A case report. World Journal of Surgical Oncology. 2014;12:194.

    DOI: 10.1186/1477-7819-12-194
15. Dhabalia J V, Nelivigi G G, Singh Punia M, Kumar V, Kakkattil M, Suryayanshi M, Gokhale A. A rare case of synovial sarcoma of the prostate. African Journal of Urology. 2009;15(3):183-185.
16. Olivetti L, Benecchi L, Corti S, Del Bocca C, Ferrari M, Sergio P, Bercich L, Tanzi G. Monophasic synovial sarcoma of prostatic fascia: Case report and literature review. Case Reports in Urology. 2015;2015: Article ID 419180:5.

    Available:http://dx.doi.org/10.1155/2015/419180
17. Mullen JR, Zagars GK. Synovial sarcoma outcome following conservation surgery and radiotherapy. Radiother Oncol. 1994; 33(1):23–30.
18. Ferrari A, Gronchi A, Casanova M, Meazza C, Gandola L, Collini P, Lazza L, Bertulli R, Olmi P, Casali PG. Synovial sarcoma: A retrospective analysis of 271 patients of all ages treated at a single institution. Cancer. 2004;101(3):627-634.

19. Porter HJ, Damjanov I, Arnold P, Brantley Thrasher J. Synovial sarcoma metastatic to the penis and prostate The Journal of Urology. 2001;166(2):605.
Available:http://dx.doi.org/10.1016/S0022-5347(05)65996-4
20. Shirakawa T, Fujisawa M, Gotoh A, Okada H, Arakawa S, Kamidono S, Complete resection of synovial sarcoma of prostatic fascia. Urology. 2003;61(3):644.
21. Pan CC, Chang YH, Primary synovial sarcoma of the prostate. Histopathology. 2006;48(3):321–323 Article first published on line 2005 Sep 2.
DOI:10.1111j.1365-2559.2005.02235.x.
22. Williams DH, Hua VN, Chowdhry AA, Laskin WB, Kalapurakal JA, Dumanian GA, Dalton DP, Synovial sarcoma of the prostate. J Urol. 2004;171(6 Pt1):2376.
23. Kransdorf MJ, Murphey MD. Imaging of soft tissue tumors. 2nd ed. Philadelphia, Pa, Lippincott William & Wilkins; 2006.
24. Weiss SW, Goldblum JR. Malignant soft tissue tumors of uncertain type: In Weiss SW, Goldblum JR, eds. Enzinger and Weiss's soft tissue tumors. 4th ed. St. Louis. Mo: Mosby. 2001;1483-1565.
25. Miettinen M. Soft tissue tumors with epithelial differentiation: In: Diagnostic soft tissue pathology. New York N Y Churchill Livingstone. 2003;463-468.
26. Kempson RL, Fletcher CD, Evans HL, Hendrickson MR, Sibley RK. Tumors of uncertain and nonmesenchymal differentiation. In: Atlas of tumor pathology: Tumors of the soft tissues. Washington D C: Armed Forces Institute of Pathology. 2001;472-484.
27. Murphey MD, Gibson MS, Jennings BT, Crespo-Rodriguez AM, Fanburg-Smith J, Gajewski DA. Imaging of synovial sarcoma with radiologic-pathologic correlation. Radio Grahics. 2006;26(5). Available:pubs.rsna.org/doi/full/10.1148/rg.265065084
28. Pack GT, Ariel IM. Synovial sarcoma (malignant synovioma): A report of 60 cases. Surgery. 1950;28:1047–1084.
29. Hare HF, Cerny MJ, Jr. Soft tissue sarcoma: A review of 200 cases. Cancer. 1963;16:1332-1337.
30. Cadman NL, Soule EH, Kelly PJ. Synovial sarcoma: An analysis of 34 tumors. Cancer. 1965;18:613–627.
31. Kransdorf MJ. Malignant soft-tissue tumors in a large referral population: Distribution of diagnoses by age, sex and location. A J R Am J. Roentgenol .1995;164:129-134.
32. Thompson DE, Frost HM, Hendrick JW, Horn RC Jr. Soft tissue sarcomas involving the extremities and the limb girdles: A review. South Med. J. 1971;64:33-44.
33. Tsujimoto M, Aozasa K, Ueda T, et al. Soft tissue sarcomas in Osaka, Japan (1962-1985): review of 290 cases. Jpn. J, Clin. Oncol. 1988;18:231-234.
34. Gustafson P. Soft tissue sarcoma: epidemiology and prognosis in 508 patients. Acta Orthop Scand Suppl. 1994; 259:1–31.
35. Trassard M, Le Doussal V, Hacene H, et al. Prognostic factors in localized primary synovial sarcoma: A mulicenter study of 128 adult patients. J Clin Oncol. 2001;19: 525-534.
36. Vargas B, Gellman H. Synovial cell sarcoma treatment & management. Medscape.
Available:emedicine.medscape.com/article/1257131-treatment
(Up dated 2014 Nov 20).
37. Ladenstein R, Treuner J, Koscielniak E, d'Oleire F, Keim M, Gardner H, Jürgens H, Niethammer D, Ritter J, Schmidt D. Synovial sarcoma of childhood and adolescence. Report of the German CWS-81 study. Cancer. 1993;71(11):3647-3655.
38. Eilber FC, Dry SM. Diagnosis and management of synovial sarcoma. Journal of Surgical Oncology. 2008;18:97(4):314-320.
39. Spira AI, Ettinger DS. The use of chemotherapy in soft-tissue sarcomas Oncologist. 2002;7(4):348-359.
40. Siehl JM, Thiel E, Schmittel A, Hutter G, Deckert PM, Szelényi A, Keilholz U. Ifosfamide/liposomal daunorubicin is a well-tolerated and active first-line chemotherapy regimen in advanced soft tissue sarcoma: Results of a phase II study. Cancer. 2005;104(3):611–617.
41. Fukukawa C, Hanaoka H, Nagayama S, Tsunoda T, Toguchida J, Endo K, Nakamura Y, Katagiri T. Radioimmuno-therapy of human synovial sarcoma using a monoclonal antibody against FZD10. Cancer Sci. 2008;99(2):432-440.
42. Kawaguchi S, Wada T, Ida K, Sato Y, Nagoya S, Tsukahara T, Kimura S, Sahara H, Ikeda H, Shimozawa K, Asamuma H, Torigoe T, Hiraga H, Ishii T, Tatezaki S,

Sato N, Yamashita T. Phase I vaccination trial of SYT-SSX junction peptide in patients with disseminated synovial sarcoma. J Transl Med. 2005;3(1):1. DOI: 10.1186/1479-58676-3-1.

43. Terry J, Saito T, Subramanian S, Ruttan C, Antonescu CR, Goldblum JR, Downs-Kelly E, Corless CL, Rubin BP, van de rijn M, Ladanyi M, Nielsen TO. TLE1 as a diagnostic immunohistochemical marker for synovial sarcoma emerging from gene expression profiling studies Am. J Surg Pathol. 2007;31(2):240-246.