UNDER PEER REVIEW

Original Research Article

Neoadjuvant chemoradiotherapy and chemotherapy in locally advanced rectal cancer

Abstract:

Aims: Evaluate the role of neoadjuvant chemoradiotherapy (CRT) followed by an additional cycle of chemotherapy and total mesorectal excision (TME) in patients with locally advanced rectal cancer on the rate of patholocgic complete response (pCR) and tumor downstaging, their impact on survival and evaluation of treatment related toxicity and surgical complications.

Patients and methods: This prospective phase II trial included 73 patients with histologically proven non metastatic rectal adenocarcinoma. Radiotherapy (1.8 Gy, 5 days a week over 5 weeks, total dose 50.4 Gy, 3D conformational technique) was given in combination with intravenous oxaliplatin 50 mg/m2 once weekly for 5 weeks and oral capecitabine 825 mg/m2 twice daily on each day of radiation. After completion of CRT, patients received an additional cycle of chemotherapy consisted of oxaliplatin (130 mg/m2 on day 1) and capecitabine (825 mg/m2, twice per day from day 1 to day 14) for 21 days. Surgery was performed 6–8 weeks after completion of chemoradiotherapy.

Results: Seventy patients (95.9%) underwent surgery. Postoperative pathologic assessment showed an overall downstaging rate of 78.1%, while 16 patients (21.9%) had stationary disease. Complete pathologic response was achieved in 11 patients (15.1%). No tumor progression has been observed. After median follow up period of 26 months (7-30 months), the 2-year overall survival (OS) was 88%, recurrence free survival was 88.7% and distant metastasis free survival was 93.9%. Lower pathologic tumor stage was significantly associated with better OS (P = .002) and recurrence-free survival (P = .001), while pathologic nodal stage and TRG had no significant difference in overall survival, recurrence

UNDER PEER REVIEW

free survival or distant metastasis free survival. Fourteen patients (56.2%) experienced grade 1-2 toxicity and 5 patients (6.8%) experienced grade 3 toxicity.

Conclusion: Neoadjuvant CRT and one cycle of chemotherapy followed by TME is effective with pCR of 15.1% and overall downstaging rate of 78.1%. In addition to favorable toxicity profile and outcome.

Key words: capecitabine, oxaliplatin, neoadjuvant, radiotherapy, rectal cancer

1.Introduction:

Local recurrence and distant metastasis are serious problems in locally advanced rectal cancer (LARC). The local recurrence rate with conventional surgery alone was 20–45% and to <10% by total mesorectal excision (TME) [1,2]. The high local recurrence rate after surgical resection, necessitate multimodal management of surgery, chemotherapy and radiotherapy to achieve the optimal outcome [3]. The aims of preoperative treatment in LARC are improvement of survival, reduce local recurrence and increase sphincter saving surgery [4–7]. Efforts to improve such results have focused on preoperative combined chemothoradiotherapy (CRT) treatment regimens [8–10]. Several trials have also explored the role of induction of oxaliplatin and capecitabine before CRT aiming at reducing the rate of distant metastasis [11-13].

The advances in preoperative therapies have led to the need for an accurate preoperative staging technique to select those patients who are most likely to benefit from these interventions without subjecting others to unnecessary treatment. Magnetic resonance imaging (MRI) scans are the gold standard for assessing the involvement of mesorectal fascia by tumor. Patients with involovement of mesorectal fascia by tumor, have high risk of positive circumferential margin (CRM) and require downstaging before surgery.

UNDER PEER REVIEW

In our study we evaluated the role of neoadjuvant CRT (capecitabine and oxaliplatin) followed by an additional cycle of chemotherapy and TME in subgroup of patients with locally advanced rectal cancer on the rate of patholocgic complete response (pCR) and tumor downstaging, their impact on survival and evaluation of treatment related toxicity and surgical complications.

2. Patients and methods:

This prospective phase II trial included all new cases with locally advanced rectal cancer referred from or admitted at Surgical Oncology Department, Radiotherapy Department, South Egypt Cancer Institute, and Clinical Oncology Department, Assiut University, Egypt from March 2012 to September 2013.

Pre-therapeutic evaluations included a complete history and physical examination, digital rectal examination, complete blood count, liver and renal function, proctosigmoidoscopy with biopsy, colonoscopy, contrast-enhanced pelvic MRI and endorectal ultrasound before treatment and after chemoradiotherapy, computed tomography (CT) of the chest and abdomen.

All patients enrolled in the study were newly diagnosed and histologically proven T3/4, and N- / N+ non metastatic rectal adenocarcinoma according to the criteria of the 7th edition of the AJCC Cancer Staging Manual [14]. Inclusion criteria were: on MRI, patients had T3/4, and N- / N+, age >18 years, Eastern Cooperative Oncology Group (ECOG) performance status ≤ 2 and adequate liver, renal and hematological functions (granulocytes >1500/mm^3, platelets >100 000/mm^3, bilirubin ≤ 1 upper limit of normal, aspartate aminotransferase/alanine aminotransferase ≤ 2.5 ULN, creatinine ≤ 1.5 mg/dl or creatinine clearance at least 60 ml/min). Patients with history of previous malignancy, previous treatment with chemotherapy or radiotherapy, major organ dysfunction, pregnancy or breast-feeding were excluded from enrollment in the trial.

UNDER PEER REVIEW

Informed consent was taken from the patients and the study was approved by the institutional ethics committee.

2.1 Preoperative combined chemoradiation

2.1.1 Radiotherapy:

Conformal three dimentional radiotherapy was used for all patients based on a contrast CT scan of the pelvis.

2.1.1.1 Target volume: included the rectum, mesorectum and the draining lymph node chains (pararectal, hypogastric, presacral lymph nodes). CT was performed in the treatment position, with 5-mm thick slices and a 5-mm spacing between images. Gross tumor volume encompassing the tumor and involved pelvic lymph nodes. After careful review with the radiologist and surgeon, the clinical target volume (CTV) was delineated. The CTV encompassing the entire rectum, mesorectum, pararectal nodes, the presacral and promontory nodes (limit S1/S2), and the internal iliac nodes up to the venous bifurcation. The planning target volume was an expansion of the CTV (10 mm). Organs at risk were also contoured: bladder and femoral heads.

2.1.1.2 Field arrangement: Three field techniques were used (one posterior and two opposing wedged lateral fields) to give a homogeneous distribution to the target volume.

2.1.1.3 Dose and energy: All patients were treated by a photon beam of either 6 or 15 MeV. The total dose of 50.4 Gy (pelvis dose of 45 Gy/25 fractions and 5.4 Gy/3 fractions boosted to the primary tumor plus 2 cm margin) was prescribed at the isocenter of the plan according to ICRU report No. 50.

2.1.2 Chemotherapy:

Capecitabine was administered at 825 mg/m$^{(2)}$ twice daily for 5 days/week and oxaliplatin at 50 mg/m$^{(2)}$ on day 1 weekly for 5 weeks starting the first day of RT (before RT). After completion of CRT, patients received an additional cycle of chemotherapy consisted of

UNDER PEER REVIEW

oxaliplatin (130 mg/m2 on day 1) and capecitabine (825 mg/m2, twice per day from day 1 to day 14) for 21 days.

2.2 Toxicity :

Clinical examination and laboratory tests (including renal, liver and hematological evaluations) were performed weekly during chemoradiation using National Cancer Institute Common Toxicity Criteria CTCAE, v 3.0 [16]. A 25% dose reduction of chemotherapy was planned in case of grade 3 or 4 toxicity.

2.3 Surgery:

TME (R0 resection) was performed 6-8 weeks after the completion of chemoradiation. TME involves en-bloc resection of the rectum, perirectal fat and lymphoid tissue.

Evaluation of tumor and nodal downstaging was done through comparison between baseline MRI and histopathological specimen; the absence of tumor cells in the resected specimen and lymph nodes was defined as (pCR). Tumor regression grade (TRG) was quantified according to a five-point scale of Dworak et al. [15]: TRG 0: no regression; TRG 1: dominant tumor mass with obvious fibrosis and/or vasculopathy; TRG 2: dominantly fibrotic changes with few tumor cells or groups (easy to find); TRG 3: very few (difficult to find microscopically) tumor cells in fibrotic tissue with or without mucous substance; TRG 4: no tumor cells, only a fibrotic mass (total regression or response). Adjuvant chemotherapy was recommended for patients with T3/ T4 or positive nodes at pathologic examination.

2.4 Statistical analysis:

Recurrence-free survival time was defined as the date of entry to the date of recurrence. Overall survival time was defined as the date of entry to the date of death from any cause. Patients who did not experience recurrence, metastasis, or death at the time of the analysis were censored. Recurrence-free survival, metastasis free survival and overall survival were

UNDER PEER REVIEW

126 calculated by the Kaplan-Meier method [17] and the differences between the survival
127 curves were determined by the log-rank test. The p-values were double-sided with $p < 0.05$
128 considered statistically significant. All analyses were performed using the Statistical
129 package for Social Sciences software (version 18.0, SPSS, Chicago, IL).

130 **3. Results:**

131 *3.1 Patient characteristics*

132 From March 2012 to September 2013, 73 patients were included onto the study. Patients
133 and tumor characteristics are summarized in table 1. Median age was 56 years (range 34–
134 68). The majority (60.3%) of the tumors were located in the middle rectum. Eighteen
135 patients (24.7%) presented with T4N+ve disease where inoperable due to infiltration of
136 vagina (5 patients), sacrum (3 patients) and bladder neck (10 patients).

137 *3.2 Toxcicity:*

138 Toxic effects during neoadjuvant chemoradiotherapy and chemotherapy are listed in table
139 2. Forty one patients (56.2%) experienced grade 1-2 toxicity and 5 patients (6.8%)
140 experienced grade 3 toxicity. The most common adverse events were grade 1-2 neuropathy
141 and diarrhea which were experienced in 26 patients (35.5%) and 21 patients (28.8%)
142 respectively. Three patients developed grade 3 diarrhea and 2 patients developed grade 3
143 hematological toxicity (leukopenia and neutropenia) which required delay in the treatment.
144 No treatment related deaths occurred.

145 *3.3 Surgery:*

146 Six to 8 weeks after surgical exploration, 42 patients (57.5%); underwent low anterior
147 resection (using handsewn technique in 30 patients and staplers in 11 patients due to short
148 distal segment in 8 patients with lesions < 5cm from anal verge and narrow pelvis in 3
149 patients with lesions located >5 cm from anal verge) and 28 patients (38.4%) underwent
150 abdominoperineal resection. The circumferential resection margin was free in all cases.

UNDER PEER REVIEW

Three patients (4.1%) remained inoperable due to sacral infiltration. In those patients with unresectable rectal cancer during surgical exploration, palliative colostomy was done and biopsies from primary tumor and perirectal lymph nodes were taken. The postoperative 30 days mortality was not observed. Postoperative complications were in the form of chest infection (one out of 70 patients; 1.4%) and was treated with antibiotics, acute urinary infection (2 out of 70 patients; 2.9%) and were treated conservatively and anastomotic leakage (one out of 70 patients; 1.4%) which healed conservatively.

3.4 Pathologic response and downstaging:

Comparison of pre-CRT MRI scans with histology of the resected specimen showed an overall downstaging rate of 78.1% (57 out of 73 patients), while 16 patients (21.9%) had stationary disease. Complete pathologic response was achieved in 11 patients (15.1%). No tumor progression has been observed (Table 3). In subgroup of patients with unresectable rectal cancer (15 out of 18 patients) became resectable. Sphincter preservation rate was achieved in the majority of patients whose tumor were located > 5 cm from the anal verge (34 out of 51 patients; 66.7%) and in 8 out of 22 patients (36.4%) with tumor < 5cm from the anal verge. According to the Dworak classification, the majority of the patients (41 patients; 56.2%) were classified as TRG 3 (Table 4).

Table 1. Patients and tumor characteristics:

Variable	Number	Percent
Age (years)		
Median	56	
Range	34-68	
Sex		
Male	51	69.9
Female	22	30.1

UNDER PEER REVIEW

Performance status		
0	58	79.5
1	15	20.5
Location of the tumor		
0- < 5	22	30.1
5- < 10	44	60.3
10 – 15	7	9.6
Clinical stage (MRI)		
T3N0	9	12.3
T3N+ve	25	34.2
T4N0	21	28.8
T4N+ve	18	24.7

Abbreviations: MRI, magnetic resonance imaging. +ve, positive

Table 2. Toxicity of neoadjuvant chemoradiation and chemotherapy

Toxicity	Grade 1	Grade 2	Grade 3	Grade 4
	No (%)	No (%)	No (%)	No (%)
Diarrhea	12 (16.4)	9 (12.3)	3 (4.1)	0
Nausea	9 (12.3)	8 (11)	0	0
Vomiting	7 (9.6)	9 (12.3)	0	0
Stomatitis	6 (8.2)	0	0	0
Liver	11 (15.1)	5 (6.8)	0	0
Urinary	7 (9.6)	2 (2.7)	0	0
Neuropathy	23 (31.5)	3 (4.1)	0	0

UNDER PEER REVIEW

Anemia	10 (13.7)	7 (9.6)	0	0
Neutropenia	7 (9.6)	3 (4.1)	1 (1.4)	0
Thrombocytopenia	6 (8.2)	5 (6.8)	0	0
Leukopenia	7 (9.6)	3 (4.1)	1 (1.4)	0
Handfoot syndrome	1 (1.4)	0	0	0

Table 3. Postchemoradiotherapy pathologic staging compared with initial MRI staging:

Initial MRI Staging	Postchemoradiotherapy (py) pathologic staging													
	Yp T0N0	Yp T1N0	Yp T1N1	Yp T1N2	Yp T2N0	Yp T2N1	Yp T2N2	Yp T3N0	yp T3N1	Yp T3N2	Yp T4N0	yp T4N1	yp T4N2	Total (%)
T3N0	8	1	0	0	0	0	0	0	0	0	0	0	0	9(12.3)
T3N+ve	3	8	5	2	0	1	0	0	5	1	0	0	0	25(34.2)
T4N0	0	0	0	0	9	4	1	0	0	0	7	0	0	21(28.8)
T4N+ve	0	0	0	0	0	0	0	6	4	5	0	3	0	18(24.7)
Total	11 (15.1)	9 (12.3)	5 (6.8)	2 (2.7)	9 (12.3)	5 (6.8)	1 (1.4)	6 (8.2)	9 (12.3)	6 (8.2)	7 (9.6)	3 (4.1)	0	73 (100)

Abbreviation: MRI, magnetic resonance imaging. +ve, means positive

Table 4. Postchemoradiotherapy pathologic staging compared with TRG

TRG	Postchemoradiotherapy pathologic (yp) tumor staging					
	ypT0	ypT1	ypT2	ypT3	ypT4	Total (%)
1	0	2	0	1	6	9 (12.3)
2	0	1	3	7	4	15 (20.5)
3	4	13	12	12	0	41 (56.2)

UNDER PEER REVIEW

4	7	0	0	1	0	8 (11)
Total	11	16	15	21	10	73 (100)

Abbreviation: TRG, Tumor regression grade.

3.5 Pattern of treatment failure:

After median follow up time of 26 months (range, 7-30), 6 patients (8.2%) had local recurrence and 3 patients (4.1%) had distant recurrence to the liver (2 patients) and peritoneal cavity (1 patient).

3.6 Survival:

After median follow up period of 26 months (7-30 months), the 2-year OS was 88%, recurrence free survival was 88.7% and metastasis free survival was 93.9%. Lower pathologic tumor stage was significantly associated with better OS (P = .002) and recurrence-free survival (P = .001), but no significant difference in metastasis-free survival (P = .314). In contrast pathologic nodal stage and TRG had no significant difference in OS,

UNDER PEER REVIEW

189 recurrence free survival or metastasis free survival.

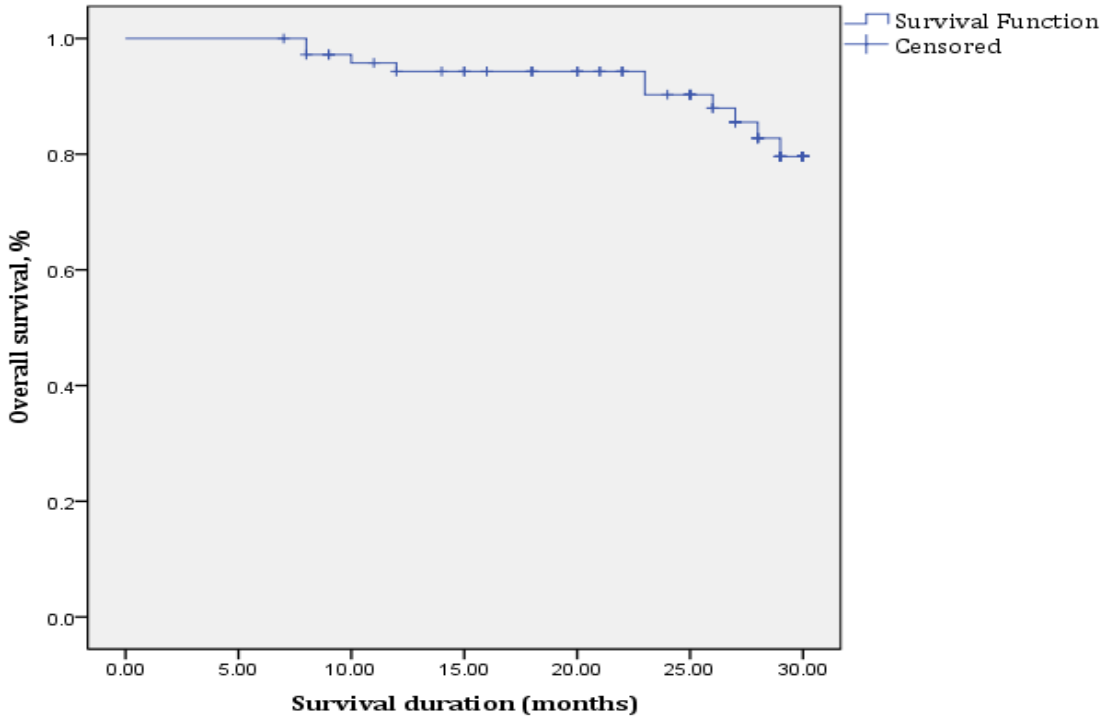

190

191 **Figure 1. Overall survival for 73 Patients with locally advanced rectal cancer.**

192 Kaplan- Meir analaysis illustrated 2-year overall survival of 88%.

193

UNDER PEER REVIEW

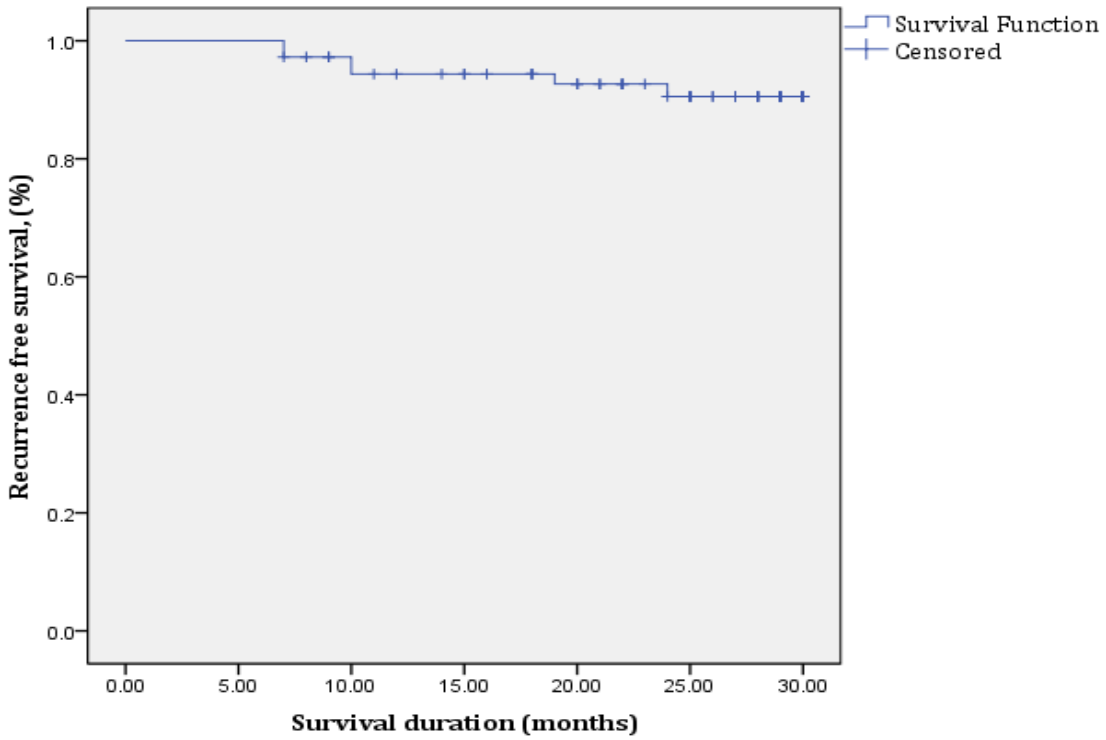

194

195 **Figure 2. Recurrence free survival for 73 Patients with locally advanced rectal cancer.**

196 Kaplan- Meir analaysis illustrated 2-year recurrence free survival of 88.7%.

UNDER PEER REVIEW

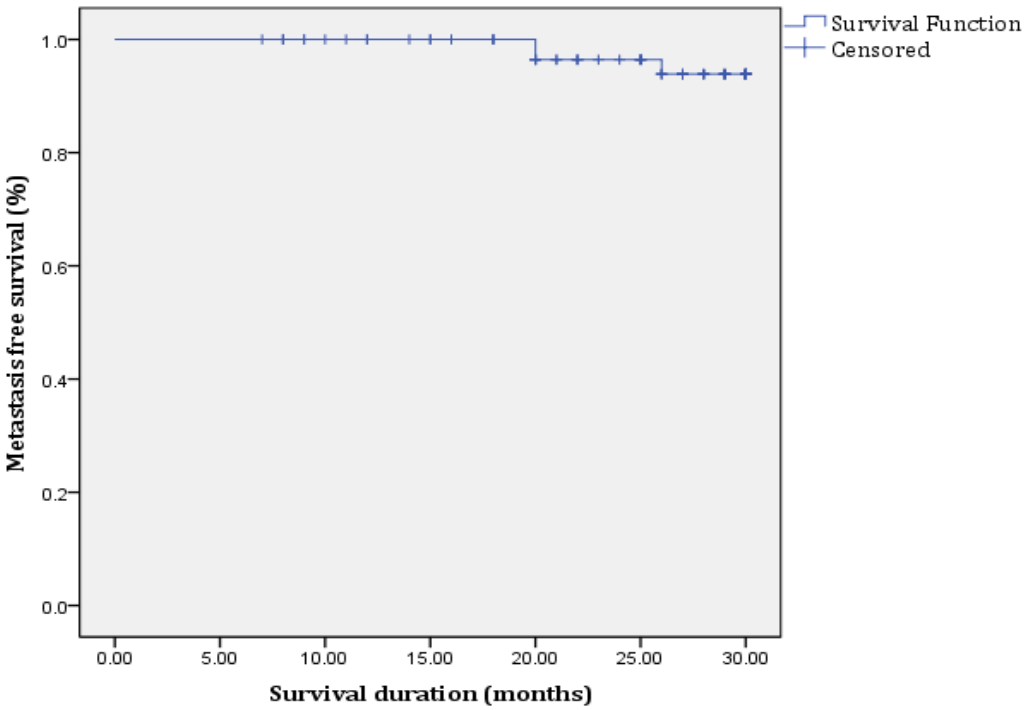

Figure 3. Metastasis free survival for 73 Patients with locally advanced rectal cancer.

Kaplan- Meir analaysis illustrated 2-year metastasis free survival of 93.9%.

UNDER PEER REVIEW

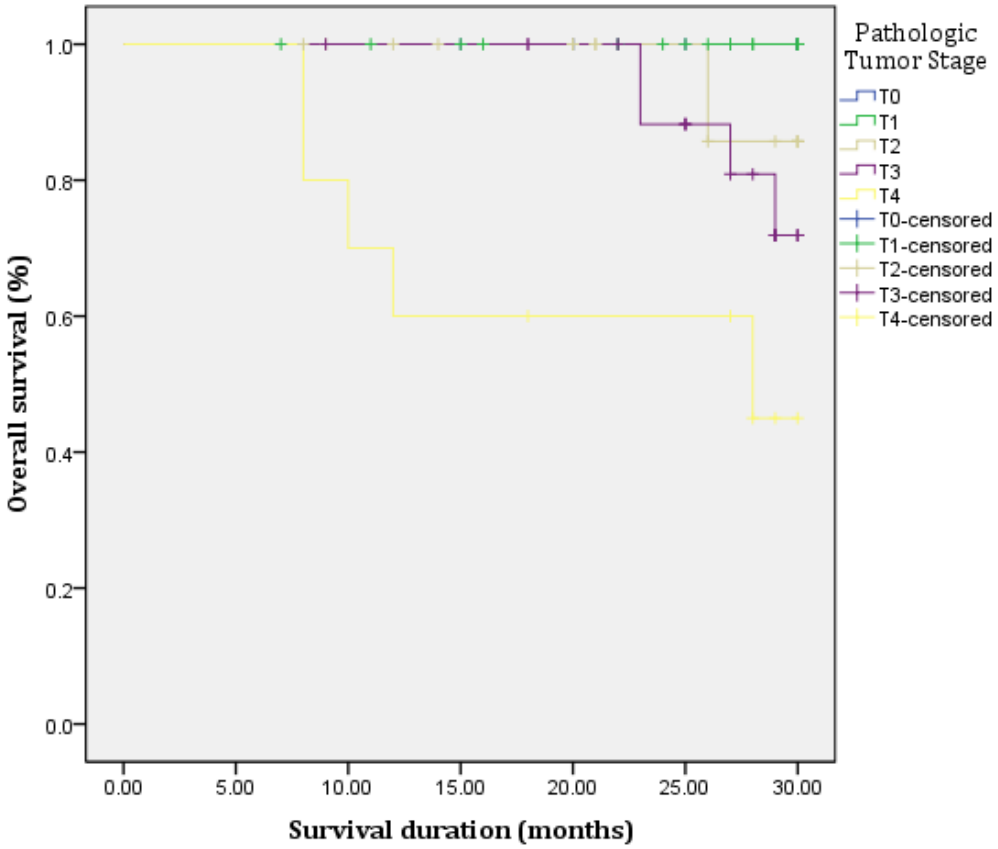

Figure 4. Survival analysis for overall survival with different pathologic tumor stage. Log rank test for overall survival illustrated, significant difference between pathologic tumor stage (P = .002).

UNDER PEER REVIEW

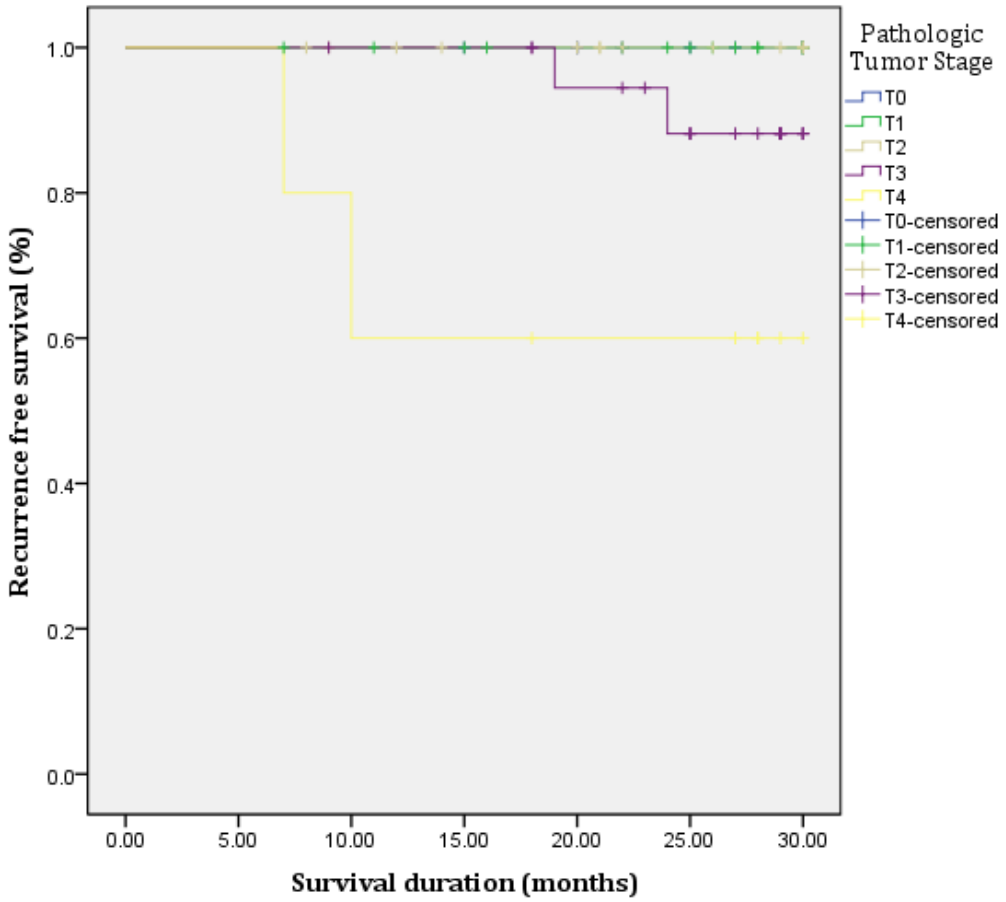

Figure 5. Survival analysis for recurrence free survival with different pathologic tumor stage.

Log rank test for recurrence free survival illustrated, significant difference between Pathologic tumor stage (P = .001).

4. Discussion:

Several phase I and II studies have evaluated oxaliplatin, FU/LV, and capecitabine in rectal cancer, with pCR rates of 15% to 28% [18-30]. These results were promising compared to what was reported by German [31] and Fédération Francophone de Cancérologie Digestive studies [32]; preoperative FU-based CRT resulted in pCR rates of 8% and 11.7% respectively. Therefore, in our current protocol, we used oxaliplatin and capecitabine during CRT plus an additional cycle of oxaliplatin and capecitabine with implementation of

UNDER PEER REVIEW

this preoperative treatment strategy based of MRI assessment for comparison between clinical and pathological down staging of the tumor and lymph nodes and on the potential resection margin.

In our study, the overall pathological downstaging rate was 78.1% (57 out of 73 patients) with pathologically determined complete response rate of 15.1% (ypT0No). Our result is comparable to Garcia-Aguilar et al. [33] who reported pCR rate of 17% after CRT plus 2 cycles of chemotherapy (5-FU + leucovorin + oxaliplatin). However, Xu et al. reported higher rate of pCR (19%) and downstaging rate of 54% after CRT (Capecitbine + Oxaliplatin + radiation) plus one additional cycle of chemotherapy (Capecitabine + Oxaliplatin). This is might probably due to inclusion of patients with lower stage (T1/T2) disease. Caravatta et al. [34] reported higher rate of pCR (32%) and a tumor down-staging rate of 76% in patients with T3/T4 and/or N≥1 rectal cancer. This might attributed to inclusion of radiotherapy boost (55 Gy/5 weeks) plus concurrent chemotherapy (raltitrexed + oxaliplatin). In our study, the pCR and the overall pathological downstaging rate was better than the study reported by Hosper et al., (pCR of 10% and downstaging to T0/T2: 33%) [35] and another study reported by Machiels et al., (pCR of 14% and downstaging rate of 53%) [36]. The previous 2 study used neoadjuvant CRT (capecitabine plus oxaliplatin). This is might be due to the addition one cycle of chemotherapy (oxaliplatin + capecitabine) after CRT in our study.

After median follow up of 26 months, our study reported high rate of local relapse (n=6, 8.2%) compared to other studies [34,36,37]. The lower rates in the current study than that in the reported studies, may be due to higher radiotherapy dose (55 Gy/5 weeks) [34], the more favorable distribution of T stage [36,37] and limited follow up period as in the study reported by Machiels et al. In this study there was no local recurrence and only 2 patients had distant metastasis [36]. Furthermore, in our study, 70% of patients with T3 tumors had

UNDER PEER REVIEW

tumors that extended more than 5 mm beyond the muscularis propria on diagnotic MRI which were shown to have a significantly higher locoregional recurrence rate and poorer 5-year cancer-specific survival [38]. We only had 3 patients with distant metastasis after median follow up period of 26 months. Xu et al., reported that 13 patients developed distant metastasis (7 cases in lung, 2 cases in liver, 2 cases in lung and liver, 1 case in brain, 1 case in bone marrow), and 8 patients died of rectal cancer [37]. The higher rate of distant metastasis in the reported study than that of our study due to longer follow up period (3 years). Chu et al., reported that 2 patients had local recurrence and 9 patients had distant metastasis after median follow up time of 23 months [12].

In our study, the 2-year overall survival was 88%, recurrence free survival was 88.7% and distant metastasis free survival was 93.9%. Our results were close to the results from Xu et al.; the 2-year metastasis-free survival and overall survival were about 96.3%, 85% and 89% respectively. However he reported higher rate of recurrence free survival (96.3%), this is might probably due to inclusion of patients with lower T stage (T1 and T2) [37]. The 2-year OS reported by our study was comparable to that reported by Chau et al., (89%) however, he reported 2–year failure free survival rates of about 69% [12]. Our results (CRT plus one cycle of chemotherapy) yielded comparable survival to the addition of 2 or 3 cycles of chemotherapy which were administered in this trial [12].

Maas et al., analysed 3105 patients with rectal cancer from 14 study datasets to explore the impact of pCR after CRT on the outcome. They reported better outcome and 5-year crude DFS of 83.3% in patients with pCR [39]. In our study, none of the 11 patients with pCR had local recurrence or distant metasatsis with 100% OS rates during follow up period and there was significant difference in tumor stage before treatment and after surgery (P <0.0001). Belluco et al., found that, patients with pCR had significantly better 5-year overall survival, disease specific survival, disease-free survival, metastasis-free survival, and local

UNDER PEER REVIEW

recurrence-free survival following neoadjuvant CRT for T3 rectal cancer [40]. In contrast, Xu et al., reported similar overall survival, recurrence free survival and distant metastasis-free survival of those patients who achieved pCR and those who did not [37].

We reported that lower T stage was significantly associated with better OS and recurrence free survival, although T stage had no effect on metastasis-free survival. Nodal stage and TRG, had no effect on OS, recurrence free survival and metastasis-free survival. In patients with T3 or T4 rectal tumors, Schou et al., reported that TRG grade was not associated with overall survival or disease-free survival after induction chemotherapy (capecitabine + oxaliplatin) followed by CRT and TME [41] . Yu et al., studied the effect of local excision after neoadjuvant CRT in patients with T3N0M0 or T2N0M0 rectal cancer. They reported no effect of T stage on disease-free survival and a marginally significant effect on the response to CRT on survival [42]. Xu et al., studied the effect of neoadjuvant CRT followed by additional cycle of chemotherapy (capecitabine + oxaliplatin); they reported lower nodal stage was significantly associated with better recurrence free survival but no effect on overall survival or distant metastasis free survival [37]. Tumor stage and TRG had no effect on overall survival, recurrence free survival or metastasis-free survival. Schou et al., reported that patients with positive lymph nodes have worse prognosis than patients without malignant lymph node involvement [41]. Klos et al., fount that, the presence of malignant lymph nodes has been associated with shorter OS and time to local recurrence in patients receiving neoadjuvant CRT [43].

Our study reported lower toxicity rates in contrast to other studies using induction chemotherapy prior to CRT [12,41]. For example, Chau et al., reported clinically significant occurrence of cardiac/thromboembolic toxicity during neoadjuvant oxaliplatin/capecitabine, which led to three mortalities and four deaths occurred during neoadjuvant chemotherapy [12]. Schou et al., reported higher grade 3 and 4 toxic effects

UNDER PEER REVIEW

during induction chemotherapy (18%) and chemoradiation (11%) [41]. Caravatta et al., reported higher rate of Grade 1 – 2 diarrhea and proctitis (n _ 18; 72%) and grade 3 gastrointestinal toxicity in two patients (8%) were recorded. Overall, grade 3 and 4 toxicity were observed in 28% of patients [34]. This is most probably due to chemotherapy combination (raltitrexed + oxaliplatin) used in the study and high radiation dose (55 Gy/5 weeks).

5. Conclusion:

Neoadjuvant CRT and one cycle of chemotherapy followed by TME is effective with pCR of 15.1% and overall downstaging rate of 78.1%. In addition to favorable toxicity profile (as we used a weekly schedule of oxaliplatin) which has been reported by our study in contrast to several studies using induction chemotherapy prior to CRT. Furthermore, our preliminary survival data were encouraging, although further follow-up would be required. Therefore, preoperative CRT followed by one cycle of chemotherapy (capecitabine plus oxaliplatin) may be applied to patients with locally advanced rectal cancer for downstaging and facilitate sphincter preservative surgery. In view of these promising results, randomized phase III trials will be necessary to prove these promising results and its impact on long-term survival.

CONSENT

Written informed concent was obtained from all patients included in this study.

ETHICAL APPROVAL

The study was approved by the institutional ethics committee.

References:

1. Dahlberg M, Glimelius B, Pahlman L. Changing strategy for rectal cancer is associated with improved outcome. Br J Surg. 1999;86(3):379–84.

UNDER PEER REVIEW

2. McFarlane JK, Ryall RP, Heald RJ. Mesorectal excision for rectal cancer. Lancet 1993;341(8843):457–60.

3. Sebag-Montefiore D, Bujko K, Valentini Vl. Rectal cancer multidisciplinary management: evidences and future landscape. Radiother Oncol. 2009;92(2):45–47.

4. Kapiteijn E, Marijnen CA, Nagtegaal ID, Putter H, Steup WH, Wiggers T, et al. Dutch Colorectal Cancer Group. Preoperative radiotherapy combined with total mesorectal excision for resectable rectal cancer. N Engl J Med. 2001;345(9):638–46.

5. Swedish rectal cancer trial: improved survival with preoperative radiotherapy in respectable rectal cancer. N Engl J Med. 1997;336(14):980–7.

6. Folkesson J, Birgisson H, Pahlman L, Cedermark B, Glimelius B, Gunnarsson U. Swedish rectal cancer trail: long lasting benefits from radiotherapy on survival and local recurrence rate. J Clin Oncol. 2005;23(24):5644–50.

7. Gerard JP. Radiotherapy in the conservative treatment of rectal cancer. Evidence-based medicine and opinion. Radiother Oncol. 2005;74(3):227–33.

8. Giralt J, Tabernero J, Navalpotro B, Capdevila J, Espin E, Casado E, et al. Pre-operative chemotherapy with UFT and leucovorin in patients with advanced rectal cancer: a phase II study. Radiother Oncol. 2009;89(3):263–9.

9. Klautke G, Küchenmeister U, Foitzik T, Ludwig K, Semrau S, Prall F, et al. Intensified irinotecan-based neoadjuvant chemoradiotherapy in rectal cancer: four consecutive designed studies to minimize acute toxicity and optimize efficacy measured by pathologic complete response. Radiother Oncol. 2007;85(3):379–84.

UNDER PEER REVIEW

10. Debucquoy A, Roels S, Goethals L, Libbrecht L, Van Cutsem E, Geboes K, et al. Double blind randomized phase II study with radiation + 5-fluorouracil ± celecoxib for resectable rectal cancer. Radiother Oncol. 2009;93(2):273–78.

11. Chua YJ, Barbachano Y, Cunningham D, Oates JR, Brown G, Wotherspoon A, et al. Neoadjuvant capecitabine and oxaliplatin before chemoradiotherapy and total mesorectal excision in MRI defined poor-risk rectal cancer: a phase 2 trial. Lancet Oncol. 2010; 11(3):241–48.

12. Chau I, Brown G, Cunningham D, Tait D, Wotherspoon A, Norman AR, et al. Neoadjuvant capecitabine and oxaliplatin followed by synchronous chemoradiation and total mesorectal excision in magnetic resonance imaging-defined poor-risk rectal cancer. J Clin Oncol. 2006;24(4):668-74.

13. Calvo FA, Serrano FJ, Diaz-González JA, Gomez-Espi M, Lozano E, Garcia R, de la Mata D, et al. Improved incidence of pT0 downstaged surgical specimens in locally advanced rectal cancer (LARC) treated with induction oxaliplatin plus 5-fluorouracil and preoperative chemoradiation. Ann Oncol. 2006; 17(7):1103–1110.

14. Greene FL, Page DL, Fleming ID, Fritz A, Balch CM, Haller DG, Morrow M (Eds): AJCC Cancer Staging Manual (6th edition). American Joint Committee on Cancer, New York, 2002.

15. Colevas AD, Setser A. The NCI Common Terminology Criteria for Adverse Events (CTCAE) v 3.0 is the new standard for oncology clinical trials. J Clin Oncol 2004;ASCO Annual Meeting Proceedings (Post-Meeting Edition)14S: 6098.

16. Dworak O, Keilholz L, Hoffmann A. Pathological features of rectal cancer after preoperative radiochemotherapy. Int J Colorectal Dis 1997;12(1):19–23.

UNDER PEER REVIEW

371 17. Kaplan EL, Meier P. Nonparametric estimation from incomplete observations.
372 Journal of the American Statistical Association. 1958;53(282):457-81.
373 18. Aschele C, Friso ML, Pucciarelli S, Lonardi S, Sartor L, Fabris G, et al: A phase I-II
374 study of weekly oxaliplatin, 5-fluorouracil continuous infusion and preoperative
375 radiotherapy in locally advanced rectal cancer. Ann Oncol. 2005;16(7):1140-
376 1146.
377 19. Gérard JP, Chapet O, Nemoz C, Romestaing P, Mornex F, Coquard R, et al:
378 Preoperative concurrent chemoradiotherapy in locally advanced rectal cancer
379 with high-dose radiation and oxaliplatin-containing regimen: The Lyon R0-04
380 phase II trial. J Clin Oncol. 2003;21(6):1119-124.
381 20. Glynne-Jones R, Sebag-Montefiore D, Samuel L, Falk S, Maughan T, McDonald A.
382 Socrates phase II study results: Capecitabine (CAP) combined with oxaliplatin
383 (OX) and preoperative radiation (RT) in patients (pts) with locally advanced
384 rectal cancer (LARC). J Clin Oncol. 2005; 23:252s.(suppl; abstr 3527
385 21. Rödel C, Grabenbauer GG, Papadopoulos T, Hohenberger W, Schmoll HJ, Sauer
386 R.Rodel C, et al: Phase I/II trial of capecitabine, oxaliplatin, and radiation for
387 rectal cancer. J Clin Oncol. 2003;21(16):3098-104.
388 22. Carraro S, Roca EL, Cartelli C, Rafailovici L, Castillo Odena S, Wasserman E, et al:
389 Radiochemotherapy with short daily infusion of low-dose oxaliplatin,
390 leucovorin, and 5-FU in T3–T4 unresectable rectal cancer: A phase II IATTGI
391 study. Int J Radiat Oncol Biol Phys. 2002;54(2):397-402.
392 23. Dunst J, Reese T, Sutter T, Zühlke H, Hinke A, Kölling-Schlebusch K, et al: Phase I
393 trial evaluating the concurrent combination of radiotherapy and capecitabine in
394 rectal cancer. J Clin Oncol. 2002;20(19):3983-91.

UNDER PEER REVIEW

24. Dunst J, Reese T, Debus J, Hoelscher T, Budach W, Rudat V, et al: Phase-II study of preoperative chemoradiation with capecitabine in rectal cancer. J Clin Oncol. 2004;22:259s, (suppl; abstr 3559).

25. Freyer G, Bossard N, Romestaing P, Mornex F, Chapet O, Trillet-Lenoir V, et al. :Addition of oxaliplatin to continuous fluorouracil, L-folinic acid, and concomitant radiotherapy in rectal cancer: The Lyon R 97-03 phase I trial. J Clin Oncol. 2001; 19(9):2433-2438.

26. Kim JC, Kim TW, Kim JH, Yu CS, Kim HC, Chang HM, et al.: Preoperative concurrent radiotherapy with capecitabine before total mesorectal excision in locally advanced rectal cancer. Int J Radiat Oncol Biol Phys. 2005;63(2):346-353.

27. Kim JS, Kim JS, Cho MJ, Song KS, Yoon WH. Preoperative chemoradiation using oral capecitabine in locally advanced rectal cancer. Int J Radiat Oncol Biol Phys. 2002;54(2):403-408.

28. Loi S, Ngan SY, Hicks RJ, Mukesh B, Mitchell P, Michael M, et al.: Oxaliplatin combined with infusional 5-fluorouracil and concomitant radiotherapy in inoperable and metastatic rectal cancer: A phase I trial. Br J Cancer. 2005. 92(4):655-661.

29. Ngan SY, Michael M, Mackay J, McKendrick J, Leong T, Lim Joon D, et al: A phase I trial of preoperative radiotherapy and capecitabine for locally advanced, potentially resectable rectal cancer. Br J Cancer. 2004;91(6):1019-1024.

30. Reerink O, Mulder NH, Verschueren RC, Wiggers T, Szabo BG, Hospers GA. Addition of oxaliplatin to neo-adjuvant radiochemotherapy for irresectable rectal cancer, a phase I study. Anticancer Res. 2005;25(1B):629-633.

UNDER PEER REVIEW

418 31. Sauer R, Becker H, Hohenberger W, Rödel C, Wittekind C, Fietkau R, et al.:
419 Preoperative versus postoperative chemoradiotherapy for rectal cancer. N Engl J
420 Med. 2004;351(17):1731-1740.
421 32. Gerard JP, Bonnetain F, Conroy T, Chapet O, Bouche O, M.-T. Closon-Dejardin M.-
422 T, et al.: Preoperative (preop) radiotherapy (RT) {+/-} 5 FU/folinic acid (FA) in
423 T3-4 rectal cancers: Results of the FFCD 9203 randomized trial. J Clin Oncol.
424 2005;23:(16)247s, (suppl; abstr 3504).
425 33. Garcia-Aguilar J, Smith DD, Avila K, Bergsland EK, Chu P, Krieg RM. Timing of
426 Rectal Cancer Response to Chemoradiation Consortium: Optimal timing of
427 surgery after chemoradiation for advanced rectal cancer: preliminary results of
428 a multicenter, nonrandomized phase II prospective trial. Ann Surg.
429 2011;254(1):97-102.
430 34. Caravatta L, Padula GD, Picardi V, Macchia G, Deodato F, Massaccesi M, et al.:
431 Concomitant boost radiotherapy and multidrug chemotherapy in the
432 neoadjuvant treatment of locally advanced rectal cancer: results of a phase II
433 study. Acta Oncol. 2011;50(8):1151-57.
434 35. Hospers GA, Punt CJA, Tesselaar ME, Cats A, Havenga K, Leer JW, et al.:
435 Preoperative chemoradiotherapy with capecitabine and oxaliplatin in locally
436 advanced rectal cancer. A Phase I-II multicenter study of the Dutch Colorectal
437 Cancer Group. Ann Surg Oncol. 2007;14(10):2773-79.
438 36. Machiels JP, Duck L, Honhon B, Coster B, Coche JC, Scalliet P, et al.: Phase II study
439 of preoperative oxaliplatin, capecitabine and external beam radiotherapy in
440 patients with rectal cancer: the RadiOxCape study. Ann Oncol. 2005;16(2):
441 1898-905.

UNDER PEER REVIEW

442 37. Xu BH, Chi P, Guo JH, Guan GX, Tang TL, Yang YH, et al.: Pilot study of intense
443 neoadjuvant chemoradiotherapy for locally advanced rectal cancer:
444 retrospective review of a phase II study. Tumori. 2014;100(2):149-57.
445 38. Merkel S, Mansmann U, Siassi M, Papadopoulos T, Hohenberger W, Hermanek
446 P.Merkel S, et al.: The prognostic inhomogeneity in pT3 rectal carcinomas. Int J
447 Colorectal Dis. 2001;16(5):298-304.
448 39. Maas M, Nelemans PJ, Valentini V, Das P, Rödel C, Kuo LJ, et al.: Long-term
449 outcome in patients with a pathological complete response after chemoradiation
450 for rectal cancer: a pooled analysis of individual patient data. Lancet Oncol.
451 2010; 11(9):835–844.
452 40. Belluco C, De Paoli A, Canzonieri V, Sigon R, Fornasarig , Buonadonna A,et al.:
453 Long-term outcome of patients with complete pathologic response after
454 neoadjuvant chemoradiation for cT3 rectal cancer: implications for local
455 excision surgical strategies. Ann Surg Oncol. 2011;18(13):3686-3693.
456 41. Schou JV, Larsen FO, Rasch L, Linnemann D, Langhoff J, Høgdall E,et al.:
457 Induction chemotherapy with capecitabine and oxaliplatin followed by
458 chemoradiotherapy before total mesorectal excision in patients with locally
459 advanced rectal cancer. Ann Oncol. 2012;23(10):2627-2633.
460 42. Yu CS, Yun HR, Shin EJ, Lee KY, Kim NK, Lim SB, et al.: Colorectal Cancer Study
461 Group, Korean Society of Coloproctology: Local excision after neoadjuvant
462 chemoradiation therapy in advanced rectal cancer: a national multicenter
463 analysis. Am J Surg. 2013;206(4):482-487.
464
465
466