

Amelogenesis Imperfecta– 3 Cases

M. Anitha^{1*}, CH. Uma Reddy¹, A. Feroz¹, L. Chandrashekar¹, R. Sudarshan¹
and BR. Sathvikalakshmi¹

¹Department of Oral Medicine & Radiology, Best Dental Science College, Madurai 625104, India.

Case Report

ABSTRACT

Amelogenesis imperfecta (AI) - a hereditary heterogenous disorder causing developmental alterations in the structure of enamel. The AI trait can be transmitted by either autosomal dominant, autosomal recessive, or X-linked modes of inheritance. Genes implicated in autosomal forms are genes encoding enamel matrix proteins, namely: Enamelin and Ameloblastin, Tuftelin, MMP-20 and Kallikrein – 4.[2] It is necessary to diagnose the case and provide durable functional and esthetic management of these patients, where the unaesthetic appearance has a definite negative psychological impact. We present here three case reports of AI that we diagnosed on the basis of clinical and radiographic features along with the complete review.

Keywords: amelogenesis, developmental disorder, enamel.

1. INTRODUCTION

Amelogenesis imperfecta (AI) (Amelogenesis – enamel formation; imperfecta – imperfecta) is a relatively rare group of inherited disorders characterized by abnormal enamel formation. [1, 22]

Tooth enamel is the most highly mineralized structure in the human body, with 85% of its volume occupied by hydroxyapatite crystals. The final composition of enamel is a reflection of the unique combined molecular and cellular activities taking place during the genesis. [2, 20] Deviation from this pattern may lead to Amelogenesis imperfecta. The abnormality can be related to autosomal or x-linked, dominant or recessive modes. The most common is autosomal dominant form. It is known that the gene

responsible to codify the most abundant protein of enamel, Amelogenin is related to occurrence of hypomineralised enamel. [3, 4] Non-enamel anomalies such as delayed eruption, crown resorption, congenitally missing teeth, pulpal calcifications, dental follicular hamartomas, and gingival hyperplasia had been found to be associated with AI. Exclusion of extrinsic environmental or other factors, the establishment of a likely inheritance pattern, and recognition of phenotype and correlation with the dates of tooth formation to exclude a chronological developmental disturbance involves diagnosis. [5] The enamel may be hypoplastic, hypo mineralized or both and teeth affected may be discolored, sensitive or prone to disintegration either post-eruption or preeruption. [5] It may be associated with morphologic or biochemical changes elsewhere in the body. [6, 20]

*Corresponding author: E-mail : donagiftson@gmail.com

Hypoplastic AI represents 60-73% of all cases; hypomaturational AI represents 20-40%, and hypocalcification AI represents 7%. [7] The most widely accepted classification is that proposed by Witkop and Sank in 1976. Witkop and Rao, (1971) classified AI broadly based on phenotype and style of inheritance [8] into three categories: Hypoplastic variety, hypocalcified variety, and hypo maturation variety. Aldred and

Crawford in 1995 (8) classified based on a molecular defect, biochemical result, mode of inheritance and phenotype.

We present here case series of AI along with a complete review that we diagnosed on the basis of clinical and radiographic features.

Table 1: Classification of amelogenesis imperfecta (Witkop and Sauk)		
Type I hypoplastic	IA	Hypoplastic, pitted autosomal dominant
	IB	Hypoplastic, local autosomal dominant
	IC	Hypoplastic, local autosomal recessive
	ID	Hypoplastic, smooth autosomal dominant
	IE	Hypoplastic, smooth X-linked dominant
	IF	Hypoplastic, rough autosomal dominant
	IG	Enamel agenesis, autosomal recessive
Type II hypomaturational	IIA	Hypomaturational, pigmented autosomal recessive
	IIB	Hypomaturational
	IIC	Snow-capped teeth, X-linked
	IID	Autosomal dominant
Type III hypocalcification	IIIA	Autosomal dominant
	IIIB	Autosomal recessive
Type IV hypomaturational-hypoplastic with taurodontism	IVA	Hypomaturational-hypoplastic with taurodontism, autosomal dominant
	IVB	Hypoplastic-hypomaturational with taurodontism, autosomal dominant

2. CASE 1

A 16 years old female patient reported to our department, with a chief complaint of sensitivity to hot and cold and pain in relation to all her teeth since last 3-4 years. A detailed case history was recorded which revealed that none of the parents, siblings or relatives suffered from similar dental conditions. Intraoral examination revealed dental fluorosis, extrinsic stains, and severe gingival inflammation resulting in loss of stippling soft erythematous and edematous gingiva with profuse bleeding. The crown of the posteriors had an altered morphology due to attrition and wearing of enamel giving a yellowish color. There were heavy chunks of calculus and there was generalized whitish flecks seen on the smooth surface of the enamel giving a snow flaked appearance of the teeth. On palpation, by probing resistance was felt and tooth material is soft in consistency with mild flaking of residual

enamel. Based on history and clinical examination a provisional diagnosis of AI - hypo maturation type was made.

Patient was advised orthopantomogram that showed generalized thinning of enamel on all tooth surfaces and enamel was even absent in certain areas (Fig. 2).body of the tooth and pulp chamber is enlarged vertically at the expense of the roots. As a result, the floor of the pulp and the furcation of the tooth is moved apically down the roots suggestive of taurodauntisim.

3. CASE 2

A patient aged 9, came with a complaint of stained teeth and wanted to descale it. He stated that his teeth were stained from the very beginning not sparing his primary dentition too. A detailed case history was recorded which revealed that none of the parents, siblings or

relatives suffered from similar dental conditions except for the fact that his parents were consanguineously married. Intraoral examination revealed gingivitis and a mixed dentition stage. The hard tissue status showed generalized yellowish discoloration and whitish flecks on the smooth surfaced enamel accompanied with

frequent chipping of the tooth as stated by the boy. He presented with anterior open bite and proximal contact spaces were lost in the dentition. On palpation through probing, the enamel was hard in consistency underlying the plaques and the calculus. The occlusal surfaces were attrited giving a flat plane.

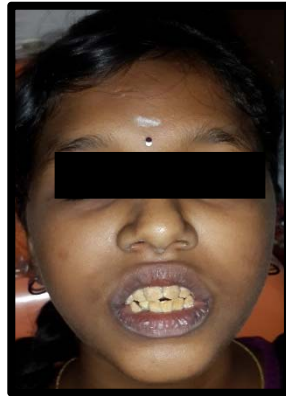

Fig. 1.Extra oral view

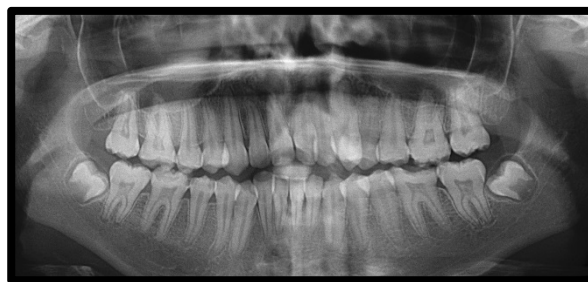


Fig. 2.OPG

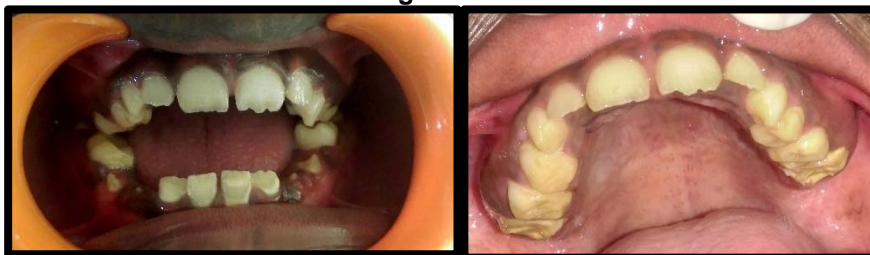

Fig. 3

Intraoral view

Fig. 4

OPG revealed anterior open bite with attrited anterior teeth almost 1mm short of the pulp coronal pulp chamber. The mixed dentition stage shows erupting canines, second molars and 3rd molar buds in the maxilla. Mandible shows erupting canines premolars and second molars and 3rd molar buds. The teeth showed varying levels of attrition in the anterior starting from mild to moderate in the coronal 3rd of the anterior crowns.

The boy was provisionally diagnosed with **AI-hypocalcified type**.

4. CASE 3

A patient aged 17 came with a complaint of painful teeth in the right upper back jaw region. She gave h/o pain for past 2 months which became dull aching gradual in onset and intermittent in nature over the course of time after having self-prescribed medications. Intraoral

examination revealed mild gingivitis. The hard tissue inspection revealed generalized yellowish discoloration of teeth covered with plaque, loss of varying amounts of enamel and attrition of the occlusal and incisal aspect of crowns. Loss of proximal contact in the maxillary anterior leading to tapering appearance of the incisors crowns. Chipping of the enamel in the incisal aspect. Running the probe along the smooth surface of the crown, resistance was felt and tooth material was soft in consistency with mild flaking of residual enamel.

Patient was advised orthopantomogram that showed generalized thinning of enamel on all tooth surfaces and enamel was even absent in certain areas (Fig. 6). Based on history, clinical

findings, radiological report and histopathological findings the case was diagnosed as **hypoplastic AI**.

5. DISCUSSION

Amelogenesis Imperfecta represents a group of conditions genomic in origin, which affect the structure and clinical appearance of the enamel of all or nearly all the teeth in a more or less equal manner and which may be associated with morphologic or biochemical changes elsewhere in the body. [9, 22] AI had been first reported in 1890. It was considered a clinical entity distinct from dentinogenesis imperfecta only in 1938. Its

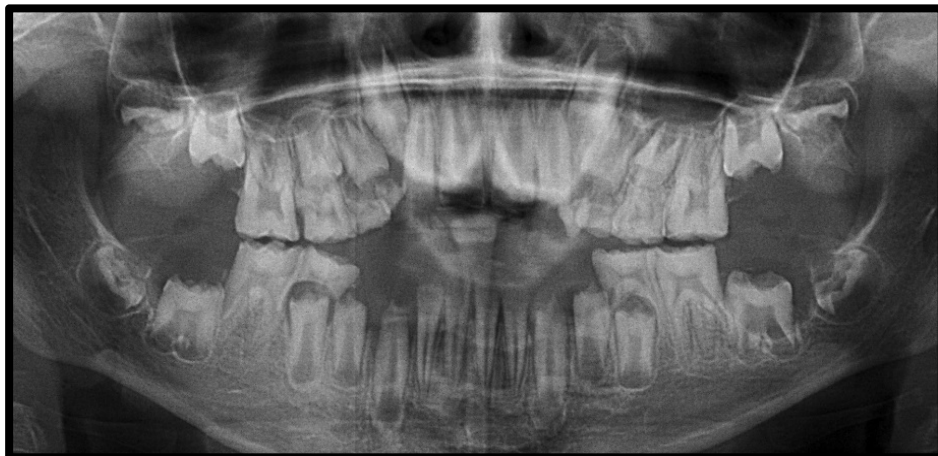

Fig. 5 OPG

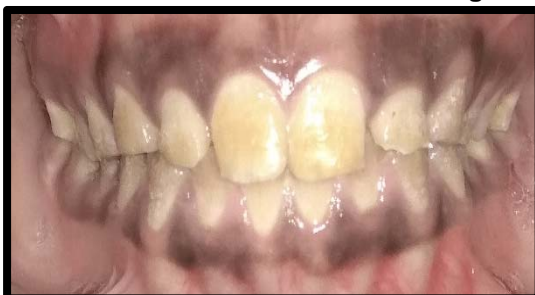

Fig. 6.

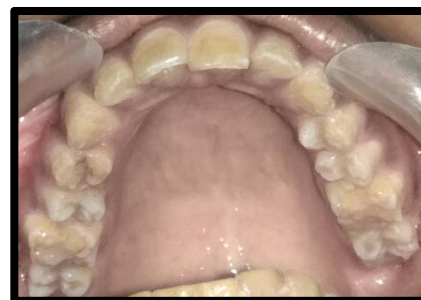

Fig. 7.

Intraoral view

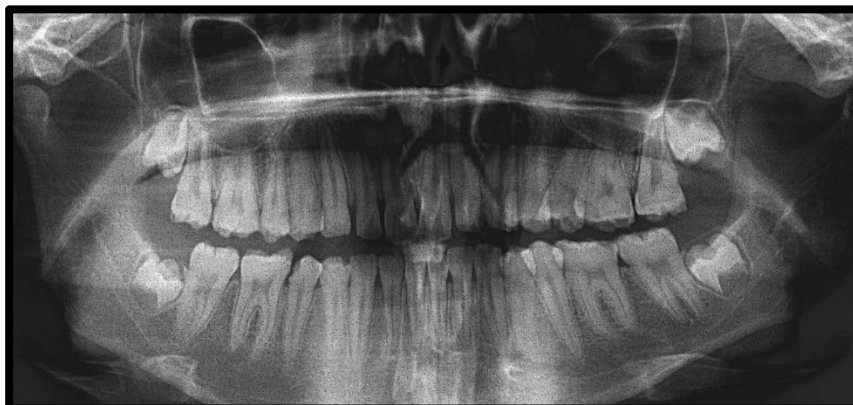

Fig. 8. OPG

prevalence varies widely between studies, from 1 in 718 to 1 in 14000. [10] The predominant clinical manifestations of affected individuals are enamel hypoplasia (enamel is seemingly correctly mineralized, but thin), hypo mineralization (subdivided into hypomaturational and hypo calcification), or a combined phenotype, which is seen in most cases. [6] The trait of AI can be transmitted by an autosomal-dominant, autosomal-recessive, or X-linked mode of inheritance. [6, 7] The distribution of AI types is known to vary among different populations. In a study in Sweden, 63% of the cases were inherited as autosomal-dominant. In contrast, in a study in the Middle East, the most common prevalent type of AI was found to be autosomal-recessive. [11]

6. ETIOLOGY

Dental enamel, a highly mineralized tissue has over 95% of its volume being occupied by unusually large, highly organized, hydroxyapatite crystals. [5, 23] The formation of enamel has been highly organized, and unusual structure is thought to be rigorously controlled in ameloblasts. This has been through the interaction of a number of organic matrix molecules. They include enamelin (ENAM; 4q21), Amelogenin (AMELX; Xp22.3-p22.1), ameloblastin (AMBN; 4q21), tuftelin (TUFT1; 1q21), amelotin (AMELOTIN; 4q13), dentine sialophosphoprotein (DSPP; 4q21.3), kallikrein 4 (KLK4; 19q13.3-q13.4), matrix metalloproteinase 20 (MMP20; 11q22.3-q23). [12]

The *DLX3* gene is a member of the family of homeo box genes that are homologous to the *distalless* (Dll) gene of *Drosophila*, known to be expressed during development of the chondrocranium, dermatocranium, sensory

organs, brain, limbs, and appendages, and in the processes of ontogenesis and hematopoiesis. [2, 13, 20] Mutation within the human *DLX3* gene homeodomain is associated with AI (hypoplastic-hypomaturational type), with taurodontism (AIHHT). Dong *et al.*, 2005, suggest that the tricho-dento-osseous syndrome (TDO) and amelogenesis imperfecta hypoplastic-hypomaturational with taurodontism (AIHHT) are allelic for *DLX3*. [14]

7. CLINICAL FEATURES

Type I / hypoplastic AI: Hypoplastic form of AI is characterized by thin enamel with yellowish-brown colour, rough or smooth and glossy, square-shaped crown, lack of contact between adjacent teeth, flat occlusal surfaces of posterior teeth due to attrition, and with/without grooves and/pitting. Radiographically, in hypoplastic type, there is a presence of thin radiopaque layer of enamel with normal radio density. Histologically, in hypoplastic type, defect is in enamel matrix formation. [4, 6] In about 50% of cases, the anterior open bite is noticed as a result of a decreased crown height. [5, 7, 17]

Type II / hypomaturational AI: Hypomaturational form of AI is characterized by normal thickness of enamel but softer than normal but harder than hypocalcified type and may crack away from the crown, mottled-colored cloudy white/yellow/brown/snow-capped. Radiographically, radio density of enamel is similar to that of dentin [23]. Histologically, in hypomaturational type, alterations in enamel rod and rod sheath structures had been noted in various studies. AI may be allied with some other dental and skeletal developmental defects or abnormalities. They are crown and root resorption, attrition, taurodontism, delayed

eruption, and tooth impaction, dens in dente, pulp stones, anterior open bite, and agenesis of teeth. [7]

AI is sometimes associated with syndromes such as AI with taurodontism, tricho-dento osseous syndrome, AI with nephrocalcinosis, and cone-rod dystrophy with AI. [5, 18, 24]

Type III / hypocalcified AI: This variety of AI appears as opaque white to yellow-brown discoloration with soft and rough enamel surface. Dentin sensitivity and open bite are common, as well as heavy calculus formation. Hypocalcified form of AI is the most common type and is characterized by normal size and shape of crown, softer enamel which wears down rapidly and can be removed by a prophylaxis instrument, and become pigmented-dark brown colored. Radiographically, in hypocalcified form, thickness of enamel is normal but radio density of enamel is less than that of dentin. Histologically, in hypo calcification type, defects of matrix structure and mineralization is seen. [5, 7]

In hypoplastic-hypomaturation with taurodontism, the enamel is thin, mottled yellow to brown, and pitted. Molar teeth exhibit taurodontism and other teeth have enlarged pulp chambers. [25]

Histologically, a ground section of the teeth involved showed very thin enamel, composed of laminations of irregularly arranged enamel prisms. [15] The SEM studies of the extracted deciduous teeth, in a case of autosomal recessive rough hypoplastic amelogenesis imperfecta, showed an exposed outer enamel surface, with irregularly shaped globular protrusions. At the cervical region of the crown, a series of wavy, parallel ridges was seen in the enamel regions. The cementum area was clearly distinguishable from the more coronal region by its mottled and fibrillar pattern, and the tendency for the cementum to overlap the ridged coronal structure along the cervical line. The enamel had a high organic content with some abnormal prism formation. The dentinoenamel junction was sharply defined and easily identifiable because of the more homogenous appearance of the enamel matrix, as compared with that of the dentin, with its array of collagen fibrils. [16] The histology of autosomal dominant hypomaturation–hypoplasia type of AI with taurodontism, definitively described by Winter *et al.*, comprised of areas of severe hypo mineralization with a pore volume of between 1 and 25%. They described a normal prismatic structure to the enamel, but with considerable post-calcification organic content and occasional

bands of globular defects. The dentin was also reported as being defective, with a decreased number of tubules, an increased amount of intertubular dentin, dilatations, and cellular inclusions. All these findings were more marked in the radicular dentin. The pulp was normal, but enlarged in size. [5]

8. DIFFERENTIAL DIAGNOSIS

Extrinsic disorders of tooth formation, chronological disorders of tooth formation, and localized disorders of tooth formation should be considered in the differential diagnosis. [26] The differential diagnosis considered most probable is dental fluorosis. The variability of this condition, from mild white “flecking” of the enamel to profoundly dense white coloration with random, disfiguring areas of staining and hypoplasia, entails careful interrogation to distinguish from AI. [5,27] Fluorosis may present with areas of horizontal white banding corresponding to periods of more intense fluoride intake. The premolars or second molars are normally spared (chronological distribution). The history often reveals excessive fluoride intake in terms of a habit, such as eating toothpaste in childhood or related to a local water supply. [5]

9. CONCLUSION

In this case series we saw all the 3 types of AI with almost similar clinical features, posing a complicated scenario for diagnosing each of the types. Several investigators have suggested a classification system for amelogenesis imperfecta, based on the phenotype and pedigree combined with scanning electron microscopic examination, biochemical methods, and molecular genetics.

Thus the dentist has to diagnose the condition as early as possible to offer early intervention and balance the decision for early intervention and long-term survival of the restorations. Dental practitioners should consider the social implications for these patients and intervene to relieve their suffering. Thus, this article is an attempt to improve the clinician's knowledge about the clinical diagnosis as well as an idea about the clinical presentation of all the 3 types of AI.

CONSENT

Prior consent was taken from the patients before publication.

ETHICAL APPROVAL

It is not applicable.

ACKNOWLEDGEMENT

I would like to extend my sincere thanks to all the authors who put their effort in this article.

COMPETING INTERESTS

Authors have declared that no competing interests exist.

REFERENCES

1. Weinmann JP, Svoboda JF, Woods RW (1945) hereditary disturbances of enamel formation and calcification. *J Am Dent Assoc* 1945; 32:397-418
2. Chaudhary M, Dixit S, Singh A, Kunte S. Amelogenesis Imperfecta: Report of a case and review of literature. *J Oral Maxfac Pathol*. 2009; 13(2): 70-77.
3. Takagi Y, Fujita H, Katano H, Shimokawa H, Kuroda T. Immunochemical and biochemical characteristics of enamel proteins in hypocalcified amelogenesis imperfecta. *Oral Surg Oral Med Oral Pathol Oral Radiol Endod*. 1998 Apr; 85(4): 424-30.
4. Sandeep Kaur et al. Amelogenesis Imperfecta: A case report, *International Journal of Oral Health Dentistry*; January-March 2017;3(1):70-73
5. Crawford PJ, Aldred M, Bloch-Zupan A. Amelogenesis imperfecta. *Orphanet J Rare Dis*. 2007;2:17
6. Aldred MJ, Savarirayan R, Crawford PJ. Amelogenesis imperfecta: a classification and catalogue for the 21st century. *Oral Diseases*. 2003; 9:19-23.
7. Rajendran R. Developmental disturbances of oral and para oral structures. In: Rajendran R, Sivaparthasundaram B, editors. *Shafer's Text book of Oral Pathology*. 5th ed., Ch. 1. Amsterdam: Elsevier; 2007. p. 67.
8. Witkop CJ Jr, Rao S. Inherited defects in tooth structure. The clinical delineation of birth defects. Part XI orofacial structures. In: Bergsma E, editor. *Birth Defects Original Article Series*. Vol. 7. Baltimore: Williams & Wilkins; 1971. p. 153-84.
9. Mehta.D.M, shah.J, Thakkar.B. Amelogenesis Imperfecta; Four case reports, *J. Nat.Sc. Biol.Med*. 2013; 4:462-465.
10. Nuzula Begum, Gowri P Bhandarkar, RaghavendraKini, VathsalaNaik, K Rashmi, Lizzy Carol DSouza. Amelogenesis Imperfecta: A Series of Case Report. *International Journal of Advanced Health Sciences* 2015; 2(1):17-21.
11. Lagerstrom M, Dahl N, Iselius L, Backman B, PetterssonU. Mapping of the gene for X-linked amelogenesis imperfecta by linkage analysis. *Am J Hum Genet* 1990; 46:120-5.
12. Iwasaki K, Bajenova E, Somogyi-Ganss E, Miller M, Nguyen V, Nourkeyhani H, et al. Amelotin – A novel secreted, ameloblast specific protein. *J Dent Res* 2005; 84:1127-32.
13. Weiss K, Stock DW, Shao Z. Dynamic interactions and the evolutionary genetics of dental patterning. *Crit Rev Oral Biol Med* 1998; 9:369-98.
14. Dong J, Amor D, Aldred MJ, Gu T, Escamilla M, MacDougall IM. DLX3 mutation associated with autosomal dominant amelogenesis imperfecta with taurodontism. *Am J Med Genet A* 2005; 133:138-41.
15. Ishikawa G, Waldron CA. Amelogenesis imperfecta. *Color atlas of Oral Pathology*. 1st Indian ed. 1999. p. 15.
16. Ooya K, Nalbandian J, Noikura T. Autosomal recessive rough hypoplastic amelogenesis imperfecta. *Oral Surg Oral Med Oral Pathol* 1988; 65:449-58.
17. Lam E. Dental Anomalies. In: White SC, Pharaoh MJ, editors. *Oral Radiology: Principles and Interpretation*. Elsevier: India; 2009. pp. 303-37.
18. Channougananda SC, Ashokan KA, Ashokan SC, Bojan AB, Ganesh RM. Literature review of amelogenesis imperfecta with case report. *J Indian Acad Oral Med Radiol* 2012; 24:83-7.
19. Mayur Chaudhary Shweta Dixit,¹ Asha Singh,² and Sinkar Kunte² Amelogenesis imperfecta: Report of a case and review of literature, *J Oral Maxillofac Pathol*. 2009 Jul-Dec; 13(2): 70-77.
20. Geetima Khanna¹, Muhammad Nishad Thyath¹, Vikram Khanna², Meha Sharma Amelogenesis imperfecta- a case report, *J of Adv Med and Den Sci Research [Vol. 3|Issue 2| April - June 2015*
21. Veena Hegde, Sunanda Sharma. "Amelogenesis Imperfecta: A Clinical Report". *Journal of Evolution of Medical and Dental Sciences* 2015; Vol. 4, Issue 01, January 01; Page: 140-146 DOI: 10.14260/jemds/2015/23

22. Dr.A.Vasanthakumari¹,Dr.G.Shanmugavadeivel²,Dr.A.Josna³,Amelogenesis Imperfecta –A Case Report OSR Journal of Dental and Medical Sciences (IOSR-JDMS) e-ISSN: 2279-0853, p-ISSN: 2279-0861.Volume 15, Issue 2 Ver. X (Feb. 2016), PP 116-118
23. Gemimaa Hemagaran¹,Arvind. M². Amelogenesis Imperfecta - Literature Review, IOSR Journal of Dental and Medical Sciences (IOSR-JDMS) e-ISSN: 2279-0853, p-ISSN: 2279-0861.Volume 13, Issue 1 Ver. IX. (Feb. 2014), PP 48-51
24. Dhaval N. Mehta, Jigna Shah¹ and Bhavik Thakkar²Amelogenesis imperfecta: Four case reports, /#J Nat SciBiol Med. 2013 Jul-Dec; 4(2): 462–465.
25. Mehta, D.N., Shah, J., Thakkar, B, Amelogenesis imperfecta: Four case report : J Nat Sci, Bio and Med 2013; 4(2): 462-465[PubMed]
26. Mahesh K P. Amelogenesis imperfecta. Int J Health Allied Sci [serial online] 2012 [cited 2018 Mar 31]; 1:283-5.
27. R.Ramya¹ , C.Sandhya¹ , R.Ramky¹ , Dr. G.S. AnandhaMala² Int. J of Latest Tech in Eng, Manag & ApplSci (IJLTEMAS)Volume VII, Issue III, March 2018 | ISSN 2278-2540