***Original Research Article***

# Invivo-study of antiviral effect of *Gossypium hirsutum* extract on Newcastle Disease Virus.


## ABSTRACT

*Gossypium hirsutum* belongs to the family Malvaceae and genus Gossypium, the name of the genus is derived from the Arabic word *goz*, which refers to a soft substance. This plant occupies a very important position in traditional medicine because of its ethnomedicinal value. The aim of the study was to evaluate the antiviral effect of *Gossypium hirsutum* extract on Newcastle disease virus. The experimental design involved the use of 59 birds (broiler). The phase involved pre-infection, infection and post-infection. Clinical signs of dyspnea, gasping, greenish diarrhea and paralysis were observed .There was mortality from day 4 in both treated and untreated groups. Gross pathological lesion of both treated and untreated groups were similar and this includes catarrhal haemorrhagic lesion, muscular haemorrhages and congestion of the kidneys, duodenum and small intestine. Also, there was congestion of lungs, liver and necrotic granules in the gland. At histology in the treated group the proventriculus, duodenum, and trachea were normal. Rectal temperature of infected and un-infected birds ranged from 41.75 0.12 $^{O}$C to 42.35 0.44 $^{O}$C, while that of treated birds did not vary significantly with treatment regimen ($p>0.05$) and ranged from 40.5 0.5 $^{O}$C on day one post infection to 42.40 0.07 $^{O}$C on day 3. It was observed that both treated and untreated group was eventually overwhelmed by the NDV despite the relatively low effect of the extract. There was no significant antiviral effect of *G. hirsutum* extract on Newcastle disease virus, since all the birds died.



Keywords; *Gossypium hirsutum*, extract, birds, Newcastle disease virus, invivo-study.


## INTRODUCTION

*Gossypium hirsutum* belongs to the family Malvaceae containing 243 genera and at least 4,225 species of herbs, shrubs and trees, Economically, the most important member of the family Gossypium [1].The genus Gossypium is a leading species, comprises around 50 species in the tribe Gossypium [2]. The leaves are 5-7 lobed, lobes ovate and rotundus only slightly constricted at base [3]. *G. hirsutum* was used in this study due to their multifaceted biological activities

including anticancer, antifertility, antioxidant and antivirus activity[4], Newcastle Disease is a highly contagious viral disease that affects poultry of all ages [5]. Although the first outbreaks recognized as Newcastle Disease occurred in Indonesia in 1926, it has been suggested that a major outbreak in Scotland in 1986 was due to Newcastle disease virus [6]. The first documented outbreak of Newcastle Disease in Nigeria occurred between December 1952 and February 1953 in Ibadan [7]. The disease has remained a notable problem in the country [8] and has become endemic in Nigeria in both local and commercial poultry, with annual epidemics recorded in highly susceptible flocks with pockets of outbreaks occurring in between the annual epidemic periods [9].

Newcastle disease (ND) is a zoonosis of economic importance, it is endemic in Nigeria and constitutes the greatest threat to the development of poultry industry in the country [7, 10, 11]. The reservoirs are found among wild and local birds [12, 13]. These and other factors leads to the disease occurring in all year round and peaks in the harmattan and dry seasons [7]. Outbreaks are usually associated with mortality which could be upto 100% and decrease in egg production [14]. Possible therapy is presently lacking and control has been by vaccination [15]. Existing vaccines do not seem to effectively protect birds against highly virulent strains of ND virus resulting in reports of vaccination failures and occurrence of post-vaccinal outbreaks [7, 16, 17]. Sequel to the above problems, the search for additional means of controlling ND in Nigeria becomes very pertinent in order to save the poultry industry from this scourge.

Besides drugs developed from medicinal chemistry, plant natural products constitute major sources of innovative therapeutic agents for various conditions including infectious disease [18, 19]. Only a minute portion of plant diversity has been explored in this regard and ample

opportunities in sourcing antimicrobial drugs from plant products selected on the basis of ethno-medicinal use [20, 21].

An apparently feasible approach to the control of ND in Nigeria therefore is the use of easily accessible antiviral drugs. This approach could be achieved through the search for ND antiviral remedies in plant natural products selected on the basis of ethno-medicinal use. This study therefore examines the antiviral effect of *G. hirsutum* extract on ND virus.

**Concentration of the extracts**

*Gossypium hirsutum* was concentrated with undiluted and 10 fold dilution of the extract in sterile distilled water.

## MATERIALS AND METHODS

**Plant extract**

One phase experimental design with fifty nine (59) birds was used for the study. A set of experimental birds was used for the study. The set comprised 59 broiler (Anank), obtained from hatchery stock in Aba, Abia State. The stock of bird was brought at day old, brooded and raised to four weeks (broilers) without Newcastle` Disease vaccination. Antibiotics, vitamins and coccidiocidal drugs, were administered during brooding while vaccination against infectious Bursal disease was at 2weeks. Treatment with the *G. hirsutum* extract commence at 5weeks. The birds were raised in veterinary experimental farm of the university

Each sub group of birds was kept in a separated cage. Control groups were kept about one kilometer away from the test groups. Birds were fed with sufficient feed and water ad-libitum and observed for clinical signs.

The leaves of *Gossypium hirsutum* was bought in dried form from medicinal natural products shop at Umuahia central market, Abia State between April and June 2012. The plant pod was identified by Professor C.U. Okeke, a plant taxonomist of the department of botany, NnamdiAzikiwe University, Awka.

For the pre-extraction preparation of plant, The plant materials were rinsed in sterile distilled water, air derived at room temperature for 7-20days, and pulverized using pestle and mortar, ground into fine texture in electric grinder and stored at room temperature in air-tight containers for further processing. Preliminary phytochemical analysis of *Gossypium hirsutum* was performed on the ground plant samples using the method of Harbone [22].

Plant extraction was by measuring fifty grams of powdered plant material and mixing with 500mls of distilled water to obtain a 10% suspension in a conical flask. The suspension was maintained at room temperature ($27^0$C) for 24hrs and filled with whatman No 1 filter paper. The residue was discarded and filtrate made into 10 fold and 100 fold dilutions of the aqueous extract of *Gossypium hirsutum* in distilled water.

**Newcastle VIRUS PROPAGATION AND QUANTIFICATION**

Newcastle virus (kudu strain) was obtained from Dr. Ponman of the National Veterinary research institute vom, Plateau State, Nigeria. It is a velogenic strain with a titer of 108.2 MLD50/ml. Nine to eleven day old (pre-incubated embryonated) chicken eggs were obtained from Guffons Veterinary Hatchery in Owerri, Imo State. The chicken eggs were used immediately on arrival in the laboratory for the study. Virus stock was passaged four times in 9-11 days old embryonated chicken eggs by inoculation of 0.2ml fraction into the allantoic sac. The inoculated eggs were incubated for four days at 37 $^{O}$C in an egg incubator chilled in the refrigerators overnight and the allantoic fluid was harvested for virus isolation. Virus in allantoic fluid was quantified by

cultivation of tenfold serially diluted stock in embryonated eggs and virus titre estimated as egg infections dose fifty per millimeter of allantoic fluid by the endpoint assay of Reed and Muench [23].This work was carriedout in Veterinary Microbiology Laboratory of Michael Okpara University of Agriculture,Umudike.

For assay of toxicity of extract, Graded concentration of plant extract in sterile phosphate buffered saline were inoculated into 9-11days embryonated chicken eggs (0.2ml) per egg) by the allantoic route. Inoculated eggs were incubated for five days at 37 $^{O}$C in an egg incubator and monitored for egg mortality.

Toxicity of extract was estimated as percentage egg mortality.

. **Immunization scheme with Newcastle virus**

All test birds were treated either at pre-infection, at time of infection, or at the beginning of clinical signs with 0.1%, 1.0% or 10% concentration of the plant aqueous extract. Each bird received 12.5ml of extract orally twice a day at 8.00am and 4pm (25ml/day) after the drinking water trough had been removed for one hour.

**Treatment of infected Birds**

Fifty nine (59) birds were used for the study. Five groups of birds were used in all.Two groups of birds A and B, numbering sixteen (16) in each group served as infected test groups. Each of the A and B group was treated with one plant extract after infection. Out of the 16 in each group, eight (8) birds in each group were infected with ND virus while the remaining 8 were housed together as in-contact with those that were infected to encourage natural transmission. The third group called group C were made of twelve (12) birds. The group C was used as positive control (6birds were infected and 6 birds left as in-contact without treatment with extract). Group D was made of 5 birds and this group were inoculated with sterile distilled water (diluents) and served

as negative control and finally is group E which is made up of 10 birds, subdivided into E1 and E2 with 5 birds in each subgroup and inoculated each with extracts (extract control). Each infected birds was inoculated intramuscularly with 0.2ml of ND virus Kudu train containing $10^{7.2}EID_{50}$/ml. Uninfected birds were similarly inoculated but with 0.2mls of either distilled water or the extracts.

## Results

### *Gosypium hirsutum*

Phytochemical analysis of methanolic extract showed the presence of alkaloids, tannis,terpenoids, saponin and cardiac glycosides, flavonoids and steroids were absent.

### Profile of clinical signs

Birds treated with *Gossypium hirsutum* extract at preinfection showed signs of dyspnea, gasping and greenish diarrhea from the third day after treatment, followed by paralysis on the fourth day. Birds treated at time of infection had whitish diarrhea on the third day. Untreated birds and those treated from onset on signs showed greenish diarrhea and respiratory sign from day 2 but whereas the untreated birds had paralysis from day 3, those treated did not show nervous signs (Table 1). Mortality started on the 4$^{th}$ day in all experimental birds of both treated and untreated groups irrespective of treatment regimen adopted. However mortality lasted for only two days (4$^{th}$ and 5$^{th}$) in the untreated group, it extended till the 6$^{th}$ day in all the treated groups. Neither the treated nor the untreated groups survived the infection as all the infected birds were dead by the sixth day (Table2. The virus haemagglutination antigen was low in lungs (16), trachea (28) and brain (18) at preinfection, at infection and no treatment, However, high virus

haemagglutination antigen occurred in duodenum (512), proventriculus (1024), duodenum (1024) and kidney (1024) at pre=infection, at infection, at disease onset and no treatment respectively.

**Gross Pathology**

Gross pathological lesions in both treated and untreated birds were similar. There were catarrhal haemorrhagic lesions in the trachea, congestion of the lungs and kidney, petechical haemorrhages in the proventriculus and muscular haemorrhages. However, lesions were more widely distributed in the untreated groups than in the treated groups (Table 1). The proventriculus, duodenum and trachea were normal at histology in the treatment group. The lungs had bronchiopneumonia and intestinal pneumonia. The meninges were inflamed and there was necrosis of intestinal mucosa and splenic lymphocytes leading to severe depletion of splenic mature lymphocytes (Figure 1 and 2).There was pericarditis and myocarditis with mononuclear infiltration of muscle fibers while in the infected but untreated group, there were erosion of the trachea, duodenum and small intestine with necrosis of intestinal mucosa and proventricular glands. There was congestion of the lungs and kidney, as well as myocarditis with mononuclear infiltrations of muscle fiber. The was necrosis of the spleen with depletion of mature lymphocytes, for uninfected and untreated groups, all organs and tissues examine were normal.There were erosion of the trachea, duodenum and small intestine with manifestation of erosive enteritis at histpathology. The liver, lungs and kidney were congested and proventriculus had necrotic glands in the glands (Figure 1 and 2). There was intravascular haemolysis and presence of haemosiderin granules.

Rectal temperature was taken with digital clinical thermometer, the rectal temperature of uninfected birds (Negative controls) in the first three days post-infection ranged from 40.17 ±

0.12 $^{O}C$ to 40.41 ± 0.24 $^{0}C$. Those of infected and untreated birds (Positive controls) ranged from 41.75 ± 0.12 $^{O}C$ to 42.35 ± 0.44 $^{O}C$. Rectal temperature of treated birds did not vary significantly with treatment regimen ($P < 0.05$) and ranged from 40.5 ± 0.50 $^{O}C$ on day 1 post infection to 42.40 ± 0.07 $^{0}C$ on day 3. The variation in rectal temperature recorded in treated and untreated group was not significant as shown in the values of treated birds on day1(40.5±0.50 $^{O}C$-41.35±0.02 $^{O}C$ and day 2 (41.25 ± 0.124-41.35 ± 0.06 $^{O}C$) than in untreated birds (41.75 ± 0.12 and 42.20 ± 0.20 respectively). In the directly infected untreated group, 33.3% mortality occurred on days 2, 4, 6, 8 and 9 p.i, whereas in the indirectly infected groups 33.3% and 66.7% of the birds died respectively on days 8 and 9p.i. None of the birds in both group survived infection.

Table 1: Profile of clinical signs in chicks infected with Newcastle disease virus and treated under various regimen with aqueous extract of *Gossypium hirsutum*

| Treatment Regiment | Clinical Sign | Onset duration of clinical signs on various days post infection | | | | | | |
|---|---|---|---|---|---|---|---|---|
| | | 1 | 2 | 3 | 4 | 5 | 6 | 7 |
| Pre infection | Dysnoea | | | + | + | | | |
| | Diarrhea | | | + | + | | | |
| | Paralysis | | | - | + | | | |
| At infection | Dyspnoea | | - | + | + | + | | |
| | Diarrhea | | + | + | + | + | | |
| | Paralysis | | - | - | - | - | | |
| At disease onset | Dyspnoea | | + | + | + | + | | |
| | Diarrhea | | + | + | + | + | | |
| | Paralysis | | - | - | - | - | | |
| Untreated | Dyspnoea | | - | + | + | | | |
| | Diarrhea | | + | + | + | | | |
| | Paralysis | | - | + | + | | | |

**Table 2: Distribution of Newcastle disease virus haemagglutinating antigen in various organs of infected chicks treated with aqueous extracts of *Gossypium hirsutum*.**

| Treatement Regimen | Virus haemasggiutinating antigen (Log base 2) in various pooled organs | | | | | |
|---|---|---|---|---|---|---|
| | Trachea | Lungs | Duodenum | Proventriculus | kidney | Brain |
| Preinfection | 64 | 16 | 512 | 256 | 128 | 128 |
| At infection | 28 | 64 | 1024 | 1024 | 128 | 64 |
| At disease onset | 256 | 128 | 1024 | 512 | 128 | 128 |
| No treatment | 128 | 64 | 1024 | 512 | 1024 | 8 |

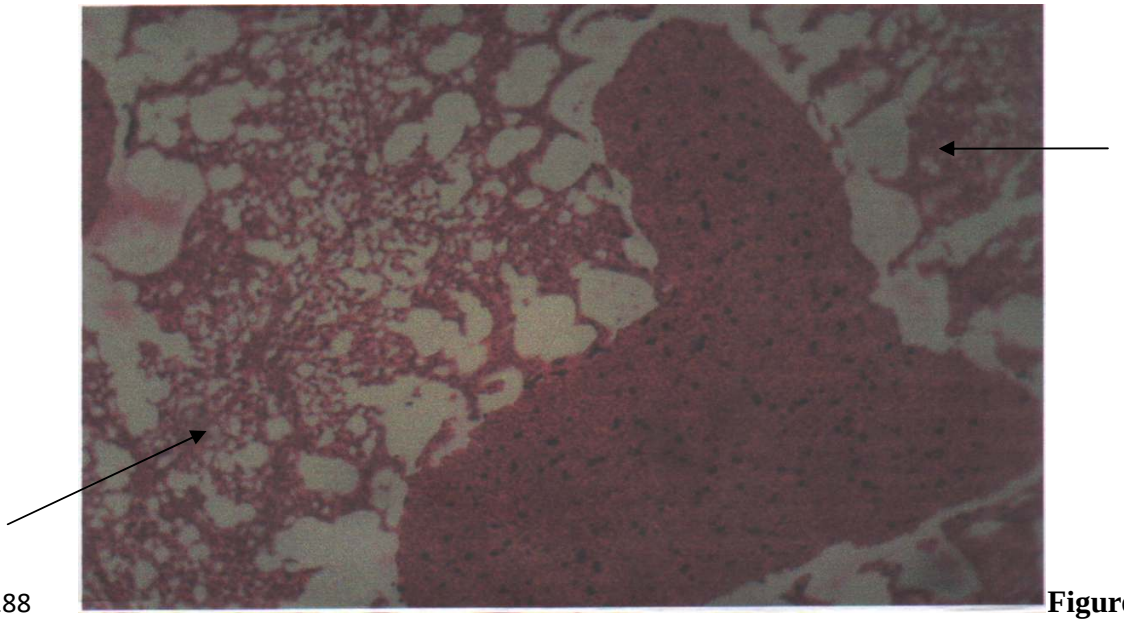

**Figure 1: Congested lung at 6days post infection (enlargement 400x)**

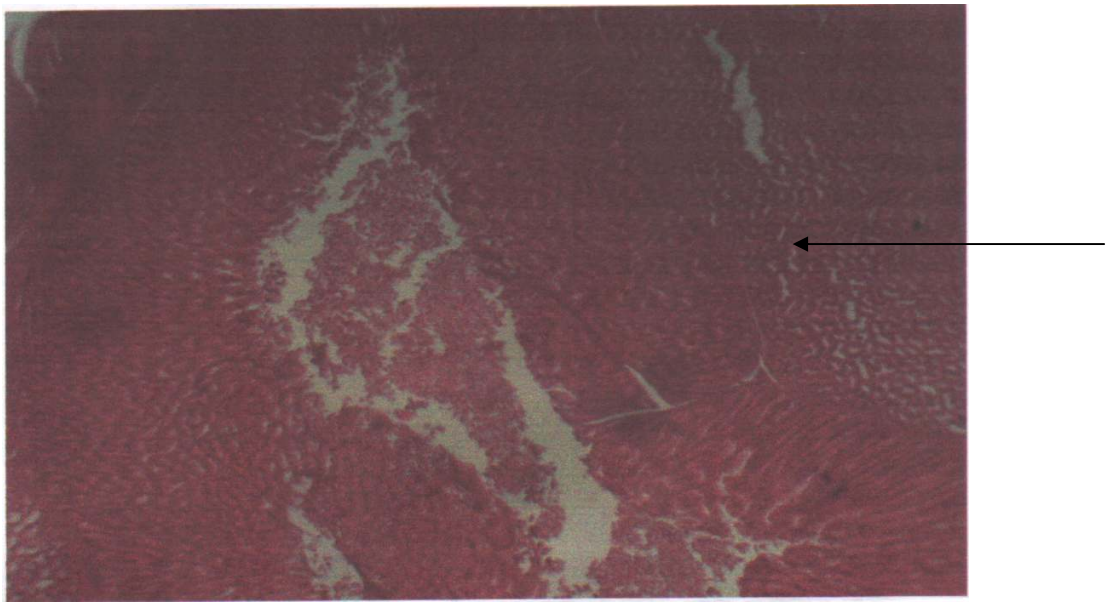

**Figure 2: Proventriculus with necrotic granules in glands at 6days post infection (enlargement 400x)**

## Discussion

The phytochemical analysis of *Gossypium hirsutum* extracts revealed the presence of some chemicals known to have some antiviral effect including alkaloids, terpenoids, saponins and tannins. These have been reported to inhibit te synthesis of viral DNA, other polynucleotides and viral proteins [24]. There was no noticeable action of the extract against ND virus in this study. However, the phytochemical components including saponins, tannis, terpenoid and alkaloids are known to affect the genetic synthesis of viruses [24]. All three antiviral regimen applied in the study did not exhibit virus inhibition by *Gossypium hirsutum* extract. Extracts of *Gossypium hirsutum* are widely used in ethnomedicine even in the treatment of viral diseases including HIV and Herpes viruses [25]. There was evidence of reduction of viral load, increase in body weight and CD4 lymphocyte count when extracts were used in AIDS patient volunteers in Anambra State before the advent of antiretroviral therapy [26]. [20] also reported significant antiviral activity of aqueous extract against Yellow fever virus in vero cells. Gossypium is a polyphenolic compound found in Gossypium species has antifertility, anticancer, antioxidant, antitrypanosoma, antiviral and antimicrobial activities [27]. The onset of clinical signs in 2days post infection (dpi) in untreated birds is in line with previous reports on the incubation period of velogenic viscerotropic NDV. [25] reported that four weeks old birds experimentally with viscerotropic velogenic NDV manifested clinical signs in 2 dpi and died between 4 and 5 dpi.

In birds treated with *Gossypium hirsutum* (GH), the profile of clinical signs and incubation period were not significantly different in treated and untreated birds except one day delay in disease onset observed in birds treated a day before infection. This correlates with the level of antiviral effect observed in the invitro antiviral study in embryonated chicken eggs, it is at variance with reports of activity of *Gossypsium hirsutum* extracts against other viruses including

HIV, herpes viruses and yellow fever virus [25, 26, 20]. These viruses belong to different families from NDV. There are to the best of our knowledge, no reports of remedy against ND by extracts of GH. Mortality started same day (4 dpi) in both untreated birds and those treated with GH. Survival period of birds was one day longer in GH treated groups than in the untreated. These extracts did not protect the birds from mortality due to NDV and this is suggestive of no positive effect by the *G. hirsutum* extract.

Similar pattern of clinical sign and survival period observed in cockerels was also replicated in broilers they were directly inoculated with the virus. In the GH treated group, both treated and untreated had same onset of signs but survival was increased by one day in those treated. Because the extract lacked complete efficacy against NDV, similar gross lesion was observed in both treated and untreated birds with widespread organ involvement resulting from the high virulence of the velogenic viscerotropic virus used [25, 28]. However, the relatively low effect of the extracts on the virus activity was manifested by the distribution of lesions being relatively wide in the untreated birds. Pathological lesions observed typical of velogenic visceroptropic NDV [25]. Since the birds, both treated and untreated was eventually overwhelmed by the NDV despite the relatively low effect of the extract, NDV haemagglutinating antigen was detected in many organs. This was so because the birds lack immunity and the challenge virus was of high virulence. [28] observed a wider distribution of virus in most organs in non-immune birds but a restriction of virus distribution to the proventriculus, caecal, tonsils and Bursa of Fabricousin immune birds challenge with velogenic NDV.

During the period of incubation (2-3dpi), rectal temperature was relatively lower in treated birds than in the untreated group. Pyrexia is known to correlate with viraemia in viral pathogenesis [29]. It is possible that the lower rectal temperature observed in the treated birds at

the stage of infection resulted from decreased viraemia due to the effect of the extracts.This activity probably could not be sustained due to high virus virulence leading to fatal disease in both treated and untreated groups. There is usually a direct relationship between pyrexia and viraemia in viral infections [30].

## Conclusion

Antiviral activity was not exhibited by aqueous extract of *Gossypium hirsutum*. One percent and ten percent suspensions respectively of crude extracts of *Gossypium hirusutum* had no significance efficiency against Newcastle disease in chicks, although pyrexia was lowered, both disease progression and mortality rate were slightly delayed

## REFERENCES


Berry PE. Malvaceae. Encyclopaedia Britannica. Encyclopaedia Britannica online. Encyclopaedia Britannica Inc. 2012. Available from; http;//www.britannica.com/EBchecked/topic/360675/Malvaceae

Wendel JF, Brubaker C, Alvarez I, Cronn R, Stewart JM. Evolution and natural history of the cooton Genus. In Paterson AH, editor. Plant Genetics and Genomics. Crops and Models. 2009; 3: 3-22.

Senchina DS, Alvarez I, Cronn RC, Liu B, Rong J, Noyes RD. Variation among nuclear genes and the age of polyploidy in Gossypium. Mol. Bio. Evol. 2003: 20 (4) 633-643.

Gledhill D, The names of plants. 4 ed. Cambridge; Cambridge University Press; 2008. P. 182.

McMullin P. A Pocket Guide of Poultry Health and Disease. 5M Enterprise Ltd., Poultry Health Services, Sheffield, 2004 UK.

Sadiq MA, Nwanta JA, Okolocha EC, Tijjani AN. Retrospective study of Newcastle Disease cases in Avian species in Maiduguri, Borno State, North-Eastern Nigeria. International J. of Poultry Science, 2011; 10: 76-81.

Okwo EC, Eze DC. The annual prevalence of Newcastle disease in commercial chickens reared in South Eastern Savana zone of Nigeria. Research J. of Poultry Sciences, 2010; 3(2): 23-26.

Oladele BS, Abdu PA, Nok AJ, Esievo KAN, Useh, NM. (2002). Effect of some inhibitors ion neuraminidase of Newcastle disease virus kudu 113 strain. Veterinar Siarlir, 2007; 72: 185-194

Saidu L, Abdu PA. Outbreak of Viscerotropicvelogenic form of Newcastle disease in vaccinated six weeks old pullets. J. of Veterinary Sciences, 2008; 7(1): 37-40.

Ogundipe SO. A review of the rural poultry production efforts in Northern states of Nigeria. In: Proceedings of the International Workshop on Rural Poultry in Africa held at the Obafemi Awolowo University, ile — Ife. E, 13. Sonaiya (ed) CTA Publication Manual 1998; pp. 201 -207.

Hills DI, Davis OS, Wilde JK. Newcastle disease in Nigeria. British Veterinary Journal, 1953; 109: 381 -385.

Echeonwu GO, lroegbu CU, Emernwa AC. Recovery of velogenicNewcastle disease virus from dead and healthy free roaming birds in Nigeria. Avian Pathology,1993; 22:283 - 287.

Ezeifeka GO, Dowoh SK. Involvement of wild and domestic birds in the epidemiology of Newcastle disease and Infectious Bursal Disease viruses in Zaria, Nigeria. Bulletin of Ani. Health and Production in Africa, 1992; 40: 125 – 127.

OIE. Newcastle disease; Aetiology, epidemiology, diagnosis, prevention, control. OlE Scientific and Technical Department Publication, 2009; ppl-6

Alexander DJ. Newcastle disease, other avian paramyxoviruses, and pneumovirus infection. In Saif, Y.M. et al (Ed). Diseases of Poultry. Iowa State University Press, Ames, U.S.A. 2003; PP 64-87.

Nwanta J, Abdu P, Ezema W. Epidemology, challenges and prospects for control of Newcastle disease in village poultry in Nigeria. Worlds Poultry Science Journal, 2008; 64(01):119-127.

Ezeifeka GO, Onunkwo EO. Comparative study of thermostability of Hitchner, BI., and Ulster2C vaccinal strains of Newcastle disease virus. Bulletin of Animal Health and Production in Africa, 2005; 52:204-206.

Cos P, Vlietinck AJ, Berghe DV, Maes L. Anti-infective Potential of natural products: Mow to develop a stronger in-vitro proof of concept. Journal of Ethnopharmacology, 2006; 106: 290-302

Clardy J, Walsh C. Lessons from natural molecdes. Nature, 2004; 423: 829 - 837.

Fashola TR, Adeyemo FA, Adeniji JA, Okonko LA. Antiviral potentials of *Gossypium hirsutum* extracts on Yellow fever virus. New York Science Journal, 2011; 4(10): 30-35.

Verporte R, Vande IK, Meent K, Inqkanirian K. Screening for acetylcholinesterase inhibitors from Amaryllidaceae using Silica gel thin-layer chromatography in combination with bioactivity staining. Journal of Chromatography, 2005; 32: 917-223.

Harbone JB. Phytochemical method a guide to modern techniques of plant analysis, Chapman and Halls, New York. 1998.

Reed LJ, Muench H. A simple method of estimating fifty percent endpoints dilution assay. American Journal of Hygiene, 1938; 27: 493-497

Jassim SA, Naji MA. A review of novel antiviral agents: A medicinal plant perspective. Journal of Applied Microbiology, 2003; 95: 412-427.

Brown C, King DJ, Seal BS. Pathogenesis of Newcastle disease in chicken experimentally infected with viruses of different virulence. Veterinary Pathology, 1999; 36: 125-132.

Gbadamosi IT, Obogo SF. Chemical constituents and in-vitro anti-microbial activities of five botanicals used traditionally for the treatment of neonatal jaundice in Ibadan, Nigeria. Nature and Science, 2013; 11(10): 130-135.

Vijayan P, Raghu C, Ashok G, Dhanaraj SA, Suresh B. Antiviral activity of medicinal plants of Nilgris. Indian Journal of Medicinal Research, 2004; 120(1): 24-29.

Parede L, Young PL. Pathogenesis of velogenic Newcastle disease infection ofchickens of different ages and different levels of immunity. Avian Diseases, 1990; 34: 803-808.

Vaughn DW, Green S, Kalayanaroo S, Innis BL, Nimmanniya S, Suntaya S, Rothman AL, Ennis FA, Misalak A. Dengue in the early febrile stage, viraemia and antibody response. J. Infectious Diseases, 1997; 176(2): 322-330.

Leitao F, Leitao SG, De-Fonseca VS, Silva IM, Martins K. Medicinal plants traded in the open-air markets in the state of Rio de Janeiro, Brazil: An overview on their botanical diversity and toxicological potential. Brasileira de Fermacognosia, 2001; 24(2): 225-247