Original Research Article

In utero exposure to oxcarbazepine causes congenital anomalies in albino rat fetuses

ABSTRACT

Aims: Oxcarbazepine (OXC) is a newer antiepileptic agent that has recently become increasingly used either as monotherapy or as an adjunct to other AEDs in adults, adolescents, and children with partial epilepsy. Our aim was to define the the potential risks of the anti-epileptic drug (OXC) orally administered daily to the pregnant rats.

Methodology: The pregnant rats administered from 7th till 20th day of gestation with 108 mg/kg oxcarbazepine (Human equivalent dose (HED)). All pregnant rats of the two groups were sacrificed and the growth parameters, skeletal malformation and the histopathology of liver, kidney and brain of the fetus were examined.

Results: Our results showed that Oxcarbazepine induced a reduction in the fetal weight and length, delayed, weak and incomplete ossification, wavy ribs and the fetal liver revealed histopathological changes, degenerated hepatocytes possessed karyorrhexed or karyolysed nuclei, the congestion of blood vessels and sinusoids.. Kidney revealed alternation changes, shrinked glomeruli, widened capsular space of the Bowman's capsule, hydrophobic degeneration of the tubules and cytoplasmic vacuole. Brain (cerebral cortex) showed neurodegenerative changes, marked neuronal cell degeneration, disorganization of the brain tissue, numerous pyknotised cells and vacuolization of the neuropil. Biochemical studies showed that OXC induced a reduction in the level GSH and catalase compared to control group.

Conclusion: These support and proof the potential risks of the OXC administration on fetus.

Keywords: *Rats, pregnancy, Oxcarbazepine, anti-epileptic drug.*

1. INTRODUCTION

Epilepsy is the most common serious chronic neurological condition, with a prevalence of between 4 and 10 people per 1000 [1]. Most of those affected, including women of childbearing age, will require long term treatment with antiepileptic drugs (AEDs) to prevent seizures. Although the interactions between epilepsy and pregnancy are multiple, it is the potential effect of AEDs on the developing fetus that raises most concern. With an estimated three to four pregnancies in every thousand occurring to women with active epilepsy [2, 3] this means between1800 to 2400 children are born to such women in the United Kingdom each year.

Seizures in pregnancy are particularly challenging, as their management requires careful consideration of not only the etiology of the seizure, but also the physiologic changes of pregnancy as well as potential adverse effects on the developing embryo or fetus [4].

Most women with epilepsy (WWE) require ongoing antiepileptic drug (AED) therapy during pregnancy in order to avoid the adverse effects of seizures on themselves and their unborn child. However, in utero AED exposure poses a risk of congenital malformations (CMs) to the child [5].

Treatment settlement for women with epilepsy are difficult due to incompatible risks. Although the majority of children born to women with epilepsy are normal, these women are at increased risk for complications during pregnancy, and their children are at increased risk for poor outcomes [6, 7]. Risks include prematurity, low birth weight, increased fetal and neonatal death rates, congenital malformations, and developmental delay. Congenital malformations are more likely in children exposed *in utero* to antiepileptic drugs (AEDs) and are increased with higher AED dosages, higher AED serum levels, or polytherapy [8].The most common major anatomic abnormalities associated with AEDs are heart malformations (e.g., ventricular septal defect), orofacial defects (e.g., cleft lip with or without cleft palate), urologic defects (e.g., hypospadius), skeletal abnormalities (e.g., radial ray defects, phalangeal hypoplasia), and neural tube defects (e.g.,

spina bifida). In addition to anatomic defects, *in utero* AED exposure has been associated with behavioral/cognitive defects [9-11].

The risk of AED teratogenesis must be balanced against potentially grave risks posed by seizures to both the mother and the child. Maternal deaths during pregnancy in women with epilepsy are 10 times more common than in women without epilepsy; this increase appears to be due to seizures, which are often related to discontinuing AED therapy or poor compliance [12].

Oxcarbazepine (OXC), a 10-keto analogue of carbamazepine, is an antiepileptic drug licensed for the treatment of partial seizures in children and adults, as monotherapy or adjunctive therapy [13].

This study will add to the medical literature on oxcarbazepine exposure during pregnancy and will provide insight to women and healthcare professionals about the risks to the fetus.

2. MATERIALS AND METHODS

2.1 EXPERIMENTAL ANIMALS

The present experimental study is thus carried out on the white albino rat (*Rattus norvegicus*). The standard guidelines of National Organization for Drug Control and Research (NODCAR) were used in handling animals. Females of 11-13 weeks old, weighing 200 to 250 g were selected and vaginal smears were prepared every morning and examined under the light microscope according to the method of [14] for 5 days to select the female with regular estrus. Two females with regular estrus cycle were selected in the pro-estrus stage and caged together with one male (weighing 200 to 250 g) overnight under controlled environmental conditions of temperature, humidity and light. The first day of gestation was determined by the presence of sperms in the vaginal smear [15].

2.2 EXPERIMENTAL PROCEDURE AND DOSING

Pregnant rats (n = 20) were randomly divided into two groups (10 pregnant rats in treatment group, 10 pregnant rats in control group). The experimental groups were as follows: group one (control group) received the ordinary drinking water was used as the control solution, group two (OXC group) received 108 mg/kg/day of OXC [Trileptal (Novartis)], The dose of drug in treated group was defined according to the weights of the rats. And the drug dose was adjusted accordingly. The control solution and antiepileptic drug were administered orally, daily from 7th till 20th day of gestation via gastric tube. Water and food were supplied *ad libitum* during all the experiment.

2.3 DEVELOPMENTAL OBSERVATIONS

At the 20th day of gestation, all pregnant rats of groups (A&B) were sacrificed. Fetal body weight, body length, tail length and external malformation were recorded.

2.4 SKELETAL EXAMINATION

Fetuses were preserved in 95% ethyl alcohol and were stained with double staining of fetal skeletons for cartilage (Alcian blue) and bone (Alizarin red) according to the method de-scribed by [16].

2.5 HISTOPATHOLOGICAL PREPARATION

On the 20th day of gestation respectively the fetuses of the two groups (A&B) were sacrified by decapitation.

Liver, kidney and brain of fetuses of different groups were fixed for histological examination by light microscopy in 10% formol saline for at least 24 hours and then preserved in 70% ethyl alcohol. The fetuses were dehydrated in ascending grades of ethyl alcohol, cleared in terpineol and embedded in paraffin wax. Serial transverse sections 5 microns thick of different neonatal tissues were cut, mounted and stained with haematoxylin and eosin for general histological studies.

2.6 OXIDATIVE STRESS INVESTIGATION

Autopsy samples were taken from the brain of fetuses in different groups were stored at -40◦C for oxidative stress investigation. Piece of liver were weighted and homogenized in 10 mmol/L phosphate buffer saline (PBS) as 10 % (W/V) at pH 7.4. The homogenates were centrifuged and the supernatants were taken for the estimation of: Glutathione Reduced (GSH) and Catalase (CAT).

2.6.1 ESTIMATION OF GLUTATHIONE REDUCED

Tissue GSH was determined by calorimetric method using reagent kits obtained from Bio Diagnostic (Egypt) by the method of [17].

2.6.2 ESTIMATION OF CATALASE

Tissue catalase was determined by calorimetric method using reagent kits obtained from Bio Diagnostic (Egypt) by the method of [18].

2.7 STATISTICAL ANALYSIS

All the values were presented as means (μ) ± standard errors of the means (S.E.M) comparison between more than two different groups was carried out using the one-way analysis of variance (ANOVA).

2. RESULTS AND DISCUSSION

Offspring of women with epilepsy on AEDs are at increased risk for intrauterine growth retardation, minor anomalies, major congenital malformation, cognitive dysfunction, microcephaly, and infant mortality [19-22]. However, continuation of medication during pregnancy is often necessary to prevent seizures which would be harmful to mother and fetus.

Use of older generation antiepileptic drugs such as Phenobarbital, phenytoin, valproate, and carbamazepine during pregnancy has been associated with an approximately 3-fold increased risk of birth defects [22].

The focus of research is currently moving from the first to the second ADE generation. Lamotrigine is relatively well studied, and data on other novel AEDs, such as levetiracetam and oxcarbazepine, topiramate, zonisamide, gabapentin and pregabaline, are in progress [23].

The present study was carried out to evaluate the teratogenic potential of the oxcarbazepine on the fetuses of albino rats orally administrated with 108mg/kg during the gestation period , the following parameters were investigated, morphological, skeletal studies, oxidative stress and histopathological changes in different fetal tissues.

3.1 MORPHOLOGICAL STUDIES

3.1.1 MORPHOLOGICAL OBSERVATION OF UTERUS

The uterus of pregnant rats treated with 108mg/kg oxcarbazepine showed asymmetrical and partial distribution of fetuses in the two uteri horns and reduced number of fetuses and diminution in the number of implanted fetuses (Fig.1)

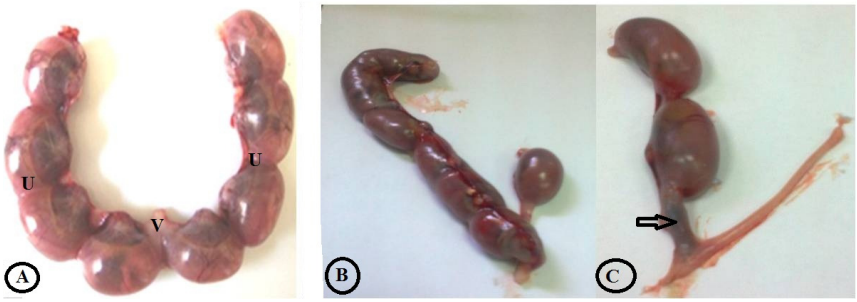

Fig.1: photographs of uterus of pregnant rat. **(A):** control uterus at the 20th day of gestation showing normal distribution of fetuses in the two uterine horns. **(B& C):** uterus of pregnant rats treated with 108mg/kg oxcarbazepin showing asymmetrical and partial distribution of fetuses. resorption site (arrow),U=uterus,v=vagina.

3.1.2 GROWTH RETARDATION

The present work showed, oral treatment of pregnant rats with 108mg/kg (which is the human equivalent dose of body weight) oxcarbazepine during the gestation caused growth retardation represented by non significant decrease in fetal body weight, body length and significant decrease in tail length (Table1).

Table 1: The body weight, body length and tail length of fetuses at the 20th day of gestation.

Groups	Average body weight of fetuses	Average body length of fetuses	Average tail length of fetuses
control	3.72 ± 0.1	5.58 ± 0.059	1.69 ± 0.043
Fetuses maternally treated with OXC.	3.52 ± 0.061	5.26 ± 0.104	1.54 ± 0.037 *

Data are represented as mean ± standard error. Sample size (n) = 10.
* Significantly different from control at $P \leq 0.05$.

Bennett *etal.* and Lockard *etal.* reported that OXC therapy showed low successful pregnancy levels. [24,25]

We suggested that the growth retardation of embryos due to the negative effect of OXC on the expression of extracellular matrix proteins that play a key role in placenta development and embryo implantation in young rats as reported in the study of [26].

3.1.3 MORPHOLOGICAL ANOMALIES

The most repeated anomalies observed were congestion, subcutaneous hematoma in different sites, abnormalities in limbs, specially paralysis, absence and shortness of digits (Fig.2). These types of anomalies might be indicated a direct effect of this drug on the developing embryos.

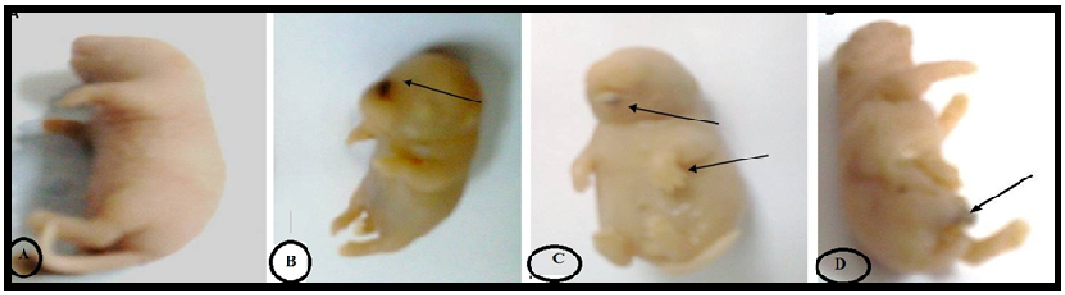

Fig.2: photographs of fetuses at 20th day of gestation. (**A):** normal fetus, showing normal growth, **(B):** fetus of maternally treated with 108 mg/kg of OXC, showing hematoma at the head (Arrow), **(C):** fetus of maternally treated showing fore limb paralysis and hematoma at the lower jaw (Arrows), (**D):** fetus maternally treated, showing lose of foot (Arrow).

3.2 SKELETAL ANOMALIES

On the 20th day of gestation, the cleared cartilage and bone preparations of control rat fetuses have designated that in all parts of the axial skeleton skull, vertebrae and ribs as well as appendicular skeleton comprising the fore and hind limbs, pectoral and pelvic girdles, both chondrification and

ossification processes have been obviously completed as demonstrated in (figs. 3A&C&E&G), displaying the developed cartilage and bone in the different parts of skeleton of these fetuses. The cartilaginous parts of the skull included the proximal part of the nasal, the tympanic, squamosal and supra occipital regions. In the vertebral column, the proximal ends of the transverse processes and vertebral arches have cartilaginous ends. Also, two thirds of the caudal vertebrae and sternal portions of the ribs appeared cartilaginous. In addition to the cartilaginous joints in between the long bones of both fore and hind limbs, cartilaginous parts were found in the distal end of the scapula as well as proximal parts of the ilium and ischium of the pelvic girdle. Ribs of control fetuses, on the 18th day of gestation, acquired a normal set of 13 pairs of ribs; each of which consists of cartilaginous parts (the sternal portion of ribs) and a fully ossified part (the vertebral portion of ribs) as demonstrated in (figs. 3A&C&E&G). The sternebrae in those fetuses were formed of six ossified segments, the first one was fused with the fully cartilaginous manubrium, while the last segment was attached to the process of xiphoid cartilage. On the other hand, fetuses of the group maternally treated with 108mg/kg of oxcarbazepine showed sever Lack of ossification of roof of the skull (Fig.3B). Non-ossified central and neural arches of the thoracic, lumbar vertebrae, the abnormal cuvature of 13th thoracic rib of seven fetuses, the rudimentary 12th thoracic rib in 11fetuses, the weakly ossification of ribs in nineteen fetuses and absence of ossification of metacarpals (Fig.3D). Sternum anomalies such as unossification of all sternbrae or parietal ossification of some sternbrae (second and last one) were observed in thirteen fetuses and in twelve fetuses respectively (Fig.3F).Caudal vertebra, metatarsals and Phalanges were absolutely non-ossified (fig. 3H).



Fig. 3: photographs of skeleton of fetuses at 20th day of gestation. **(A):** skull bones of control fetus showing well ossification **(B):** skull bones of fetus maternally treated with with 108 mg/kg of OXC, showing sever lack of ossification. (**C):** skeleton of control showing complete ossification of fore limb, cervical and thoracic vertebrae. **(D):** skeleton of fetus maternally treated showing bone of fore limbs was shorter, bones of radius and ulna shows reduction in ossification, metacarpals and phalanges of the toes were completely cartilage as compared of those of control. The12th thoracic rib was shortness and asymmetrical, however 13th thoracic rib was completely cartilage and curved. **(E):** control sternum of fetuses showing well ossified of sternbrae bones. **(F):** sternum of fetuses maternally treated showing Un-ossified sternbrae bones. **(G):** lumber, sacral, caudal vertebrae and hind limb. of control fetuses showing complete ossification **(H):** skeleton of fetuses maternally treated showing non-ossified of lumbar and sacral vertebrae of the central and neural arches. Moreover, the caudal vertebrae were absolutely non-ossified (Arrow), bones of the pelvic girdle showed reduction in size and retardation in ossification, the metatarsus and phalanges of the toes were completely cartilage.

The observed fetal abnormalities may be arise from the direct action of the used antiepileptic drugs (AEDs) on placenta development and fetal tissues and may be secondary due to maternal toxicity.

[27] Added that the pregnant women with epilepsy receiving Newer AEDs (oxcarbazepine) therapy may have a lower teratogenic risk than traditional AEDs.

Contrary to the previous studies [28] who found that the newborns of women receiving oxcarbazepine monotherapy during pregnancy do not appear to show an increased risk for malformations compared with newborns in the general population.

Also, Contrary to these studies [29] who reported that a patient with a history of CPS (complex partial seizures) can be treated with oxcarbazepine with no adverse effects during and after pregnancy.

3.3 HISTOPATHOLOGICAL STUDIES

Examination of serial transverse sections of the brain, liver and kidney of albino rat fetuses maternally treated with 108mg/kg oxcarbazepine on the 20th day of gestation indicated that oxcarbazepine induced marked histopathological changes.

3.3.1 Liver of fetuses

The sections of the control group showed normal histological structure in the form of lobules, each is surrounded by very thin connective tissue capsule. The tissue of the lobules is made up of radiating cords of cells alternating with sinusoids and enclosing minute blood sinusoids. The hepatic sinusoids are lined by the undifferentiated reticular cells, possessing small, darkly stained, elongated nuclei, and the stellate cells, phagocytic cells of Kupffer (Fig.4A).

The liver of fetuses maternally treated with 108mg/kg oxcarbazepine revealed that severe histopathological alterations. The most striking effects of this dose were the congestion of blood vessels and sinusoids. Most of the central veins were congested and contained stagnant intact and hemolysed blood cells and lined with detached epithelial cell (Fig. 4 B). The liver of this group showed marked loss of the lobular architecture and disorganization of the hepatic strands. These degenerated hepatocytes possessed karyorrhexed or karyolysed nuclei (Fig. 4 C &D).

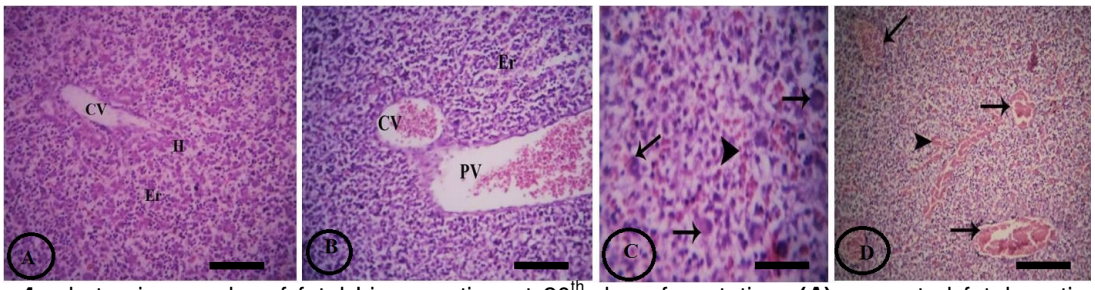

Fig.4: photomicrographs of fetal Liver section at 20th day of gestation. **(A):** a control fetal section, showing no histopathological alteration .The central vein with its intact endothelial lining (CV). Er= erythroblasts. (**B):** Section of liver of fetus maternally treated with 108mg/kg oxcarbazepine , showing congested central vein (CV) and portal vein (PV). (**C):** Section of liver of fetus maternally treated showing megakaryoblasts (Arrow), congested of blood sinusoids (Head arrow). (**D):** Section of liver of fetus maternally treated showing megakaryoblasts (Arrow), congested sinusoids (Head arrow). H&E stain. Bar =1µm

[30, 31] reported that OXC like other AEDs is significantly transferred through the placenta, leads to liver toxicity of fetuses.

It is possible that higher OXC concentrations in cord blood in some cases are due to the slightly slower clearance of this compound from the fetal side than from the maternal side. Fetal liver has

been shown to metabolize many foreign compounds [32], and also is known that half-life of most drugs is prolonged in human neonate [33].

[34] Reported that fetal metabolism is generally slower than that in the adult because metabolizing enzyme activities such as cytochrome P-450 are much lower in the fetal liver.

[35] Found a significant relation between antiepileptic affecting the liver such as carbamazepine and OXC and increased fracture risk. These antiepileptic drugs influence the cytochrome P 450 system in the liver and increase the vitamin D catabolism. The decreased intestinal calcium absorption as a result of the induction of the cytochrome P 450 enzyme system can lead to inactive vitamin D production, secondary hyperparathyroidism, increased urinary calcium and phosphate excretion and increased bone turnover, resulting in bone mineral density (BMD) reduction [36,37].

3.3.2 Kidney of fetuses

The control group showed normal histological structure (Fig.5A). Meanwhile sections of kidney of fetuses maternally treated with 108 mg/Kg oxcarbazepine from (7th to 20th) day of gestation revealed some histological changes such as oedema in between the tubules and glomeruli, shrinked glomeruli, widened capsular space of the Bowman's capsule, hydrophobic degeneration of the tubules and cytoplasmic vacuole. The outer borders of the cells lining tubules were deteriorated (Fig.5B).

The functional immaturity of the prenatal kidney limited the excretion of many drugs so that their level in the embryo was often higher than in the mother and therefore increasing the toxic effects [38].

These findings are in agreement with the study of **[39]** Levetiracetam administration caused shrinking in glomeruli, acute cellular swelling in lining epithelium of the tubules at the cortex and Hydropic degeneration in kidney.

Oxcarbazepine, like carbamazepine, may cause hyponatraemia presumably due to an antidiuretic hormone-like effect [40,41].

[42] Reported that Low serum sodium levels and hyponatremia are more common in female patients and in elderly subjects treated with OXC.

[43] hypothesized that Oxcarbazepine could induce hyponatremia as a consequence of its influence on distal nephron where it could promote free water retention, urinary sodium loss, or both of them. A greater tubular sesitivity to oxcarbazepine influence.

In addition, edema and kidney structure disruption in between the tubules and glomeruli were observed in the present study. This can be due to the entrance of sodium into the cell with fluid, which might cause intracytoplasmic edema and disruption in kidney structure.

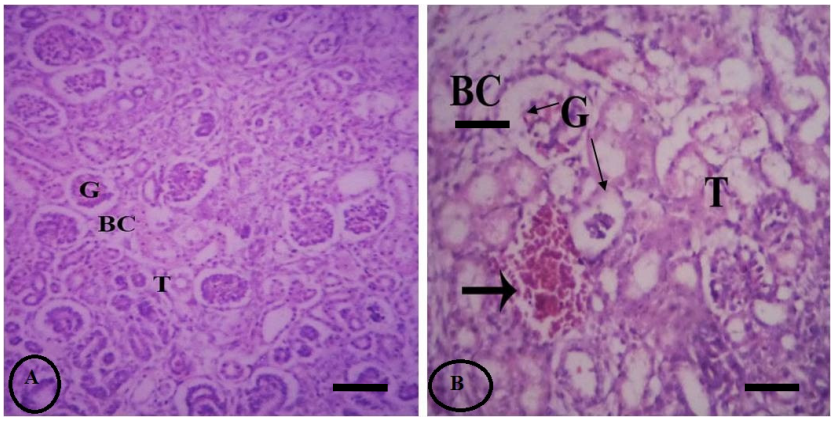

Fig.5: photomicrographs of fetal kidney section at the 20th day of gestation. **(A):** a control fetal kidney section, showing a part of the cortical region containing a glomeruli (G) with Bowman's capsule (BC)

and tubules (T). (**B):** Section of kidney of fetus maternally treated with 108mg/kg oxcarbazepine, showing shrinked glomeruli(G) (arrow)**,** widened capsular space of the Bowman's capsule (BC) and degeneration of the epithelial cells lining the tubules (T) thrombosis(Arrow). H&E stain. Bar =1µm

3.3.3 Brain of fetuses

In the control group there was normal histological structure of cerebral hemispheres (Fig.6A), while in fetuses maternally treated with 108mg/kg oxcarbazepine from (7th to 20th) day of gestation revealed sever degenerative change that characterized by marked neuronal cell degeneration, disorganization of the brain tissue, numerous pyknotised cells and vacuolization of the neuropil (Fig.6 B &C).

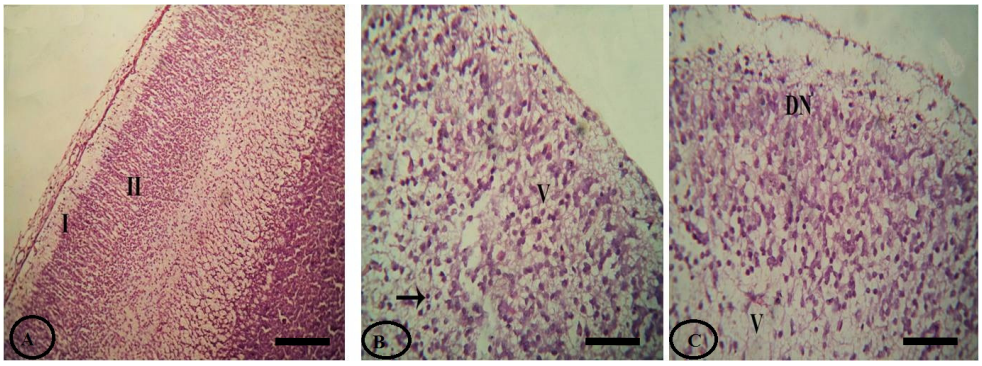

Fig.6: photomicrographs of fetal brain section at the 20th day of gestation. **(A):** a control fetal brain section, showing cerebral cortex layers. I= Molecular layer, II= granular layer. **(B):** Section of brain of fetus maternally treated with 108mg/kg oxcarbazepine, showing Cerebral cortex with low neurons density, disorganization of brain tissue structure, and numerous pyknotised cells (Arrow), extensive neuropil vacuolization (V). (**C):** Section of brain of fetus maternally treated showing degenerated neuron (DN), vacuolization of neuropil (V). H&E stain. Bar =1µm

Ambrosio *et al.* Studied the neurotoxic and neuroprotective effects of some AEDs, demonstrated that, treatment with AEDs, mainly carbamazepine(CBZ) and oxcarbazepine, caused nuclear chromatin condensation in some neurons, which was characteristic of apoptosis[44] .

In our studies, the histopathological changes in brain of fetuses could also be explained through induction of oxidative stress. Lack of GSH leads to more reactive oxygen species (ROSs) that damage and kill the glial cell, which then cannot reuptake and process extracellular glutamate as stated [45].

3.4 OXIDATIVE STRESS OBSERVATIONS

The data in table 2 showed the effect of oral administration of oxcarbazepine during gestation on the level of some non-enzymatic antioxidant defense system as reduced glutathione (GSH), enzymatic antioxidant defense system such as (CAT) in their fetuses.

Table2: Catalase content and Glutathione reduced:

Groups	Catalase content	Glutathione reduced content
Control group	0.7183± 0.011	0.0380± 0.007
Groups maternally treated with OXC.	0.6383± 0.014*	0.0293± 0.007

Data are expressed as mean ±Standard error
* Significantly different from control at P<0.05.

Our results indicated that oxcarbazepine induced a marked decrease in brain glutathione reduced and a significant decrease in brain catalase content throughout the experiment compared to control. It is clear that glutathione was depleted while combatingfree radicals.

Our data indicated that oxcarbazepine induced oxidative stress in rat brain. These results are in consistent with the previous studies [46] showed that oxcarbazepine significantly decreased levels of reduced glutathione in rats with pentylenetetrazole induced epilepsy.

Pavone and Cardile studied effects of AEDs such as carbamazepine (CBZ), TPM and oxcarbazepine (OXC) on oxygen stress in an astrocyte culture from rats. Selected list of studied variables includes: lactate dehydrogenase (LDH) and glutamine synthtase (GS) levels, ROS production, lipid peroxidation and DNA fragmentation [47]. They found that these Drugs caused oxygen stress whatever their dose.

Anti-epileptic drugs in therapeutic dosage have been known to unfavorably alter the redox balance in experimental models and in human beings [48, 49].

Increased free radicals lead to neuronal degeneration through increased lipid peroxidation, decreased glutathione levels and decrease in superoxide dismutase and catalase activites [50].

Excess oxidative stress can be a final common pathway, by which AEDs exert teratogenic effects [51].

Contrary to other previous studies of Guerra *et al*. who reported that oxcarbazepine had no evidence of toxicity to the mother or pre-embryos in development [52].

The major limitation of this study, where this study was performed in healthy rats, it would have been of more translational value in doing this study in true epilepsy models for instance, animal mutants or transgenic animals with spontaneously recurrent seizures, which are more closely related to human epilepsy than traditional seizure models like MES (maximal electroshock seizure) and PTZ (pentylenete trazol) induced seizure models.

4. CONCLUSION

It can be concluded that oxcarbazepine had teratogenic effects when administered at dose 108 mg/ kg from 7th to 20thday of gestation. Although oxcarbazepine is induced oxidative stress which revealed by reduction in the level GSH and catalase compared to control group. In addition, the drug induced histopathological changes in liver, kidney, brain of fetuses. All of these led to growth retardation, skeletal malformation.

Finally, it can be concluded that the administration of oxcarbazepine during pregnancy should only be considered if the expected benefit to the mother is greater than any possible risk to fetuses. Our findings should now be tested using different methods and larger numbers of subjects in future Studies to explainthese eratogenic effects.

ETHICAL APPROVAL

It is not applicable.

COMPETING INTERESTS

Authors have declared that no competing interests exist.

5. REFERENCES

1. Hauser WA, Annegers JF, Rocca WA. Descriptive epidemiology of epilepsy: contributions of population-based studies from Rochester, Minnesota. Mayo ClinProc. 1996; 71: 576–586.
2. Dansky LV, Finnell RH. Parental epilepsy, anticonvulsant drugs, and reproductive outcome: epidemiological and experimental findings spanning three decades; 2: human studies. ReprodToxicol. 1991; 5(4):301–335.
3. Olafsson E, Hallgrimsson JT,Hauser WA, Ludvigsson P, Gudmundsson G. Pregnancies of women with epilepsy: a population-based study in Iceland. Epilepsia. 1998; 39:887–892.
4. Moussa HN, Ontiveros AE, Haidar ZA, Sibai BM. Safety of anticonvulsant agents in pregnancy. Expert opinion on drug safety. 2015; 14(10):1609-1620.
5. Meador KJ, Baker GA, Finnell RH, Kalayjian LA, Liporace JD, Loring DW, Mawer G, Pennell PB, Smith JC, Wolff MC. In utero antiepileptic drug exposure: fetal death and malformations. Neurology. 2006; 67(3):407–412.
6. Pennell PB. Pregnancy in women who have epilepsy. NeurolClin. 2004; 22:799–820.
7. Tomson T, Gram L, Sillanpää M, Johannessen S. Recommendations for the management and care of pregnant women with epilepsy. Epilepsy and Pregnancy. Petersfield: Wrighton Biomedical Publishing. 1997.
8. Finnell RH, Nau H, Yerby MS. General principals: teratogenicity of antiepileptic drugs. In: Levy RH, Mattson RH, Meldrum BS, editors. Antiepileptic drugs.Vol. 4. New York: Raven Press. 1995; 4: 209–230.
9. Meador KJ. Neurodevelopmental effects of antiepileptic drugs. CurrNeurolNeurosciRep. 2002;2:373–378.
10. Dean JC, Hailey H, Moore SJ, Lloyd DJ, Turnpenny PD, Little J. Long term health and neurodevelopment in children exposed to antiepileptic drugs before birth. J. Med Genet. 2002;39:251–259.
11. Cost LG, Steardo L, Cuomo V. Structural effects and neurofunctionalsequelae of developmental exposure to psychotherapeutic drugs: experimental and clinical aspects. Pharm Rev. 2004;56:103–147.
12. Adab N, Kini U, Vinten J, Ayres J, Baker G, Clayton-Smith J, Coyle H, Fryer, A, Gorry J, Gregg J, Mawer G, Nicolaides P, Pickering L, Tunnicliffe L, Chadwick DW. The longer term outcome of children born to mothers with epilepsy.J. NeurolNeurosurg Psychiatry. 2004; 75(11): 1575–1583.
13. Bang L, Goa K. Oxcarbazepine: a review of its use in children with epilepsy. Paediatr Drugs. 2003; 5: 557–573.
14. Snell GD. Biology of the laboratory Mouse, 5th ed. The Blakiston Company, pholadeliphia.1956.
15. McClain RM, Becker BA. Teratogenicity, foetal toxicity and placental transfer of lead nitrate in rats. Toxicol Appl Pharmacol. 1975; 931: 72-82.
16. Peters PWJ. Double staining of fetal skeletons for cartilage and bone. In: Neubert D, Merker HJ, Kwasigroch TE: Methods in prenatal toxicology. Stuttgart: Georg Thieme 1977; 153–154.
17. Beutler E, Duron O, Kelly M.B. J. Lab Clin Med 1963; 61: 882.
18. Aebi H. Catalase *in vitro*. Methods Enzymol 1984; 105: 121- 126.

19. Hvas C, Henriksen T, Ostergaard J, Dam M. Epilepsy and pregnancy: effect of antiepileptic drugs and lifestyle on birthweight. Br J. Gynaecol. 2000;107:896-902.

20. Yerby MS. Quality of life, epilepsy advances, and the evolving role of anticonvulsants in women with epilepsy. Neurology. 2000; 55:21-31.

21. Kaplan PW, Norwitz ER, Ben Menachem E, Pennell PB, Druzin M, Robinson JN, Gordon JC. Obstetric risks for women with epilepsy during pregnancy. Epilepsy Behav. 2007; 11:283-291.

22. Meador KJ, Pennell PB, Harden L, Gordon JC, Tomson T, Kaplan PW, Holms GL, French JA, Hauser WA, Wells PW, Cramer JA. Hope Group. Pregnancy registries in epilepsy: a consensus statement on health outcomes. Neurology. 2008; 71:1109-1117.

23. Reimers A, Brodtkorb E. Second-generation antiepileptic drugs and pregnancy: a guide for clinicians. Expert Rev Neurother. 2012; 12(6):707-717.

24. Bennett GD, Amore BM, Finnell RH, Wlodarczyk B, Kalhorn TF, Skiles GL, Nelson SD, Slattery JT. Teratogenicity of carbamazepine-10, 11-epoxide and oxcarbazepine in the SWW mouse. J. Pharmacol. Exp. Ther. 1996; 279, 1237–1242.

25. Lockard JS, Burkhead-Potter TM, Phillips NK, Congdon WC. Is oxcarbazepine a contraceptive? Pregnancy rate compared to carbamazepine,synthetic CBZ10–11 epoxide, and placebo in monkey. Epilepsia 2000; 41, 97–98.

26. Gurgen SG, Erdogan D, Coskun ZK, Cansu A. The effect of valproic acid and oxcarbazepine on the distribution of adhesion molecules in embryo implantation. Toxicology. 2012; 292, 71–77.

27. Meischenguiser R, D'Giano CH, Ferraro SM. Oxcarbazepine in pregnancy: clinical experience in Argentina. Epilepsy Behav. 2004; 5(2):163-7.

28. Montouris G. Safety of the newer antiepileptic drug oxcarbazepineduring pregnancy. Curr. Med. Res. Opin. 2005; 21(5):693-701.

29. Eisenschenk S. Treatment with oxcarbazepine during pregnancy.Neurologist. 2006; 12(5):249-54.

30. Pacifici GM, Nottoli R. Placental transfer of drugs administered to the mother. Clin. Pharmacokinet. 1995; 28(3):235–269.

31. Ohman I, Vitols S, Tomson T. Lamotrigine in pregnancy: pharmacokinetics during delivery, in the neonate, and during lactation. Epilepsia. 2000; 41:709–713.

32. Pelkonen O. Biotransformation of xenobiotics in the fetus. Pharmacology & therapeutics. 1980; 10(2), 261-281.

33. Klinger W. Biotransformation of drugs and other xenobiotics during postnatal development. Exp. ToxicicolPathol. 1996; 48(1):1–88.

34. Hakkola J, Pelkonen O, Pasanen M, Raunio H. Xenobiotic-metabolizing cytochrome P450 enzymes in the human feto-placental unit: role in intrauterine toxicity. Critical reviews in toxicology. 1998; 28(1): 35-72.

35. Vestergaard P. Epilepsy, osteoporosis and fracture risk - a meta-analysis. Acta Neurol. Scand., 2005; 112: 277-286.

36. Alison MP, Lucia SO, Martha JM, Edith F, Stanley RR, Elisabeth S. Bone mineral density in an outpatient population receiving enzyme inducing antiepileptic drugs. Epilepsy Behav. 2003; 4: 169-174.

37. Imran IA, Gregory LB, John, RG. Antiepileptic drugs and reduced bone mineral density. Epilepsy Behav. 2004; 5: 296-300.

38. Mucklow JC. The fate of drugs in pregnancy. Clinics in obstetrics and gynaecology, 1986; 13(2):161-175.

39. El Ghareeb AE, Hamdi H, Eleyan M .Teratogenic Effects of the Anti-Epileptic Drug (Levetiracetam) on Albino Rat Fetuses during Pregnancy and Lactation. RJPBCS 2015; 6(1): 1456-74.

40. Nielsen OA, *et al.* Oxcarbazepine-induced hyponatraemia, across sectional study. Epilepsy Research 1988; 2: 269–271.

41. Pendlebury SC, *et al.* Hyponatraemia during oxcarbazepine therapy. Human Toxicology 1989; 8: 337–344.

42. Grant SM , Faulds D. Oxcarbazepine. A review of its pharmacology and therapeutic potential in epilepsy, trigeminal neuralgia and affective disorders. Drugs1992; 43: 873-888.

43. Musso CG, Vilas M, Aparicio C, Bevione P, Reynaldi J, Rojas J, Jauregui R, Algranati L. oxcarbazepine induced hyponatremia. A potenial explanation of its physiopathology Rev Electron Biomed / Electron J. Biomed. 2009; 1:32-35.

44. Ambrosio AF, Silva AP, Araujoa I, Malva JO, Soares-da-Silva P, Carvalho AP, Carvalho CM. Neurotoxic/neuroprotective profile of carbamazepine, oxcarbazepine and two new putative antiepileptic drugs, BIA 2-093 and BIA 2-024. Eur J Pharmacol. 2000; 406:191–201.

45. Markowitz AJ, White MG, Kolson DL, Jordan-Sciutto KL. Cellular interplay between neurons and glia: toward a comprehensive mechanism for excitotoxic neuronal loss in neurodegeneration. Cell science. 2007; 4(1): 111–146.

46. Agarwal NB, Agarwal NK, Mediratta PK, Sharma KK. Effect of lamotrigine, oxcarbazepine and topiramate on cognitive functions and oxidative stress in PTZ-kindled mice. Seizure. 2011; 20: 257–262.

47. Pavone A, Cardile V. An in vitro study of new antiepileptic drugs and astrocytes. Epilepsia, 2003;44 (supl. 10): 34–39.

48. Ayciecek A, Iscan A. The effects of carbamazepine, valproic acid andphenobarbital on the oxidative and antioxidative balance in epileptic children. Eur.Neurol. 2007; 57:65-69.

49. Michoulas A, Tong V, Teng XW, Chang TK, Abbott FS, Farrell K. Oxidative stress in children receiving valproic acid. J.Pediatr. 2006; 149:692-696.

50. Sejima H, Ito M, Kishi K, Tsuda H, Shiraishi H. Regional excitatory and inhibitory amino acid concentrations in pentylenetetrazole kindling and kindled rat brain. Brain Dev 1997; 19:171–5.

51. Deepa D, Jayakumari N, Thomas SV. Oxidative stress is increased in women with epilepsy: Is it a potential mechanism of antiepileptic drug-induced teratogenesis?. AnnIndian Acad Neurol. 2012; 15:281-286.

52. Guerra MO, Oliveira LEG, Peters VM. Pre-embryoic development in rats treated with oxcarbazepine in the first days after insemination. Rev Ass Med Brasil 2000; 46(4): 346-53