HEPATOPROTECTIVE EFFECT OF AQUEOUS BARK EXTRACT OF *BOSWEILLIA DALZIELII* AGAINST PARACETAMOL INDUCED HEPATOTOXICITY IN RABBITS

Sa'id, A.M[1*], Ibrahim, M.S[1] , Mashi, J.A[1] and Daha, I.U[1]
[1]Department of Biochemistry, Faculty of Basic Medical Sciences, Bayero University Kano, PMB 3011, Kano State. Nigeria.

ABSTRACT

Aim: This study assessed the hepatoprotective potential of aqueous stem bark extract of *Boswellia dalzielii* on paracetamol-induced hepatotoxicity in adult rabbits.

Study design: Fifteen adult rabbits weighing between 1.4-2.0kg were divided into five groups (I, II, III, IV and V), where group I served as normal control, group II was the test control, while groups III, IV and V served as test groups. Paracetamol (3.24g/kg was administered to the test control and the test groups to induce hepatotoxicity. Groups III, IV and V were treated for 7 days with 25mg/kg Silymarin, 150mg/kg and 225mg/kg/Body weight of *Boswellia dalzielii* stem bark extract respectively, while group II was left untreated and served as the test control.

Place and Duration of Study: Department of Biochemistry, Faculty of Basic Medical Sciences, College of Health Sciences, Bayero University Kano between August and November, 2015.

Methodology: Using standard laboratory procedures, liver function was assessed by the assay of alanine aminotransferase (ALT), aspartate aminotransferase (AST), alkaline phosphatase (ALP), total protein (TP), albumin (ALB), total and direct bilirubin (TB and DB). Data was analyzed using one-way ANOVA using SPSS. P values ≤ 0.05 were considered significant.

Results: The two doses of the plant extract showed dose-dependent hepatoprotective effect on Paracetamol-induced hepatotoxicity, as evident by the significant reduction ($P < 0.05$) in serum levels of AST, ALT, ALP and bilirubin alongside with improved histopathological liver sections compared to paracetamol-treated animals.

Conclusion: The aqueous extract of *Boswellia dalzielii* could serve as a good alternative to relieve the toxic effect of paracetamol on rabbit liver. And also, it could provide a suitable source for new drug development.

Keywords: Hepatoprotective, Bosweillia dalzielli, Paracetamol, Hepatotoxicity, Histopathology.

E-mail address: aminasaid02@yahoo.com

1. INTRODUCTION

The liver is a vibrant organ found in vertebrates and some animals, and is characteristically the principal visceral organ. One of the major functions of the liver is the transformation and clearance of chemicals and it is highly susceptible to toxicity from these chemicals. Some pharmaceutical agents may injure the liver even when taken in therapeutic doses not necessarily when taken in overdoses. [1] Drug-induced liver diseases are caused by both prescribed medications, over-the-counter medications, illicit drugs, herbs etc through a range of mechanisms. [2] These diseases are mainly caused by hepatotoxic chemicals (acetaminophen, carbon tetrachloride and alcohol), infections and autoimmune disorders. The hepatotoxic chemicals caused damage to liver cells mainly by inducing lipid peroxidation and other oxidative damages. [3]

Medicinal plants are of great importance to individual's health of and the community at large. The main objective strategy in the management of liver diseases is to terminate the sequential consequences at the pre-fibrotic stage of the liver. [4] Naturally based compounds are now employed in the effective treatment of certain liver disease, this in turn cause contemporary medicines to have little contribution to offer for lessening hepatic diseases. [4] Also, there is an improved consideration in these natural products that may neutralize the harmful effects of environmental or toxic chemical compounds and prevent numerous hepatic disorders in humans. [5]

E-mail address: xyz@abc.com.

Paracetamol is a widely used analgesic and antipyretic drug; it produces acute liver damage in high doses. Paracetamol overdose induces acute liver injury via heightened oxidative stress and glutathione (GSH) reduction. [6]

Boswellia dalzielii Hutch is a tree plant of the savannah forest belonging to the family of "*Burseraceae*". It is commonly known as the "Frankincense tree". The tree has a characteristic smooth, pale brown bark that peels off in ragged papery patches, which on rapping exudes a whitish fragrant resin. It grows up to 13metre high. [7] The tree is planted in the northern parts of Nigeria like Kebbi [8] Kano, [9] Kaduna [10] where the Hausa speaking people refer to it as 'ararrabi'. It is locally abundant in Togo, Cote d' Ivoire, Cameroon, Benin, Ivory coast, Poland, Ghana, Burkina Faso, Nigeria and Czech Republic. [11] The plant is used to treat tuberculosis, [12], gingivitis, [13], skin diseases, digestive disorders, nervous disorders, musculoskeletal disorders, breathing difficulties and certain infections. [14]

In view of the potentials of Bosweillia dalziellii in medicine, the present study was conducted to evaluate the hepatoprotective effect of the aqueous extracts of stem bark of *Bosweillia dalzielii* on liver function using rabbits induced with paracetamol hepatotoxicity.

2. MATERIAL AND METHODS

Drug

Paracetamol tablets BP (500mg) GlaxoSmithkline Consumer Nigeria Plc was purchased from a pharmacy shop.

Collection and Extraction of Plant Sample

The stem bark of *Boswellia dalzielii* was collected from Fagwalawa village of Dambatta Local Government Area, Kano in July 2015. The plant was identified by Baha'uddeen Sa'id Adam, a plant taxonomist in the Department of Biological Sciences, Bayero University, Kano. A herbarium accession number 0362 was deposited at the Department's herbarium. The stem bark was dried under the shade and pulverized into powder.

Bosweillia dalzielii tree and leaf. [15]

Stem bark of *Bosweillia dalzielii*. [15]

Preparation of Plant Extract

Five grams (5g) of the pulverized stem bark of *Boswellia dalzielii* was steeped in 1000ml of distilled water and kept at room temperature for 24 hours. Thereafter, the mixture was filtered using a white silky cloth, the residue was dried and its weight taken.

Animals

Male and female adult rabbits weighing between 1.4 - 2.0kg were obtained from Sheka and Sabongari markets in Kano State. The males were separated from the females and kept in cages They were maintained on feed and in the experimental facility provided standard layer feeds, lettuce, spinach and water *ad libitium* throughout the experimental period. The ethical guidelines regarding animal care as approved by the Institutional Animal Ethics Committee of the Department of Biochemistry, Bayero University, Kano were observed during the study.

Study Design

Fifteen male and female rabbits were divided into five groups of 3 rabbits each. Group 1 did not receive any dose of the extract neither did they receive any induction thus, serves as the normal control, group 2 which served as the test control received 3.24g/kg paracetamol. [16] Then groups 3,4,and 5 which served as the test groups receives 3.24g/kg of paracetamol each and 25mg/kg body weight Silymarin, [17] then 150mg/kg and 225mg/kg of the extract, respectively for 7 days.

Twenty four hours after the last administration, samples of blood were collected from the animals in which serum aspartate aminotransferase (AST), alanine aminotransferase (ALT) and alkaline phosphatase (ALP) activities were determined, and the concentration of bilirubin (direct and total) were also determined.

Biochemical Analysis:

Serum AST, ALT and ALP activities, Albumin, total protein and Bilirubin (total and direct) concentrations were determined using reagents and kits obtained from Randox Laboratories, UK.

Determination of Serum AST and ALT

For serum AST and ALT estimation, reagent blank was prepared by mixing 0.5ml of reagent 1 with 0.1ml of distilled water. While for serum samples, 0.1 ml of each sample was mixed with 0.5ml of reagent. These mixtures were incubated for exactly 30mins at 37ºC, then 0.5ml of reagent 2 was added to both the reagent blank and sample test tubes and allowed to stand for 20mins at 23ºC. Sodium hydroxide (5.0ml) was added and mixed, then absorbance of the samples against the reagent blank was read after 5minutes at 546nm. [18]

Determination of Serum ALP

For each sample, 0.5ml of alkaline phosphatase substrate was dispensed into labeled test tubes and equilibriated to 37ºC for 3 minutes. At timed intervals, 0.05ml of each standard, control, and sample were added to the labeled test tubes and mixed gently. Deionized water was used as sample for reagent blank. The mixtures were incubated for 10minutes at 37ºC and 2.5ml alkaline phosphatase color developer was added to all test tubes and mixed carefully. Absorbance of the coloured solutions was measured at 590nm spectrophotometrically. [19].

Determination of Total Protein

In total protein determination, 0.02ml each of distilled water, standard and serum was pipetted into labeled test tubes. Then 1.0ml of reagent 1 was added to each of the labeled test tubes. The mixtures

were incubated at for 30 minutes at 22ºC. Absorbance of the sample was read against reagent blank at 550nm. [20]

Determination of Albumin

For albumin estimation, 0.01ml each of reagent, standard and sample was pipetted into labeled test tubes. Subsequently, 3.0ml of of BCG (bromocresol green) reagent 1 was added. The mixture was incubated for 5 minutes at 22ºC. Absorbance of the sample was read against reagent blank at 630nm. [21]

Determination of Serum Bilirubin

For estimation of total bilirubin, 200µl of reagent 1, 50µl, 1000µl and 200µl of sample were mixed for each sample and allowed to stand for 20 minutes at 22ºC. Reagent 4 (1000µl) was added to the mixture and allowed to stand at 23ºC for 20 minutes. Absorbance of the sample was read at 578nm against sample blank (A_{TB}).

Total bilirubin (µmol/l) = 185 × A_{TB} (578nm).

For direct bilirubin, 200µl of reagent 1, 50µlof reagent 2, 2000µl of 0.9% NaCl and 200µl were mixed in a cuvette and incubated at 22ºC for 10 minutes. The absorbance of the sample was read at 546nm against sample blank (A_{DB}).

Direct bilirubin (µmol/l) = 246 × A_{DB} (546nm).

Unconjugated bilirubin = Total bilirubin – Direct bilirubin. [22]

Histopathological analysis

The rabbits were sacrificed and the liver was harvested and fixed in 10% formal saline. The biopses of liver of the rabbits were fixed with 10% formal saline, dehydrated with ascending grade of alcohol cleared with toluene, infiltrated with molten paraffin wax. The microtome sections were stained with haematoxylene and eosin staining technique [23].

Statistical analysis

The results obtained were expressed as mean ± SD for each group. Data was statistically analyzed with one-way ANOVA followed by Benforoni multiple comparisons, using Graphpad instat software. *P* value < 0.05 was considered significant.

3. RESULTS AND DISCUSSION

RESULTS

Serum levels of ALT, AST, ALP, Total protein, Albumin, Total and Direct Bilirubin obtained were significantly elevated in the test (paracetamol) control group. The Silymarin treated group (group III) showed significant reduction in AST, ALP, TP and TBil. All treatment groups (group III, IV and V) showed significant reduction in all the parameters when compared to group II with highest reduction recorded in group V (225mg/kg of *B. dalzielii* stem bark aqueous extract). Results were presented in Table 1.

All biochemical parameters recorded at the end of the treatment, showed that, the standard drug (Silymarin) and the plant extracts (150mg/kg and 225mg/kg of *B. dalzielii* stem bark) lowered the elevated levels of liver enzymes following paracetamol administration in comparison to paracetamol-only treated group (group II). The different concentrations (150 and 225mg/kg) of the plant extracts used in the study indicated a dose dependent effect.

Table 1. Effect of aqueous extract of *Boswellia dalzielii* stem bark and Silymarin against paracetamol Induced hepatotoxicity on biochemical parameters.

	ALT (IU/L)	**AST (IU/L)**	**ALP (IU/L)**	**TP (g/dL)**	**ALB (g/dL)**	**TBIL (µmol/L)**	**DBIL ((µmol/L)**
GROUP I (Normal control)	8.50±6.36	8.50±2.12	28.12±4.41	56.78±44.66	30.67±3.46	52.04±4.66	34.26±3.70
GROUP II (Test control)	16.00±6.55	82.50±9.19	38.53±15.72	88.72±25.58	43.61±10.40	77.46±18.14	55.83±41.62
GROUP III (Paracetamol+25 mg/kg Silymarin)	15.33±4.04[a]	74.00±21.21[a,b]	30.20±3.60	82.81±10.48[a]	42.39±14.38[a]	71.23±17.25[a]	53.55±15.09[a]
GROUP IV (Paracetamol + B. dalziellii 150mg/kg)	15.00±11.31[a]	50.33±39.52[a,b]	23.43±2.21[b]	80.05±7.38[a,b]	40.73±1.10[a]	64.73±23.12[a,b]	42.74±8.17[b]
GROUP V (Paracetamol + B. dalziellii 225mg/kg)	10.50±0.07[b]	24.66±15.50[a,b]	6.25±0.00[a,b]	72.67±11.53[a,b]	29.80±6.07[b]	62.51±15.28[a,b]	35.27±3.93[b]

n = 3
a = significant at 95% confidence limit (P<0.05) when compared with the normal control group
b = significant at 95% confidence limit (P<0.05) when compared with the test control group.

The histological findings (H and E) showed normal histological features in the liver hepatocytes of the control group (A) (figure 1), while that of the hepatotoxic control (group II) presented marked degeneration of hepatic cord (B), (figure 2). On the other hand, liver features of the treated groups (III IV and V) showed moderate degeneration of hepatocytes and fibrosis (C) for the group III treated rabbits (figure 3), while the 150mg/kg *Boswellia dalzielii* extract treated rabbits showed milder degeneration of hepatocytes and fibrosis (D) (figure 4). And the 225mg/kg *Boswellia dalzielii* extract treated rabbits showed no degeneration of hepatocytes, hence shows area of fibrosis (E). The hepatoprotective effects of *Boswellia dalzielii* bark extract was confirmed by the comparative histopathological changes presented by the treated groups (III IV and V) in relation to the features presented by group I (control) and group II (untreated).

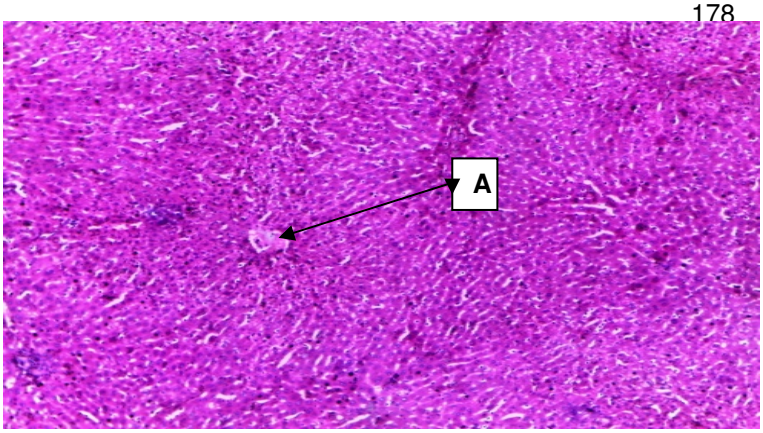

Figure 1 (Group I): Section shows unremarkable liver biopsy with hepatocytes arranged in cord radiating from central vesicles.

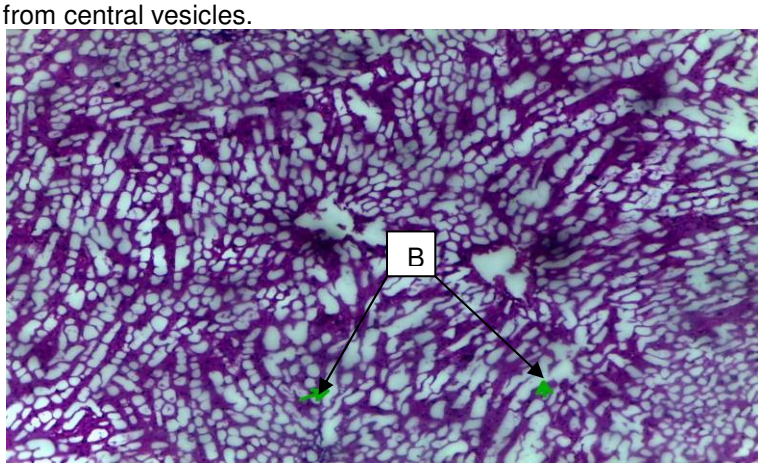

Figure 2 (Group II): Section shows marked degeneration of hepatic cord.

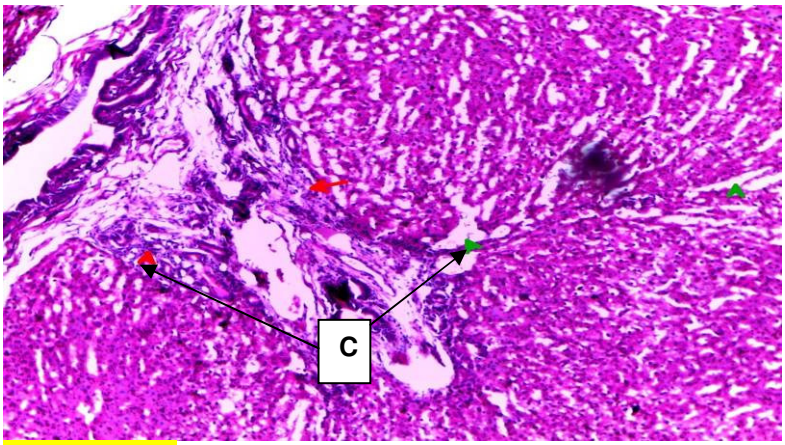

Figure 3 (Group III): Section shows area of moderate degeneration of hepatocytes, and fibrosis

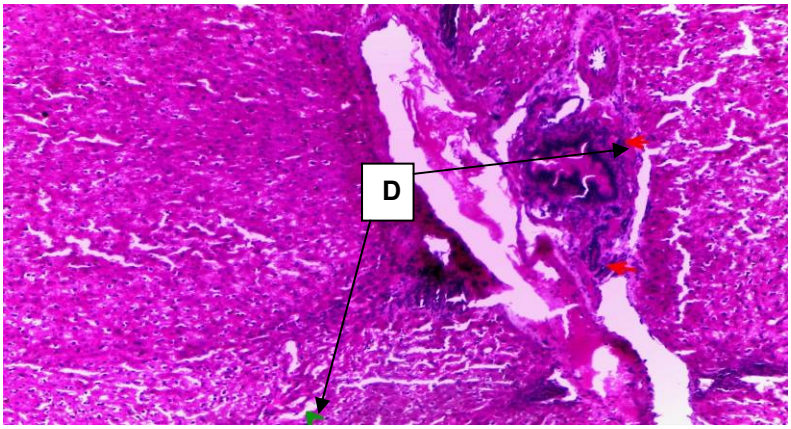

Figure 4 (Group IV): Section shows area of mild degeneration of hepatocytes and fibrosis

Figure 5 (Group V): Section shows areas of fibrosis

DISCUSSION

Generally, damage or injury to the liver impairs protein synthesis and increases serum protein concentration due to leakages from the hepatocytes [24]. The administration of acetaminophen at in this study produced a hepatotoxic effect that resulted in the leakages of these proteins from the hepatocytes into the systemic circulation (Table. 1). This was why these proteins were detected in the serum of the treated animals. It is eminent that all the groups that were given acetaminophen (Groups II, III, IV and V) produced high values of all the parameters when compared to Group I. The result of this study shows that paracetamol elevated the plasma levels of AST, ALT, ALP, total protein, albumin and bilirubin (total and direct) in rabbits. Such elevation is indicative of liver injury [25]. The possibility of these enzymes to change to normal state in the extract-administered groups is a strong indication of hepatoprotective effect of the extract. The results of this investigation indicated that, treatment of rabbits with the aqueous extract of *Boswellia dalzielii* hutch after paracetamol administration caused a decline in hepatotoxicity of the rabbits. This is evidenced in the significant decrease in serum AST, ALT, ALP, TBIL, DBIL, total protein (TP) and albumin (ALB) relative to the paracetamol treated group as shown in the table above.

Paracetamol is a common analgesic that is safe in therapeutic doses. But with overdose it can leads to hepatic necrosis. Induced hepatic injury from paracetamol has been reported in many instances [26-27] and this was justified in view of the hepatocytotoxic indications observed in the liver sections of group II (figure 2) in this study. The hepatotoxic mechanism of paracetamol is said to be mediated through direct liver toxicity of the parent drug or it's metabolites, [26-27] and formation of toxic metabolite; N-acetyl-p-benzoquinone imine. [28] Also, the observed efficacy of stem bark extract in the treatment groups was dose dependent (figures 4 and 5). The reduced hepatic damage by the administration of *Boswellia dalzielii* bark extracts in group III IV and V compared to that of group II, indicates recovery from paracetamol hepatic damage and suggests its healing capacities as well. This finding was in line with other studies in which different types of *Boswellia dalzielii* extracts have showed hepatoprotective activity against CCl_4, ethyl alcohol and diethylnitrosamine [29-31]

4. CONCLUSION

From the results of the study, it could be concluded that, the oral administration of aqueous extract of *B. dalzielii* exhibited it's hepatoprotective potentials on Paracetamol-induced hepatotoxicity in rabbits. Therefore, efficacy, safety, and the possible role of *B. dalzielii* in treatment of liver disorders should be further evaluated by ingenious controlled studies.

ACKNOWLEDGMENTS

This work was partially supported by Department of Biochemistry, Faculty of Basic Medical Sciences, Bayero University Kano.

COMPETING INTERESTS

Authors have declared that no competing interests exist.

AUTHORS' CONTRIBUTIONS

SA'ID A.M designed the study, performed the statistical analysis, wrote the protocol, and wrote the first draft of the manuscript. Ibrahim M.S and Daha I.U managed the analyses of the study. Mashi J.A managed the literature searches. All authors read and approved the final manuscript.

REFERENCES

1. Maity T, Ahmad A. Experimental models and hepatotoxic agents used to study hepatoprotective effect of traditional drugs. Journal of Acute Diseases, 2012 85 – 89.
2. Yuan L, Kaplowitz N. Mechanisms of drug-induced liver injury. Clin Liver Dis 2013; 17:507.
3. Adewusi EA, Afolayan AJ. A review of natural products with hepatoprotective activity. Journal of Medicinal Plants Research., 2010; 4(13): 1318-34.
4. Hamzawy MA, El-Denshary ES, Abdel-Wahhab MA. Effects of natural compounds in treatment and prevention of hepatotoxicity and hepatocellular carcinoma. Hepatoma Res 2015;1:111-8.
5. Hamzawy MA, El-Denshary ES, Hassan NS, Mannaa FA, Abdel-Wahhab MA. Dietary supplementation of calendula officinalis counteracts the oxidative stress and liver damage resultedfrom aflatoxin. ISRN Nutr 2013;2013:538427.
6. Eesha, B.R., MohanbabuAmberkar, V., MeenaKumari K, Sarath B, Vijay M, Lalit M, Rajput R. Hepatoprotective activity of Terminaliapaniculataagainst paracetamol induced hepatocellular damage in Wistar albino rats. Asian Pac J Trop Med 2011; 4: 466-469.
7. Lame Y, Nukenine EN, Pierre DYS, Esimone CO. Larvicidal activity of Annona senegalensis and Boswellia dalzielii leaf fractions against Aedes aegypti (Diptera: Culicidae) Int J Mosq Res. 2014;1(4):25–29.
8. Ethuk EU, Agale BM, Onyeyili PA, Ottah CU. Toxicological studies of aqueos stem bark extract of boswellia dalzielii in albino rats. Indian J. pharmacology, 2006-38: 359-360.
9. Nwinyi FC, Binda L, Ajoku GA, Anyagu SO, Enwerem SM, Orisadipe A, Kubmarawe D, Gamaniel KS. Evaluation of the aqueous extract of Boswellia dalzielii Stem bark for antimicrobial activities and gastro intestinal effects. African journal of biotechnology, 2004 3(5), 284-288.
10. Hassan HS, Musa AM, Usman MA, Abdulaziz M. Preliminary phytochemical and antiplasmodic studies of the stem bark of boswellia dalzielii. Nigerian J.pharmaceutical sci, 2009 8(1), 1-6.
11. Farida A. Pharmacological evaluation of three locally used medicinal plants against carbon tetrachloride-induced hepatotoxicity in rats; 2012 p. 118.
12. Kubmarawa D, Akiniyi JA, Okorie DA. Ethnomedicinal survey of the traditional medicine of Lala people of Nigeria. Int J Med Plants Altern Med. 2013;1(3):039–057.
13. Henley-Smith CJ, Botha FS, Lall N. The use of plants against oral pathogens. Formatex. 2013;30:1375–1384.
14. Zerbo P, Compaore M, Meda NTR, Lamien-Meda A, Kiendrebeogo M. Potential medicinal plants used for by traditional healers in western areas of Burkina Faso. World J Pharmacol Pharm Sci. 2013;2(6):6706–6719.
15. West African Plants, A photoguide – *Bosweillia dalzielii*. 2012.
16. Sajedianfard J, Saeb M, Edalatpisheh M. Therapeutic effect of cimetidine on acetaminophen-induced hepatotoxicity in rabbits Comparative Clinical Pathology; 2009, Vol. 18 Issue 3, p325
17. Musab AM, Imad MT, Abd-elwahab HM, Hozeifa MH (2015). Hepatoprotective effect of adansonia digitata L.(baobab) fruits pulp extract on ccl4-induced Hepatotoxicity in rats.

18. Reitman S, Frankel S. A colorimetric method for the determination of serum glutamic oxalacetic and glutamic pyruvic transaminases. Am J Clin Pathol. 1957 Jul;28(1):56–63.

19. Roy AV. Rapid method for determining alkaline phosphatse. Clin. Chem. 1970; 16: 431.

20. Smith PK, Krohn RI, Hermanson GT, Mallia AK, Gartner FH, Provenzano MD, Fujimoto EK, Goeke NM, Olson BJ, Klenk DC. Measurement of protein using bicinchoninic acid. Anal Biochem. 1985;150(1):76-85.

21. Varley H. Practical Clinical Biochemistry, 5th edn. William Hienemann Medical Books Ltd., London, 1980 pp 550-5.

22. Jendrassik L, Grof PA. Colorimetric method for the determination of direct and total bilirubin. Journal of Ethnopharmacology. 1981; 33: 213 - 216.
23. Auwioro OG. Histochemistry and tissue pathology techniques. 2010: 2nd Edition
24. Rajesh SV, Rajkapoor B, Kumar RS, Raju K. Effect of Clausenadentata (Willd.) M. Roem. Against paracetamol induced hepatotoxicity in rats. Pak. J. Pharm. Sci. 2009 22(1):90–93.
25. Patrick-Iwuanyanwu KC, Onyeinke EN, Wegwu MO. Hepatoprotective effect of methanolic extract and fractions of African mistletoe (Tapinanthus bangwensis) from Nigeria. EXCLI J. 2010 9,187-194.`
26. Schnellmann RG. Toxic responses of the kidney. In: Casarett and Doull's Toxicology. Basic Science of Poisons. McGraw-Hill Medical Division. New York. 2001 Pp. 491-514.
used by the Garo tribal community living in Netrakona district, Bangladesh.
27. Bessems JG, Vermeulen NP. Paracetamol (acetaminophen)-induced toxicity: molecular and biochemical mechanisms, analogues and protective approaches. Crit Rev Toxicol; 2001; 31: 55-138.
28. Lee D, Marks J. Tylenol liver damage. Why should we know that the generic name of Tylenol is acetaminophen? 2007. Retrieved September 4, 2009 from www.medicinenet.com/tylenol_liver_damage/page2.htm
29. Bhakta T, Banerjee S, Mandal SC, Maity TK, Saha BP, Pal M. Hepatoprotective activity of Cassia fistula leaf extract. Phytomedicine. 2001(8): 220–224.
30. Rani SM, Emmanuel S, Sreekanth RM, Ignacimuthu S. Evaluation of in vivo antioxidant and hepatoprotective activity of Cassia occidentalis linn. against paracetamol induced liver toxicity in rats. International Journal of Pharmacy and Pharmaceutical Sciences; 2010 2 (3): 67 – 70.
31. Sastry VS, Girija Sastry V, Appalanaidu B, Srinivas K, Annapurna A. Chemical and pharmacological evaluation of aqueous extract of seeds of Cassia occidentalis. J. Chem. Pharm. Res. 2011 3(2):566-575