Hepatoprotective activity of *Nigella sativa* oil against Antitubercular drug-induced Hepatotoxicity in Rats

Shazia Wahid[a], Parvaze Ahmad Wani[b*], Nazia Wahid[c] , Neelofar Jan[d]

[a]Department of Pharmacy, Integral University, Lucknow, India

[b]Department of Biological Sciences, College of Natural and Applied Sciences, Crescent University, Abeokuta, Ogun State, Nigeria

[c]Department of Applied Statistics Baba Sahib Bhim Rao Ambedkar University Lucknow UP India

[d]Alamdar Memorial College of Nursing and Medical Technology, Islamic University of Science and Technology, Srinagar Kashmir, India

[*]Correspondence to

Parvaze Ahmad Wani

ABSTRACT

AIM: Drug induced hepatotoxicity is a potentially serious adverse effect of the currently used antitubercular chemotherapeutic regimens containing isoniazid (INH) and rifampicin. The aim of this study is to check the hepatoprotective action of *Nigella sativa* against the antitubercular drugs (Rifampicin and Isoniazed)-induced hepatotoxicity in rats.

PLACE AND DURATION OF STUDY: This study was carried out in the Department of Pharmacy, Integral University, Lucknow, UP, India in the year 2011.

METHODOLOGY: *Nigella Sativa* oil was purchased from local market of Lucknow India with assured quality in the month of January, 2011 and study was performed in same year. Powder form of drugs like Rifampicin and Isoniazid were gifted by Cadila Pharmaceuticals limited, Ahmedabad, Gujarat, India whereas 24 Albino rats (Wistar strain) female, weighing 120–150 g, were procured from the Animal House Facility, Integral University, Lucknow. Rats were divided into four groups; first group which is an untreated control was given only standard diet. Second group was treated with *Nigella sativa*, which served as drug control. Third group were treated with 100 mg of each Isoniazid and Rifampicin/kg of body weight. In fourth group rats were treated with *Nigella sativa* oil and 100 mg of Isoniazid and Rifampicin/kg of body weight. At the end of dosing, serum was used for estimation of marker enzymes like aspartate aminotransferase (AST), lactate dehydrogenase (LDH), alanine aminotransferase (ALT), alkaline phosphatase (ALP) and total and direct bilirubin. Grading of treated and untreated liver was also done.

RESULTS: This study showed that *Nigella sativa* acted as antiinflammatory and antinecrotic in isoniazid and rifampicin administered drugs in rats. When *nigella* sativa was coadminstered with Rifampicin + Isoniazid, it resulted in the dearease of these marker enzymes and maintained these enzymes at normal levels in the serum of rats compared to the only Rifampicin + Isoniazid administered rats thus indicates the hepatoprotective action of *Nigella sativa*.

CONCLUSIONS:

Due to above properties of *Nigella sativa* can be used as hepatoprotective against antitubercular drugs.

Keywords: *Nigella sativa*, hepatoprotective, antioxidant activity, Rifampicin, Isoniazid, grading of liver, Rats

1. Introduction

Liver is the only organ in the body that can easily replace damaged cells, but if enough cells are lost, the liver may not be able to meet the needs of the body. Liver is considered as a factory whose functions include 1) production of bile which is required for the digestion of food particularly fats 2) conversion of the extra glucose into glycogen in the liver cells and then converting it back into glucose when the need arises 3) production of blood clotting factors and amino acids including those used to fight infection 4) processing and storage of iron necessary for the production of red blood cells 5) manufacture of cholesterol and other chemicals required for fat transport 6) conversion of waste products produced by the metabolism of the body into urea that is excreted in the urine and 7) metabolization medications into their active ingredient in the body [1].

The causes of liver disease include infection, injury, exposure to drugs or toxic compounds, an autoimmune process, or a genetic defect that leads to the deposition and build-up of damaging substances such as iron or copper which may result in inflammation, scarring, obstructions, clotting abnormalities, and liver damage [2, 3].

Most antituberculous drugs, with the notable exception of streptomycin, are prone to cause liver injury. The hepatotoxic potential of isoniazid alone is well established, while data on the hepatotoxicity of rifampicin, pyrazinamide, and ethambutol are difficult to interpret since these drugs are almost always used in different combinations. The evidence supporting possible hepatotoxic interaction between rifampicin and isoniazid is circumstantial [4]. Drug induced hepatotoxicity is a potentially serious adverse effect of the currently used antitubercular chemotherapeutic regimens containing isoniazid (INH) and rifampicin [3]. Adverse effects of antitubercular therapy are sometimes enhanced when multiple drugs are used. INH and rifampicin used alone are itself most hepatotoxic, but when these drugs are used in combination, their toxic effect is enhanced. The conversion of monoacetyl hydrazine, a metabolite of INH, to a toxic metabolite via cytochrome P450 leads to hepatotoxicity. Patients who are on concurrent rifampicin therapy have an increased incident of hepatitis [5].

This toxicity is due to rifampicin-induced cytochrome P450 enzyme-induction, causing an increased production of toxic metabolites from acetyl hydrazine (AcHz). Other investigators demonstrated that rifampicin increases the metabolism of INH to isonicotinic acid and hydrazine, both of which are hepatotoxic. The plasma half life of AcHz (metabolite of INH) is shortened by rifampicin and AcHz is quickly converted to its active metabolites by increasing the oxidative elimination rate of AcHz, which is related to the higher incidence of liver necrosis caused by INH and rifampicin in combination. Rifampicin induction of the hydrolysis pathway of INH metabolism into the hepatotoxic metabolite hydrazine was reported [4]. The currently used drugs (rifampicin and isoniazid) results in the production of free radicals in excess of basal rates that damage lipids, DNA and proteins [6, 7, 8]. Isoniazid and rifampicin treatment in experimental animals enhances lipid peroxidation, indicating increased oxidative stress in liver [9]. Generation of free radicals may be the basis of many human diseases. A number of liver like subclinical icteric hepatitis to necroinflammatory hepatitis, cirrhosis and carcinoma are associated with the redox imbalance and oxidative stress [3, 10, 11].

The seed of *Nigella sativa* L (NS), an annual *Ranunculaceae* herbaceous plant, known to have many properties in traditional medicine, used as a natural remedy for a variety of complications including liver diseases and also for the treatment of asthma from many centuries in middle East, Northern America, Far East and Asia. The volatile oil contains 18.4-24% thymoquinone which is the main component of the seed and 46% many monoterpenes such as p-cymene, and α-pinene. Recently conducted clinical and experimental research showed many therapeutic effects of NS extracts such as immunomodulator, anti-inflammatory [12, 13] and anti-tumour [14]. It has been reported that *Nigella Sativa* Oil (NSO) could diminish the CCl4-induced hepatotoxicity, the doxorubicin-induced cardiotoxicity and the harmful effects of some chemicals [15, 16]. Many studies showed that *Nigella sativa* plays a protective and antioxidant role [17, 18]. Based on the above facts, the present study was designed to investigate the hepatoprotective action of *Nigella sativa* oil against the antitubercular drug-induced hepatotoxicity in rats.

1. Materials and Methods

1.1. Collection of *Nigella sativa* oil, drugs and rats

Nigella Sativa oil wan purchased from local market of Lucknow India with assured quality in the month of January, 2011 and study was performed in the year 2011. The powder form of drugs like Rifampicin and Isoniazid were gifted by Cadila Pharmaceuticals limited, Ahmedabad, Gujarat, India whereas 24 Albino rats (Wistar strain) female, weighing 120–150 g, were procured from the Animal House Facility, Integral University, Lucknow. The animals were kept in polypropylene cages (6 in each cage) under good laboratory conditions (12 hr light and 12 hr dark at day and night cycle) and had a free access to appropriate diet and tap water. The temperature of animal house was maintained at 25 ± 2℃ & relative humidity at (50 ± 15 %).

1.2. Treatment of animals

The rats were divided into four groups. Each group consisted of 6 animals. The first group is the untreated control was given only the standard diet daily for a period of 30 days. The second group of animals was treated with *Nigella Sativa* oil (1 ml/kg-body weight) daily orally for 30 days served as drug control. In the third group the animals were treated with 100 mg Isoniazid/kg body weight plus 100 mg rifampicin /kg body weight daily for a period of 30 days. In group fourth, the animals were treated simultaneous with *Nigella Sativa* oil (1 ml/kg-body weight) plus two antitubercular drugs (100 Isoniazid/kg body weight and 100 mg Rifampicin/kg body weight) orally daily for 30 days. Ethical clearance was obtained from Institutional Animal Ethical Committee (IAEC), IU/Pharm./M.Pharm./CPCSEA/10/27 Faculty of pharmacy Integral University, Dasauli, P.O. Bas-ha Kursi Road; Lucknow – 226026 (U.P), India.

1.3. Biochemical determination

At the end of 24 hours of the 30 days of treatment, rats in each treated and un-treated groups were sacrificed and blood was collected by retro orbital puncture from all the treated

and untreated animals without any anticoagulant with the help of a 2 ml syringe under the anesthesia of light ether and the room temperature was used to clot the blood upto a period of 30 minutes. The serum was separated by centrifugation at 3000 rpm at 30℃ for 15 minutes and used for the estimation of biochemical enzymes like aspartate aminotransferase (AST), lactate dehydrogenase (LDH), alanine aminotransferase (ALT), alkaline phosphatase (ALP) by the method of Reitman and Frankel [19] and Kind and King [20] and total and direct bilirubin by the method of Mallory and Evelyn [21] using the diagnostic kits (Oscar Diagnostic Services Pvt. Ltd., New Delhi India).

1.4. Light Microscopic Observation

The Liver with and with out the treatment of the drugs and *N. sativa* oil were dissected, chilled and perfused with Ice-cold saline at the end of the 30th day of treatment. The tissue was kept for 48 hours in 10% formalin. The specimens were dehydrated in ascending grades of ethanol and cleared in xylene and then embedded in paraffin wax. Sections of about 5 µm were cut and then stained with hematoxylin and eosin for examination by light microscopy.

1.5. Statistical Analysis

Data of the measured parameters were subjected to analysis of variance (ANOVA One way) and significant partial difference (LSD) was calculated at 5% probability level. Significant difference among the treatments was calculated using Duncan's multiple range test. Values indicate mean ± S.D of replicates.

2. Results

2.1. Body Weight and Light Microscopic Observation of Liver

In the present study the authors found the harmful effect of Rifampicin and Isoniazid drugs on rat liver and the possible ameliorating effect of *N. sativa* treatment in those animals. The body weight of control and treated animals varied among treatments (from day first which is initial weight and last day (30th day which is final weight) (Table 1). The body weight of Rifampicin+Isoniazid treated rats significantly increased compared to control animals. The body weight of *N. sativa* and Rifampicin+Isoniazid treated rats did not increase significantly

compared to the only drug (Rifampicin+Isoniazid) treated rats (Table 1). The light microscopic examination of the liver revealed that the drug (Rifampicin+Isoniazid) treated rats showed scar formation and necrotic lesions in the liver compared to the *Nigella sativa* and Rifampicin+Isoniazid treated rats which showed less inflammation, yellowish colour and necrotic lesions (Fig. 1).



Control Normal, No lesions

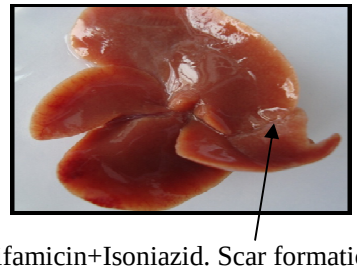

Rifamicin+Isoniazid. Scar formation, Necrosis and inflammation

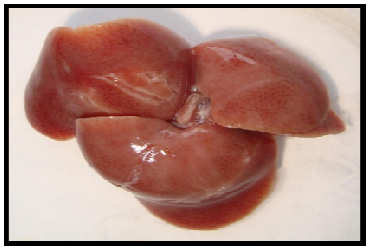

Drug control *Nigella Sativa* No lesions.

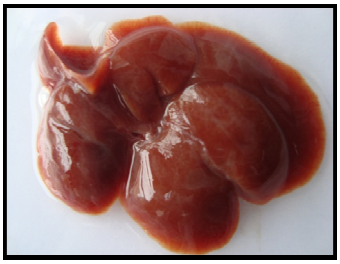

Nigella Sativa+Rifamicin+Isoniazid. Inflammation and Yellowish in portal and lobular area, Necrosis

Fig. 1. Effect of treatment with *N. sativa*, Rifampicin and Isoniazid either alone or in combination on the liver of rats

Table 1. Weight of rats (g) before and after treatment with the drugs and *Nigella sativa*

Weight of Rats	**Treatment of Rats**			
	Control	*N. sativa* (drug control)	Rifampicin + Isoniazid	*N. Sativa* + Rifampicin + Isoniazid
Initial Weight	125± 3.2	127 ± 2.9	122± 2.4	129± 2.7
Final Weight	127± 3.1	128 ±3.3	145* ± 3.5	132± 3.1
LSD	10.2	11.4	11.1	9.7

* Significantly different from control at $p \leq 0.05$; Values indicate mean ± S.D of replicates

2.2. Biochemical Determination

The results of this study showed that the marker enzymes like AST, ALT, LDH, ALP and bilirubin significantly increased in the serum of Rifampicin + Isoniazid antitubercular drugs-administered rats as compared to normal controls rats (Table 2). But when *nigella* sativa was coadminstered with Rifampicin + Isoniazid, it resulted in the dearease of the liver enzymes and maintained them at normal levels in the serum of rats compared to the only Rifampicin + Isoniazid administered rats thus showed the hepatoprotective action of *Nigella sativa* (Table 2).

Table 2. Effect of *Nigella. sativa* on the biochemical activity in the serum of control and drug administered rats.

Treatment of Rats	**Production of Marker Enzymes**				
	Alanine aminotransferase (IU/L)	Aspartate aminotransferase (IU/L)	lactate dehydrogenase (IU/L)	alkaline phosphatase (IU/L)	Bilirubin (Total) (mg/dl)
Control	9.18d ± 0.4	76.1d ± 0.4	1089 d± 14.3	106.8d ± 0.6	0.48d ± 0.1
N. sativa (drug control)	19.40c ± 0.5	53.01[c] ± 0.3	1227c ± 16.6	119.1c ± 0.4	0.65c± 0.1
Rifampicin + Isoniazid	28.59[a] ± 0.3	105.7[a] ± 0.5	2113a ± 20.9	219.8 a± 0.3	1.1a ± 0.1
N. Sativa + Rifampicin + Isoniazid	23.02[b] ± 0.6	65.58[b] ± 0.3	1584b ± 19.5	156.1b ± 0.3	0.87b ± 0.1
LSD ($p \leq 0.05$).	4.3	8.5	55.6	11.4	0.33

Within columns, means followed by the different letter are significantly different according to Duncan's multiple range test ($p \leq 0.05$).

3. Discussion

Liver, an organ responsible for metabolism of toxins, can sometimes generate reactive oxygen species (ROS) [22] is susceptible to pesticides, food additives, pharmaceuticals, and industrial waste [23]. Rifampicin and Isoniazid can cause cellular, molecular, and biochemical changes [3-5]. Lots of liver damages ranging from subclinical icteric hepatitis to necroinflammatory hepatitis, cirrhosis and carcinoma have been proved to be associated with the redox imbalance and oxidative stress [3, 10, 11] .

Rifampicin and Isoniazid are well known liver carcinogen which introduces certain changes in the liver [5, 12]. In this study, we found the harmful effect of Rifampicin and Isoniazid on rat liver and the possible ameliorating effect of *N. sativa* treatment in those rats. The body weight of *N. sativa* and Rifampicin+Isoniazid treated rats did not increase significantly compared to the only drug (Rifampicin+Isoniazid) treated and control rats. Drug administration also showed more scar formation and necrotic lesions in the liver compared to the *Nigella sativa* and Rifampicin+Isoniazid treated rats. The similar results were shown by Mohamed et al., [24] who observed a decrease in the weight of liver of the animals treated with a hepatoptotective agent and drugs and also found less necrotic lesions compared to control animals. Our results are also in agreement with the results of Desmet and Fevery [25] and Bedossa and Poynard [26] who also found the same results as in our study.

Antibiotic therapy favors the production of free radicals in excess of basal rates. Many antibiotics that depend on bound metals for their activity are able to generate free radicals and cause cellular damage [6, 7]. The combination of isoniazid and rifampicin treatment in experimental animals enhanced lipid peroxidation, indicating increased oxidative stress in liver [9]. Antioxidants are necessary for preventing the formation of free radicals and they inhibit some of the deleterious actions of reactive oxygen species that damage lipids, DNA and proteins [8]. It is reported that compounds isolated from *N. Sativa* (including thymoquinone, carvacol, tanethole and 4- terpineol) have good free radical scavenging properties [16] which could be the reason in our study that the *N. Sativa* reduced the toxicity of these harmful drugs. Generation of free radicals may be the basis of many human

diseases. Therefore, the antioxidant action of *N. sativa* may explain its claimed usefulness in folk medicine. This antioxidant property would explain its action against hepatotoxicity [17], liver fibrosis and cirrhosis [27], and hepatic damage induced by Schistosoma Mansoni infection [28]. There are many reports that support the use of antioxidant supplementation for reducing the level of oxidative stress and in slowing or preventing the development of complications associated with diseases [29]. Recently there has been an interest towards the use of natural antioxidants to prevent oxidative damage [29]. In the same time, flavonoids and other phenolic compounds of plant origin are reported as scavengers and inhibitors of lipid peroxidation [30]. Fruits and vegetables which are reported to contain natural antioxidants can provide a sufficient protection thus can slow down the process of oxidative damage caused by reactive oxygen species (ROS) [31]. Among the promising medicinal plants, *N. sativa*, an amazing herb with rich historical and religious background are the source of the active ingredients of this plant [32]. A majority of the studies on *N. sativa* have confirmed its antitoxic properties both *in vitro* and *in vivo* [32].

Nigella Sativa is hepatoprotective probably due to the antioxidant nature by blocking isoniazid- and rifampicin-induced lipid peroxidation. The results of this study showed that the marker enzymes like AST, ALT, LDH, ALP and bilirubin significantly increased in the serum of Rifampicin + Isoniazid antitubercular drugs-administered rats as compared to normal controls rats (Table 2). But when *Nigella* sativa (Table 2) was coadminstered with Rifampicin + Isoniazid, it resulted in the decrease of these marker enzymes and maintained these enzymes at normal levels in the serum of rats compared to the only Rifampicin + Isoniazid administered rats thus indicates the hepatoprotective action of *Nigella sativa* [33]. Similar results were also found by Mahesh *et al*., [34], who found protective effect of Indian honey on acetaminophen produced oxidative stress and liver toxicity in rat. The protective action of *nigella sativa* against these antitubercular drugs-induced necrotic damage could be probably due to the membrane stabilizing action [35]. The findings of this study are in agreement with the study of El-Dakhakhany *et al*., [36] who reported that the daily administration of *N. sativa*

oil (800 mg/kg orally for 4 weeks) did not adversely effect the serum transaminases, alkaline phosphatase or bilirubin. In another study Turkdogan *et al*., [37] found that the *N. sativa* resulted in successful prevention of liver fibrosis in rabbits and that its oil may play a role against liver damage induced by *Schistosoma mansoni* infection in mice [28].

4. Conclusions

This study showed that the isoniazid and rifampicin increased the marker enzymes significantly in the liver of the rats compared to the control rats, thus showed hepatotoxic activity and can damage the liver of the rats. But when *N. sativa* oil was used against these hepatotoxic drugs, decreased the marker enzymes significantly in the liver compared to the only isoniazid and rifampicin treated rats. Due to the above properties shown by *Nigella sativa* can be used as hepatoprotective against antitubercular drugs.

Funding

There was no funding for this project

Competing interest: Authors do not have any competing interests

References

[1]. Chaffee EE, Greisheimer EM. Basic physiology and anatomy. 3rd (Eds), JB Lippincott Company Philadelphia, 1974

[2.]. Rana SV, Attri S, Vaiphei K, Pal R, Attri A, Singh K. W J Gastroenterol. 2006; 12: 287–91.

[3]. Usmani A, Mujahid M, Khushtar M, Siddiqui HH, Rahman MA. Hepatoprotective effect of Anacyclus pyrethrum Linn. against antitubercular drug-induced hepatotoxicity in SD rats. Journal of Complementary and Integrative Medicine. DOI 10.1515/jcim-2016-0001.

[4]. Askgaard DS, Wilcke T, Dossing M. Hepatotoxicity caused by the combined action of isoniazid and rifampicin. Thorax. 1995; 50: 213-214.

[5]. Vijaya Padma V, Suja V, Shyamala Devi CS. Hepatoprotective effect of Liv. 52 on antitubercular drug induced hepatotoxicity in rats. Fitoterapia. 1998; 6: 520.

[6]. Doroshow J, Hochstein P. Redox cycling and the mechanism of action of antibiotics in neoplastic diseases. Pathology of Oxygen. Academic Press, New York. 1982; 245–250.

[7]. Georgieva N, Gadjeva V, Tolekova A. New isonicotinoylhydrazones with SSA protect against oxidative-hepatic injury of isoniazid. Trakia J Sci. 2004; 2(1):37–43.

[8]. Eidelman RA, Lamas GS, Hennerkens CH. The new national education program guidelines. Arch Intern Med. 2002; 162: 2033–2036.

[9]. Skakun NP, Slivka Y. The correction of hepatotoxicity of antitubercular preparations with tocopherol acetate and riboxin. Eksp. Klin Farmakol. 1992; 55: 52–54.

[10]. Vrba J, Modriansky M. Oxidative burst of Kupffer cells: Target for liver injury treatment. Biomed Pap. 2002; 146: 15-20.

[11]. Chen X, Xu J, Zhang C, Yu T, Wang H. The protective effects of ursodeoxycholic acid on isoniazid plus rifampicin induced liver injury in mice. Eur J Pharmacol. 2011; 659:53–60.

[12]. Houghton PJ, Zarka R, De las Heras B, Hoult RS. Fixed oil of *Nigella sativa* and derived thymoquinone inhibit eicosanoid generation in leukocytes and membrane lipid peroxidation. Planta Med. 1995; 61:33–6.

[13]. Mutabagani A, El-Mahdy SAM. A study of the anti-inflammatory activity of *Nigella sativa* L. and thymoquinone. Saudi. Pharm. J.1997; 5:110–113.

[14]. El-Daly ES. Protective effect of cysteine and vitamin E *Crocus sativus* and *Nigella sativa* extracts on cisplatin-induced toxicity in rats. J Pharm Belo. 1998; 53: 87-95.

[15]. Mansour MA. Protective-effects of thymoquinone and desferrioxamine against hepatotoxicity of carbon tetrachloride in mice. Life Sci. 2000; 66: 2583-2591.

[16]. Burits M, Bucar F. Antioxidant activity of *Nigella sativa* essential oil. Phytother. Res. 2000; 14: 323-328.

[17]. Nagi MN, Alam K, Badary OA, *al*-Shabanah OA, *al*-Sawaf HA. Thymoquinone protects against carbon tetracholide hepatotoxicity in mice via an antioxidant mechanism. Biochem Mol Biol Int. 1999; 47:153–159.

[18]. Jadhav, R. and Mateenuddin, M., 2013. Effect of Nigella Sativa Oil on Hepatotoxicity Induced by Antitubercular Drugs in Albino Rats. Indian Medical Gazette—APRIL, 147.

[19]. Reitman S, Frankel S. *In vitro* determination of tranaminase activity in serum. Am J Clin Pathol. 1957; 28: 56.

[20]. Kind PRN, King EJ Estimation of plasma phosphatase by determination of hydrolysed phenol with amino antipyrine. J Clin Pathol. 1954; 7: 322.

[21]. Mallory HT, Evelyn EA. The determination of bilirubin with photoelectric colorimeter. J Biol Chem. 1937; 119: 481-485.

[22]. Fernandez-Checa JC, Kaplowitz N. Hepatic mitochondrial glutathione: Transport and role in disease toxicity. Toxicol Appl Pharm. 2005; 204: 263-273.

[23]. Ward JM, Shibata MA, Devor DE. Emerging tissue in mouse liver carcinogenesis. Toxicol Pathol. 2005; 24: 129-137.

[24]. Mohamed HA, El-Sayed IH, Moawad M. Protective effect of *Nigella sativia* seeds against dimethylaminoazobenzene (DAB) induced liver carcinogenesis. Nat Sci. 2010; 8: 80-87.

[25]. Desmet V, Fevery J. Liver Biopsy. In: Hayes PC eds. Baillieres Clinical Gastroenterology. International Practice and Research. Investigations in Hepatology. London: Baillière Tindall. 1995; 9: 811-828.

[26]. Bedossa P, Poynard T. Cooperative Study Group. An algorithm for the grading of activity in chronic hepatitis C. Hepatology. 1996; 24: 289-293.

[27]. Turkdogan MK, Agaoglu Z, Yener Z, Sekeroglu R, Akkan HA, Avci ME. The role of antioxidant vitamins (C and E), selenium and *Nigella sativa* in the prevention of liver fibrosis and cirrhosis in rabbits, new hopes. Dtscch Tierarzt Wschr. 2000; 108: 71– 73.

[28]. Mahmoud MR, El-Abhar HS, Saleh S. The effect of *Nigella sativa* oil against the liver damage induced by *Schistosoma mansoni* infection in mice. J Ethnopharmacol. 2002; 79: 1–11.

[29]. Kamath V, Joshi AKR, Rajini PS. Dimethoate induced biochemical perturbation in rat pancreas and its attenuation by cashew nut skin extract. J Nutr Biochem. 2008; 90: 58-65.

[30]. Formica JV, Regelson W. Review of the biology of quercetin and related biflavonoids. Food Chem Toxicol. 1995; 33:1061-1080.

[31]. Jacob RA, Burri BJ. Oxidative damage and defense. Am J Clin Nutr. 1996; 63:985S-990S.

[32]. Salem ML. Immunomodulatroy and therapeutic properties of the *Nigella sativa* L. seed. Int Immunopharmacol. 2005; 5:1749-1770.

[33]. Anandan R, Suseela M, Viswanathan NPG. Antiulcerogenic effects of chitin and chitosan on mucosal antioxidant defense system in HCl–ethanol induced ulcer in rats. J Pharm Pharmacol. 2004; 56: 265–269.

[34]. Mahesh A, Shaheetha J, Thangadurai D, Rao DM. Protective effect of Indian honey on acetaminophen induced oxidative stress and liver toxicity in rat. Biologia. 2009; 64: 1225-1231.

[35]. Filipovic-Grcic J, Skalko-Basnet N, Jalsenjak I. Mucoadhesive chitosan-coated liposomes: characteristics and stability. J Microencapsul. 2001; 18: 3–12.

[36]. El-Dakhakhny M, Mady NI, Halim MA. *Nigella sativa* L. protects against induced hepatotoxicity and improves serum lipid profile in rats. Arzneimittelforsch. 2000; 50: 832–836.

[37]. Turkdogan MKZ, Agaoglu Z, Yener R, Sekeroglu HA, Akkan AME. The role of antioxidant vitamins (C and E), selenium and *Nigella sativa* in the prevention of liver fibrosis and cirrhosis in rabbits: new hopes. Dtsch Tieraztl Wochenschr. 2001; 108: 71–73.