Original Research Article

HISTOCHEMICAL EVALUATION OF SOME OF THE EFFECTS OF *Annona muricata* LEAF EXTRACT ON DERMATOPHYTOSIS IN WISTAR RATS: A Pilot Study

ABSTRACT

Aims: This study was carried out to investigate the antifungal activity of the aqueous leaf extract of *Annona muricata* (*A. muricata*), and to analyze its effects on growth and morphology of *Trichonphyton rubrum* (*T. rubrum*) and *Epidermophyton flocossum* (*E. flocossum*) strains respectively.

Study design: The gross observation, histological and histochemical analysis were studied for this research work.

Methodology: Twenty one (21) animals were divided into seven (7) groups, three (3) animals each were allocated to group A-G. Group A was the control, not infected and not treated (ACNINT); group B was *T. rubrum*-infected, and later treated with *A. muricata* (BTRIT); group C was *E. flocossum*-infected, and later treated with *A. muricata* (CEFIT); group D was *T. rubrum*-infected without treatment (DTRIWT); group E was *E. flocossum*-infected without treatment (EFIWT); group F was not infected but treated with *A. muricata* (FNIT) and group G was *T. rubrum*-infected with concurrent *A. Muricata* treatment (GTRICT). 2ml of washed fungal organisms were spilled on shaved, cleaned and disinfected skin of the Wistar rats separately. The dermatophytes were allowed to incubate with noticeable changes, a dose of 100mg/kg body weight of aqueous leaf extract of *A. muricata* were used in the treatment. Animals were sacrificed under chloroform anaesthesia in two batches; post infections (12 days) and treatment (2 weeks). Skin tissues were harvested for both histological and quantitative histochemical analysis.

Results: The histochemical study of melanoaldehyde (MDA), superioxide dismutase (SOD) and total protein (T.P) was done with tissue homogenates, there was an increase in SOD level in BTRIT & CEFIT groups with about 9.21% compared to DTRIWT & EFIWT . Also, the T.P level of BTRIT & CEFIT groups was 4.4% higher compare to DTRIWT & EFIWT . The same rise in level of MDA was recorded in infected and later treated group of BTRIT , but otherwise in CEFIT.

Conclusion: The infected and later treated group had an improved histological integrity compared to infected without treatment. It can be concluded from this study that the aqueous leaf extract of *Annona muricata* has some antifungal effects, though reported to be statistically insignificant in this investigation.

Keywords: *T. rubrum, E. flocossum, A. muricata*, Dermatophytes

INTRODUCTION

Dermatophytes are a fungal group with capacity to invade keratinized tissues (skin, hair, nails) of Man and other animals resulting in dermatophytosis [1]. The incidence of dermatophytosis infection has increased over recent years, particularly in immuno-compromised patients and it is considered the most common and widespread infectious disease worldwide [1]. *Trichonphyton rubrum* is a worldwide pathogen causing various superficial infections, accounting for at least 60% of dermatophytosis, such as *tinea capitis, tinea corporis, tinea inguinalis, tinea manuum, tinea unguium* and *tinea pedis*[2].

Researchers from South and North America, and Europe mentioned this microorganism as one of the most commonly isolated in case of dermatophytosis in these regions and with recognized local resistance to therapy [3]. Dermatophytosis treatment has been a cause of great concern among researchers around the world. This fact is justified by increasing prevalence of these diseases in the world, extensive use of antifungal agents and consequent emergence of fungal strains resistant to the main drugs commonly used in clinical therapy [4]. To overcome this problem, the development of new antifungal products is necessary. In this situation, interest in plants with antifungal properties has increased as a consequence of current problems associated with the antifungal therapy. Since antiquity, medicinal plants have been used to treat common infectious diseases and the essential oils of these plants have been widely used in the treatment of infectious pathologies in many body parts including the skin [5].

The dermatophytes belong to the small category of disease organisms that almost every human alive will be infected by at some point over the course of his or her lifetime. However, identification of individual dermatophytes species causing infection remains important for diagnostic reasons [6].

Plant of interest (Graviola-*Annonamuricata*):

Graviola (*Annonamuricata*) is a small, upright evergreen tree, 5-6m high, with large, glossy, dark green leaves. It produces a large, heart-shaped, edible fruit that is 15-23cm in diameter, is yellow-green in colour, and has white flesh inside. Graviola is indigenous to most of the warmest tropical areas in South and North America, including the Amazon. The fruit is sold in local markets in the

tropics, where it is called Guanabana in Spanish-speaking regions and Graviola in Brazil. The fruit pulp is excellent for making drinks and sherbets and, though slightly sour-acid, can be eaten out of hand [7]. All parts of the graviola tree are used in natural medicine in the tropics, including the bark, leaves, roots, fruit, and fruit seeds. Different properties and uses are attributed to the different parts of the tree. Generally, the fruit and fruit juice are taken for worms and parasites, to cool fevers, as a lactagogue (to increase mother's milk after childbirth), and as an astringent for diarrhoea and dysentery [7]. The crushed seeds are used as a vermifuge and anthelmintic against internal and external parasites, head lice, and worms. The bark, leaves, and roots are considered sedative, antispasmodic, hypotensive, and nervine, and a tea is made for various disorders from those parts [8,9].

Graviola has a long, rich history of use in herbal medicine as well as lengthy recorded indigenous use [7]. In the Peruvian Andes, a leaf tea is used for catarrh (inflamation of mucous membranes) and the crushed seed is use to kill parasites. In the Peruvian Amazon the bark, roots, and leaves are used for diabetes and as a sedative and antispasmodic [8]. Indigenous tribes in Guyana use a leaf and/or bark tea as a sedative and heart tonic. In the Brazilian Amazon a leaf tea is used for liver problems, and the oil of the leaves and unripe fruit is mixed with olive oil and used externally for neuralgia, rheumatism, and arthritis pain [10]. In Jamaica, Haiti and West Indies, the fruit and /or fruit juice is used for fevers, parasites and diarrhoea, and as a lactagogue; the bark or leaf is used as an antispasmodic, sedative, and nervine for heart conditions, coughs, grippe, difficult childbirth, asthma, asthenia, hypertension, and parasites [7,9,11].

MATERIALS AND METHODS

Animals Care: Twenty one (21) healthy Wistar rats (*Rattusnorvegicus*) were used for this research. The animals were acclimatized in the Animal holding of the University of Ilorin, Nigeria. The rats were fed with rat pellets and given water ad libitum.

Plant Material (Annonamuricata): Fresh leaves of Annonamuricata (Linn.) (family: *Annoaceae*) commonly known as 'sour sop' or 'Graviola' in English, and 'Abo' in Yoruba Language, was collected from the Department of Botany, University of Ibadan, Ibadan, Nigeria.

Preparation of Aqueous Leaf Extract: Annona muricata leaves were air-dried at room temperature and milled into fine powder using waring mechanical blender. The powdered leaf then macerated in distilled water 20g/250ml and continuously shaken using an electric shaker for 48 hours. The solution was filtered, and the filtrate was concentrated using an electric rotary evaporator at the Department of Biochemistry, University of Ilorin.

Collection of Dermatophytes: Sub-cultured fungi organisms (*Trichonphyton rubrum*, and *Epidermolphyton flocossum*) were collected from the Department of Microbiology, University of Ilorin. The organisms were washed in 50ml of sterilized distilled water each, and later put on shaker for 48 hours.

Infections and Treatments:

2ml of organism solution was applied on to the shaved skin and left for 12days before commencement of the extract administration. Group G was however, combined infection and treatment concurrently for two weeks.

100mg/kgbwt/day of aqueous leaf extract of *Annona muricata* was given orally for 2 weeks from the 13th day post-infection.

Table 1: Illustrates the infections and administrations of 100mg/kgbwt/day

Group Identity	Adminisration
ACNINT	Control
BTRIT	*T.rubrum* infected, & later treated
CEFIT	*E.flocossum* infected, & later treated
DTRIWT	*T. rubrum*-infected without treatment
EFIWT	*E. flocossum*-infected without treatment
FNIT	not infected but treated
GTRICT	*T. rubrum*-infected & concurrently treated

Excision of the Skins: The animals were sacrificed under chloroform anaesthesia; skin tissues were carefully excised, those for paraffin embedding were fixed in 10% formol-saline for 24 hours, and those for quantitative histochemistry were put in 0.5% sucrose solution.

Histological Procedure: Tissues for histological analysis were processed using Leica TP 1020 Automatic tissue processor and embedded using Leica EG 1160 Embedding system. Sections were cut at 3 microns with a Leica rotary microtome and dried for 30 minutes at 60°C. All sections were stained with Haematoxylin and Eosin (H&E) and Grocott Methenamine (Hexamine) Silver for Fungi. The sections were examined with the light microscope and photomicrographs were taken.

RESULTS

The following are the results of gross observation or physical changes, histological and histochemical analyses.

Observations:

Table 2: Morphological observation of different (fungal and leaf extract) treated rat groups during experimental periods (12 days).

GROUP	OBSERVATION
ACNINT	fur started growing on the 4th day
BTRIT	brownish particle appeared on the 7th day, loss of hair beyond the shaved part of the skin in 9th day
CEFIT	fur started falling from the 7th day & loss of hair beyond the shaved part of the skin on 9th day
DTRIWT	brownish skin and little fur felt on 7th day & loss of hair beyond the shaved part of the skin on 9th day
EFIWT	little brownish skin and fur felt on 7th day & loss of hair beyond the shaved part of the skin in 9th day
FNIT	hair started growing in the 4th day
GTRICT	Fur started growing in the 4th day

Aqueous Leaf Extract of *Annona muricata*-treated (Post Infection):

Table 3: ***A.muricata* Treatment Effects**

GROUP	**OBSERVATION**
ACNINT	hair almost grown in the shaved part of the skin
BTRIT	little fur started growing from the 3rd day
CEFIT	little fur started growing from the 3rd day, the growth became rapid from the 6th day
DTRIWT	fur kept falling
EFIWT	fur kept falling
FNIT	fur kept growing
GTRICT	fur started growing from the 5th day

Quantitative Histochemistry:

Table 4: Quantitative Histochemistry Parameters

Sample Identity (I.D)	MDA (µml/L)	SOD (µ/ml)	T.P (G/L)
ACNINT	16.02	772.01	12.03
DTRIWT	14.01	778.02	12.02
BTRIT	19.03	919.03	15.02
DTRIWT+days	18.04	899.03	12.05
EFIWT	17.02	741.01	13.02
CEFIT	16.03	984.01	16.01
EFIWT +days	20.03	939.02	14.01
FNIT	15.01	852.01	11.03
GTRICT	16.02	843.03	11

Table 5: Statistical Analysis (Using Chi-square):

S/N	MDA	SOD	T.P	Total
BTRIT+ CEFIT	35.05	1903.02	31.01	1969.08
(DTRIWT+days) +(EFIWT +days)	31.06	1519.04	25.07	1576.17
DTRIWT+ EFIWT	38.01	1838.02	25	1901.03
Total	104.12	5260.08	81.08	5446.28

Table 6: Chi-square Test

	X*cal	Degree of freedom	Sig.
Pearson(X*)	0.88	4	0.213

At 5% level of significance, the null hypothesis was accepted.

Histological Observations:

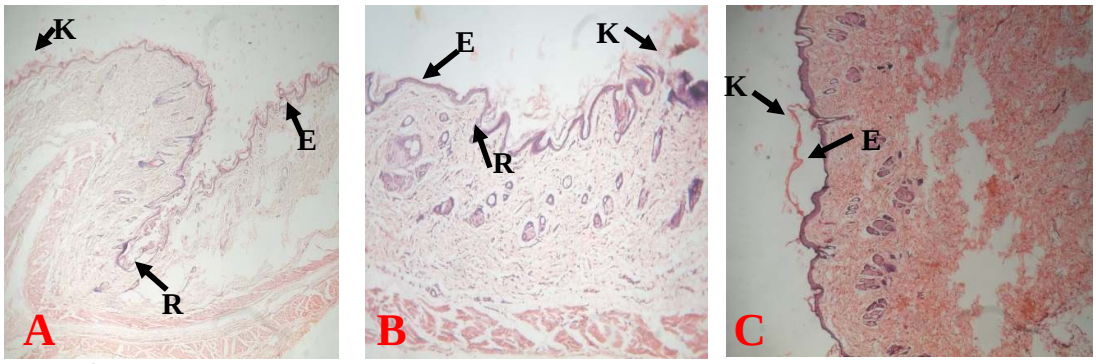

Skin of ACNINT **(A),** EFIWT **(B) and** DTRIWT **(C)Wistar rats (H&E** x100**).**

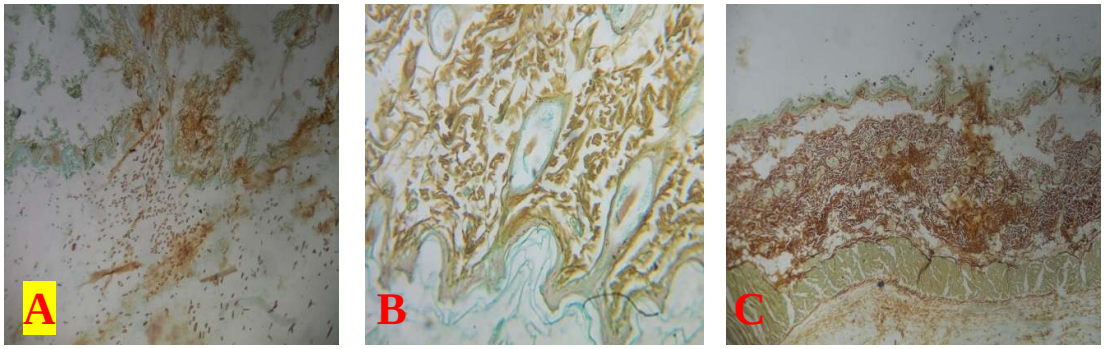

Skin of ACNINT **(A),** EFIWT **(B) and** DTRIWT **(C) .Grocott Methenamine x100.**

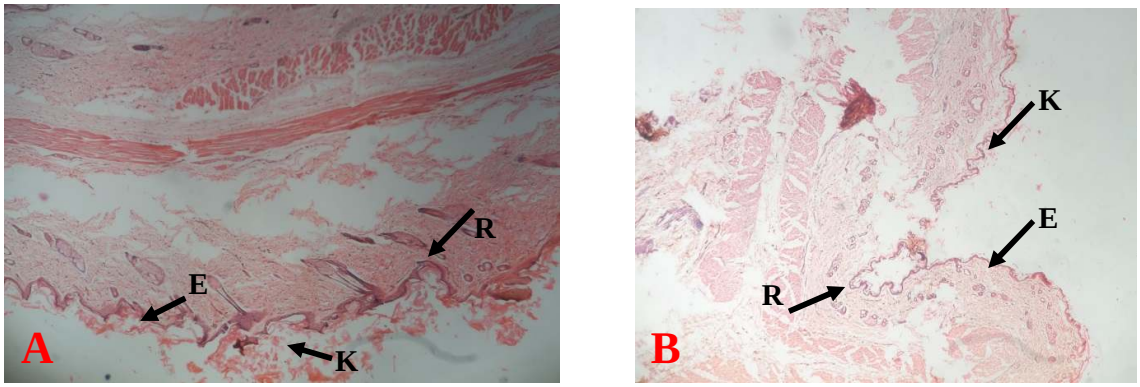

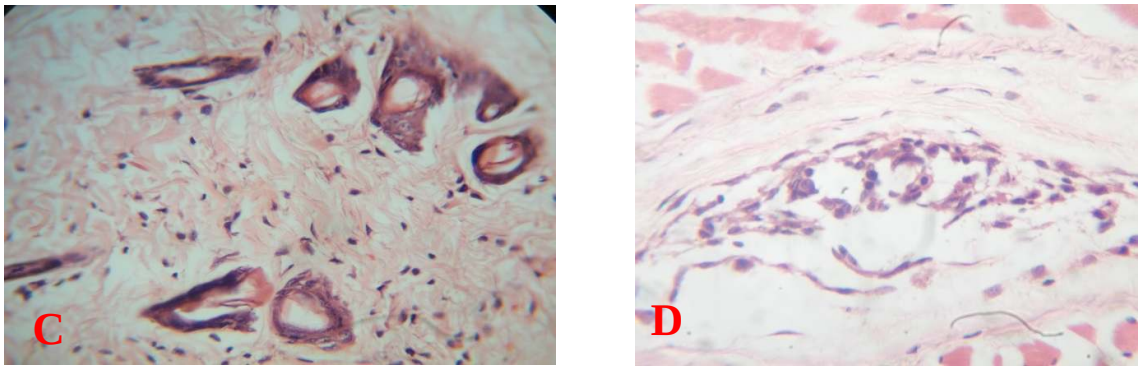

Skin sections of CEFIT **(A&C) and** BTRIT **(B&D). H&E.**

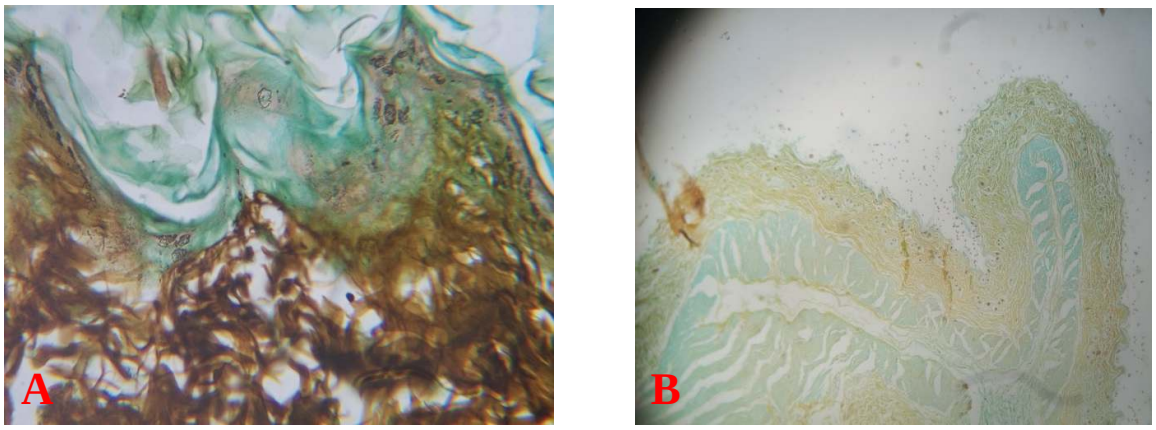

Skin sections of CEFIT **(A) and** BTRIT **(B). Grocott Methenamine x100.**

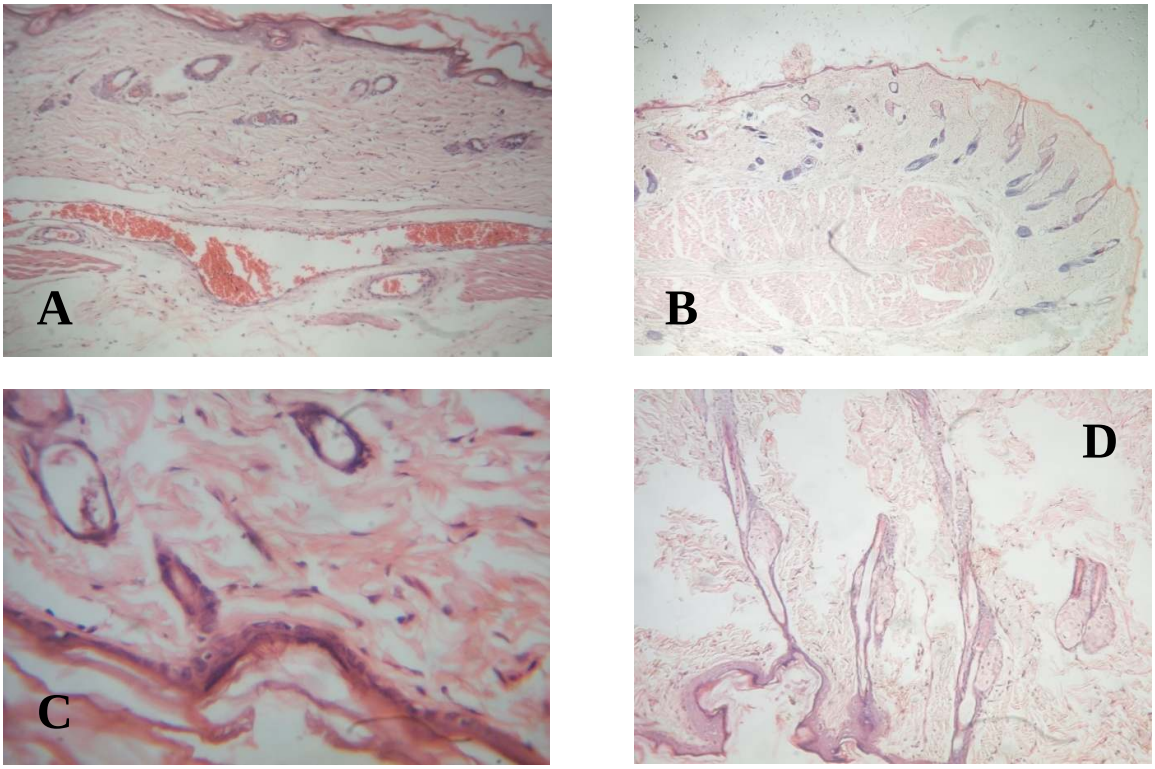

Skin sections of FNIT **(A),** DTRIWT+days **(B),** EFIWT +days **(C) and** GTRICT **(D). H&E x100.**

Histological Analysis:

GRADING ARRANGEMENTS;

EPIDERMAL LAYERS: Poor = 1, Fair = 2, Good = 3, Very Good = 4
KERATIN: Disarranged= 1, Averagely Arranged= 2, Well Arranged=3
RETES RIDGES: Not Hollow = 1, Hollow = 2

Table 7: Grading Arrangement of the Histology of the Skin

GROUP	OBSERVATION		
	EPIDERMIS	KERATIN	RETES RIDGES
ACNINT	4	3	2
BTRIT	3	2	2
CEFIT	2	2	2
DTRIWT	1	1	1
EFIWT	2	1	1
FNIT	4	3	2
GTRICT	2	2	2

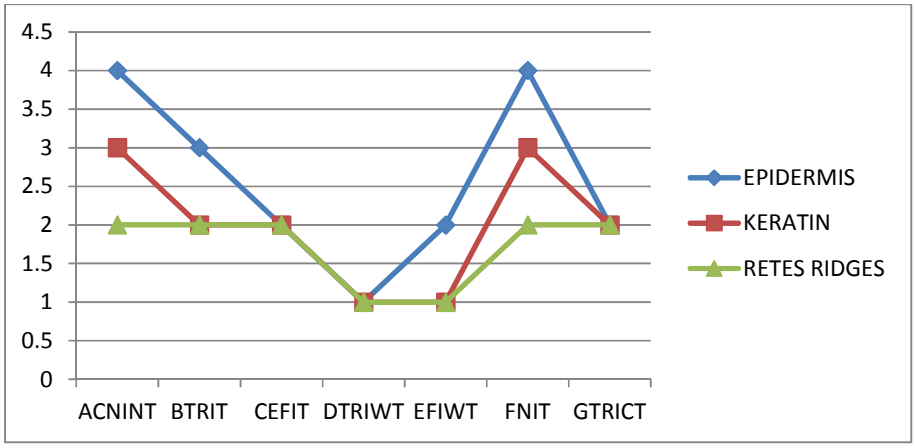

CHART 1: Illustrates histological features of the skin (rat)

DISCUSSION

There were different observations and physical changes with regards to the dermatophytes induced and treatment (*A.muricata*) given, little fur was observed growing from the 3rd day in BTRIT, while fur was rapidly growing from the 6th day in CEFIT contrary to what was observed in both DTRIWT and EFIWT. In quantitative histochemical analysis, having known antioxidant enzymes such as superoxide dismutase (SOD), melanodealdehyde (MDA) and total protein to constitute a mutual supportive team of defence against Reactive Oxygen Species (ROS). The high reactivity of ROS can trigger a host of disorder in biological systems, and endogenous antioxidant enzymes are responsible for preventing or neutralizing the free radical induced damage of tissues [12]. In *T.rubrum*-infected and treated group, the aqueous leaf extract of *A. muricata* was observed to have highest SOD activity against the reactive oxygen species (SOD level in BTRIT & CEFIT groups with about 9.21% compared to DTRIWT & EFIWT), such increment was observed for MDA and TP (as collagen matrix and tissue bundle), T.P level of BTRIT & CEFIT groups was 4.4% higher compare to DTRIWT & EFIWT, this suggested the effect of the aqueous leaf extract used, and the same was observed in *E. flocossum*-infected, and later treated group, though MDA of *E. flocossum* of untreated group remained higher, this suggested that, there could be an anti-oxidation with the organism. For aqueous leaf extract of *A. muricata* treated only and infected-treated group there was no broad statistical significance differences in their SOD, MDA and T.P, which testifies to the effectiveness of the aqueous leaf extract.

Thus, from the statistical analysis which said to be insignificant, this confirms the little effect of aqueous leaf extract on the infected animals, as rightly identified by the demonstration of SOD stress maker above.

However, the general skin appearance in the control group was well arranged and organized at epidermal layer with epidermis, keratin and rete ridges observed contrary to *E. flocossum*-infected and *T. rubrum*-infected groups, and from the graph chart above, it demonstrates how epidermis and the keratin are the most involved features of the histology of the skin in this experiment. The

E.flocossum-infected, and treated was better improved in integrity (in terms of epidermis, keratin and rete ridges arrangements) when compared to *T. rubrum*-infected, and treated group, this suggested that *T. rubrum* could be more infectious than *E. flocossum*. Using Gomori 1946, Grocott, 1955) as a special staining technique for fungi infections. Fungi stained black, but with pale green backgroud indicates normal, the organisms infected showed a profound change at the epidermal layer.

CONCLUSION

It can therefore be concluded that, aqueous leaf extract of *A.muricata* has an antifungal effect, even though reported to be statistically insignificant in this investigation.

ETHICAL APPROVAL

"All authors hereby declare that "Principle of laboratory animal care" (NH publication No. 85-23, revised 1985) was followed, as well as specific national laws where applicable. All experiments have been examined and approved by the appropriate ethic committee"

REFERENCES

1. Squeo, R.F.; Beer, R.; Silvers, D.; Weitzman, I.; Grossman, M. Invasive Trichonphytonrubrum resembling blastomycosis infection in the immunocompromised host. J. Am. Acad. Dermatol. 1998; 39 (2.2), 379-380.
2. Graser, Y.; de Hong G.S.; Kujipers, A.F.A. Recent advances in the molecular taxonomy of dermatophytes. In: Kushwaha RKS, Guuarro J, editors. Biology of dermatophytes and other keraatinophilic fungi. Rev IberoamMicol; 2000; 17 (Suppl.): 17-21.
3. Padilla, A.; Sampedro, A.; Sampedro, P.; Delgado, D. Clinical and epidemiological survey of dermatophytoses in Jaen (Spain). Rev. Iberoam. Micol. 2002; 19 (1), 36-39.
4. Odds, F.C.; Alistair, J. P.; Gow, A.R. Antifungal agents: mechanisms of action. Trends in Microbiol. 2003; 11 (6),272-279.
5. Nunes, X.P.; Maia, G.L.A., Almeida, J.R.G.S.; Pereira, F.O.; Lima, E.O. Antimicrobial activity of the essential oil of Sidacordifolia L. Braz. J. Pharmacogn. 2006; 16 (1), 642-644.
6. Rippon, J.W.; Fromting, R.A. Cutaneous antifungal agents. New York: Dekker; 1993; pp.

199-214

7. Padma, P.; Chansouria, J.; Khosa, R. “Effect of *Annona muricata* and *Polyalthiacerasoides* on brain neurotransmitters and enzyme monoamine oxidase following cold immobilization stress.” *J. Natural Remedies* 2001; 1(2): 144–46.
8. Feng, P. C.; Haynes, L. J.; Magnus, K. E; Plimmer J. R.; Sherratt, H. S. A. “Pharmacological screening of some West Indian medicinal plants.” *J. Pharm. Pharmacol*. 1962; 14: 556–61.
9. Nwokocha, C. R.; Owu, D. U.; Gordon, A.; Thaxter, K.; McCalla, G.; Ozolua, R. I.; Young, L. "Possible mechanisms of action of the hypotensive effect of Annonamuricata (soursop) in normotensive Sprague-Dawley rats." *Pharm Biol.* 2012; 50(11):1436-41.
10. De Sousa, O. V.; Vieira, G. D.; De Pinho R. G.; Yamamoto, C. H.; Alves, M. S. "Antinociceptive and Anti-Inflammatory Activities of the Ethanol Extract of Annonamuricata L. Leaves in Animal Models." *Int J Mol Sci.* 2010;11(5):2067-78.
11. Heinrich, M.; Kuhnt, M.; Wright, C. W.; Rimpler H.; Phillipson, J. D.; Schandelmaier, A.; Warhurst D.C. “Parasitological and microbiological evaluation of Mixe Indian medicinal plants (Mexico).” *J. Ethnopharmacol.* 1992; 36(1): 81–5.

12 Ashawat, M. S.; S. Shailendra and S. Swarnlata. In vitro antioxidant activity of ethanolic extracts of CentellaasiaticaPunicagranatum, Glycyrrhizaglabra and Areca catechu. Res.J. Med. Plant. 2007; 1:13-16