Original Research Article

ASSESSMENT OF THE EFFECTS OF *MORINGA OLEIFERA* OIL, *ANACARDIUM OCCIDENTALE* OIL AND VITAMIN C AND E ON THE RETICULAR FIBRES OF CADMIUM- INDUCED LIVER DAMAGE IN WISTAR RATS.

Abstract

Background: Cadmium is one of the most toxic pollutants in the environment. This study aims at assessment of the effects of *Moringa Oleifera oil*, *Anacardium Occidentale oil* and vitamin C and E on the reticular fibres of cadmium- induced liver damage in wistar rats.

Methods: Thirty-five (35) wistar rats (80-180g) were randomly selected and divided into seven groups of five rats each after acclimatization for two week. Group A served as control group received phosphate buffer, Group B received Cadmium only (3.5mg/kg body weight). Group C received Vitamin C and Vitamin E, Group D received Vitamin C and Vitamin E and Cadmium. Group E received Cadmium and Moringa oleifera oil, Group F received Cadmium and Cashew nut oil and Group G received Cadmium (3.5mg/kg body weight) and *Moringa oleifera* oil and *Anacardium occidentale* nut oil

Results: Microscopic examination revealed normal histo- architecture of the liver, the portal vein and the reticular fibres were seen clearly and there was orderly arrangement of the reticular fibres in group A and in treatment groups there was enlargement of the portal vein, distortion of reticular fibres and sinusoidal and restoration of the reticular fibres.

Conclusion: This therefore suggests that *Moringa Oleifera* oil and *Anacardium occidentale* nut oil have ameliorative effects that led to the regeneration of the damaged and distorted reticular fibres.

Key words: *Moringa oleifera, Anacardium occidentale*, Oxidative stress, Liver, Cadmium.

Introduction

Cadmium is a metal with an oxidation state of +2. It is chemically similar to zinc and occurs naturally with zinc and lead in sulfide ores [23]. It is a soft white solid whose density is 8.64 g/cm^3, melts at 320.9 °C and boils at 765 °C at 100 kPa. It is soluble in dilute nitric and concentrated in sulfuric acids [11][18][21] . Cadmium compounds are used in electric batteries, electronic components and nuclear reactors [7][18]. Cadmium (Cd) is one of the most toxic metal ions of the environment which is bound in the air, food and water [13]. Cadmium has been classified as a number 1 category human carcinogen by the International Agency for Research on Cancer of USA because of its carcinogenic properties [12]. Cadmium can cause osteoporosis, anemia, non-hypertrophic emphysema, irreversible renal tubular injury, eosinophilia, anosmia and chronic rhinitis. Cadmium intoxication is responsible for alterations in various metabolic processes [22] and the inhibition of nucleic acid and protein synthesis (Beyersmann and Hechtenberg) [3]. Cadmium has been reported extensively as being carcinogenic, mutagenic and teratogenic under experimental conditions. Cadmium's action of being teratogenic has sometimes been attributed to placental or yolk sac damage in rodents [5], it has also been reported that cadmium is found in early organogenesis-stage embryonic tissues[16], indicating that embryonic cells may be the direct targets of cadmium action.

Moringa oleifera is the most widely cultivated species of a monogeneric family, the Moringaceae that is native to the sub-Himalayan tracts of India, Pakistan, Bangladesh and Afghanistan [8]. It is a small, fast, growing, evergreen, or deciduous tree that usually grows up to

10 or 12 m in height. It is a perennial softwood tree with timber of low quality, but which for centuries has been advocated for traditional, medicinal and industrial uses [8]. Moringa seed oil (yield 30-40% by weight), also known as Ben oil, is a sweet non-sticking, non-drying oil that resists rancidity. It has been used in salads, for fine machine lubrication, and in the manufacture of perfume and hair care products [20]. Some of its activities include; antihypertensive and cholesterol lowering [4]; hepatoprotective and anticancer, [10]; as biosorbent (for the removal of Cadmium); Antibacterial and antifungal activities and Antitumor activities amongst others [17][19].

Anacardium occidentale tree is a native of Brazil and the Lower Amazons. Cashew nut is a high value edible nut. It yields two "Oils" one of these found, between the seed coat (or pericarp) and the nuts, is called the Cashew Nut Shell Liquid (CNSL)**.** It is not a triglyceride and contains a high proportion of phenolic compound. It is used in industry as a raw material for brake lining compounds, as a water proofing agent, a preservative and in the manufacturing of paints and plastics. Cashew apples are sometimes made locally into fruit drinks, wines and pickles. In some countries they are also Osmo-Sol dried to produce a date- like caramel. An ability of cashew apples to supply and fortify the nutritional requirement for vitamin C, particularly in Africa was reported by Akinwale [2]. The importance of the Nut Kernel Oil and Cashew Nut Shell Liquid (CNSL**)** cannot be overemphasized. The fat of nut is completely natural and unprocessed which is best for the body. It is especially rich in Linoleic acid (Omega-3) and is least damaging to heart and arteries. In fact, it constitutes about 47% of the total weight of the nut. Nuts often produce oil half their weight. Cashew has what is called the 'good fat. Cashew has the right combination of fat and the ratio of saturated: monounsaturated: polyunsaturated is 1:2:1 which is ideal for human consumption. The relative abundance of monounsaturated fatty acids in

Anacardium occidentale nut is conducive to the promotion of good health and that the relative abundance of fat in cashew nut in no way poses a nutritional risk [1]. It has been shown to have antifungal, medicinal and antidiarrhoeal properties amongst others [14].It has been reported that continuous exposure and intoxication of liver to different types of exogenous compounds on a daily basis lead to hepatic dysfunction [15]

Vitamin C (Ascorbic acid) is a water-soluble antioxidant occurring in the organism as an ascorbic anion. It also acts as a scavenger of free radicals and plays an important role in regeneration of α-tocopherol [25]**.** Ascorbic acid is a powerful antioxidant because it can donate a hydrogen atom and form a relatively stable ascorbyl free radical. As a scavenger of reactive oxygen and nitrogen oxide species, ascorbic acid has been shown to be effective against the superoxide radical ion, hydrogen peroxide, the hydroxyl radical and singlet oxygen [23].

Vitamin E (α-tocopherol) is a fat-soluble vitamin known to be one of the most potent endogenous antioxidants. α-tocopherol is a term that encompasses a group of potent, lipid soluble, chain-breaking antioxidants that prevents the propagation of free radical reactions. Vitamin E is an important antioxidant, which is suggested to play a physicochemical role in the stabilization of bio-membrane by virtue of lipid-lipid interaction between the vitamin and the unsaturated fatty acids [6]. Reports have shown that antioxidants like vitamin C and Vitamin E have shown protection against cadmium induced toxicity in different animal models [26][27].

The present study therefore assessment of the effects of *Moringa Oleifera oil, Anacardium Occidentale oil* and vitamin C and E on the reticular fibres of cadmium- induced liver damage in wistar rats.

Materials and Method

Extract preparation;

Extraction of Moringa oleifera oil

Moringa oleifera seed was purchased from Maraba market in Nasarawa State, Nigeria. The oil was extracted using the following procedures. The husks were removed from 2330g of *Moringa oleifera* seeds and were heated in an oven at a temperature of 40^0C and were pounded using a mortar and pestle to separate the chaff from the seeds. The seed was grind into powder using a grinding mill. The powdered form of *Moringa Oleifera* was dissolved in 466ml of water at ambient temperature for two days and was later filtered through Whatman filter paper. The aqueous extracts was then poured into molten mesh and placed on an oil extractor machine. The seed oil was removed at high temperature and pressure.

Extraction of *Anacardium occidentale* Nut oil

Anacardium occidentale nut was purchased from Kuchikau in Nasarawa state, Nigeria. The oil was extract using the following procedure. Cashew (*Anarcardium occidentale*) nuts (2000g) were heated in an oven at a temperature of 40^0C and were ground into powder using a grinding mill. The powdered form was poured into a molten mesh and placed in an oil extractor machine. The oil was removed at high temperature and pressure and both oil extracts were kept at room temperature.

Drug Preparation

The Cadmium Sulphate Solution ($3CdSO_4.8H_2O$) was prepared by dissolving 9.9198mg of Cadmium Sulphate salt (CdS) in 5ml of 0.9% w/v Phosphate buffer. The Ascorbic acid (Vitamin C) was prepared by dissolving 5mg of Vitamin C in 10ml of 0.9% w/v Phosphate buffer. The

Vitamin E (Alpha Tocopherol) was prepared by dissolving 6mg of Vitamin E in 20ml of olive oil.

Experimental animals:

Thirty five (35) Wistar rats weighing between 80g-180g were used for this research work. The rats were randomly selected into seven groups as follow A, B, C, and D, E, F and G of five Rats each. They were kept in the animal house of Bingham University, Nigeria and given feed and water *ad libitum*. The treatment for the various groups was administered accordingly.

Chemical and Extract Administration

0.32ml (40mg/kg body weight) of *Moringa Oleifera* and *Anacardium occidentale* nut seed oil, 0.16ml (20mg/kg body weight) ,0.8ml (100mg/kg body weight) of Vitamin C, 0.3ml of Vitamin E (300mg/kg body weight) and 5ml of 0.9% w/v of Phosphate buffer were administered orally to the experimental Rats according to their individual groups for a period of four weeks using a 2ml syringe with an oral cannular at the tip. The treatment was done every morning after which the animals were fed.

Animal Treatment

The animals were treated as shown below in the table

Table 1: Number of Animals in each group and Dosage of treatment given:

Groups	Number of Animals	Dosage
A	5	5ml of 0.9% w/v Phosphate buffer per kg bw

B	5	3.5mg/kg bw Cadmium only
C	5	100mg/kg Vitamin C (0.8ml) and 300mg/kg Vitamin E (0.3ml)
D	5	100mg/kg Vitamin C (0.8ml) and 300mg/kg (0.3ml) Vitamin E + 3.5mg/kg bw Cd
E	5	3.5mg/kg bw Cadmium+ 40mg/kg *Moringa oleifera* seed oil (0.32ml)
F	5	3.5mg/kg bw Cadmium+ 40mg/kg *Anacardium occidentale* nut oil (0.32ml)
G	5	3.5mg/kg bw Cadmium+ *Moringa oleifera* seed oil + *Anacardium occidentale* nut oil 20mg/kg each (0.16ml each).

Control Groups

The animals were grouped into three control groups which are; the normal control (A), the negative control (B) and the positive control (C). The Normal Control Group (A) received 5ml of 0.9% w/v Phosphate buffer orally for a period of four weeks. The Negative Control Group (B) was induced intraperitoneally with 3.5mg/kg $3CdSO_{4.}8H_2O$. The Positive Control Group (C) received 100mg/kg (0.8ml) Vitamin C and 300mg/kg (0.3ml) Vitamin E orally for a period of four weeks.

Prophylactic Treatment Group

The animals in Group D were the prophylactic group that received 100mg/kg (0.8ml) Vitamin C and 300mg/kg (0.3ml) Vitamin E for a period of four (4) weeks followed by intraperitoneal injection of 3.5mg/kg body weight $3CdSO_{4.}8H_2O$. The rats were then sacrificed after 24 hours.

Therapeutic Treatment Groups

The animals in Groups E, F and G were the therapeutic control group. The animals in each group were injected intraperitoneally with 3.5mg/kg $3CdSO_4.8H_2O$. After 48 hours of the injection, the animals in Group E and F received 40mg/kg body weight of *Moringa Oleifera* Seed Oil and *Anacardium occidentale* Nut Oil for a period of four (4) weeks. The animals in Group G received 20mg/kg each (0.16ml each) of both *Moringa Oleifera* Seed oil and *Anacardium occidentale* nut oil.

Animal Sacrifice

The animals were sacrificed twenty four hours through cervical dislocation. The thoracic and abdominal cavities were exposed adequately by using a surgical blade to make a midline incision through the skin of the abdominal wall from the xiphisternum to the pubic symphisis. After the abdominal cavity had been adequately exposed, the liver was removed and fixed in 10% formosaline for histological analysis.

Histological Preparation of Tissues

The liver was fixed in 10% formosaline to prevent autolysis. The liver was passed through ascending grades of alcohol (70%, 80%, 90% and absolute 100%) to gradually remove its water contents. The sample was placed in xylene to remove the alcohol. This improves the refractive index of the tissue. The tissue was immersing in molten paraffin wax so that the holes left by the alcohol would be filled up. This gives the tissue support. The tissue is placed into an embedding mould which is filled with more paraffin wax and allowed to solidify. This is done in order to make the tissue compact for sectioning. The block is trimmed to remove the excess wax. The block of tissue was placed in a

microtome and trimmed to expose the surface. The microtome was set to 3-5 micron and the tissue was sectioned. The sections were picked with forceps and placed in a water bath to float out and spread well. It was picked with a slide and the slide was placed on a hot plate in order for the tissue to slick to the slide. The slides were arranged on a staining rack and dewaxed in two changes of xylene for 10 minutes. It was then hydrated in descending grades of alcohol and rinsed. The stain was applied and the slides left to dry. Photomicrographs were taken with a JVC colour video digital camera (JVC, China) mounted on an Olympus light microscope (Olympus UK Ltd, Essex,UK) to demonstrate the reticular fibres.

RESULT AND DISCUSSION

Group A

Photomicrograph of the liver of experimental control group received phosphate buffer

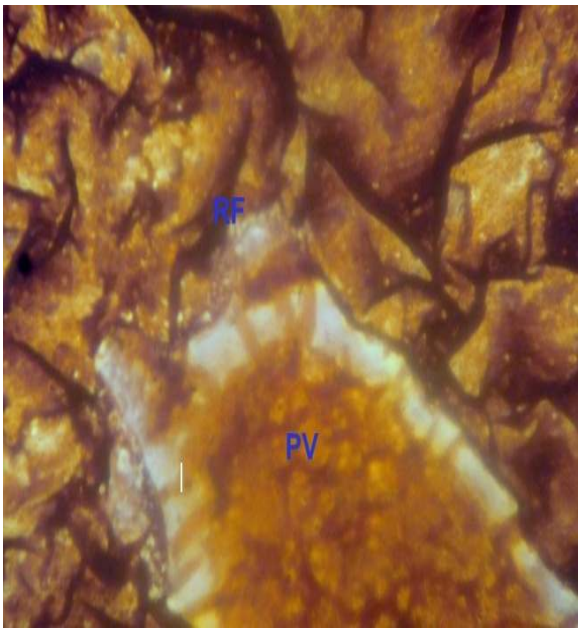

Fig. 1: Histological demonstration of the liver using silver staining techniques [X400] showing the normal reticular fibres (RF) and portal vein (PV).

Group B

Photomicrograph of the liver of experimental administered Cadmium only (3.5mg/kg body weight).

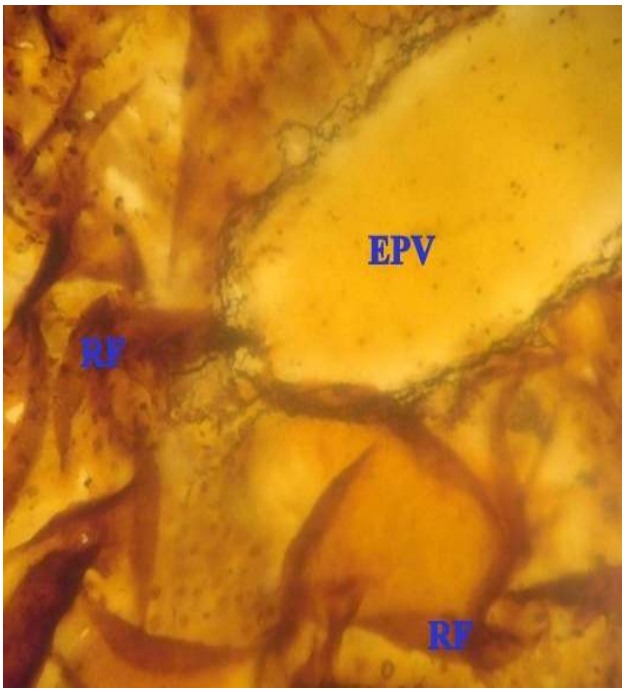

Fig.2: Histological demonstration of the liver using silver staining techniques [X400] showing the enlarged portal vein (EPV) and reticular fibres

Group C

Photomicrograph of the liver of experimental animal administered Vitamin C and Vitamin E,

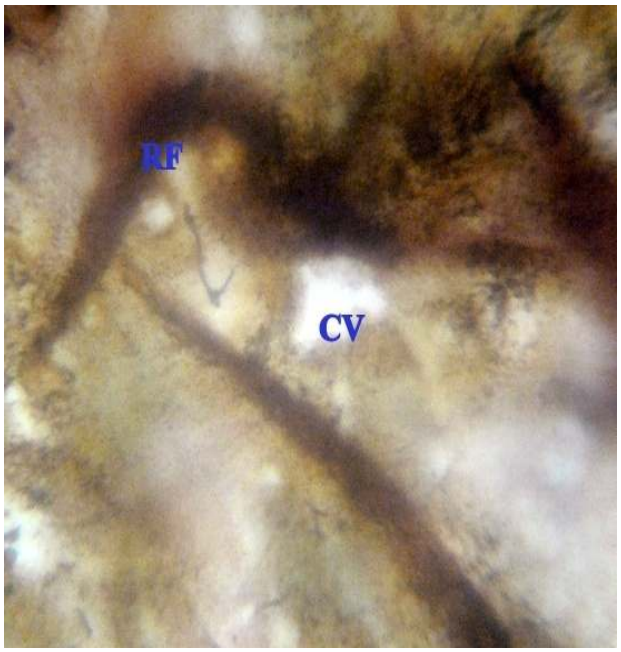

Fig.3: Histological demonstration of the liver using silver staining techniques [X400] showing the reticular fibres (RF) and central vein (CV)

Group D

Photomicrograph of the liver of experimental animal administered Vitamin C and Vitamin E and Cadmium.

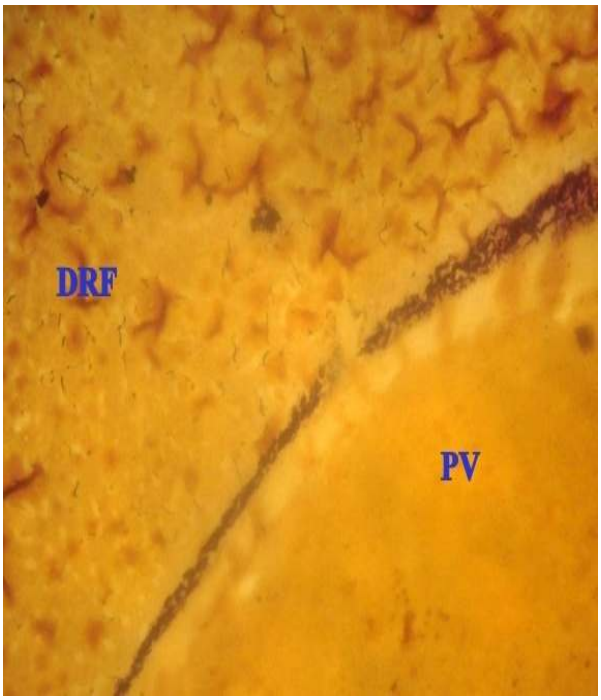

Fig.4: Histological demonstration of the liver using silver staining techniques [X400] showing the portal vein (PV) and degeneration of reticular fibres (DRF)

Group E

Photomicrograph of the liver of experimental animal administered Cadmium and *Moringa oleifera* oil

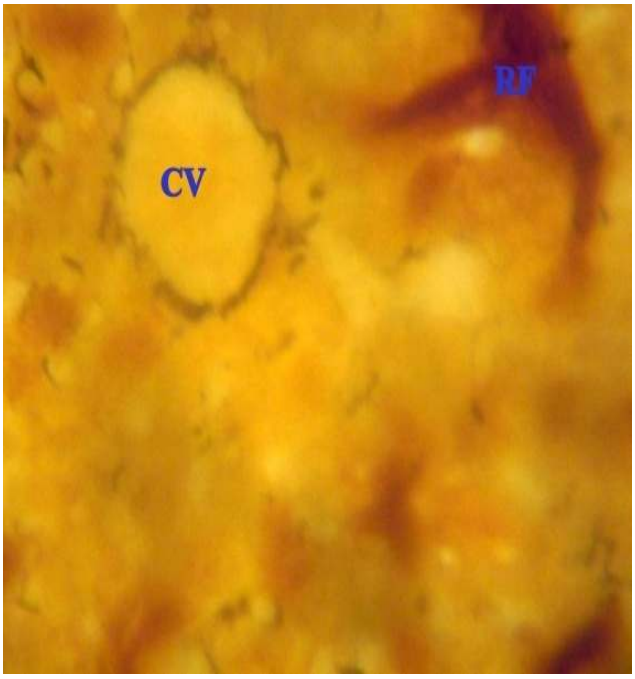

Fig.5: Histological demonstration of the liver using silver staining techniques [X400] showing the central vein (CV) and reticular fibres (RF).

Group F

Photomicrograph of the liver of experimental animal administered Cadmium and *Anacardium occidentale* nut oil

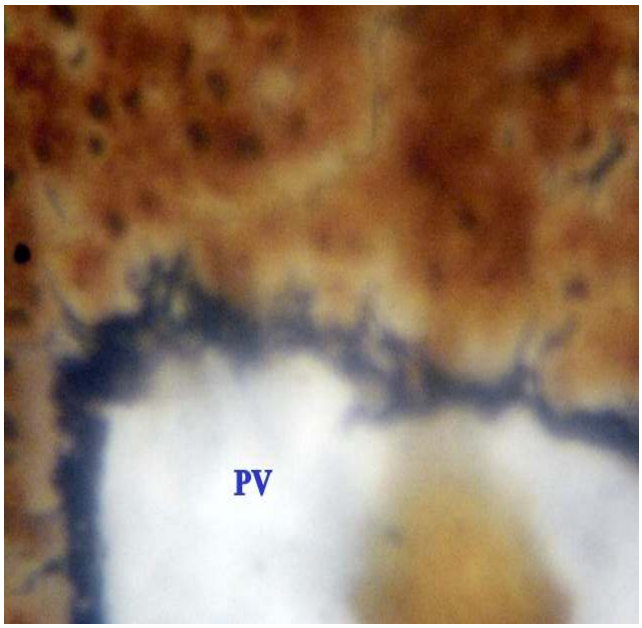

Fig.6: Histological demonstration of the liver using silver staining techniques [X400] showing the portal vein

Group G

Photomicrograph of the liver of experimental animal administered Cadmium (3.5mg/kg body weight) and Moringa oleifera oil and Cashew nut oil

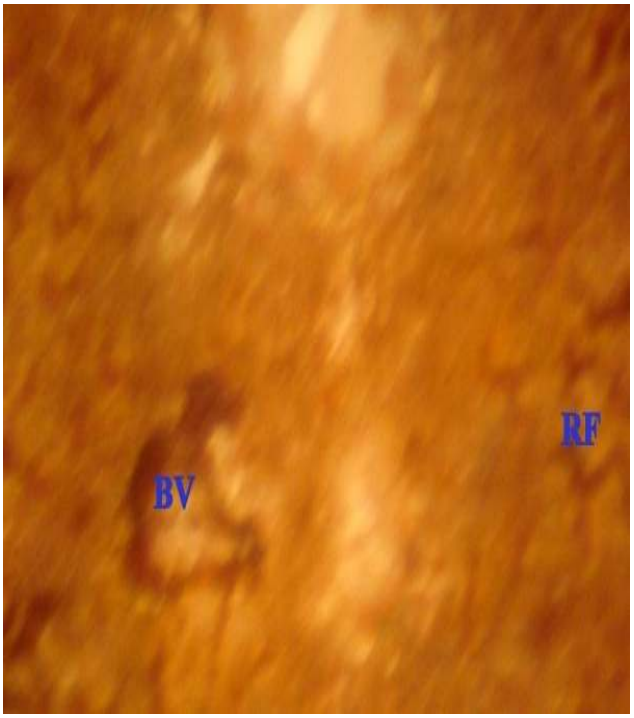

Fig.7: Histological demonstration of the liver using silver staining techniques [X400] showing the blood vessel (BV) and reticular fibres (RF).

Silver staining aids the visualization of the intracellular and extracellular components such as DNA and proteins such as type III collagen and reticulin fibres by the deposition of metallic silver particles on the target of interest [28]. *Moringa oleifera* is widely distributed in the world especially in Asian countries and is a highly cultivated and valued plant in tropical and subtropical countries [29].

Present study revealed normal histological architecture of the liver, the portal vein and the reticulr fibres were seen clearly and there was orderly arrangement of the reticular fibres in phosphate buffer group. In cadmium only group, there was enlargement of the portal vein and distortion of the arrangement of the reticular fibres. This thus indicates hepatic dysfunction due to the generation of reactive oxygen species. In group C, resolution was observed and the reticular fibres were seen though not orderly arranged. This suggests that the antioxidant

activities of the Vitamins can help to enhance the liver functions. In group D, the portal vein and reticular fibres were seen though not well arranged and the sinusoidal beds were a little bit distorted. This suggests that the antioxidant activities of the Vitamins have helped to curb the effects of free oxygen radicals generated by Cadmium although not highly potent. This is supported by the previous research by Flora [6] that antioxidant has been found to heal the free radical mediated cell damage. In groups E, F and G, there was restoration of the reticular fibres and the portal vein was seen unlike the group B which was induced with Cadmium only. This therefore suggests that *Moringa oleifera* oil and *Anacardium occidentale* nut oil have ameliorative effects that led to the regeneration of the damaged and distorted reticular fibres. We therefore deduced from our finding that vitamin C, vitamin E, *Moringa Oleifera* oil and *Anacardium occidentale* nut oil attenuate the effects of cadmium on liver of wistar rats.

Conclusion

The histo- architecture of the livers of the treated rats showed the central vein and restoration of the damaged and distorted reticular fibres these show ameliorative effect of *Moringa Oleifera* seed oil and *Anacardium occidentale* nut oil on Cadmium induced liver damage.

CONSENT

It is not applicable.

ETHICAL APPROVAL

All the authors hereby declare that all the experiments have been examined and approved by the appropriate ethics committee and have therefore been performed in line with the ethical

procedure laid down by Nigeria Medical Ethical Association for Accreditation of Laboratory Animal Care.

REFERENCES

[1] ACHAL (2002). Cashew: Nutrition and medicinal value. C*olarado state University,* pp: 159-165.

[2] Akinwale, T. O. (2000). Cashew apple juice: its use in fortifying the nutritional quality of some tropical fruits. *Eur Food Res Technology,* 211:205-207.

[3] Beyersmann, D and Hechtenberg S. (1997). Cadmium, gene regulation, and cellular signalling in mammalian cells. *Toxicol Appl Pharmacol*, 144:247–261.

[4] Faizi, S., Siddiqui, B.S, Saleem, R, Siddiqui, S, Aftab, K, Gilani, A.H (1995). Fully acetylated carbamate and hypotensive thiocarbamate glycosides from Moringa oleifera. *Phytochemistry*, 38:957–963.

[5] Feuston, M.H and Scott, W.J Jr. (1985). Cadmium- induced forelimb ectrodactyly: a proposed mechanism of teratogenesis. *Teratology*, 32: 407-419.

[6] Flora S.J.S. (2002). Lead in the Environment: Prevention and Treatment. *J Environ Biol*; 23:29-44.

[7] Friberg, L., Nordberg, G.F, Vouk, V.B. eds. (1986). Handbook of the toxicology of metals. Vol. II. Amsterdam, *Elsevie*; pp. 130–184.

[8] Fulgie, L.J. (1999). The Miracle Tree: Moringa oleifera: Natural Nutrition for the Tropics. Church World Service; pp 172

[9] Gibbon, D and Pain, A. (1981). Crops of the drier regions of the tropics. *Longman Singapore publications Ltd,* pp 66-67.

[10] Gilani, A.H., Janbaz, K.H and Shah, B.H. (1997). Quercetin exhibits hepatoprotective activity in rats. *Biochem. Soc. Trans*. 25: 85.

[11] IARC (1976) *Cadmium, nickel, some epoxides, miscellaneous industrial chemicals and general considerations on volatile anaesthetics*. Lyon, International Agency for Research on Cancer, pp. 39–74.

[12] IARC, International Agency for Research on Cancer, Beryllium, cadmium, mercury, and exposures in the glass manufacturing industry (1993). In: International Agency for Research on Cancer Monographs on the Evaluation of Carcinogenic Risks to Humans. *IARC Scientific Publications Lyon*, 58:119–237.

[13] Lin, S., Sandow, M, Decandido, S, Waslien, C and Naughton, B. (1992). The effect of vitamin D3 and 1,25- dihydroxy vitamin D3 on the toxic symptoms of cadmium exposed rats. *Nutr. Res*. 12:1393.

[14] Mustapha, Y; Hasfat, S. (2007). Antibacterial activities of *Anacardium occidentale* leaf extract against some selected bacterial isolates. IJPAS., 1(1):40-43.

[15] Nithya, N., Chandrakumar, K, Ganevan, V and Senthilkumar, S (2012). Efficacy of *Momordica charantia* in attenuating abnormalities in cyclophosphomide intoxicated rats. *J. Pharmacol. Toxicol.* 7(1): 38-45.

[16] Ochi, T., Takahashi, K and Ohsawa, M. (1987). Indirect evidence for the induction of a prooxidant state by cadmium chloride in cultured mammalian cells and a possible mechanism for the induction. *Mutat. Res*. 180:257–266.

[17] Rao, V.A., Devi, P.U and Kamath, R. (2001). In vivo radioprotective effect of Moringa oleifera leaf extract on gastric ulcer models in rats. Phytother Res, 9: 463–465

[18] Ros, J.P.M and Slooff W, eds. (1987). Integrated criteria document. *Cadmium*. Bilthoven, National Institute of Public Health and Environmental Protection (Report No. 758476004).

[19] Sharma P, Kumari P, Srivastava MM, Srivastava S (2006). Removal of cadmium from aqueous system by shelled Moringa oleifera Lam. seed powder. *Bioresour Technol*; 97: 299–305.

[20] Tsaknis, J.V and Spiliotis (1999). Quality changes of *Moringa oleifera*, variety Mbololo of Kenya, seed oil during frying. *Grasas y Aceites*, 50(1): 37-48.

[21] Ware, GW., ed. (1989). Cadmium. US Environmental Protection Agency Office of Drinking Water health advisories. *Reviews of Environmental Contamination and Toxicology*, 107:25–37.

[22] Webb., M. and In: Brown, S.S. (Ed.) (1977). Clinical Chemistry and Chemical Toxicology of Metals. Elsevier, Amsterdam; pp:51–64.

[23]Weber, P., Bendich, A and Schalch (1996). Ascorbic acid and human health – a review of recent data relevant to human requirements. *Int J Vit Nutr Res*, 66:19-30.

[24] WHO (in preparation) (2010). Safety evaluation of certain food additives and contaminants in food. Geneva, World Health Organization. *WHO Food Additives Series*, No. 64.

[25] Young, I.S., Woodside, I.S. (2001). Antioxidants in health and disease. *J Clin Pathol, 54*: 176- 186.

[26] Ognjanovic, B.I., Pavlovic, S.Z, Maletic, S.D, Zikic R.V, Stajn A.S, Radojicic R.M, Saicic Z.S, and Petrovic V.M. (2003). Protective influence of vitamin E on antioxidant defense system in the blood of rats treated with cadmium. *Physiol Res*, 52:563-70.

[27] Beytut, E., Yuce, A, Kamiloglu, N.N and Aksakal M. (2003). Role of dietary vitamin E in cadmium-induced oxidative damage in rabbit's blood, liver and kidneys. *Int J Vitam Nutr Res*, 73 : 351-5.

[28] Schwint, O.A, Labraga, M, Cervino C.O, Haffar, M, Sequeiros, P.H and Marcos, H.J. (2004). A modification of the staining technique of reticular fibres for image analysis of the cardiac collagen network". *Cardiovasc. Patho*. 13(4): 213- 20.

[29] Khalafalla, M.M.; Abdellatef, E.; Dafalla, H.M.; Nassrallah, A.A.; Aboul-Enein K.M.; Lightfoot, D.A.; El-Deeb, F.E.; El-Shemy, H.A (2010). Active principle from Moringa oleifera Lam leaves effective against two leukemias and a hepatocarcinoma. Afr. J. Biotechnol. 9:8467–8471.