UNDER PEER REVIEW

Original Research Article

Histological and biochemical studies of the actions of a multi-herbal tea on the testis in Wistar rats

Summary: Tea is consumed almost worldwide as a beverage and for its perceived health benefits. Tea has been used in folk medicine to treat a wide range of disorders. Tea is believed to be safe but recent studies suggest that under certain conditions, components of tea may be toxic to the liver and testis in rats. This study examined the effects of a multi-herbal tea on sperm parameters, markers of oxidative stress and histology in the testes of Wistar rats. We analysed histology of testis, and estimated sperm parameters and markers of oxidative stress such as catalase and reduced glutathione in 3 groups of rats that had been treated with 150mg/kg of a tea extract for 4 and 8 week durations. One of the treated groups received ascorbic acid along with the extract. Our results show that the extract caused a significant reduction in all sperm parameters, with a 25% and 50% reduction in sperm count and motility respectively. Tea also caused oxidative stress with raised levels of Malondialdehyde and reduced levels of catalase and glutathione. The extract also induced considerable degenerative changes in histology of the testes. Co-administration of ascorbic acid resulted in significant improvement in all sperm parameters and protection of testes from histological damage. We conclude that tea may be generally safe to take but at certain dosage and length of use, multi-herbal teas can impair spermatogenesis and damage the histology of testicular tissue, at least in rats.

Key words: Multi-herbal tea, spermatogenesis, testicular tissue, oxidative stress.

INTRODUCTION

Tea is one of the most widely consumed liquids in the world. Tea was originally processed from the leaves of the *Carmelia sinensis* plant in China thousands of years ago. Today it is made from a mixture of medicinal herbs. [(1)] Most of the teas in use today usually include the leaves of Senna (*Cassia acutifolia*); Mallow (*Malva verticulata*); Persimon (*Diospyros kaki*) and Green tea (*Carmelia sinensis*). The composition of tea varies with climate, season, horticultural practice, age and plant variety as well as processing technique. Green tea for instance is processed by steaming the fresh leaves at high temperatures. This inactivates the oxidising enzymes and leaves the polyphenol content intact.

The main components of unfermented tea are polyphenols, mostly catechins which make up about 20-25% of the dry weight of the leaves. [(2)] Tea also contains methyl xanthines,

UNDER PEER REVIEW

primarily in the form of caffeine (2-5%) and smaller amounts of theophylline and theobromine. [3] Some of these plants contain other bioactive compounds however. Persimon leaves for example contain steroids, terpenoids, flavonoids, carotenoids and dietary fibers. [4]

Tea has been used in folk medicine for a wide range of conditions. Senna is used in Islamic traditional medicine as a general remedy for diseases such as: constipation, gout, arthritis and haemorrhoids. [5] Tea polyphenols are presently the subject of intense research owing to accumulating evidence that they have a wide range of health benefits. Among the potential health benefits are the anti-microbial, anti-inflammatory, anti-mutagenic and anti-cancer properties of these compounds. [6 - 8]

The widespread benefits ascribed to polyphenols are believed to stem from their anti-oxidant properties. [9, 10] Though these compounds are generally considered safe, possibly because of a tradition of long use in both diet and folk medicine, evidence is accumulating to show that under certain conditions, they can have harmful effects on animal systems. Studies in rats have shown that tea polyphenols can be hepatotoxic [11] and testiculotoxic. [12] This study reports on the effects of a multi-herbal tea mixture on sperm parameters, markers of oxidative stress and histology in the testes of albino rats.

MATERIALS AND METHODS

TEA AND ASCORBIC ACID

A herbal mixture named Tripple Leaf Tea (Triple Leaf Tea Inc. USA) and ascorbic acid in the form of chewable vitamin C (Kunimed Pharmachem Limited, Lagos) were purchased from a local pharmacy in Lagos. All chemical reagents were obtained from reputable manufacturers and were of research grade.

PREPARATION OF TEA EXTRACTS (TE)

Tea extract was prepared according to the method described by Maina *et al* [1]. Briefly, 33.03 g of the herbal tea mixture was weighed and steeped in a container holding 500 ml of boiling distilled water. The mixture was allowed to stand for 15 minutes and then filtered. The residue was dried and weighed. It weighed 20.70g. The concentration of the filtrate which was used as the extract was calculated from this weight difference.

UNDER PEER REVIEW

ANIMALS

Twenty-five Sprague-Dawley rats weighing between 150 and 200 g were obtained from the animal house of our Medical School and used for the study. They were housed in clean cages and acclimatized at room temperature for 2 weeks in 12 hour light/darkness rhythm. They had access to standard animal food and clean water ad-libitum. They were then randomly assigned to one of five groups, 1 to 5 of 5 each and treated as follows:

ANIMAL TREATMENT

Group 1: Control, Distilled water only for 8 weeks.

Group 2: 150mg / kg of Tea Extracts (TE) for 4 weeks

Group 3: 150mg / kg of (TE) for 8 weeks

Group 4: 150mg / kg of TE plus 4mg / kg of ascorbic acid (AA) for 8 weeks

Group 5: 4mg / kg of AA only for 8 weeks

All treatments were administered by gavage. At the end of each experiment, the animals were sacrificed under ketamine anaesthetics. The testis and epididymis were dissected out of each rat, cleared of fat and weighed separately. Testis volume was determined by water displacement method. One testis was fixed in formol saline for histological studies and the other was macerated in distilled water and used for biochemical assays.

The protocol for this study was approved by the Review Board of the Lagos State University College of Medicine and complied with International Guiding Principles for Biomedical Research Involving Animals (2012) of the Council for International Organisation of Medical Sciences (CIOMS).

DETERMINATION OF EPIDIDYMAL SPERM PARAMETERS

Epidydimal sperm concentration, motility and morphology were determined by modifying a method described by Yokoi and others. [13] Briefly, the cauda epidydimis was minced in 2ml of fresh physiologic saline solution buffered with sodium bicarbonate and allowed to stand for a few minutes to liberate spermatozoa. Motility estimation was carried out at room temperature between 24 ^{o}C and 28 ^{o}C. One drop from the sperm suspension was placed on a warmed slide and the microscopic field was scanned systematically. Spermatozoa encountered were assessed as motile or non-motile. An estimate of the percentage of motile

UNDER PEER REVIEW

sperm was made from the average of three fields [14]. Sperm density was estimated by charging a haemocytometer from a preparation made by diluting the sperm suspension 1:1 with distilled water to which a drop of formalin had been added to immobilise sperm. Sperm morphology was determined by counting all abnormal cells out of 100 cells examined across several high power fields. [13]

BIOCHEMICAL ASSAYS:

The testis was washed in ice-cold solution of 1.15% KCL. It was then macerated and homogenised in 0.1M phosphate buffer solution (pH 7.2).The homogenate was centrifuged at 2500 rpm for 15 min and the supernatant was stored at -20 ^{o}C and used for biochemical assays.

Malondialdehyde (MDA) levels were determined using a method described by Buege and Aust (1978) [15]. This involved reacting the sample with a mixture containing thiobarbituric acid and generating a colour complex which was measured at 532 nm because it absorbs light maximally at this wavelength. The result was expressed as µmg $^{-1}$ protein in the sample.

Catalase (CAT) activity was determined from the rate of disappearance of H_2O_2 at 37 ^{o}C, measured colorimetrically at 620nm according to the method described by Aksenes and Njaa and is expressed as U mg $^{-1}$ protein in the sample. [16]

Reduced glutathione (GSH) was estimated by the method of Sedlak and Linsay. Briefly, 0.5ml of Elman's reagent was added to 1ml of the supernatant. Distilled water and 3ml of 0.2M phosphate buffer was then added to the mixture and the absorbance was read at 412 nm. The result was expressed as U mg $^{-1}$ protein. [17] Superoxide dismutase (SOD) activity was determined by its ability to inhibit the auto-oxidation of epinephrine determined by the increase in absorbance at 480nm as described by Sun and Zigma. [18]

HISTOLOGY

Tissue sections from testes and epidydimis were prepared for histologic examination by the method of Sheehan and Wrapshak. [19] Briefly the specimens were cleared of fixative (Bouin,s fluid), and dehydrated in graded alcohol. They were then blocked out in paraffin and cut into 0.5 µ sections. The sections were deparaffinised, rehydrated and stained with hematoxyline and eosin. They were examined in a Ceti microscope fitted with an XLI camera and software at total magnifications ranging from between 100 and 1000.

UNDER PEER REVIEW

STATISTICAL ANALYSIS

All data are expressed as mean ± SD. The level of homogeneity among groups was tested by Analysis of Variance (ANOVA). Where heterogeneity occurred, the groups were separated using Duncan Multiple Range Test (DMRT). A value of $p<0.05$ was considered as significant. Data analysis was done with SPSS version 19.0 (Cary, NC, USA).

RESULTS

General observations, body weight and parameters of the testis

The experiment was well tolerated in all groups. Animals continued to gain weight during the course of the experiment. A significant difference occurred between groups in weight gain, with animals in group 5, which had only ascorbic acid showing maximum weight gain, $p<0.05$. No significant difference occurred between groups in the weight and volume of the testis (Table 1).

Sperm parameters

The tea extract caused a time-dependent significant reduction in total sperm counts in all treated groups when compared to control group, $p<0.05$. Ascorbic acid administration caused significant improvement in all sperm parameters in group 4, when compared to the other extract treated groups. After 8 weeks of extract treatment there was close to 25% and 50% reduction in total counts and sperm motility respectively when this group is compared to control (Table 2).

Total sperm count was 45.0 ± 2.0 in group 3 compared to 76.0 ± 2.0 in control group. Sperm with normal morphology was also significantly reduced in this group. Concurrent administration of ascorbic acid conferred complete protection from the effects of the extract on sperm morphology. All semen parameters were better in group 5 which was given ascorbic acid only than other groups including group 1which was negative control group (Table 2).

Biochemical parameters

The tea extract caused a significant time –dependent increase in lipid peroxidation as measured from MDA levels, suggesting it generated oxidative stress. For example, MDA level was 0.28 ± 0.02 in group 3 which had extract only for 8 weeks compared to 0.05 ± 0.01 in control group, $p< 0.05$, (Table 3). The extracts also caused significant reduction in the

UNDER PEER REVIEW

levels of all anti-oxidants measured, namely superoxide dismutase, catalase and reduced glutathione (GSH). Again ascorbic acid virtually normalised all these parameters used to evaluate oxidative stress. As in the case of semen parameters, the levels of all biochemical parameters assayed were better group 5 which was given ascorbic acid only than occurred in all other groups (Table 3).

Histological profile

Tea extracts caused degenerative changes in histology of seminiferous epithelium. This was associated with a reduction in the presence of free mature spermatozoa in lumen of these tubules (Figure 2). Histological changes were maximal in group 3 which was administered the extract for a longer duration (Figure 3). In this group pronounced derangement in tubular outline and cyto-architecture was observed. There was distortion of tubular outline in some areas and massive sloughing of germ cells and loss of cell to cell adhesion in other areas. Again ascorbic acid administration caused notable protection of seminiferous epithelium from histological damage induced by the extracts (Figure 4).

DISCUSSION

In this study, animals in all groups, including those treated with tea extracts continued to gain weight during the course of the experiment. Some studies indicate that green tea, a component of the mixture used in this study, can prevent weight gain and it has been marketed with claims of being useful as a weight control agent. [20] Our findings are however in agreement with those of Maina and others which found no weight control benefits with these teas. [1] More studies are needed therefore to elucidate the effects of tea on body weight in animals and humans.

Tea extracts produced significant alterations to all sperm parameters assessed in this study. There was reduction in epididymal sperm concentration, progressive motility and percentage of spermatozoa with normal morphology. Reduced sperm density suggests an interruption of spermatogenesis and the ability of the extracts to reduce motility and normal morphology ratio as well is considered by some researchers to indicate that components of the extracts or at least their metabolites are able to cross the blood-testis barrier. This alters the micro-environment in which the later stages of spermatogenesis are taking place. Ascorbic acid conferred significant protection from all alterations of sperm parameters. This suggests that these effects may be induced by oxidative stress.

UNDER PEER REVIEW

The tea extracts also increased lipid peroxidation and decreased levels of both enzymatic and non-enzymatic anti-oxidants: superoxide dismutase, catalase and reduced GSH. These effects reflect underlying oxidative stress. As have been alluded to earlier in his paper, though many of the health benefits ascribed to tea polyphenols are believed to derive from their anti-oxidant activities, there is sufficient evidence that under certain conditions, they have pro-oxidant activity that can destroy tissue. [21] Schilter and others have shown that relevant factors in such toxic activity include: dosage, use in vulnerable populations and prior existence of certain diseases. [22]

A major tea polyphenol, epigallocatechin-3-gallate (EGCG) have been reported to produce H_2O_2 in-vitro as part of a process of oxidative phosphorylation. [1] Indeed many of the cytotoxic properties of these agents found against cancer cell lines such as human lung and esophageal cancers are believed to be due to free radical generating ability. The ability of EGCG for instance to inhibit the growth of these cell lines was diminished when superoxide dismutase or catalase was added to the culture medium. Galati and others have demonstrated that cytotoxicity in these situations was due to production of reactive oxygen species (ROS), and depletion of reduced GSH. [11]

Many testiculotoxic substances including anti-cancer drugs such as doxorubicin and metotrexate have been shown to exert their effects through oxidative stress. [23, 24] There is also evidence that the anti-fertility effects of physical conditions such as varicoceles and cryptorchidism that increase testicular temperature are mediated through increased oxidative stress. [25, 26] The testis is equipped with a considerably formidable anti-oxidant defence system. This includes enzymes such as catalase, superoxide dismutase and non-enzymatic anti-oxidants such as reduced GSH and ascorbic acid. Our findings in this study suggest that under certain conditions, tea consumption can cause a state in which the testicular anti-oxidant defence apparatus is overwhelmed and tissue damage ensues.

The histology of the testis was considerably disrupted in animals treated with the tea extracts in this study. This agrees with the findings of an earlier study by Chandra and others. [27] Many substances that suppress spermatogenesis, especially those that generate reactive oxygen species (ROS) and other free radicals tend to produce histological alterations in the testis. [27, 28] Most of them cause germ cell loss, especially of the more mature ad-luminal cell population. In this study, considerable histological damage occurred in the unprotected treated groups, such that there was severe distortion of tubular outline in addition to germ cell atrophy. Ascorbic acid also conferred significant protection from histological damage in the animals that received the vitamin. Ascorbic acid is an effective broad spectrum free radical

UNDER PEER REVIEW

scavenger readily available to the human population from a wide variety of fruits, especially from citrus plants.

Published studies on the effects of tea catechins on the testis do not portray a uniform picture. A number of studies in rat and mice report that tea catechins have a protective effect on testicular damage induced by nicotine, a chemical toxin which is an important constituent of tobacco. [29, 30] This protection was aptly ascribed to the anti-oxidant properties of these polyphenols. Since tea consumption began in China, a nation that has gone on to become the most populous on earth, tea, especially when used as a beverage is certainly more likely to have a pro, rather than anti-fertility activity. More studies are needed to elucidate the conditions under which tea constituents exert a predominantly pro-oxidant and testiculo-toxic rather than anti-oxidant and testiculo- protective activity. In the meantime, the use of ascorbic acid should be encouraged because of its protective power and the many health benefits possessed by this substance.

REFERENCES

1. Maina MB, Garba SH, Jacks TW. Histological evaluation of rat testis following administration of an herbal tea mixture. J Pharm Toxicol 2008; 3: 464-470.

2. Bruneton J. Pharmacognosy, Phytochemistry, Medicinal Plants, 2nd edn. 1999; Lavoisier Publications, Paris, pp 79-95.

3. Wolfram S. Effects of green tea and EGCG on cardiovascular and metabolic health. J Am Coll Nutr 2007; 26: 373S–388S.

4. Mallavadhani UV, Panda AK, Rao YR. Pharmacology and chemotaxonomy of Diospyros. Phytochemistry 1998; 49: 901-951

5. Al-adhal A. The effect of *Cassia augustifolia* (senna) leaves on the fasting blood sugar in a sample of mild diabetic Yemeni patients. Yemeni J Med Sci 2009; 1(3): 57-59.

UNDER PEER REVIEW

6. Alan L, Miller MD. Antioxidant flavonoids: Structure, function and clinical usage. Alt Med Rev 1996; 1: 103–111.

7. Yang CS, Maliakal P, Meng X. Inhibition of carcinogenesis by tea. Ann Rev Pharmacol Toxicol 2002; 42: 25-54.

8. Kiefer S, Weibel M, Smits J, Juch M, Tiedtke J, Herbst N. Citrus flavonoids with skin lightening effects, safety and efficacy studies. SOFW 2010; 136: 45–54.

9**.** Lambert JD, Yang CS**.** Mechanisms of cancer prevention by tea constituents. J Nutr 2003; 133: 3262S-3267S.

10. Sang S, Hou Z, Lambert JD, Yang CS. Redox properties of tea polyphenols and related biological activities. Antioxid Redox Signaling 2005; 7: 1704-1714.

11. Galati G, Lin A, Sultan AM, O'Brien PJ. Cellular and in vivo hepatotoxicity caused by green tea phenolic acids and catechins. Free Radic Biol Med 2006; 40:570–580.

12. Chandra AK, Choudhury SR, De N, Sarkar M. Effect of green tea (*Camellia sinensis* L.) extract on morphological and functional changes in adult male gonads of albino rats. Indian J Exp Biol 2011; 49: 689-697.

13. Yokoi K, Uthus EO, Nielsen FH. Nickel deficiency decreases sperm quantity and motility in rats. Biol Trace Elem Res 2003; 93: 141-153.

14. Sonmez M, Turk G, Yuce A. The effect of ascorbic acid supplementation on sperm quality lipid peroxidation and testosterone levels of male Wistar rats. Theriogenology 2005; 63: 2063-2071.

15. Buege JA, Aust SD. Microsomal lipid peroxidation. Methods Enzymol 1978; 52: 302–310.

UNDER PEER REVIEW

16. Aksenes A, Njaa L. Determination of catalase activity in fish. Comp Biochem Physiol 1981; 69: 893-896.

17. Sedlak J, Lindsay RH. Estimation of total protein-bound and non-protein sulfhydryl groups in tissue with Ellman's reagent. Ann Biochem 1968; 25: 1192–1205.

18. Sun M, Zigma S. An improved spectrophotometric assay of superoxide dismutase based on ephinephrine antioxidation. Ann Biochem 1978; 90: 81-89.

19. Sheehan DC, Hrapchak BB. Theory and practice of histotechnology, 2nd edition. Columbus: Battelle Memorial Institute 1987; 39-40.

20. Kao YH, Chang HH, Lee MJ, Chen CL. Tea, obesity and diabetes. Mol Nutr Food Res 2006; 50:188–210.

21. Bukovsky HL. Hepatotoxicity associated with supplements containing Chinese green tea (*Camellia sinensis*). Ann Intern Med 2006; 144: 68-71.

22. Schilter B, Andersson C, Anton R, Constable A, Kleiner J, O'Brien J, Renwick AG, Korver O, Smith F, Walker R. Guidance for the safety assessment of botanicals and botanical preparations for use in food and food supplements. Food Chem Toxicol 2003; 41, 1625-1649.

23. Vardi N, Parlakpina H, Ates B, Cetin A, Orlu A. Anti-apoptotic and anti-oxidant effects of a carotene against methotrexate - induced testicular injury. Fert Steril 2009; 2 (6): 2028-33.

24. Atessahin A, Karahan T, Turk G, Gur S, Yilmaz S, Ceribasi AO. Protective role of lycopene on cisplatin-induced changes in sperm characteristics, testicular damage and oxidative stress in rats. Reprod Toxicol. 2006; 24: 345-51.

UNDER PEER REVIEW

25. Saalu L.C, Jewo PI, Fadeyibi IO, Ikuerowo SO. The effects of unilateral varicocele on the contra-lateral histo-morphology and function in *Rattus norvegicus* J Med Sci 2008; 8 (7): 654-659.

26. Kawakami E, Hirano T, Hori T, Tsutsui T. Testicular superoxide dismutase activity, heat shock protein 70 concentration and blood plasma inhibin alpha concentration of dogs with a Sertoli cell tumor in a unilateral cryptorchid testis. Vet Med Sci 2007; 69: 1259-1262.

27. Jewo PI, Fadeyibi IO, Saalu LC, Amole OO, Izegbu MC, and Ashiru OA. Effects of short and medium term use of artersunate on spermatogenesis in rats. Nig J Health Biomed Sci 2008, 7 (2): 18-21.

28. Saalu LC, Osinubi AA, Jewo PI, Oyewopo AO and Ajayi GO. An evaluation of influence of citrus paradisi seed extract on doxorubicin-induced oxidative stress and impaired spermatogenesis. Asian J Sci Res. 2010,3, 1:51-61.

29. Gawish AM, Issa AM, Basilly NS, Manaa SM. Role of green tea in nicotine toxicity in liver and lung of mice: Histological and morphometric studies. Afr J Biotech 2012; 11 (8): 2013-2025.

30. Zhong Z, Froh M, Connor ID, Li X, Conzelmann LO, Ronald PM. Prevention of hepatic ischeamia reperfusion injury by grean tea extract. Am J Physiol Gastro 2002; 283: G957-G964.

UNDER PEER REVIEW

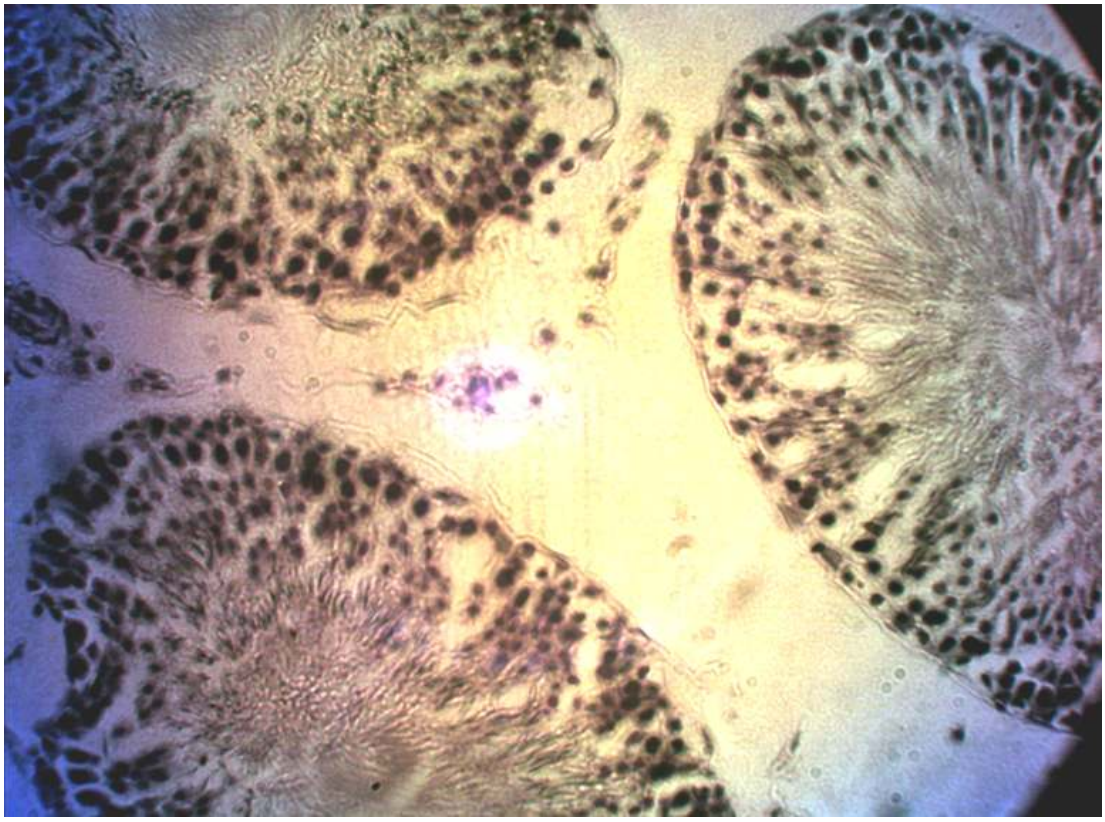

Figure:1

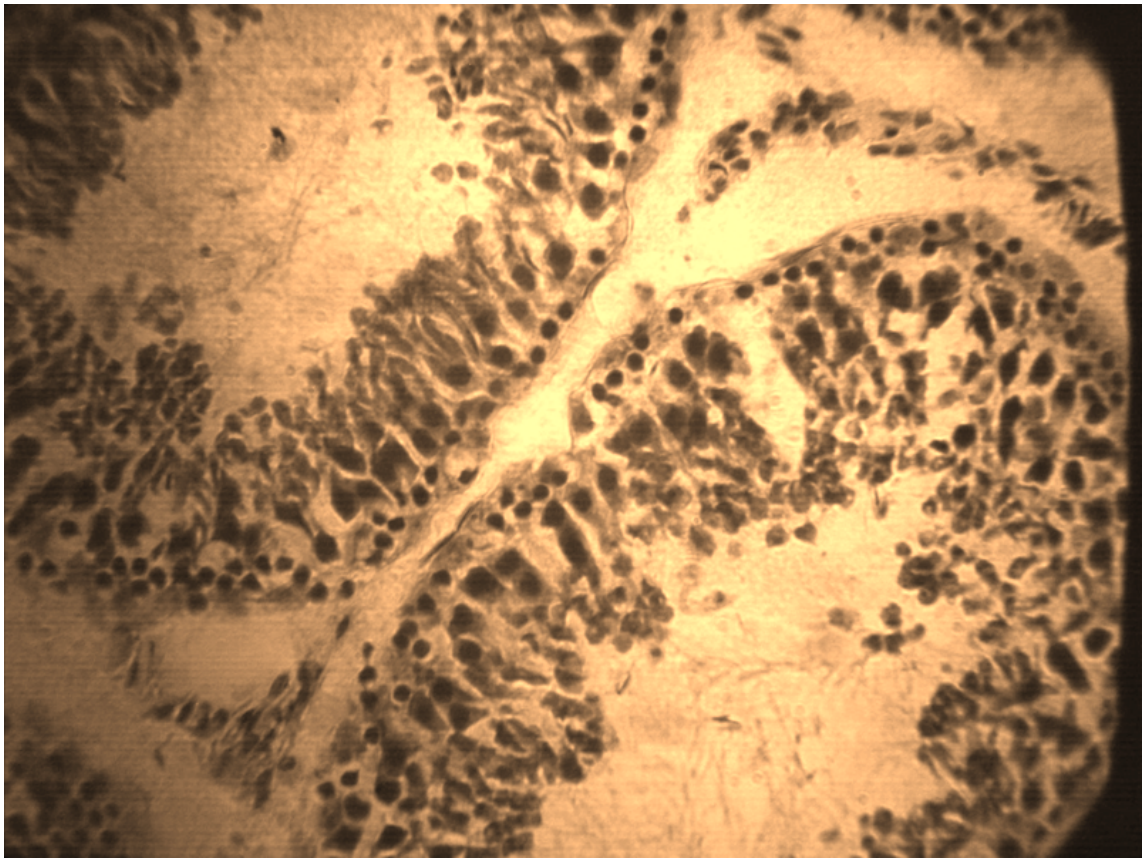

UNDER PEER REVIEW

Figure 2:

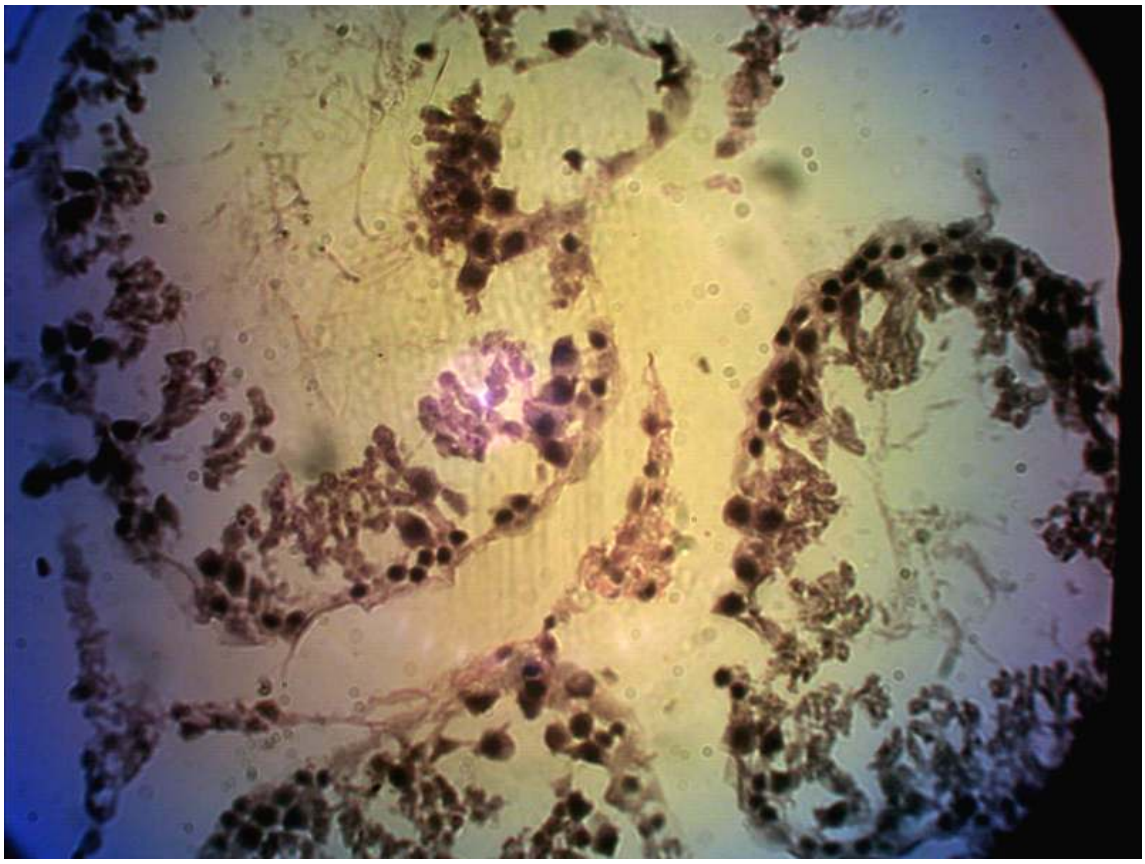

Figure 3:

UNDER PEER REVIEW

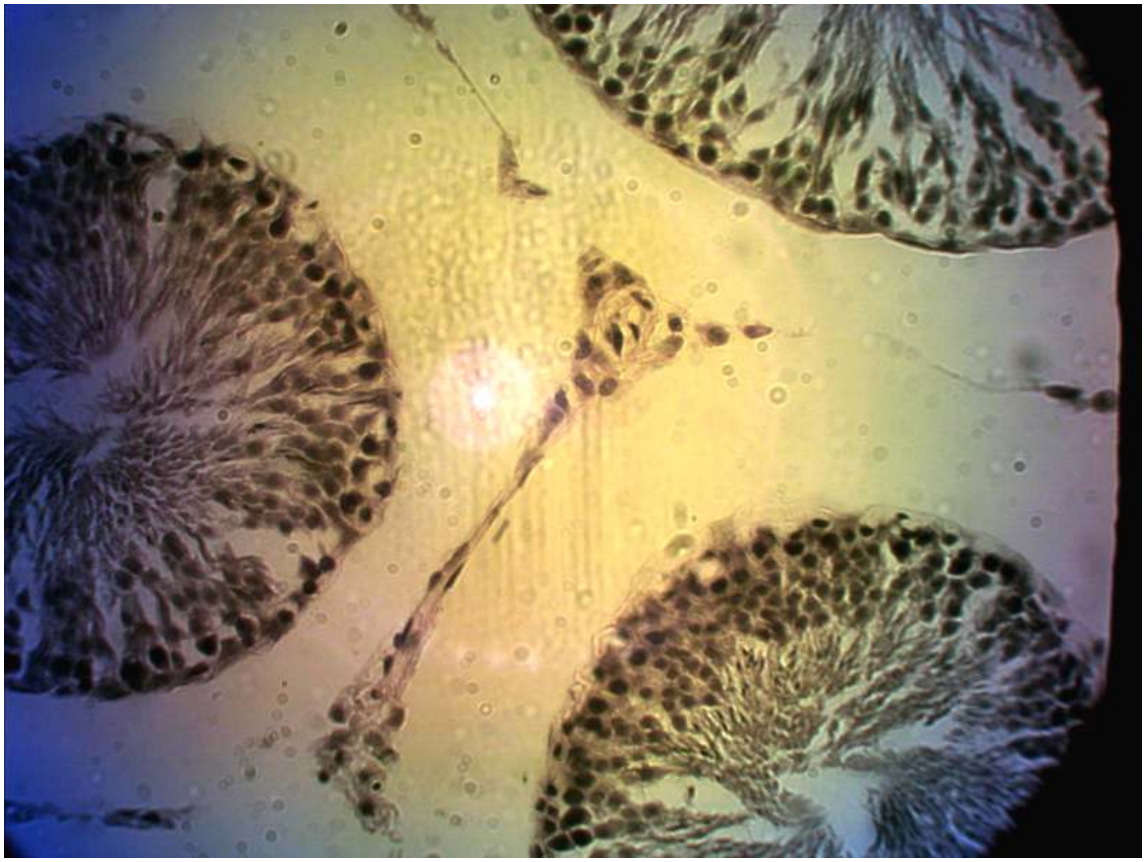

Figure 4:

UNDER PEER REVIEW

Table 1: Effect of MTE and ascorbic acid on body weight and weight and volume of testis

Treatment Groups	Initial Body Weight (g)	Final Body Weight (g)	% Change	Testis Weight (g)	Testis Volume (ml)
Group 1	215.00±91.79	259.00±79.64	10.58±5.41	1.15±0.03	1.00±0.01
Group 2	190.33±44.05	217.67±49.05	7.91±2.37	1.22±0.28	1.13±0.12
Group 3	155.33±6.81	193.33±6.43	10.91±2.07	1.17±0.03	1.17±0.21
Group 4	200.67±24.99 [ab]	253.33±14.05[ab]	11.78±4.61	1.16±0.05	1.13±0.06
Group 5	157.33±7.51[ab]	206.33±9.07 [ab]	13.47±2.52 [ab]	1.27±0.15	1.10±0.17

Table 2: Effect of MTE and ascorbic acid on sperm parameters

Treatment Groups	Total Count ($x10^6$/ml)	Motility (%)	Sperm Abnormal (%)	Morphology Normal (%)
Group 1	76.0±2.0	92.0±2.0	14.1±2.1	85.9±2.1
Group 2	52.7±1.2 [a]	61.7±2.9 [a]	33.9±1.1 [a]	66.1±1.1 [a]
Group 3	45.0±2.0 [ab]	48.3±2.9 [ab]	50.1±13.3 [ab]	43.3±2.9 [ab]
Group 4	69.0±1.0 [ab]	82.7±2.5 [ab]	18.8±1.0 [ab]	81.2±1.0 [ab]
Group 5	80.3±2.5 [ab]	92.7±2.5 [ab]	5.3±1.0 [ab]	93.0±2.3 [ab]

UNDER PEER REVIEW

Table 3: Effect of MTE and ascorbic acid on biochemical parameters

Groups	SOD (µ/mg protein)	CAT (µ/mg protein)	GSH (µ/mg protein)	MDA (µ/mg protein)
Group 1	3.97±0.02	20.03±0.02	1.52±0.02	0.05±0.01
Group 2	2.31±0.02 [a]	16.30±0.01 [a]	0.81±0.01 [a]	0.25±0.01 [a]
Group 3	1.43±0.02 [ab]	15.51±0.02 [ab]	0.48±0.01 [ab]	0.28±0.02 [ab]
Group 4	3.77±0.02 [ab]	18.41±0.02 [ab]	1.03±0.02 [ab]	0.05±0.02 [ab]
Group 5	4.21±0.02 [ab]	21.01±0.02 [ab]	1.64±0.04 [ab]	0.04±0.01