

Authors - Dr. Sibiya. V Ms OBG postgraduate, Saveetha medical college and hospital, Prof and unit cheif Dr. V.Manimekalai department of OBG, Saveetha medical college and hospital, Dr.Paramasivam Manikandan DCH,Dnb paediatrics senior resident department of paediatrics Saveetha medical college and hospital.

ABSTRACT:

Soft tissue tumours account for ~ 25% of all congenital tumours, among which infantile fibrosarcoma is one of the most common nonrhabdomyosarcoma. Infantile fibrosarcoma is a soft-tissue sarcoma occurring under 1 year of age. Forty percent of infantile fibrosarcomas are observed in infants under 3 months of life, which include congenital fibrosarcoma that is discovered antenatally. The prognosis of this tumour is relatively good compared to adult forms. Here we report an unusual case of congenital fibrosarcoma along the paravertebral region of the new born, which was successfully resected. The infant is now 6 months old with no impaired motor development.

Keywords: Infantile fibrosarcoma, paravertebral region, surgery.

INTRODUCTION:

Fibrosarcomas are malignant tumours that predominantly arise in soft tissues. They are <1% of all childhood tumours and are characterized by a cellular proliferation reproducing fibroblasts¹. Surgery with wide resection is the mainstay of treatment. Although histologically similar to fibrosarcomas occurring in adults, the congenital lesions differ in their clinical behaviour. Metastases are rare < 10%, local recurrence is common, and the prognosis is good. Overall survival is given as high as 90% in different series.

CASE REPORT:

- A 23 years old , primigravida with 9 months of amenorrhea came for safe confinement of pregnancy. During her regular antenatal visit, ultrasound showed a solid mass in thoracolumbar region at 22wks. Fetal MRI was done at around 24 weeks which revealed a mass lesion in left posterior paravertebral region(2x2.5x3cm), is attached to muscle, subcutaneous plane and superficial surface of bony spine. Lesion showed solid and cystic component. There was a tiny communication of subarachnoid CSF into the mass and there was no spinal cord extension into the mass- Lipomenigocele . Patient was counseled for termination of pregnancy but patient opted for continuation. Growth scan were normal but tumor was fast growing and highly vascular hence was thought to be sarcoma. The prognosis for sarcoma was poor, hence planned for normal vaginal delivery. At 39 weeks patient went into spontaneous labour and was allowed for normal vaginal delivery. Delivered alive girl baby of birth weight-2.9kg, Apgar 7/10, 8/10. Baby was active, able to move all four limbs. Neonatal MRI showed: Fairly large mixed intense lesion in the left posterior paravertebral region mid dorsal region with no definite intraspinal extension – suggestive of neoplasm(?rhabdomyosarcoma). As the tumor was fast growing the tumor was immediately resected and sent for HPE which was turned out to be fibrosarcoma. Post operatively baby was active moving all four limbs and the milestones are normal till date (6 months of life). And baby is under regular follow up with the paediatrician and is vaccinated till date ie august 2017

DISCUSSION:

1. Fetal tumours have different prevalence, histological characteristics, anatomic location, and biological behaviours than their paediatric counterparts. The reported prevalence of all congenital tumours is 1.7- 13.5 per 100000 live births. Among all congenital tumours 25% are soft tissue tumours and are predominantly benign. However one third are malignant².
2. Infantile fibrosarcomas are rare tumours, , with a male predominance ,with an incidence of 5cases per one million infants ¹. It is common in extremities(71%), then comes the neck and trunk. The main cause of infantile fibrosarcoma still remains unknown, but some gene fusions and some trisomies have been reported¹¹. . More recently, CIF has been found to have t (12;15) translocation leading to the gene fusion ETV6-NTRK3, which is not present in the other diseases. Trisomies of 8, 11, 17, and 20 have also been reported. CIF can mimic and must be differentiated from congenital hemangiopericytoma, infantile fibromatosis/myofibromatosis, malignant fibrous histiocytoma, rhabdomyosarcoma, malignant peripheral nerve sheath tumour, monophasic synovial sarcoma, and leiomyosarcoma clinically. Histopathology, immunohistochemical stains, radiological findings, and physical examination help us to differentiate CIF from other conditions mentioned above¹¹.
3. It presents as a rapidly growing mass at birth or shortly after. Its clinical course is more favourable with a rare metastatic spread. The local recurrence rate is high, up to 43%, and recurrence may occur as late as 15 to 31 years after the initial operation¹³.
4. Surgery still remains the main stay of treatment. In inoperable cases chemotherapy may be the treatment of choice.
5. The prognosis of this tumour is relatively good compared to adult forms. Higher-stage and higher grade tumours of adult form have poor prognosis than lower-grade tumours¹².

CONCLUSION:

Though fibrosarcoma have poor prognosis, when diagnosed and treated earlier they have better prognosis and need multidisciplinary team including obstetricians, neurologist, anaesthetists, neonatologists, paediatric surgeon and geneticists for good obstetric and neonatal outcomes.

CONSENT:

All authors declare that ‘written information consent was obtained from the mother for publication of this paper and accompanying images ‘.

COMPETING INTERESTS:

We do not have any commercial association that might pose a conflict of interest in connection with the manuscript.

ACKNOWLEDGEMENT:

All author here by thank our Department of neonatology ,Department of paediatrics surgery , Department of oncologist ,Department of Transfusion medicine, outpatient staff , Labour room staff, NICU staff, OT staff, blood bank staff for helping in the care given to the patient .

ETHICAL APPROVAL:

All authors hereby declare that the case has been performed in accordance with the ethical standards laid down in the 1964 Declaration of Helsinki.

REFERANCE:

1. Prenatal management of congenital infantile fibrosarcoma: unexpected outcome C. Dumont, M. Monforte, A. Flandrin, A. Couture, R. Tichit, P. Boulot 10.1002/uog.8878 2011
2. Fetal paravertebral congenital fibrosarcoma: MR imaging findings. *Diagnostic and Interventional Imaging* (2016) 97 , 483-485.
3. E. Lesieur, N. Menager, P. Delagausie, A. Verschuur, F. Bretelle, C. Coze, D. Scavarda, B. Guidicelli, G. Gorincour, Fetal paravertebral congenital fibrosarcoma: MR imaging findings, *Diagnostic and Interventional Imaging*, 2016, 97, 4, 483
4. Infantile Fibrosarcoma: Management Based on the European Experience Daniel Orbach, Annie Rey, Giovanni Cecchetto, Odile Oberlin, Michela Casanova, Estelle Thebaud, Marcelo Scopinaro, Gianni Bisogno, Modesto Carli, and Andrea Ferrari.10.1200/JCO.2009.21.9972
5. Unusual case of congenital/infantile fibrosarcoma in a new born Eddiba Tarik, Rouas lamiae, Amrani Abdelouahed, Madhi Tarik, Gourinda Hassan, Dendane Mohammed Anouar, Department of Pediatric Orthopedic and Traumatology, Children's Hospital of Rabat and the Unity of Teaching and Research in Pediatric Surgery, Rabat, Morocco.
6. Gosau M, Draenert FG, Winter WA, Mueller-Hoecker J, Driemel O. Fibrosarcoma of the childhood mandible. *Head Face Med*. 2008;4:21.
7. Aggouris K, Brilakis E, Giokas A. Infantile fibrosarcoma and infantile fibromatosis diagnosis and treatment clinical presentation of three cases. *EEXOT*. 2008;59:170–75.
8. Demir HA, Akyüz C, Varan A, Ergen FB, Büyükpamukçu M. Right foot congenital infantile fibrosarcoma treated only with chemotherapy. *Pediatr Blood Cancer*. 2010;54(4):618–20.
9. Minard-Colin V, Orbach D, Martelli H, Bodemer C, Oberlin O. [Soft tissue tumors in neonates] *Arch Pediatr*. 2009;16(7):1039–48.
10. Orbach D, Rey A, Cecchetto G, Oberlin O, Casanova M, Thebaud E, et al. Infantile fibrosarcoma: management based on the European experience. *J Clin Oncol*. 2010;28(2):318–23.
11. Right foot congenital infantile fibrosarcoma treated only with chemotherapy. *Demir HA, Akyüz C, Varan A, Ergen FB, Büyükpamukçu M, Pediatr Blood Cancer*. 2010 Apr; 54(4):618-20.

12. Adult Soft Tissue Sarcoma Treatment (PDQ®)–Health Professional Version, National cancer institute.
13. A newborn with infantile fibrosarcoma of foot: treatment with chemotherapy and extremity-sparing surgery C Akyüz, N Sari, İ Vargel, G Gedikoglu, M Haliloglu and M Büyükpamukçu *Journal of Perinatology* (2010) 30, 63–65; doi:10.1038/jp.2009.92.

Figure 1

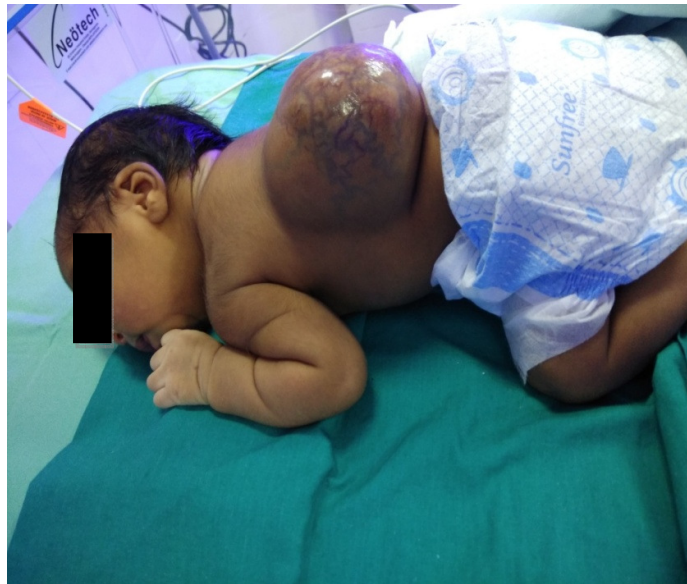

Figure 2

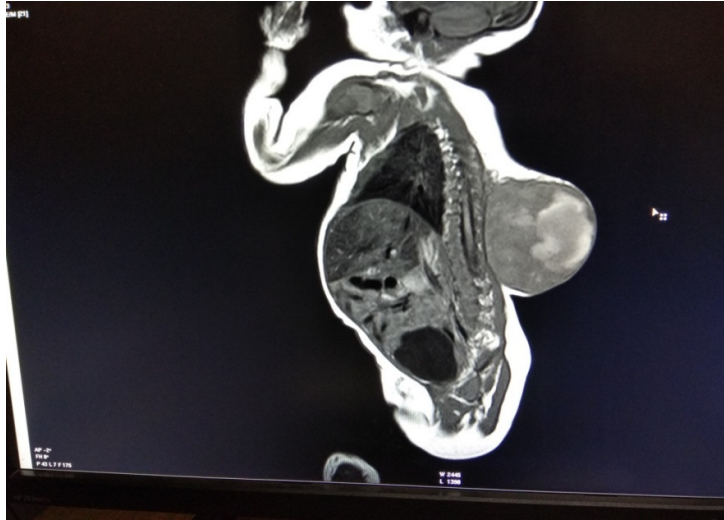


Figure 3

