

Original Research Article

ADENO-HYPOPHYSEAL CONSEQUENCE OF UTERINE FIBROID AND THE EFFECTS OF GINGER EXTRACT ON THE MONOSODIUM GLUTAMATE-INDUCED TUMOR

Olanrewaju A.J.^{1,3}, Olatunji SY¹, Owolabi J.O.¹, Oribamise E.I.¹, Omotuyi O.I.², Desalu A.B.O.¹

¹Department of Anatomy, Benjamin S. Carson School of Medicine, Babcock University, Ilishan-Remo, Ogun State, Nigeria.

²Centre for Bio-computing and Drug Development, Adekunle Ajasin University, Akungba-Akoko, Ondo State, Nigeria.

³Department of Anatomy, College of Health Sciences, University of Ilorin, Ilorin, Kwara State, Nigeria.

afeesjohn@yahoo.com , olanrewaju@babcock.edu.ng

Author's contribution:

This work was carried out in collaboration between all authors. Authors Desalu and Olanrewaju designed, wrote the protocol, supervised the study, performed the statistical analysis, and wrote the first draft of the manuscript. Authors Olanrewaju and Oribamise managed the analyses of the study. Author Oribamise managed data collection, the literature searches, and laboratory work. All authors read and approved the final manuscript.

Abstract:

Background: Uterine fibroids, also referred to as uterine myomas, leiomyomas, myomas, or simply fibroid are benign soft-tissue tumors that arise from uterine smooth muscle tissue (myometrium). They have been described numerously to be hormone-dependent and uterine structure-damaging, but the present study reports the implication of this soft-tissue tumor to the functioning and eventual anatomical change in the pituitary gland and the potential role of ginger extract in reversing the damages.

Aim: To understand uterine fibroids at the level of the pituitary gland, while studying the effects that aqueous extract of ginger will play in the Monosodium Glutamate-induced uterine fibroid

Study design: Experimental

Place and Duration of Study: Department of Anatomy, Benjamin S. Carson School of Medicine, Babcock University, Ilishan-Remo, Ogun State, Nigeria between January 2017 and May 2017

Methodology: Acclimatization lasted for 10 days following procurement, after which oral administration of Monosodium Glutamate (MSG) and Aqueous ginger extract ensued to determine the prophylactic, protective and curative effects of ginger on MSG-induced uterine fibroid in adult female wistar rats. Administration lasted for 50 days, after which the experimental animals were sacrificed via cervical dislocation, blood samples were collected for Luteinizing Hormone (LH) and Follicular Stimulating Hormone (FSH) level determination and the pituitary gland was fixed in 10% formal saline for histological analysis.

Results: The MSG-induced uterine fibroid showed abnormal effects on the pituitary gland histology and in the level of Luteinizing and Follicular Stimulating Hormones, while ginger extract reversed this effect.

Conclusion: Ginger has fibroid-preventing and fibroid-reducing properties at the level of the pituitary gland. The results of this study may contribute greatly to knowledge and may offer a non-invasive therapy of treating women with fibroids.

1. INTRODUCTION

Uterine fibroids are non-malignant tumors of the uterus. Uterine fibroids occur in up to 80% of reproductive-age women, causing significant morbidity in up to 30% of women [5,6,7]. Ethnic origin has been considered one of the known risk factors for uterine leiomyoma and African-American women are at a higher risk of fibroid, as many as 50% have fibroids of a significant size. One study found that between 80% and 90% of African American women and 70% of white women will develop fibroids by age 50 [8]. Among U.S. women ages 25 to 44, about 30% have symptoms of fibroids [9] Affected African American women are more likely to have multiple fibroids [10]. Some studies suggest that black women who are obese and who have high blood pressure are more likely to have fibroids [11]. Also, uterine fibroids are the most common indication for hysterectomy in women of child-bearing age and therefore, are a major health issue in the public: It is the leading indication for hysterectomies in women of reproductive age [12]. Of the 600,000 hysterectomies performed annually in the U.S, one-third are due to fibroids. In the United States, uterine fibroids are a common reason for surgical removal of the uterus [13]. Studies relating to these showed that every year, fibroids lead to more than 200,000 hysterectomies [14], with yearly cost estimates of \$5.9-34.4 billion [15]. Hence, it is of utmost importance that natural, non-surgical therapies such as ginger be investigated for the cure of the global health hazard. Also, according to their location, uterine fibroids are classified as submucosal, intramural or subserosal [1,2,4].

They have been considered as growths with unknown aetiology [16], but depend mostly on estrogen hormone which has cranial control from pituitary hormones including LH and FSH.

The pituitary gland is a pea-sized gland, also known as the master endocrine gland. It measures 12 × 8 mm and weight approximately 500 mg [17]

The hypothalamus and pituitary gland (also referred to as the master gland) regulate the reproductive hormones. The hypothalamus releases the GnRH which, in turn, stimulates the pituitary gland to produce FSH and LH. At the command of FSH and LH, estrogen and progesterone are released from the ovaries [3]. The pituitary gland (hypophysis) is anatomically divided into the anterior and posterior lobes (adenohypophysis and neurohypophysis respectively). The anterior lobe is considered in this study. GnRH-I is the classic hypothalamic hormone responsible for the regulation, synthesis, and secretion of the pituitary gonadotropins FSH and LH [18]. GnRH-I acts on the anterior pituitary leading to the synthesis and storage of gonadotropins, movement of the gonadotropins from the reserve pool to a readily released point, and finally the secretion of gonadotropins. For this action to take place appropriately, pulsatile GnRH release is necessary [19,20]. Continuous GnRH secretion will lead to the suppression of FSH and LH release as well as suppression of FSH and LH gene transcription by the anterior pituitary (Belchetz et al., 1978; Haisenleder, 1991). This is the basis of use of GnRH agonists such as Lupron for the suppression gonadotropin secretion. The pulse frequency of GnRH will vary depending on the menstrual cycle phase. LH pulse frequency is used to indicate GnRH pulse secretion.

MSG: Monosodium Glutamate (MSG) is a salt of glutamate, synthesized from L-glutamic acids; it is also used as a flavour enhancer in foods [23]. It is important to note that various processed and prepared foods such as traditional seasonings sauce and certain restaurant foods contain significant levels of free glutamate (as MSG), both from natural sources and from added monosodium glutamate [24,25]. Various studies have reported the toxicity of MSG in humans and experimental animals [26,27,28]. Also, monosodium glutamate has been used to induce uterine fibroids in experimental animals [29,30].

Ginger (*Zingiber officinale* Roscoe) is one of the most commonly consumed dietary condiments in the world [31], a commonly used spice in the world found to have medicinal precedence [32], reported to have anti-inflammatory [33], anti-oxidant [34], and anti-tumor effects [35].

2. METHODOLOGY

After receiving ethical approval from Babcock University Health Research Ethics Committee (BUHREC), Forty nine (49) healthy, non-pregnant adult female wistar rats (*Rattus norvegicus*) weighing between 190-230g were obtained from, housed, and cared for at the Babcock University animal house, Babcock University, Ilishan-Remo, where a good housing measure was observed as recommended by the Animal Research Review Panel [36]. MSG, which was used to induce uterine fibroid, was obtained from a major seasoning shop at Agric Bus-stop, Ikorodu, Lagos State, dissolved in distilled water to produce the desired concentration of 900mg/kg body weight and stored in the refrigerator below 4°C. The median lethal dose of MSG is 15,000mg/kg [37]. Ginger extract was used as a prophylactic, protective and curative

agent in the present study. As stated earlier, ginger is one of the most commonly consumed dietary condiments in the world [31]. The horizontal stem from which the roots grow, the rhizome, is the main portion of ginger that is consumed. Fresh ginger rhizomes were purchased from Mile 12 market in Lagos directly from Kaduna State Ginger Processing Company in Kaduna, Nigeria. They were cut into thin slices, washed in distilled water and ground in distilled water for 1 minute using a kitchen blender (Gray NutriBullet 12-Piece High-Speed Blender, with a High-torque power base and 600-watt motor). The ground mixture was filtered through a fine cotton cloth and the aqueous extracts was administered orally to the animals in various grades (i.e., 500mg/kg, 900mg/kg, 1,700mg/kg) as instructed by the treatment regimen in Table 1.0. After the animals were allowed to acclimatize for a period of 10 days with free access to feed and water, administration began.

Table 1.0: Table showing treatment regimen design for control and experimental groups

GROUP	Animals	Treatment schedule	Rationale
Group A	7	A placebo of water	Control group
Group B	7	Animals were treated orally with 900mg/kg body weight of MSG only for 25 consecutive days	(Negative control group) To induce Uterine fibroid
Group C	7	Animals receiving 900mg/kg body weight of ginger extract only for 25 consecutive days	(Positive control group) A placebo for ginger extract
Group D	7	Animals receiving 900mg/kg body weight of ginger extract orally for 25 days, followed by oral administration 900mg/kg of MSG for 25 consecutive days	Prophylactic group
Group E	7	Animals receiving oral administration of 900mg/kg of MSG + 900mg/kg body weight of ginger extract for 25 consecutive days	Protective group
Group F	7	Animals receiving oral administration of 900mg/kg of MSG for 25 consecutive days, followed by oral administration of low dose ginger (500mg/kg) extract for 25 consecutive days	(Curative group 1) To reverse uterine fibroid induced by MSG
Group G	7	Animals receiving oral administration of 900mg/kg of MSG for 25 consecutive days, followed by oral administration of high dose ginger (1,700mg/kg) extract for 25	(Curative group 2) To reverse uterine fibroid induced by

		consecutive days	MSG
--	--	------------------	-----

For each of the animals in groups A, F and G, blood tests were carried out on the 25th day to confirm the presence of fibroids before administration of ginger extract. These were done using the Accubind ELISA kit (2013) to test for the levels of estradiol and progesterone in the serum of the respective animals. The animals in Groups F and G showed abnormally high levels of serum estradiol and progesterone in contrast to those of the control group. As earlier stated, it is also important to note that Obochi *et al.* (2009), Zia *et al.* (2012) and Koffour *et al.* in 2013, amongst other authors have carried out biochemical assays on serum estradiol, serum progesterone as these hormones have been reported to be notable markers for uterine fibroid.

The day after the last administration, the experimental animals were weighed, in the early hours of the day between the hours of 09:00 to 12:00, blood was also collected from their orbit using a micro-hematocrit capillary tube, the animals were weighed and then sacrificed by cervical dislocation. The portion of brain tissue near the pituitary gland was excised from animals in each group and fixed in 10% formal saline for histological demonstration.

Procedure for Haematoxylin and Eosin (H&E) for general histoarchitecture of the Pituitary glands

SERUM FSH and SERUM LH [using Elabscience ELISA kit (2015)]

After blood was collected from the animals through ocular puncture and transferred into plain red-covered, clot-activator sample bottles, the blood was allowed to clot and then centrifuged at 3000rpm for 15 minutes to separate serum from the cells. Serum samples were then refrigerated at -7°C for 4 days (this is so as to prevent loss of bioactivity and contamination)

Statistical Analysis

Bar graphs were obtained by the software Graph Pad Prism for Windows version 5 (GraphPad Software, San Diego, CA, USA) and subjected to One-Way Analysis of Variance (ANOVA) with Newman-Keuls's *post hoc* test. $P \leq 0.05$ was considered statistically significant in all analysis.

3. RESULTS

3.1. Results from fibroid confirmation

3.1.1. Serum estradiol level:

Group A: Control group

Group F: MSG → Ginger low dose

Group G: MSG → Ginger high dose

Results from biochemical confirmation of uterine fibroid before commencement of ginger extract showed in Fig 1.0 that estradiol levels of groups F (25.28 ± 1.414) and G (26.23 ± 1.403) were significantly higher than that of the group A (7.677 ± 0.4707)

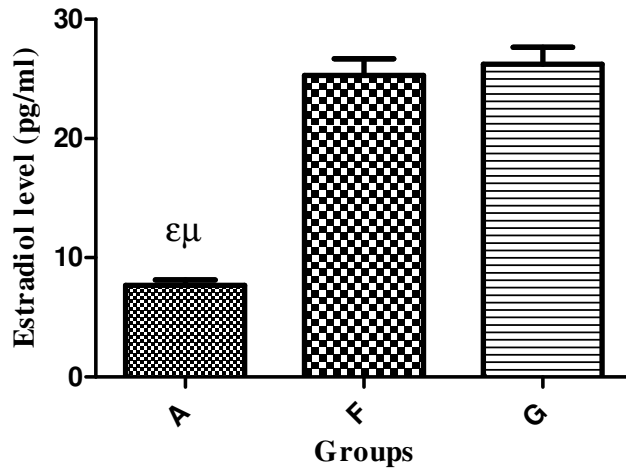


Fig 1.0. Bar graph showing estradiol levels (pg/ml) across groups A, F, G

$\epsilon = P < 0.05$ when compared with Group F

$\mu = P < 0.05$ when compared with Group G

3.1.2. Serum progesterone level:

Group A: Control group

Group F: MSG → Ginger low dose

Group G: MSG → Ginger high dose

Results from biochemical confirmation of uterine fibroid before commencement of ginger extract showed in Fig 1.1 that estradiol levels of groups F (12.45 ± 0.6867) and

G (12.71 ± 0.7123) were significantly higher than that of the group A (6.390 ± 0.3635)

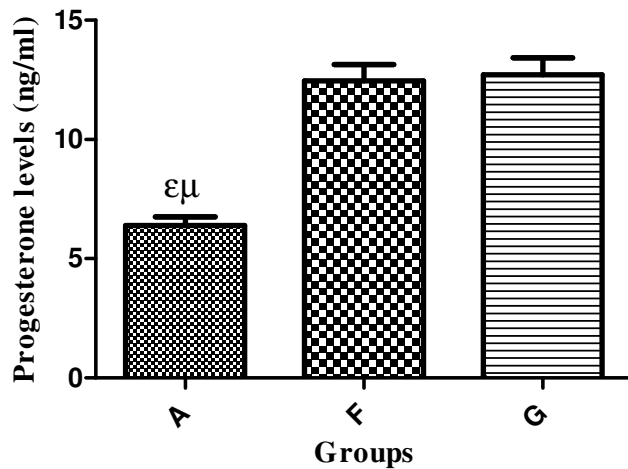


Fig 1.1. Bar graph showing progesterone levels (ng/ml) across groups A, E, F

$\epsilon = P < 0.05$ when compared with Group E
 $\mu = P < 0.05$ when compared with Group F

HISTOLOGICAL ANALYSIS

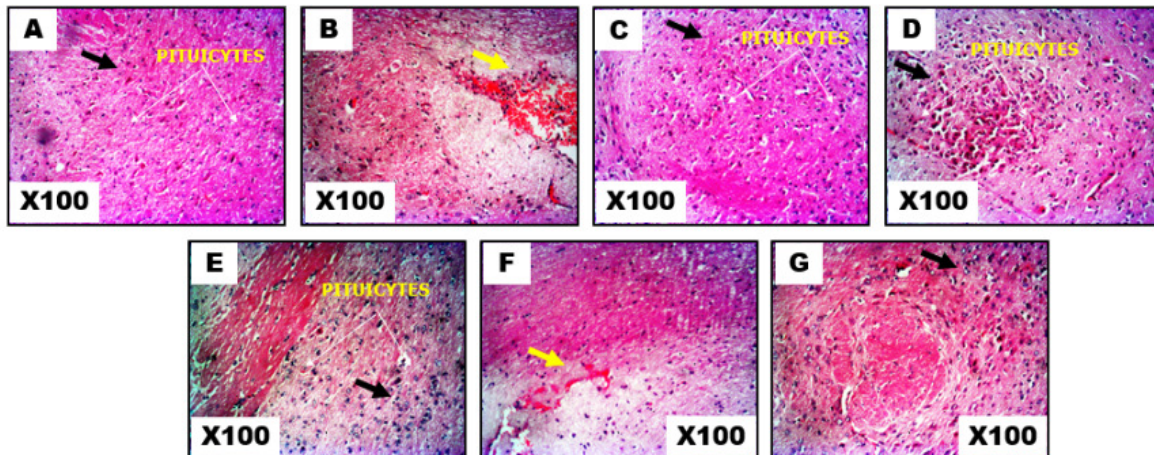


Plate 1: Photomicrographs showing panoramic views of hypophyseal general histomorphological presentations in Adult female Wistar rats across the various groups A-G. H&E stain ($\times 100$).

Luteinizing Hormone (LH) level

- Group A: Control
- Group B: MSG only
- Group C: Ginger only
- Group D: Ginger \rightarrow MSG
- Group E: Ginger + MSG
- Group F: MSG \rightarrow Ginger (Low dose)

Group G: MSG → Ginger (High dose)

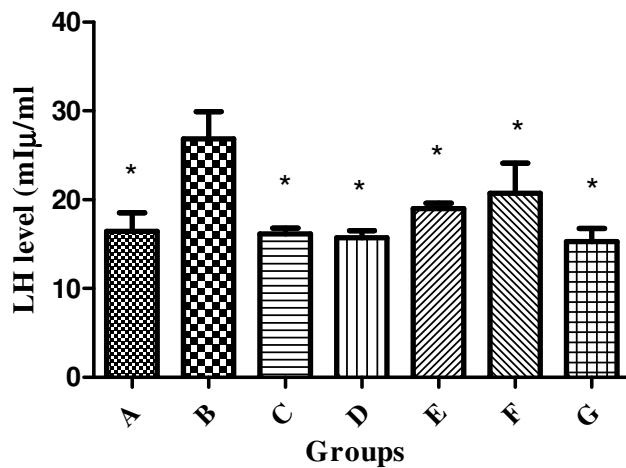


Fig 1.2. Bar graph showing LH levels (mIU/ml) of control and experimental groups

*= $P < 0.05$ when compared with Group B

As shown in Fig 1.2., there was a statistically significant increase in the LH level of group B (26.84 ± 3.088) in comparison with that of group A (16.44 ± 2.067). Also, when compared to group B, there was a significant decrease in the LH levels of groups D (15.72 ± 0.8120), E (19.01 ± 0.6106), F (20.71 ± 3.410), G (15.30 ± 1.458), as these groups held no statistical significant difference when compared to group A (16.44 ± 2.067). Also, in comparison with group A, Group C (16.17 ± 0.6548) held no significant statistical difference.

It is also depicted in Fig 1.2. that group B (26.84 ± 3.088) had the highest LH level while group G (15.30 ± 1.458) had the lowest.

LH levels were more pronounced in uterine fibroid animals than in the control animals. Also there was a decrease in the level of LH in the ginger-administered groups.

FOLLICLE-STIMULATING HORMONE (FSH) LEVEL

Group A: Control

Group B: MSG only

Group C: Ginger only

Group D: Ginger → MSG

Group E: Ginger + MSG

Group F: MSG → Ginger (Low dose)

Group G: MSG → Ginger (High dose)

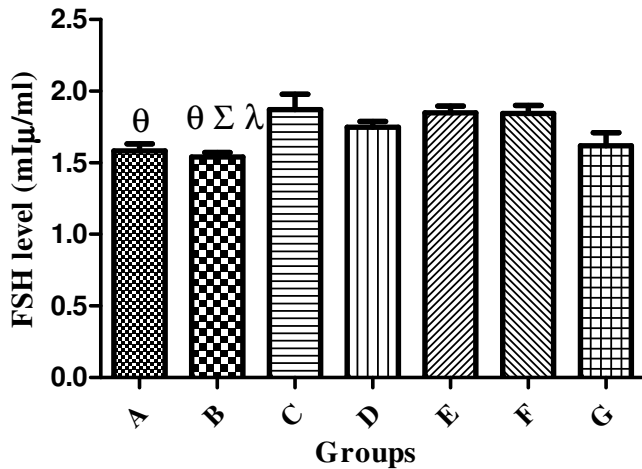


Fig 1.3. Bar graph showing FSH levels (mIU/ml) of control and experimental groups

$\theta = P < 0.05$ when compared with Group C

$\lambda = P < 0.05$ when compared with Group F

$\Sigma = P < 0.05$ when compared with Group E

FSH levels were slightly decreased in uterine fibroid animals than in the control animals. Also there was an increase in the level of FSH in the ginger-administered groups.

4. DISCUSSION

Results from an attempt to confirm the presence of uterine fibroid in this study showed that the groups induced with uterine fibroid showed increased levels of estradiol - E2 (the form of estrogen found in non-pregnant conditions) and progesterone when tested. There was a remarkable rise in the estradiol level of groups E and F when compared to the control group. This can be attributed to the fact that estrogen promotes the growth of uterine fibroids, as these benign tumors have been described as estrogen-feeding tumors [38,39]. MSG which was used to induce the uterine fibroid has been reported to increase estrogen levels in experimental animals thus causing fibroid growth. The mechanism behind the MSG-induced fibroid formation and growth doesn't just involve the hormones estrogen and progesterone but also circulating enzymes and hormone receptors. Aromatase and 17beta-hydroxysteroid dehydrogenase enzymes are aberrantly expressed in fibroids. Some of the known factors that increase aromatase activity are age, insulin, obesity, gonadotropins, and alcohol [40]. Aromatase and 17beta-hydroxysteroid dehydrogenase convert circulating androstenedione (a pro-hormone released by the adrenal cortex & ovaries) into estradiol [68]. Estradiol action is then mediated by its nuclear receptors ER α and ER β to promote other uterine-fibroid-inducing conditions, amongst which is to induce the production of Progesterone Receptor (PR) which is then responsible for the response of uterine tissues to progesterone secreted by the ovaries. Upon ligand binding, these receptors act as transcriptional factors that up- or down-regulate gene expression by interacting with the regulatory regions of target

genes. Estrogen also promotes fibroid growth by up-regulating Transforming Growth Factor- β 3 which leads to increased cell proliferation, Insulin Growth Factor-1, Epidermal Growth Factor Receptor, and Platelet-derived Growth Factor (PDGF), and also promotes the abnormal survival of leiomyoma cells by reducing apoptosis through down-regulation of p53, increasing expression of the anti-apoptotic factor PCP4 and antagonizing PPAR-gamma signaling [41]. Progesterone also promotes growth of leiomyoma through up-regulating EGF, TGF-beta1 and TGF-beta3, and promotes survival through up-regulating Bcl-2 expression and down-regulating TNF-alpha [42,43]. Estrogen and Progesterone, through their up-regulation of TGF- β 3 and down-regulation of p53, increases cell proliferation and survival and enhances extracellular matrix formation through induction of fibrosis which is characterized by resistance to apoptosis leading to the persistence of cells, and secretion of collagen and other ECM components by those cells leading to abundant disposition of highly cross-linked, disoriented, and often widely dispersed collagen fibrils. Also, the stiffness of ECM that surrounds the cells depends on the amount of cross-linking of the newly secreted altered collagen. ECM stiffness have been reported to contribute to fibroid growth. [44].

Histologically, in conjunction with hormonal assay of LH and FSH, the photomicrographs of the pituitary gland were captured a magnification of x100 for better appreciation of cellular components. Neurohypophysis is well demonstrated while adenohypophysis is not conspicuous at this cortical section, pars distalis, pars intermedia and pars nervosa are the various parts of the hypophysis associated with different secretions. Results showed that Plate 1A, which represents the control group at a magnification of x100, had no abnormality, unlike the negatively-induced group where there was degeneration of pituicytes. Across the groups, degenerative changes as well as presentation of red and inflammatory cells are seen present in treated group B & F (yellow arrows) as against the control group A & C with well outlined panoramic cytoarchitectural presentation (black arrows). Hence, it is safe to say Monosodium Glutamate treatment induces degenerative changes in the cytoarchitectural presentation of the pituitary gland as demonstrated by H&E stain. Treatment received by groups D, E & G showed a mild degenerative change – not very conspicuous. These findings can be attributed to the fact that in group B, MSG-induced uterine fibroid caused over-production of estrogen and LH which has been reported to be a trigger for estrogen hormone also. This finding is in conjunction with works done by Danuta Plewka et al. in 2014 [46]. As seen, compared to the negative induced group, LH levels were lower in all ginger-treated groups especially in the prophylactic and high-dosed curative groups. FSH levels in the present study were not increased in the uterine fibroid group, but were seen to increase in the group administered ginger only.

In a research article titled, “Receptors of Hypothalamic-Pituitary-Ovarian-Axis Hormone in Uterine Myomas” by Danuta Plewka et al. in 2014, the expression of GnRH, FSH, LH, amongst other parameters were examined in uterine myomas of women in reproductive and perimenopausal ages, results from this study showed

that in myomas of women in reproductive age, independently of their size, expression of GnRH, FSH, and LH receptors was more pronounced than in myometrium. In women of peri-menopausal age, independently of myoma size, expression of LH was higher while expression of GnRH receptors was lower than in myometrium. FSH receptor expression was not observed.

These findings can be compared to results from the study “The anti-oxidant effects of ginger and cinnamon on spermatogenesis dys-function of diabetes rats” by Khaki *et al.* in 2014 [47].

Also, published in the New York Times, an article titled, “Fibroids In-Depth Report” stated that in women, six hormones serve as chemical messengers that regulate the reproductive system: the hypothalamus first releases the GnRH which then stimulates the pituitary gland to produce FSH and LH [48]. Estrogen, progesterone and the male hormone testosterone are then secreted by the ovaries at the command of FSH and LH. As stated earlier, it is not clear what causes fibroids, but estrogen and progesterone have been reported to play a role in their growth. Also, an article titled, “Zoladex (goserelin)” in 2009 [49], reported that the amount of FSH and LH released from the pituitary gland is controlled by another hormone called gonaderelin (LHRH). This hormone acts on LHRH receptors in the pituitary gland, causing the release of LH and FSH, hence subsequent release of estrogen in women. GnRH is secreted into the portal pituitary circulation, reaching the anterior pituitary to affect FSH and LH release from the anterior pituitary.

Although there is very little that has been reported on the relationship between uterine fibroid and the master gland, With respect to the anterior pituitary gland in this study, there were degenerative changes in the negative-induced and low-dosed curative groups. These changes were seen to have been prevented, reversed or reduced in the prophylactic, protective and high-dosed curative groups.

5. CONCLUSION

While ginger prevented and reversed these effects, Uterine fibroid affects the brain at the level of the pituitary gland as a result of over-production of FSH and LH which in turn increases estrogen and progesterone production that causes further increase of the fibroid volume, as fibroids are estrogen-feeding tumors. While ginger prevented and reversed these effects.

References:

1. Vitiello D., & McCarthy S. (2006). Diagnostic imaging of myomas. *Obstetrics and Gynecology Clinics of North America.*; 33(1):85–95.
2. Brosens I (2006): *Uterine Leiomyomata: Pathogenesis and Management.* Abingdon, England, Informa Healthcare/Taylor & Francis.

3. Marshall LM, Spiegelman D, Goldman MB, et al (1998). A prospective study of reproductive factors and oral contraceptive use in relation to the risk of uterine leiomyomata. *Fertil Steril*;70:432e9.
4. Reis FM, et al. (2015). Hormones and pathogenesis of uterine fibroids, *Best Practice & Research Clinical Obstetrics and Gynaecology*, 1-12 <http://dx.doi.org/10.1016/j.bpobgyn.2015.11.01>. *Hormones and pathogenesis of uterine fibroids*
5. Cramer SF, Patel A (1990). The frequency of uterine leiomyomas. *Am J Clin Pathol*. 94(4):435-438.
6. Myers ER, Barber MD, Gustilo-Ashby T, Couchman G, Matchar DB, McCrory DC (2002). Management of uterine leiomyomata: what do we really know? *Obstet Gynecol*, 100(1):8–17. doi: 10.1016/S0029-7844(02)02019-7.
7. Bulun S. E. (2013). Uterine Fibroids. *New England Journal of Medicine*. 369: 1344-1355
8. Baird, D. D., Dunson, D. B., Hill, M. C., Cousins, D., & Schectman, J. M. (2003). High cumulative incidence of uterine leiomyoma in black and white women: Ultrasound evidence. *American Journal of Obstetrics and Gynecology*, 188(1), 100–107.
9. Hartmann, K. E., Birnbaum, H., Ben-Hamadi, R., Wu, E. Q., Farrell, M. H., Spalding, J., et al. (2006). Annual costs associated with diagnosis of uterine leiomyomata. *Obstetrics and Gynecology*, 108, 930–937. Retrieved April 11, 2012, from http://journals.lww.com/greenjournal/Fulltext/2006/10000/Self_Reported_Heavy_Bleeding_Associated_With.17.aspx
10. Laughlin, S. K., Baird, D. D., Savitz, D. A., Herring, A. H., & Hartmann, K. E. (2009). Prevalence of uterine leiomyomas in the first trimester of pregnancy: An ultrasound-screening study. *Obstetrics and Gynecology*, 113, 630–635. Retrieved April 11, 2012, from http://journals.lww.com/greenjournal/fulltext/2009/03000/prevalence_of_uterine_leiomyomas_in_the_first.10.aspx
11. "Black Women and High Prevalence of Fibroids". *Fibroid Treatment Collective*. November 29, 2010. Retrieved 30 March 2011.
12. Cooper, P. G (2004). *Uterine Fibroids*. [© 2003 McKesson Health Solutions LLC., Clinical Reference Systems 2004 Women's Health Advisor, Elsevier Inc.]; Accessed 15 June, 2013 from <http://www.cumc.columbia.edu/student/health/pdf/E-H/Fibroids.pdf>.
13. Wallach EE, Vlahos NF (2004). "Uterine myomas: an overview of development, clinical features, and management". *Obstet Gynecol*, 104 (2): 393-406.
14. Agency for Healthcare Research and Quality (AHRQ). (2007). *Management of uterine fibroids: An update of the evidence* (AHRQ Publication No. 07-E011). Retrieved December 8, 2011, from <http://archive.ahrq.gov/downloads/pub/evidence/pdf/uterupdate/uterup.pdf> (PDF - 343 KB).

15. Cardozo ER, Clark AD, Banks NK, Henne MB, Stegmann BJ, Segars JH (2012 Mar). The estimated annual cost of uterine leiomyomata in the United States. *Am J Obstet Gynecol.*;206(3):211.e1-9.
16. Andrea Ciavattini, Jacopo Di Giuseppe, Piergiorgio Stortoni, Nina Montik, Stefano R. Giannubilo, Pietro Litta, Md. Soriful Islam, Andrea L. Tranquilli, Fernando M. Reis, and Pasquapina Ciarmela (2013). Uterine Fibroids: Pathogenesis and Interactions with Endometrium and Endomyometrial Junction. *Obstetrics and Gynecology International Volume 2013*, Article ID 173184, 11 pages <http://dx.doi.org/10.1155/2013/173184>
17. Mancall, Elliott L.; Brock, David G., eds. (2011). "Cranial Fossae". *Gray's Clinical Anatomy. Elsevier Health Sciences.* p. 154. ISBN 9781437735802.
18. Yao B, Liu HY, Gu YC, Shi SS, Tao XQ, Li XJ, et al (2011). Gonadotropin-releasing hormone positively regulates steroidogenesis via extracellular signal-regulated kinase in rat Leydig cells. *Asian J Androl*;13(3):438–45.
19. Knobil E (1980). The neuroendocrine control of the menstrual cycle. *Recent Prog Horm Res.*;36:53–88.
20. Mais V, Kazer RR, Cetel NS, Rivier J, Vale W, Yen SS (1986). The dependency of folliculogenesis and corpus luteum function on pulsatile gonadotropin secretion in cycling women using a gonadotropin-releasing hormone antagonist as a probe. *J Clin Endocrinol Metab*;62(6):1250–5.
21. Belchetz PE, Plant TM, Nakai Y, Keogh EJ, Knobil E (1978). Hypophysial responses to continuous and intermittent delivery of hypothalamic gonadotropin-releasing hormone. *Science*;202(4368): 631–3.
22. Haisenleder DJ, Dalkin AC, Ortolano GA, Marshall JC, Shupnik MA (1991). A pulsatile gonadotropin-releasing hormone stimulus is required to increase transcription of the gonadotropin subunit genes: evidence for differential regulation of transcription by pulse frequency in vivo. *Endocrinology*;128(1):509–17.
23. Ikonomidou C, Turski L. (1995). Glutamate in neurodegenerative disorders. In: Stone TW Ed. *CNS neurotransmitters and neuromodulators: Glutamate. Boca Raton, Florida: CRC press; 253-272.*
24. Eskes, T. K. (1998). Neural tube defects, vitamins and homocysteine. *European Journal of Pediatrics.*, 157(52), 5139-5141.
25. Rodriguez, M.C., J.A. Obeso and C.W. Olanow, (1998). Sub thalamic nucleus-mediated excitotoxicity in Parkinson's disease: A target for neuroprotection. *Am. Neurol.*, 44: 174-188.
26. Eweka A.O. & Om'Iniabo F.A.E. (2011). Histological Studies of the effects of Monosodium Glutamate on the ovaries of Adult Wistar Rats. *Annals of Medical and Health Sciences Research.* 1(1), 37-43.
27. Dixit S.G., Rani P., Anand A., Khatri K., Chauhan R., Bharihoke V. (2014). To study the effects of Monosodium Glutamate on Histomorphology of cortex of kidney in adult albino rats. 36(2), 266-270.

28. Veronika Husarova & Daniela Ostatnikova (2013). Monosodium Glutamate Toxic Effects and their implications for Human Intake: A Review. *JMED Research*: 2013(2013). Doi:
29. Obochi GO, Malu SP, Obi-Abang M, Alozie Y, Iyam MA. (2009)Effect of garlic extracts on monosodium glutamate (MSG) induced fibroid in Wistar Rats. *Pakistan Journal of Nutrition.*;8(7):970-76. DOI: 10.3923/pjn.2009.970.976.
30. Koffuor, A. G., Annan, K., Kyekyeku, J. O., Fiadjoe, H. K., & Enyan, E. (2013). Effect of Ethanolic Stem Bark Extract of *Blighia unijugata* (Sapindaceae) on Monosodium Glutamate-Induced Uterine Leiomyoma in Sprague-Dawley Rats. *British Journal of Pharmaceutical Research*, 3(4), 880-896.
31. Surh Y. J, Park K. K, Chun K. S, Lee L. J, Lee E, Lee S. S (1999). Anti-tumor-promoting activities of selected pungent phenolic substances present in ginger. *J Environ Pathol Toxicol Oncol*;18(2):131–9.
32. Koh E.M., Kim H.J., Kim S., Choi W.H., Choi Y.H., Ryu S.Y., Kim S.Y., *et al.* (2009). Modulation of macrophage functions by compounds isolated from *Zingiber officinale*. *Planta medica*. 75(2), 148-151
33. Young HY, Luo YL, Cheng HY, Hsieh WC, Liao JC, Peng WH (2005). Analgesic and anti-inflammatory activities of [6]-gingerol. *J Ethnopharmacol*, 96, 207–210.
34. Stoilova I, Krastanov A, Stoyanova A, Denev P, Gargova S (2007). Antioxidant activity of a ginger extract (*Zingiber officinale*). *Food Chem*, 102, 764-770
35. Shukla Y, Singh M (2007). Cancer protective properties of ginger: a brief review. *Food Chem Toxicol*, 45(5), 683-690
36. *Animal Research Review Panel. (2002). Guidelines for the Housing of Rats in Scientific Institutions. Guideline 20, pg 1-74.*
37. Walker R, Lupien JR (April 2000). School of Biological Sciences, Univeristy of Surrey, UK, and Food and Nutrition Division, FAO of the United Nations, Italy. "The Safety evaluation of monosodium glutamate". *Journal of Nutrition* 130(4S Suppl): 1049S-52S
38. Center for Uterine Fibroids (2011). What are fibroids? Boston: Brigham and Women's Hospital; 2006 Sept 19 [cited 2011 Mar 13]; [about 3 screens]. Available from: <http://www.fibroids.net/aboutfibroids.html>.
39. Veronica Medikare, Lakshmi Rao Kandukuri, Venkateshwari Ananthapur, Mamata Deenadayal, and Pratibha Nallari. The Genetic Bases of Uterine Fibroids; A Review. *J Reprod Infertil*. 2011 Jul-Sep; 12(3): 181–191.
40. Purohit V (2000). Can alcohol promote aromatization of androgens to estrogens? A review. *Alcohol*. Nov;22(3):123-7.
41. Davis BJ, Risinger JI, Chandramouli GVR, Bushel PR, Baird DD, Peddada SD (2013) Gene Expression in Uterine Leiomyoma from Tumors Likely to Be Growing (from Black Women over 35) and Tumors Likely to Be Non-Growing

- (from White Women over 35). PLoS ONE 8(6): e63909. <https://doi.org/10.1371/journal.pone.0063909>
42. J. Julie Kim* and Elizabeth C. Sefton (2012 Jul 25). The role of progesterone signalling in the pathogenesis of uterine leiomyoma. *Mol Cell Endocrinol*; 358(2): 223–231.
 43. Cermik D, Arici A, Taylor HS (2002). Coordinated regulation of HOX gene expression in myometrium and uterine leiomyoma. *Fertil Steril*;78:979–84
 44. P. C. Leppert, T. Baginski, C. Prupas, W. H. Catherino, S. Pletcher, and J. H. Segars (2004). “Comparative ultrastructure of collagen fibrils in uterine leiomyomas and normal myometrium,” *Fertility and Sterility*, vol. 82, supplement 3, pp. 1182–1187.
 45. Nafiseh Shokri Masshadi, Reza Ghiasvand, [...], and Mohammad Reza Mofid (2013). Anti-Oxidative and Anti-Inflammatory Effects of Finger in Health and Physical Activity: Review of Current Evidence. *International Journal of Preventive Medicine*. 4(Suppl 1): S36-S42.
 46. Danuta Plewka, JacekMarczyNski, Micha Morek, Edyta Bogunia, and Andrzej Plewka. Receptors of Hypothalamic-Pituitary-Ovarian-Axis Hormone in Uterine Myomas. *BioMed Research International*. Volume 2014, Article ID 521313, 13 pages
 47. Arash Khaki, Amir Afshin Khaki, Laleh Hajhosseini, Farhad Sadeghpour Golzar, Nava Ainehchi. (2014). THE ANTI-OXIDANT EFFECTS OF GINGER AND CINNAMON ON SPERMATOGENESIS DYS-FUNCTION OF DIABETES RATS. *Afr J Tradit Complement Altern Med*. (2014) 11(4):1-8
 48. Fibroids In-Depth Report. *The New York Times*. nytimes.com
 49. Zoladex (goserelin). 15 April 2009. Netdoctor.co.uk