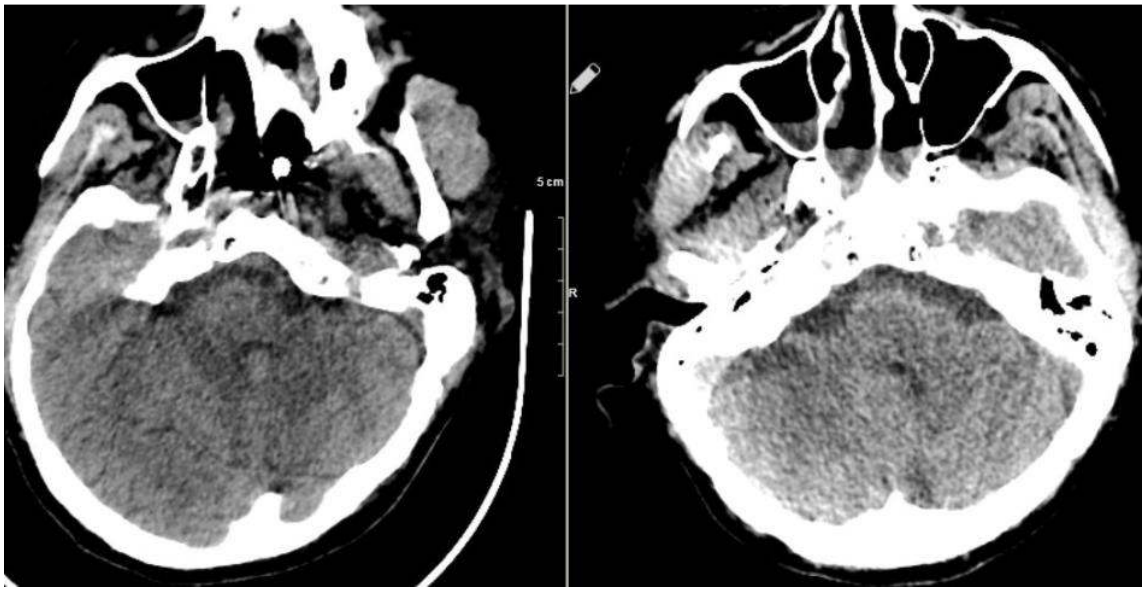
5 cm
R

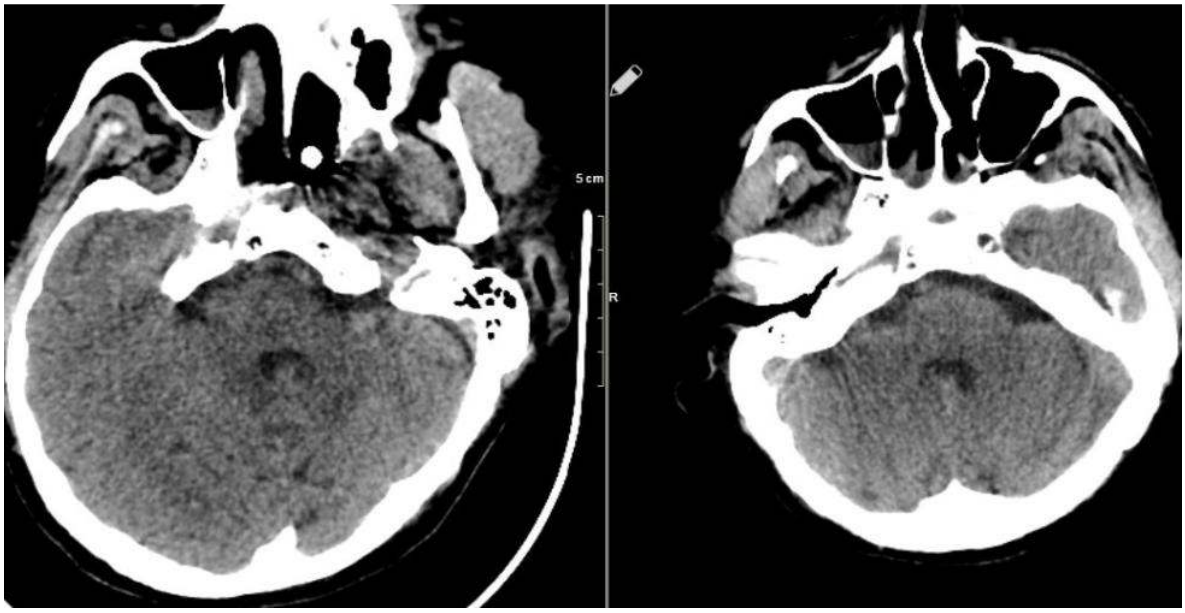
5 cm
R

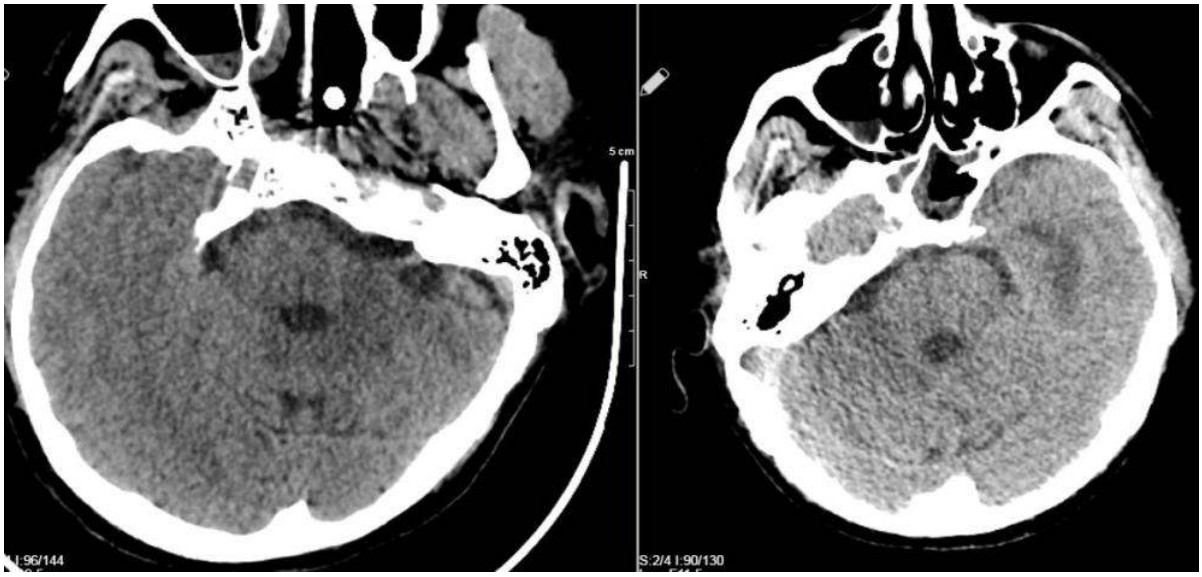

We do not observe clear differences in the size of the fourth ventricular as it has been shown in the above axial plan cranial CT compresion of slice images between the first CT on the left and the second CT which was taken 48 hours on the right views. Although there is asymetry between the two CT's but we can observe clear dilatation of the third and the lateral ventricular in the imges we have send before but not the fourth ventricular.