RHEUMATOID ARTHRITIS IN IMAGE OF MAGNETIC RESONANCE: A PROPOSAL FOR REVIEW OF LITERATURE.

Rebeson Moraes da Silva[6]; Daniele Salgado de Sousa[4,5]; Fábio Salgado da Silva[2,6]; Ysadora Maria Rodrigues Pinto[7]; Dhiego Lima Costa[1,3]; Matheus Pinheiro[8]; Vitor Hugo Auzier Lima[4,9].

1 Department of Biology, UFPA - Federal University of Pará, Pará, Brazil.
2 Department of Medicine, UEPA - University of the State of Pará, Brazil.
3 Department of Environmental Microbiology, UFPA - Federal University of Pará, Brazil.
4 Department of Biotechnology, UFPA - Federal University of Pará, Pará, Brazil.
5 Department of Natural Sciences, UFPA - Federal University of Pará, Pará, Brazil.
6 Department of Magnetic Resonance Imaging, Porto Dias Hospital, Pará, Brazil.
7 Department of Social Assistance, FAMAZ - Metropolitan Faculty of Amazon, Pará, Brazil.
8 Department of Exercise Physiology, CESUPA - Pará State University Center, Brazil.
9 Department of Physiotherapy, UEPA - State University of Pará, Pará, Brazil.

ABSTRACT

Rheumatoid arthritis is a chronic poly arthritis of unknown etiology resulting in progressive destruction of bone and joint failure may be assessed by methods OMERACT group as RAMRIS, resulting tool advances in MRI. Objective: This study aimed to offer a new reading of magnetic resonance imaging in the diagnosis and monitoring of rheumatoid arthritis, describing results obtained by various authors using the criteria of OMERACT (Measurements of Results in Clinical Trials of Rheumatoid Arthritis) / RAMRIS (Rheumatoid Arthritis Counting System in Magnetic Resonance Imaging), suggesting it as a method of diagnosis and monitoring of disease. Materials and Methods: We used recent articles, publications in editorials and master's theses on the criterion of literature to which the present review is based. Articles from more distant dates for 5 years were also used by having indispensability for this study. Results: MRI proved to be the best method of diagnosis and monitoring of rheumatoid arthritis and applied the criteria of OMERACT group through RAMRIS. The RAMRIS shown to be able to guide best diagnostic evaluations and proof of therapeutic efficiency in the use of disease-modifying medicines. Conclusion: The method RAMRIS protocols can be played on most services, requiring radiologists trained on the criteria of OMERACT group to be introduced to their routines.

Keywords: RAMRIS, Rheumatoid Arthritis, Magnetic Resonance.

1. INTRODUCTION

The constant advances of MRI (magnetic resonance imaging) provided new methods for early diagnosis and monitoring of RA (rheumatoid arthritis), as well as the possibility of proving the efficacy of disease-modifying drugs (TOLERES JUNIOR; ROLIM & KAKEHASI, 2011).

According to Tavares Junior et al. (2011), RA is a chronic polyarthritis of unknown etiology that results in progressive destruction of bone tissue and joint incapacity, and can be evaluated through methods of the OMERACT group. Results in Clinical Trials of Rheumatoid Arthritis), such as RAMRIS (Rheumatoid Arthritis Counting System in Magnetic Resonance Imaging). This method showed efficacy in longitudinal studies, such as Baan et al (2011) and Vítule (2006), and was suggested as a means of positioning the disease in the study by Tavares Junior et al. (2011).

RAMRIS is a method of the OMERACT group that scores the damage caused by RA, especially in smaller articular spaces such as the carpus joints using MRI imaging (TAVARES JUNIOR; ROLIM & KAKEHASI, 2011; BAAN et al., 2011). Comparative studies have been carried out by several authors and the RAMRIS score is still the most indicated as suggested by Baan et al (2011); Tavares Junior et al (2011); Vítule (2006), and having a great correlation with the findings of computed tomography as demonstrated by Dohn et al. (2007).

Synovial volumetry is also a precise and reproducible method, but it is as time-consuming as MRI, lasting from 1 to 2 hours, and is less conducive to repetition than MRI, which takes up to 20 minutes to reproduce the suggested RAMRIS *score* criteria (NOGUEIRA-BARBOSA, 2011.; HODGSON; O'CONNOR; MOOTS, 2008).

2. GOALS

The present work aims to offer a new reading of MRI in the diagnosis and follow-up of RA, describing results obtained by several authors through the criteria of the OMERACT / RAMRIS group and suggesting it as a method of diagnosis and follow-up for the disease.

3. METHODS AND MATERIALS

Data collection took place in a virtual environment, at the bases of Google academic, Scielo, National Center for Biotechnology Information (NCBI), Database of the National Library of Medicine of the United States (PubMed) and in the digital library USP.

Articles from more distant dates than 5 years ago were also used because they are indispensable for the present study.

4. THEORETICAL REFERENCE

4.1. RHEUMATOID ARTHRITIS (RA) AND ITS DIAGNOSTIC MEDIA

According to Kumar (2013, p.179), "RA is a chronic and progressive systemic inflammatory

disease that mainly affects the joints, especially the small joints, but can affect several tissues."

The etiology of RA remains unknown. It is believed to be related to genetic, hormonal, environmental and immunological factors (ZORZI; DA SILVEIRA & VON MÜHLEN, 2000).

Its pathophysiology involves a nonspecific inflammatory response, activated by an unknown stimulus, which subsequently, an initial response of CD4 + T cells is induced, where it amplifies and perpetuates inflammation. Once activated T cells induce stimulation of polyclonal B cells and local production of FR. With the spread of tissue damage other autoantigens are produced. Finally, the function of the synovial fibroblasts is altered so that they can acquire destructive characteristics that do not need the stimulation of T cells or macrophages, resulting in proliferative and invasive synovitis (the pannus articular), which invades the cartilage and the subchondral bone causing erosion (LIPSKY, 1998; SCUTELLARI & ORZINCOLO, 1998; WINALSKI et al., 1996).

The clinical onset of the disease may be variable; in general RA has its onset with the symmetrical involvement of small joints, pain, morning stiffness and movement limitation for more than one hour (ALMEIDA., ALMEIDA & BERLOTO, 2014).

It is a condition that affects 0.5% to 1% of the adult world population in all ethnic groups, but with a predominance of females on a scale that is about three times larger than males, fourth and sixth decades of life, despite records in all age groups (ALARCÓN, 1995; HARRIS & FIRESTEIN, 2008; MARQUES-NETO et al., 1993). The duration of symptoms, for RA to be defined as initial, varies according to the various authors (CASTRO-RUEDA & KAVANAUGH, 2008; MOTA, LAURINDO & SANTOS NETO, 2010).

Dixon & Symmons (2005), reports in his studies that RA evolves in four phases. Being the first asymptomatic phase, in which genes of susceptibility and one or several triggering factors, triggers, eventually determine the development of inflammation of the joint. In a third stage, it evolves into a specific form of arthritis. In the last stage, the severity of arthritis is established (MONTEIRO, 2012).

Lee & Weinblatt (2001), reveal in their study that RA has a clinical course and a variable prognosis from patient to patient, making it difficult to predict the severity of the disease at an early stage. In view of the difficulty in performing a correct prognosis, several clinical, molecular, histological and imaging biomarkers have been identified in the approach of the patient with RA (LINDSTROM & ROBINSON, 2010).

According to Van Venrooij et al. (2006), the ideal biomarker to diagnose RA early should meet at least 4 criteria: good sensitivity, good specificity, presence at an early stage and prognostic capacity.

Several studies aimed at monitoring the disease by means of diagnostic methods such as rheumatoid factor, an antibody directed against the IgG Fc portion, classically associated with RA and found in the serum of about 70% of the patients afflicted by the disease; such as anti-protein antibodies and citrullinated peptides (MONTEIRO, 2012); cyclic citrullinated anti-peptide antibodies (SCHELLEKENS et al., 2000)

(VISSER, 2005; and genetic evaluation (RENAUDINEAU et al., 2005).

Several imaging methods are used in the evaluation of RA, including conventional radiology, US, bone scintigraphy, computed tomography (CT), MRI and bone densitometry (BROWN et al., 2004). Among the most used imaging tests as a diagnostic and follow-up resource are conventional radiography, ultrasonography and MRI. A brief consideration of the advantages and disadvantages of these imaging tests was described by Mota (2011) and shown in Table 1.

A study by Dohn et al. (2007) showed that computed tomography presents approximate values in the calculation of the total volume of erosion caused by RA when compared to MRI, and may be valid in longitudinal studies that aim to monitor the total volume of erosion.

Table 1: Advantages and disadvantages of the imaging methods used in the evaluation of patients with RA.

Methods	Benefits	Disadvantages
Conventional radiography	- Low cost - Easy access	- Two-dimensional representation of three-dimensional lesion - Exposure to ionizing radiation - Low sensitivity for early bone damage
Ultrasonography	- Intermediate cost - Absence of ionizing radiation - Allows examination of several joints - Allows to guide diagnostic and therapeutic interventions - Early detection of cartilage and bone damage.	- Operator-dependent exam - Low sensitivity for changes in deep joints (hip)
Magnetic resonance imaging	- High sensitivity - Absence of ionizing radiation - Complementing the examination with contrast - Early detection of bone and cartilage structural damage, and bone edema	- High cost - Limited availability of equipment - Prolonged examination time - Limitation of one examination per joint

Source: Mota (2011).

4.2. FINDINGS IN RM

4.2.1. SINOVITE

The RM identifies thickening of synovial tissue with quality resulting from the inflammatory process of rheumatoid arthritis. In a study carried out by Tavares Júnior et al. (2011), we report T1-weighted images showing low to intermediate signal intensity, and T2-weighted images with high signal intensity due to the increase in water content.

According to the same authors cited above, on MRI the signs of synovitis include increased synovial volume, as well as water content and contrast enhancement (increase in signal intensity after intravenous injection of gadolinium-based contrast), shown in figure 1. The RM is shown to be more sensitive than clinical examination in the diagnosis of synovitis, and shows synovial inflammation in early RA (HETLAND et al., 2010.; CONAGHAN et al., 2007.; TAVARES JUNIOR; ROLIM & KAKEHASI, 2011).

A study by Tavares Júnior et al. 2011, demonstrated that in RA the active hypertrophic synovial membrane eventually invades and causes erosion in contiguous bone and cartilage. The same authors also note that contrast-enhanced T1 weighting images are considered sensitive and specific for the evaluation of acute synovitis. In an examination of the second phalangeal metacarpal joint using a minarthroscope and MRI, it showed post-contrast enhancement in 86% of patients with synovitis.

McQueen et al. (1998), evaluated that 93% of a cohort of 42 RA patients had signs of wrist synovitis seen by MRI 6 months after the onset of symptoms. Still according to the study of the same authors, the synovitis enhances rapidly after the intravenous administration of gadolinium-based contrast and with great intensity, different from the joint effusion, which does not emphasize as soon as the contrast is administered. This initial phase lasts about 5 minutes after injection. Images obtained 10 minutes after injection do not correctly delineate the extent of synovitis because gadolinium can be excreted into the joint synovial fluid. Pannus fibrotic, common in the late stage of RA, is relatively hypovascular after intravenous administration of gadolinium. With T2-weighted sequences, fibrotic pannus of intermediate to low signal intensity can be differentiated from acute synovitis and joint fluid (FREESTON, BIRD & CONAGHAN, 2009; KÖNIG, SIEPER & WOLF, 1990; TAMAI et al., 1994).

Figure 1: Synovitis in 36-year-old man with early wrist RA (8 months duration) and normal radiographic examination.

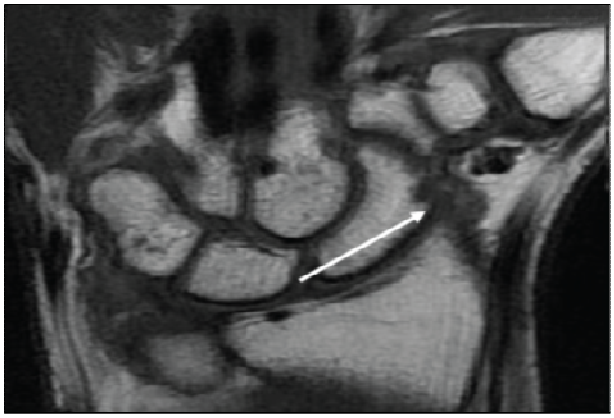

(A) Coronal T1-weighted MR image shows radiocarpal synovitis with low signal intensity (arrow).

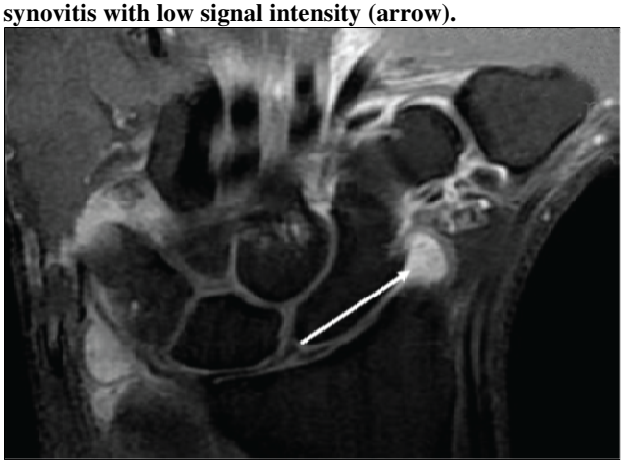

(B) Coronal T1-weighted MR imaging with gadolinium-enhanced fat suppression shows intense accentuation of radiocarpal synovitis (Tavares Junior et al., 2011).

4.2.2. BONE MARROW EDEMA

Although not specific and well portrayed in traumatic, neoplastic, and degenerative processes, bone marrow edema is an important finding by MR imaging in patients afflicted with early-stage RA. Bone edema is an abnormality detected by MRI with intense signal in fat suppression sequences and may be enhanced after administration of contrast, as can be seen in figure

2 (TAVARES JUNIOR; ROLIM & KAKEHASI, 2011; MOTA & LAURINDO, 2010).

The definition of bone edema through the Measurement of Results in Clinical Trials of RA (OMERACT: Outcome Measures in Rheumatoid Arthritis Clinical Trials) is the lesion inside the trabecular bone, having poorly defined margins and increased water sign (ALETAHA et al., 2010; HODGSON, O'CONNOR & MOOTS, 2008).

Bone edema and adjacent synovitis are related to the severity of inflammation, and edema is the independent predictor of erosion development (RAZA & FILER, 2009; KARASICK & SCHWEITZER, 1996).

Bone marrow edema is considered an early indicator of inflammation, since its presence is correlated with increased levels of acute phase reactants (erythrocyte sedimentation rate and C-reactive protein) and scales for clinical evaluation of disease activity (GHOZLAN & VACHER, 2009; PETERFY, 2001).

Conaghan et al. (2003) demonstrated in their study through MRI images of early RA cuffs that bone edema is a predictor of erosion development and also predicts functional outcome six years later.

Figure 2: Bone marrow edema in a 37-year-old man with early arthritis of the wrist. Coronal T2-weighted MRI image shows pyramidal bone edema represented by high signal intensity (arrow).

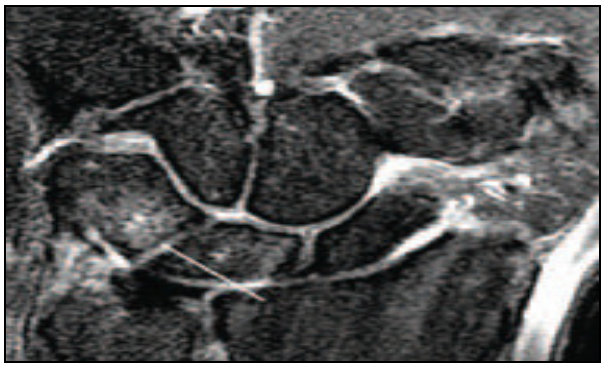

Source: Tavares Junior et al., (2011).

4.2.3. EROSIONS

The detection of erosions in MRI helps the diagnosis and prognosis of patients with RA (BOYESEN et al., 2010). Erosions at RM in cuts followed up to six years, predict the progress of RA (MCQUEEN et al., 2003).

According to Ostergaard et al. (2005), the definitions of erosions in T1-weighted images are shown with loss of low and normal signal intensity of the cortical bone and loss of high and normal signal intensity from the bone marrow cavity, enhancing after gadolinium-based contrast administration, and high signal intensity in T2-weighted images and STIR, as shown in figure 3.

Contrast impregnation in erosions represents the inflammatory process of the synovial membrane and distinguishes erosions of cystic lesions filled by fluid (FREESTON; BIRD & CONAGHAN, 2009).

The foramen nutrício in the carpal bones can be confused with small erosions in certain sequences. Similarly, interosseous insertions of ligaments in the carpal bones may mimic erosions (TAVARES JUNIOR; ROLIM & KAKEHASI, 2011). In this case, attention is needed, since small erosion-like lesions were identified in two cut planes in about 2% of the metacarpal bones and wrists of healthy people, with no enhancement in these lesions after administration of gadolinium-based contrast and without association with bone edema, according to the Ejbjerg et al (2004).

Figure 3: Erosions in T1-weighted images.

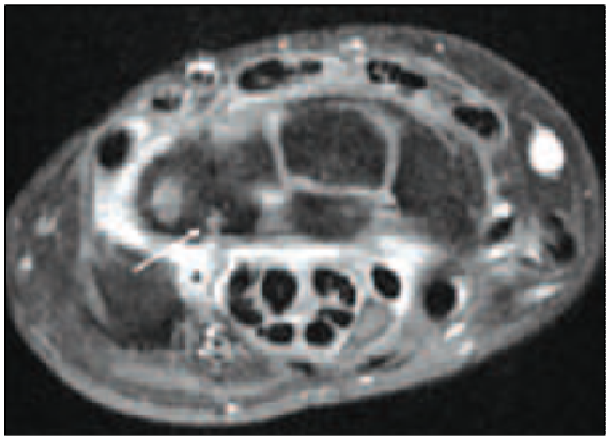

(A) T1 unweighted axial MRI and T1 axial and coronal T1 MRI with fat suppression and gadolinium accentuation.

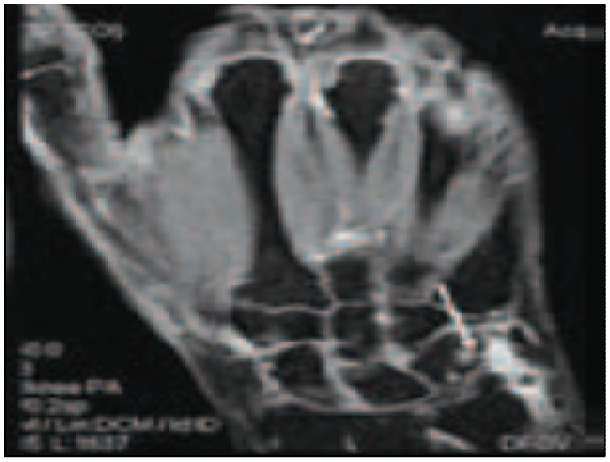

(B) Erosion in pyramidal bone enhanced after gadolinium (arrow). Synovitis is seen in the wrist. (right). Source: Tavares Junior and collaborators (2011).

4.2.4. TENOSINOVITE

According to Tavares Junior; Rolim & Kakehasi (2011), the signs of tenosynovitis in MR images include fluid in the tendon sheath, increased thickening and contrast enhancement of the synovial membrane of the tendon sheath, according to figure 4. The same authors also argue in their work that small amounts of fluid are normally seen in the wrist tendon cuffs of healthy people, especially in the extensor compartments. When the diameter of the fluid in the tendon sheath is less than the corresponding diameter of the tendon, the fluid can be considered normal.

Contrast impregnation in the synovial membrane of the tendon sheath is considered a sign of tenosynovitis. Tenenosynovitis is clinically significant in early RA, since joint synovitis and tenosynovitis represent the inflammatory process of RA. Tenenosynovitis, in patients with early RA, exceeds articular synovitis during inflammation (ESHED et al., 2009).

Dorsal tenosynovitis of the wrist is associated with tendon rupture, described as the invasion by the synovial membrane of the sheath in the tendon and the friction thereof against eroded bony margins (GHOZLAN & VACHER, 2009).

Figure 4: Tenosynovitis in a 53-year-old woman with early arthritis of the wrist (16 months duration) and normal radiographic examination.

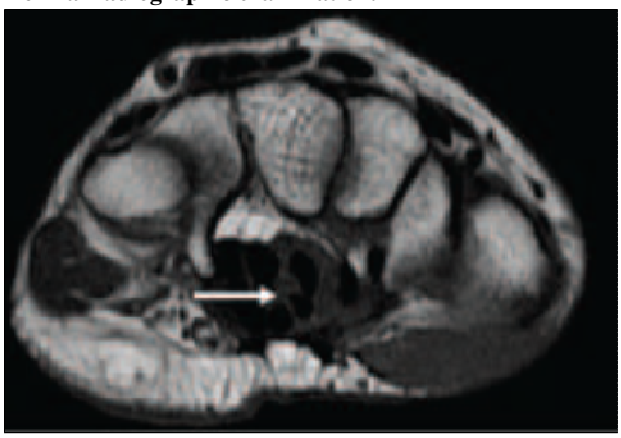

(A) Axial T1-weighted MR (left).

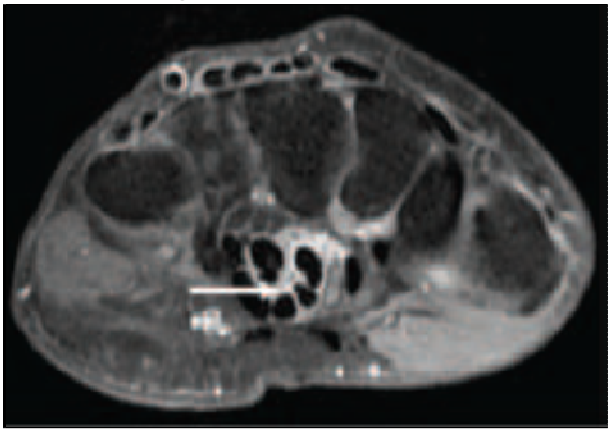

(B) Axial T1 MRI with fat suppression and gadolinium enhancement shows flexor tenosynovitis with intense stress (arrow) and minimal extensor tenosynovitis with moderate accentuation under the arrowhead (right). Source: Tavares Junior, Rolim & Kakehasi, 2011).

4.2. OMERACT – RAMRIS

The group OMERACT (*Outcome Measures in Rheumatoid Arthritis Clinical Trials)* it is a task force of rheumatologists, who establish clinical evaluation criteria for RA, having as expression in the imaging diagnosis the method RAMRIS (*Rheumatoid Arthritis Magnetic Resonance Image Scoring)* developed to assess the inflammatory and destructive changes in the hands and wrists of patients afflicted by RA, and approved at the sixth OMERACT meeting as a useful evaluative / comparative standard for RA in MRI, being suggested by later longitudinal studies of various authors (TAVARES JUNIOR; ROLIM & KAKEHASI, 2011.; BAAN et al., 2011.; ESPEN et al.,. 2005.; MCQUEEN et al., 2003).

Baan et al (2011) used OMERACT / RAMRIS criteria in RA patients in their study and also obtained reliable results.

4.3. PROTOCOLS ADOPTED IN THE RM

In general, it is agreed among several authors that a differentiated protocol should be adopted for the best diagnosis of RA, and the devices to be used need a high magnetic field (> 0.6 T), preferably 1.5 T devices due to the use of STIR and fat saturation sequences (TAVARES JUNIOR; ROLIM & KAKEHASI, 2011.; BAAN et al., 2011.; CYTEVAL et al., 2010).

Cyteval et al (2010), when performing a study with 58 patients with RA in the fist in several stages, applied the following protocol and resources for optimization of the RAMRIS evaluation: Two 1.5 T appliances (Siemens, Magneton; Philips, Achieva), wrist coil for evaluation of wrist and phalangeal metacarpal joints of both hands in a comparative study, patients positioned in the ventral or lateral decubitus position with immobilization to reduce possible movements. The applied technique consisted of images T1-w (*weighted*) *spin-echo,* T2-w *spin*-echo with fat saturation, axial and coronal post-contrast (gadolinium) sequences T1-w *spin-echo* with fat saturation.

The images of Cyteval et al (2010) were obtained following the following parameters: 3 mm of cut thickness without spacing between cuts, FoV of 130 x 130, matrix of 230 x 256. For images T2-wo repetition time used was 3500 msec, echo time of 60 msec and echo train of 7. For T1-w images, a repetition time of 500 msec and an echo time of 20 msec were used.

The contrast was Magnevist, Schering, using manual injection of 0.1 mmol per kilogram body. The total time of examination was 35 minutes.

A brief guideline on the protocol adopted for the evaluation of RA in the hand and wrist was also described in the literature review study by Tavares Junior et al. (2011), suggesting that: the examination should start with a coronal STIR sequence or T2 with fat saturation , Gradient echo T1-w isotropic 3D and coronal and axial T1 after contrast administration (gadolinium).

Baan et al. (2011), in a longitudinal study with 29 RA patients afflicted with RA in the foot and ankle, used a 1.5 T Philips device and 4-channel body coil, simultaneously acquiring images of both feet. All acquired images were satisfactory in all 29 patients with the application of the following protocol and parameters: axial T1-w 3D GRE (*gradient echo)* (2 mm of cut thickness, 1 mm of space between cuts, TR 17 ms, TE 4.6 ms, *flip angle* 25); sagittal T1-w SE (Spin

Echo) [cut-off thickness of 3.5 mm, 0.3 interspace, TR 609 ms, TE 19 ms, NSA 3 (Number of Signal Avarages)]; sagittal T2 TSE with fat saturation (3.5 mm thickness of cut, 0.3 of space between cuts, TR 4785 ms, TE 150 ms, 4 NSA). Following administration of 15 ml of gadodiamide contrast (0.5 mmol / ml) the sagittal T1-w SE sequences with fat saturation (3.5 mm shear thickness, 0.3 shear space, TR 609 MS, TE 19 ms, 3 NSA), and axial T1 SE with fat saturation (3.0 mm of cut thickness, 0.3 of cut space, TR 609 ms, TE 19 ms, 3 NSA). In all sequences the FoV was 10-14 and the matrix 256 x 217.

A brief compilation of the characteristics of RM to RA suggested by the same authors above and corresponding to the criteria of the OMERACT group and RAMRIS system is depicted in table 2.

Table 2: Main pattern of RM in RA.

Characteristics	Specifications
Regions of joints examined	Fist, from the second to fifth unilateral phalangeal metacarpal joint (the most painful)
Signs of MRI Damage	Edema, synovitis, erosion and tenosynovitis
Type of magnetic equipment	The field recommendation is 1.5 Tesla
Contrast	Gadolinium
Sequences	Coronal T1, axial T1, coronal T2 with fat saturation, axial with enhanced contrast and coronal T1 with fat saturation
Monitoring response therapy (punctuation)	OMERACT / RAMRIS*, Synovial Volume Measurement, Dynamic Punctuation with High Contrast
***OMERACT / RAMRIS: Measurement of Clinical Trials of Rheumatoid Arthritis / Magnetic Resonance Imaging System of RA.**	

5. RESULTS

MRI has been shown to be the best diagnostic and monitoring method for RA, especially if applied within the criteria of the OMERACT group through RAMRIS, although reproduction is still limited due to its duration and cost. Other diagnostic methods, despite reproducing results similar to those of MRI, as demonstrated by Dohn and collaborators (2014), in their comparative study of computed tomography and MRI results, have not yet reproduced such reliable values as those provided by MRI.

The RAMRIS system of the OMERACT group has been shown to be capable of guiding better diagnostic evaluations and demonstrating therapeutic efficacy when using the disease modifying drugs, although MRI or OMERACT group have not yet demonstrated efficacy in early diagnosis and only in the early stages of RA.

6. DISCUSSION

Methods that try to improve the assessment of RA in its various stages are necessary, especially when trying to prove the efficacy of medicines that fight the disease. An example of this type of method is the Cimmino et al (2014) pilot study on Dynamic Contrast-Enhancement MRI (DCE-MRI), in which 10 rituximab-treated RA patients were monitored. MRI wrist acquisitions were made from 4 to 24 weeks of treatment and evaluated within the criteria of RAMRIS and DCE-MRI. It was verified throughout the study that the RAMRIS did not present alterations, whereas DCE-MRI suggested improvement through the treatment of rituximab.

Diagnostic criteria such as these promote expectations and prove therapeutic efficacy, being important factors throughout the treatment of patients with RA, but are still poorly reproducible methods due to their dependence on the operator and the need for well trained and experienced professionals in their evaluative criteria. Access to the necessary technology.

In view of these limitations, the present study considered the criteria of the OMERACT group for RAMRIS to be easier to reproduce in routine, which was applied and validated as effective by several studies of the theoretical reference to which this work was based.

Aimed as effective in longitudinal studies such as those of Baan, et al (2011) and Dohn et al (2007), the RA score method using RM (RAMRIS) demonstrates current advantage over other methods of easy access and reproduction. Mota (2011) says from the ultrasonography that its dynamism in the study of several joints and the absence of contraindications of the method, besides the lower cost, are advantages in relation to MRI, being able to diagnose early joint lesions and inflammatory activity, experienced operator for such.

Studies performed by Dohn et al. (2007 and 2014), were able to report through computed tomography to reach similar values in relation to MRI through the evaluation criteria of the RAMRIS in the study of articular space of the wrist of 14 patients with RA and 1 healthy patient for control. However, computerized tomography is known to be invasive because it uses ionizing radiation, is less sensitive than MRI, and has a similar cost.

Cyteval et al (2010) in his study, mentioned in item 7 of this study, demonstrated the protocol applied with rich details, being this protocol easily reproduced in most of the services and requiring for its realization of experienced professional and adequate equipment. Radiologists trained in the evaluation of RA within the parameters of the OMERACT group are required and were the evaluators of the protocols applied in the studies cited in this study.

Different regions of the body that may also be afflicted by RA, such as the hip, are still poorly studied within the RAMRIS criteria, a fact noted in the paucity of studies addressing the problem, but their diagnosis has been validated as satisfactory through MRI as demonstrated by Caldana et al (2005) in a study that sought to verify the main findings of RA by MR.

At this point it is intended for a future study the evaluation of regions less studied within the RAMRIS method, such as the elbow, for a validation of the efficacy of the method in regions other than wrists, hands and feet.

7. CONCLUSION

Based on the consulted reference it was verified that the protocols that optimize the study of the RAMRIS method can be reproduced in most services, requiring radiologists trained in the criteria of the OMERACT group to be introduced to their routines. Because it is a differential assessment of RA, the diagnosis and confirmation of therapeutic efficacy may be better observed, but it is not useful in early diagnosis of RA. One should think of the same differentiated evaluation of other regions of the body afflicted by RA, such as elbow or hip.

MRI already produces high quality images for the evaluation of cartilaginous degenerations, synovitis, erosions, requiring specific criteria to evaluate RA to verify therapeutic efficacy in patients responding or not to the treatment adopted.

8. REFERENCES

ALMEIDA, M. S. T. M., ALMEIDA, J. V. M & BERTOLO, M. B. Demographic and clinical characteristics of patients with rheumatoid arthritis in Piauí, Brazil - evaluation of 98 patients. **Brazilian Journal of Rheumatology,** v. 54, n. 5, p. 360–365, 2014.

ALARCÓN, G. S. Epidemiology of rheumatoid arthritis. **Rheum Dis Clin North Am.** v. 21, p. 589-604, 1995.

ALETAHA, D., NEOGI, T., SILMAN, A. J., FUNOVITS, J., FELSON, D. T., BINGHAM, C. O., BIRNBAUM, N. S., BURMESTER, G. R., BYKERK, V. P., COHEN, M. D., COMBE, B., COSTENBADER, K. H., DOUGADOS, M., EMERY, P., FERRACCIOLI, G., HAZES, J. M., HOBBS, K., HUIZINGA, T. W., KAVANAUGH, A., KAY, J., KVIEN, T. K., LAING, T., MEASE, P., MÉNARD, H. A., MORELAND, L. W., NADEN, R. L., PINCUS, T., SMOLEN, J. S., STANISLAWSKA-BIERNAT, E., SYMMONS, D., TAK, P. P., UPCHURCH, K.S., VENCOVSKY, J., WOLFE, F., HAWKER. G. 2010 rheumatoid arthritis classification criteria: an American College of Rheumatology/European League Against Rheumatism collaborative initiative. **Ann Rheum Dis**. v. 69, n. 9, p.1580-8, 2010.

BAAN, H., BEZOOIJEN, R., AVENARIUS, J. K., DUBBELDAM, R., DROSSAERS-BAKKER W. K., VAN DE LAAR, M. A. Magnetic Resonance Imaging of the Rheumatic Foot According to the RAMRIS System Is Reliable. **The Journal of Rheumatology**. v. 38. p. 6. 2011.

BØYESEN, P., HAAVARDSHOLM, E. A., OSTERGAARD, M., VAN DER HEIJDE, D., SESSENG, S., KVIEN, T. K. MRI in early rheumatoid arthritis: synovitis and bone marrow oedema are independent predictors of subsequent radiographic progression. **Ann Rheum Dis.** V. 70, n. 3, p.428-33, 2010.

BROWN, A. K., WAKEFIELD, R. J., CONAGHAN, P. G., KARIM, Z., O'CONNOR, P. J., EMERY, P. New approaches to imaging early infl ammatory arthritis. **Clin Exp Rheumatol.** V. 22, n. 5, p. 18-25, 2004.

CASTRO-RUEDA, H & KAVANAUGH, A. Biologic therapy for early rheumatoid arthritis: the latest evidence. **Curr Opin Rheumatol**. v. 20, n. 3, p. 314-9, 2008.

CALDANA, W. C. I. CICONELLI, R.M. JULIANO, Y. FERNANDES, A.R.C. MRI of the hip in the evaluation of patients with rheumatoid arthritis: a descriptive study. **Radiol Bras**. v. 38. n. 4. p. 255-60. 2005

CIMMINO, M. A. PARODI, M. ZAMPOGNA, G. BOESEN, M. KUBASSOVA, O. BARBIERI, F. Dynamiccontrast-enhanced, extremity dedicated MRI identifies synovitis changes in the follow-up of rheumatoid arthritis patients treated with rituximab. **Clin Exp Rheumatol**. v. 32. n. 5. p. 647-52. 2014.

CONAGHAN, P. G., O'CONNOR, P., MCGONAGLE, D., ASTIN, P., WAKEFIELD, R. J., GIBBON, W.W.,QUINN, M., KARIM, Z., GREEN, M. J., PROUDMAN, S., ISAACS, J., EMERY, P. Elucidation of the relationship between synovitis and bone damage: a randomized magnetic resonance imaging study of individual joints in patients with early rheumatoid arthritis. **Arthritis Rheum**. v. 48. n. 1. p. 64–71. 2003.

CONAGHAN, P.G., EJBJERG, B., LASSERE, M., BIRD, P., PETERFY, C., EMERY, P., MCQUEEN, F., HAAVARDSHOLM, E., O'CONNOR, P., EDMONDS, J., GENANT, H., OSTERGAARD, M. A multicenter reliability study of extremity-magnetic resonance imaging in the longitudinal evaluation of rheumatoid arthritis. **Journal Rheumatol**. v. 34. n. 4. p. 857–8, 2007.

CYTEVAL, C. MIGUEL, A. HOA, D., DAURES, J. P., MARIETTE, X., COMBE, B. Rheumatoid Arthritis of the Hand: Monitoring with a Simplified MR Imaging Scoring Method—Preliminary Assessment. **Radiology.** v. 256. n. 3. p. 863-9. 2010.

DIXON, W. G., SYMMONS, D.P. Does early rheumatoid arthritis exist? **Best Pract Res Clin Rheumatol**. v. 19, n. 1. p.37-53, 2005.

DOHN, U. M ., CONAGHAN, P.G., ESHED, I., BOONEN, A., BOYESEN, P., PETERFY, C. G., LILLEGRAVEN, S., EJBJERG, B., GANDJBAKHCH, F., BIRD, P., FOLTZ, V., GENANT, H. K., HAAVARDSHOLM, E., MCQUEEN, F. M., OSTERGAARD, M. The OMERACT-RAMRIS rheumatoid arthritis magnetic resonance imaging joint space narrowing score: intrareader and interreader reability and agreement with computed tomography and conventional radiography. **Jounal Rheumatol**. v. 41. n. 2. p. 392-397. 2014.

DOHN, U. M., EJBJERG, B. J., HASSELGUIST, M., NARVESTAD, E., COURT□PAYEN, M., SZKUDLAREK, M., MOLLER, J., THOMSEN, H. S., OSTERGAARD, M. Rheumatoid arthritis bone erosion volumes on CT and MRI: reliability and correlations with erosion scores on CT, MRI and radiography**. Ann Rheum Dis**. v. 66. n. 10. p. 1388-92. 2007.

EJBJERG, B., NARVESTAD, E., ROSTRUP. E., SZKUDLAREK, M., JACOBSEN, S., THOMSEN, H. S., OSTERGAARD, M. Magnetic resonance imaging of wrist and fi nger joints in healthy subjects occasionally shows changes resembling erosions and synovitis as seen in rheumatoid arthritis. **Arthritis Rheum**. v. 50, n. 4, p.1097–106, 2004.

ESHED, I., FEIST, E., ALTHOFF, C. E, HAMM, B., KONEN, E., BURMESTER, G. R., BACKHAUS, M., HERMANN, K. G. Tenosynovitis of the flexor tendons of the hand detected by MRI: an early indicator of rheumatoid arthritis. **Rheumatology (Oxford)**, v. 48, n. 8, p. 887-91, 2009.

ESPEN, A. HAAVARDSHOLM. OSTERGAARD, M. EJBJERG, B. J., KVAN N. P., UHLIG, T. A., LILLEÅS, F. G., KVIEN, T. K. Reliability and Sensitivity to Change of the OMERACT Rheumatoid Arthritis Magnetic Resonance Imaging Score in a Multireader, Longitudinal Setting. **Arthritis & Rheumatism**. v. 52. n.12. p. 3860-67. 2005.

FREESTON, J. E., BIRD, P., CONAGHAN, P.G. The role of MRI in rheumatoid arthritis: research and clinical issues. **Curr Opin Rheumatol**. v. 21. n. 2. p. 95–101. 2009.

GIORGI, R. D. N., R. A. C., PINHEIRO, G. R. C. Consenso da Sociedade Brasileira de Reumatologia 2011 para o diagnóstico e avaliação inicial de artrite reumatoide. **Rev Bras Reumatol**. v. 51. n. 3. p. 199-219, 2011.

GHOZLAN, R & VACHER, H. Where is imaging going in rheumatology? **Best Pract Clin Rheumatol**, v. 14, n. 4, p. 617–33, 2009.

JUNIOR, T.; ROLIM, R.; KAKEHASI, A. M. Magnetic Resonance Imaging in Rheumatoid Arthritis. **Rev Bras Reumatol.** v. 51. n. 6. p. 629 641. 2011.

HARRIS, E. D., FIRESTEIN, G. S. **Clinical Features of Rheumatoid Arthritis**. In: FIRESTEIN, G. S., BUDD, R. C., JR. E. D. H, MCINNES IB, RUDDY S, SERGENT J. S, editors. KELLEY'S Textbook of Rheumatology. Philadelphia: Mosby; 2008.

HETLAND, M. L. STENGAARD-PEDERSEN, K. JUNKER, P. OSTERGAARD, M. EJBJERG, B.J. JACOBSEN, S., LOTTENBURGER, T., HANSEN, I., TARP, U., ANDERSEN, L. S., SVENDSEN, A., PEDERSEN, J. K., LAURIDSEN, U. B., ELLINGSEN, T., LINDEGAARD, H., PODENPHANT, J., VESTERGAARD, A., JURIK, A. G., HORSLEV-PETERSEN, K. Radiographic progression and remission rates in early rheumatoid arthritis – MRI bone oedema and anti-CCP predicted radiographic progression in the 5-year extension of the double-blind randomized CIMESTRA trial. **Ann Rheum Dis**. v. 69 n. 10. p. 1789–95. 2010.

HODGSON, R. J., O'CONNOR, P., MOOTS, R. MRI of rheumatoid arthritis image quantification for the assessment of disease activity, progression and response to therapy. **Rheumatology**, n. 47, v.1, p. 13–21, 2008.

KARASICK, D & SCHWEITZER, M. E. The os trigonum syndrome: imaging features. **AJR Am J Roentgenol**. v.166, p. 125–9, 1996.

KÖNIG, H., SIEPER, J., WOLF, K. J. Rheumatoid arthritis: evaluation of hypervascular and fibrous pannus with dynamic MR imaging enhanced with Gd-DTPA. **Radiology**, v. 176, n. 2, p. 473-477, 1990.

KUMAR, V. **Robbins Basic Pathology**. 9th Ed. Rio de Janeiro. Elsevier. 2013. p. 928 p.

LEE, D. M & WEINBLATT, M. E. Rheumatoid arthritis. **Lancet**. v. 15, n. 358, p. 903-11, 2001.

LINDSTROM, T. M., ROBINSON, W. H. Biomarkers for rheumatoid arthritis: making it personal. **Scand J Clin Lab Invest Suppl**. V. 242, p. 79-84, 2010.

LIPSKY, P. E. **Rheumatoid arthritis**. In Fauci, Braunwald, Isselbacher et al eds. Harrison's principles of internal medicine, 14ª ed. P. 1880-1888, New York, Mc Graw-Hill, 1998.

MARQUES-NETO, J. F., GONÇALVES, E. T., LANGEN, L. F. O. B., CUNHA, M. F. L., RADOMINSKI, S., OLIVEIRA, S. M., CURY, S. ELISA., MEDEIROS, F., SAMPAIO, G. C. Multicentric study of the prevalence of adult rheumatoid arthritis in Brazilian population samples. **Rev Bras Reumatol**. v. 33, p.169-73, 1993.

MOTA, L. M. H.; CRUZ, B. A.; BRENOL, C. V., PEREIRA, I. A., FRONZA, L. S. R., BERTOLO, B. M., DE FREITAS, M. V. C., SILVA, N. A., LOUZADA-JUNIOR, P., NOGUEIRA-BARBOSA M. H. Magnetic Resonance in Rheumatoid Arthritis (Editorial), **Rev Bras Reumatol**., v. 51. n. 6. p. 535-538. 2011.

MOTA, L. M. H. D., LAURINDO, I. M. M., SANTOS NETO, L. L. D. Initial rheumatoid arthritis: concepts. **Journal of the Brazilian Medical Association**, v. 56, p. 227-229, 2010.

MONTEIRO, S. S. O. **Biomarkers in early Rheumatoid Arthritis**. Dissertation (Master's Degree in Medicine), 51 f. Faculty of Medicine of the University of Porto, 2012.

MCQUEEN, F.M. STEWART, N. CRABBE, J. ROBINSON, E. YEOMAN, S. TAN, P.L., MCLEAN L. Magnetic resonance imaging of the wrist in early rheumatoid arthritis reveals a high prevalence of erosions at four months after symptom on set. **Ann Rheum Dis**. v. 57. n. 6. p. 350–6.1998

MCQUEEN, F., OSTERGAARD, M., CONAGHAN, P., SHNIER, R., PETERFY, C., BIRD, P., O'CONNOR, P., EJBJERG, B., KLARLUND, M., STEWART, N., EMERY, P., SHNIER, R., GENANT, H., , M. OMERACT Rheumatoid Arthritis Magnetic LASSERE Resonance Imaging Studies. Exercise 3: an international multicenter reliability study using the RA-MRI Score. **Journal Rheumatol.** v. 30. n. 6. p. 1366-75. 2003.

OSTENDORF, B. PETERS, R. DANN, P. BECKER, A. SCHERER, A. WEDEKIND, F., FRIEMANN, J., SCHULITZ, K. P., MÖDDER, U., SCHNEIDER, M. Magnetic resonance imaging and miniarthroscopy of metacarpophalangeal joints: sensitive detection of morphologic changes in rheumatoid arthritis. **Arthritis Rheum.** v. 44. n. 11. p. 2492–502, 2001.

OSTERGAARD, M. EJBJERG, B. SZKUDLAREK, M. Imaging in early rheumatoid arthritis: roles of magnetic resonance imaging, ultrasonography, conventional radiography and computed tomography. **Best Pract Res Clin Rheumatol**. v. 19 n. 1. p. 91–116, 2005.

PETERFY, C. G. Magnetic resonance imaging of rheumatoid arthritis: the evolution of clinical applications through clinical trials. **Semin Arthritis Rheum,** v. 30, n. 6, p.375–96, 2001.

RAZA, K & FILER, A. Predicting the development of RA in patients with early undifferentiated arthritis. **Best Pract Res Clin Rheumatol**. v. 23. n. 1. p. 25–36. 2009.

RENAUDINEAU, Y., JAMIN, C., SARAUX, A., YOUINOU, P. Rheumatoid factor on a da daily basis. **Autoimmunity**. v. 38. p. 11-16. 2005.

SCHELLEKENS, G. A., VISSER, H., DE JONG, B. A., VAN DEN HOOGEN, F. H., HAZES, J. M., BREEDVELD, F. C., VAN VENROOIJ, W. J.The diagnostic properties of rheumatoid arthritis antibodies recognizing a cyclic citrullinated peptide. **Arthritis Rheum**. v. 43, n. 1, p. 155-63, 2000.

SCUTELLARI, P. N., ORZINCOLO, C. Rheumatoid arthritis: sequences. **Eur Journal Radiol**, v. 27, n. 1, p. 31-8, 1998.

TAMAI, K., YAMATO, M., YAMAGUCHI, T., OHNO, W. Dynamic magnetic resonance imaging for the evaluation of synovitis in patients with rheumatoid arthritis. **Arthritis Rheum.** v. 37, n. 8, p. 1151-1157, 1994.

VAN VENROOIJ, W. J., ZENDMAN, A. J., PRUIJN, G. J. Autoantibodies to citrullinated

antigens in (early) rheumatoid arthritis. **Autoimmun Rev**. v. 6, n. 1, p. 37-41, 2006.

VISSER H. Early diagnosis of rheumatoid arthritis. **Best Pract & Res Clin Rheum**, v. 19, p. 55-72, 2005.

VÍTULE, L. F. **Magnetic Resonance Imaging of the Dominant Hand in Early Rheumatoid Arthritis: Correlation with Conventional Radiology**. (Doctoral Thesis), Faculty of Medicine of the University of São Paulo, Department of Radiology, 2006.

WINALSKI, C. S., PALMER, W. E., ROSENTHAL, D. I., WEISSMAN, B. N. Magnetic resonance imaging of rheumatoid arthritis. **Radiol Clin North Am**. V. 34, p. 243–58,1996

WHITING, P. F., SMIDT, N., STERNE, J. A., HARBORD, R., BURTON, A., BURKE, M., BEYNON, R., BEN-SHLOMO, Y., AXFORD, J., DIEPPE, P. Systematic review: accuracy of anti-citrullinated Peptide antibodies for diagnosing rheumatoid arthritis. **Ann Intern Med**. v. 152. p. 456–64. 2010.

ZORZI, L. A., DA SILVEIRA, I. G & VON MÜHLEN, C. A. New perspectives for the diagnosis of rheumatoid arthritis. AMRIGS Magazine, Porto Alegre, v. 44, n. 3,4, p. 168-173, 2000.