UNDER PEER REVIEW

CASE REPORT

DENGUE FEVER OPTICAL NEUROPATHY WITH EXPECTANT CONDUCT: CASE REPORT.

ABSTRACT:

Dengue is a mosquito borne viral disease endemic in many parts of the world. It can manifest from a classic form, with fever, headache and myalgia, to more serious cases, such as dengue hemorrhagic fever, with high mortality rates. Ocular manifestations are relatively uncommon, but when present they have a wide variety of findings. Optic neuropathy is a rare manifestation and has a variable prognosis. In this article, we report a case of optic neuropathy secondary to dengue, adopting expectant conduct and evolving with a significant improvement of visual acuity.

Key words: dengue fever, optic neuritis, papilitis

Introduction

Dengue fever is a viral infection very prevalent in the tropics. (1-3) Its virus belongs to the family Flaviridae and has 4 serotypes identified: DENV 1 - 4. (1) The infection usually generates symptoms such as fever, myalgia, headache, (1) However, more severe forms may occur with thrombocytopenia and other blood alterations that cause hemorrhagic conditions. (2)

Ocular manifestations are usually uncommon, but their reports in the literature have been growing over the years. (3) Other reported findings are: cotton wool exudates and retinal vasculitis, anterior uveitis, retinal vein occlusion, vitreous hemorrhage and optic neuropathy. (3)

Optic neuropathy associated with dengue is a rare finding. (4) It commonly manifests as papillary edema, hyperemia, and optic disc hemorrhage. (1) The

UNDER PEER REVIEW

prognosis is variable in the literature, with reports of total visual acuity recovery, to cases that have evolved into blindness. (1) In general, most patients have some sequelae. (3)

The mechanisms of ocular manifestations, including optic neuropathy, are still unknown, but the clinical behavior of the lesions suggests an immunogenic cause to the detriment of the infective itself, since it is during the period of increase of the immunological response that the ocular manifestations usually arise. (5)

The objective of this work is to document a case of dengue fever optic neuropathy, to discuss its pathophysiological process and the conduct of this disease.

Case report

A 32-year-old woman with a history of classic dengue fever a week ago, confirmed by sorology, appeared in the service referring to sudden low visual acuity in the left eye. At ophthalmologic examination visual acuity was 20/400 in the affected eye. Extrinsic ocular motility, pupillary reflexes, biomicroscopy and intraocular pressure with no abnormalities in both eyes.

In the indirect binocular ophthalmoscopy of the left eye, there was an increase in vascular tortuosity associated with papilloedema, presence of hemorrhages and cotton wool spots in the perimacular region, characterizing unilateral optic neuropathy with probable peripapillary and retinal vasculitis that evolved with occlusion of the cilioretinal artery.

We opted for expectant conduct. After 30 days, the patient evolved with significant clinical improvement (Figures 1) and ended on the day of discharge with visual acuity of 20/40 in the affected eye, but with paracentral residual lesion in the visual field (Figures 2), besides the decrease of the layer of nerve fibers in the

UNDER PEER REVIEW

papillomacular bundle and temporal atrophy of optic nerve demonstrated in optical coherence tomography (OCT). (Figure 3)

Figure 1 - Retinography with 15 day intervals between them

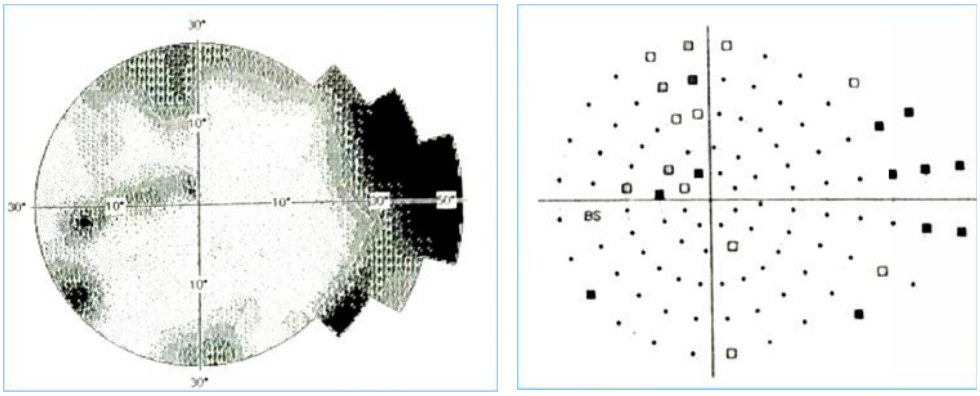

Figure 2 - Visual field showing paracentral and nasal lesion in left eye after 30 days.

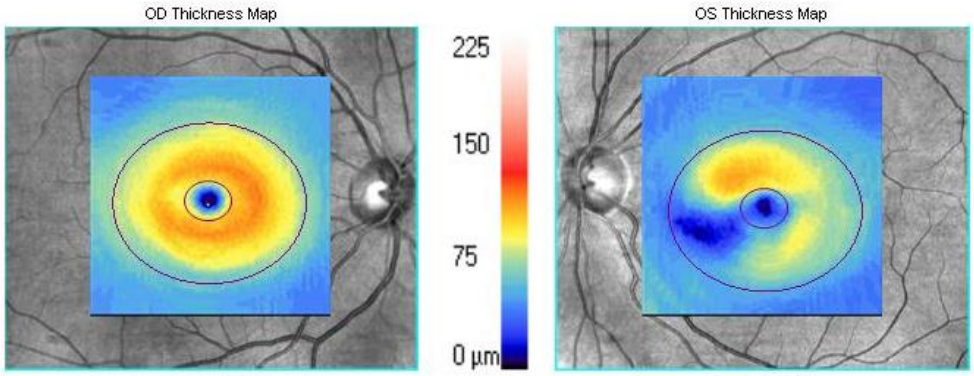

Figure 3 - Tomography of macular coherence showing comparatively the distribution of ganglion cells between right and left eye.

UNDER PEER REVIEW

Discussion

Dengue fever in recent years has become an important public health problem, as it has spread to several continents and has evolved with new clinical manifestations. The clinical picture associated with the visual alteration described in this study is a rare and yet little discussed event in the medical literature.

Visual changes usually occur at the end of the acute phase of the disease, typically present on the seventh day (interval 5-8) after onset of fever. (4) And visual impairment may be either unilateral or bilateral, (6) however, patients generally complain of visual blurring, and, less commonly, of non-specific visual disturbances. (5)

Most ocular complications are found in the posterior pole, such as retinal hemorrhage and macula, peridiscal bleeding, roth spots, diffuse retinal edema, vitreous cells, optic disc margin blurring, serous retinal detachment, choroidal effusion and maculopathy does not specify.

Optic neuropathy is uncommon and results from an inflammatory, infectious or demyelinating process of the optic nerve presenting as retrobulbar neuritis, papillitis or neuroretinitis. (1,9) The mechanism of these manifestations is not well known, but is indicative of an immune-mediated or of etiology for the affective (1,3)

The broad spectrum of ophthalmologic manifestations allows us to conclude that several pathophysiological processes are involved. The thrombocytopenic state, with its tendency to bleed, leads to an increase in the incidence of hemorrhage. The release of cytokines with vasoactive and inflammatory properties, causing capillary leakage, may explain neuritis with papillary edema and perimacular cotton spot, presented in this case.

UNDER PEER REVIEW

Another possibility is a viral mutation, which has already been proven to have occurred in several serotypes, however, without studies of the biological consequences that it can cause. (4)

After recovery from optic neuritis, some patients persist with residual visual alteration, presenting central or paracentral (2) scotoma, due to the lesion in the layer of nerve fibers proved, in our case, by macular OCT. According to Teoh *et al*, this lesion becomes more evident after one month of the initial picture.(5)

The prognosis for ophthalmologic complications is generally good, with improvement in visual acuity and ocular signs and symptoms in most patients without any treatment. (1,8) Steroid use may be an option for patients with more severe or refractory eye involvement , for the possibility of being an immune-mediated process. However, it is still controversial and should be avoided in the acute viremia stage. (4,8)

Thus, further studies are needed to elucidate the mechanism of dengue fever ophthalmic complications. Randomized and controlled trials will help standardize the investigations and better determine the form of treatment for these patients. (1)

Conclusion

Dengue fever is the mosquito-borne viral disease that spreads most rapidly in the world, being the most important arbovirose that affects the human being, being a serious problem of public health in the world. In Brazil since 1986 an epidemic has occurred annually causing great socioeconomic impact.

Prophylactic measures are needed to combat the transmission of dengue. The elimination of breeding foci, the use of protective screens and repellents are fundamental measures to prevent the access of the *Aedes* sp. The non-control

UNDER PEER REVIEW

of the epidemic increases the cases of dengue and consequently there is a greater ocular and systemic affection thus raising the sequelae that the disease can leave.

Ophthalmologic evaluation with fundus examination in the most severe cases, especially in endemic areas, seeking early detection of involvement of the central nervous system could promote better monitoring and treatment.

The treatment in neuropathy is quite controversial and not yet defined, some authors advocate the use of systemic and endovenous corticosteroids in an attempt to improve the visual prognosis, but studies reveal a spontaneous resolution in most cases, even in that cited in the article.

Referencia bibliográfica

1. Yip VC, Sanjay S,Koh YT. Ophthalmic Complications of Dengue Fever: a Systematic Review. Ophthalmol Ther 2012;1(2):1-19
2. Chan DP, Teoh SC, Tan CS, Nah GK, Rajagopalan R, Prabhakaragupta MK et al. The eye institute dengue-related ophthalmic complications workgroup. Ophthalmic complications of dengue. Emerg Infect Dis 2006; 12: 285–289.
3. Sujatha R, Nousheen S, Nazlin A, Prakash S. Ocular manifestations of dengue fever. Int J Med Sci Public Health 2015;4:690-693.
4. Sanjay S, Wagle AM, Au Eong KG. Optic neuropathy associated with dengue fever. Eye 2008; 22; 722–724
5. Teoh SCB et al. Dengue Chorioretinitis and Dengue-Related Ophthalmic Complications. The Eye Institute Dengue-Related Ophthalmic Complications Workgroup 25/01/2012 Acesso em 15/02/2015 disponível em http://www.uveitis.org/docs/dm/dengue_chorioretinitis_and_dengue_related_ophthalmic_complications.pdf
6. Araon W et al. Major Review Dengue Eye Disease Survey of ophthalmology 2015;60:106-114.

UNDER PEER REVIEW

7. Aragão, REM de, Barreira IMA, Lima LNC, Rabelo LP, Pereira FBA. “Neurite Óptica Bilateral Após Infecção Viral Por Dengue: Relato de Casos.” Arquivos Brasileiros de Oftalmologia 2010;73(2):175–178

8. Haritoglou C, Scholz F, Bialasiewicz A, Klauss V. Okuläre Manifestation bei Dengue-Fieber. Ophthalmologe. 2000;97(6):433-6.