UNDER PEER REVIEW

Case study

CYTODIAGNOSIS OF DISSEMINATED RHINOSPORIDIOSIS - A CASE REPORT

ABSTRACT

Aim : Fine needle aspiration cytology of palpable lumps is a simple, inexpensive diagnostic modality. The aim of presenting this case is to highlight its utility in diagnosis of a patient presenting with multiple subcutaneous nodules, which may have varied clinical differential diagnosis.

Presentation of case: We report a case of disseminated rhinosporidiosis diagnosed on fine needle aspiration cytology presenting with swelling in left supraclavicular region andsimilar swellings over his nose, oral cavity, chest wall, forearm and thigh.

Discussion: Rhinosporidiosis is a chronic granulomatous disease of the anterior nares and nasopharynx with polypoidal appearance. Subcutaneous tissue involvement with widespread nodules is extremely rare.

Conclusion: Disseminated Rhinosporidiosis is a rare presentation. Cytomorphological findings are distinctive, FNAC serves as a useful tool in early diagnosis and management of these cases.

Keywords : Rhinosporidiumseeberi, disseminated, recurrent, cytology, stains

INTRODUCTION

Rhinosporidiosisis a chronic granulomatous disease caused by an organism of mesomycetozoea group known as Rhinosporidiumseeberi.[1]

UNDER PEER REVIEW

The first case was described as nasal polyp by Guillermo Seeber from Buenos Aires in 1900. The causative organism was considered as a fungus, and Asworth in 1923 described its life cycle establishing the nomenclature Rhinosporidiumseeberi. [2]

It commonly involves the mucocutaneous sites presenting frequently as polypoidal lesions in the nasal cavity. Uncommon sites of involvement include orbital region, lip, palate, uvula, larynx, trachea, buccal cavity, lacrimal sac, scalp, skin, penis, urethra, vulva, and bone. [3]

Rarely, disseminated infections are reported, involving limbs, trunks and viscera. Brain involvement may lead to fatality. Disseminated infection of limbs is often associated with destruction of underlying bones. [4]

Sporadic cases are reported from all over the world. But>90% of cases occur in South East Asia especially from India, Sri Lanka and Pakistan. [1,3,4]

FNAC or scrape cytology is economical and reliable in preoperative diagnosis. FNAC diagnosis of rhinosporidiosis is specific and has diagnostic utility in cases with unusual clinical presentations. We report a case of disseminated rhinosporidiosispresenting as multiple subcutaneous tissue involvement with widespread nodules diagnosed on fine needle aspiration cytology.

Presentation of Case

A 32 years male presented with swelling in left supraclavicular region and right leg. He also complained of nose block and epistasis. On examination,mobile, slightly tender subcutaneous nodules were also palpable over his jaw, chest wall and forearm. Overlying skin was normal at most places with a slight cutaneous protuberance over swelling in neck and on nose. Nasal

UNDER PEER REVIEW

and oral cavity examination showed fleshly hemorrhagic polypoid structure. (Figure 1) Systemic examination was unremarkable.

Past history revealed that his illness started 14 years back as swelling protruding through the nose, for which he was operated. The swelling recurred at the same site after 3 months of operation. It was excised again and was diagnosed as rhinosporidiosis. He took treatment for the same and subsequent period was uneventful till he developed these swellings at multiple sites.

There was no past history of tuberculosis, Diabetes Mellitus. No significant family history. There was no weight loss or loss of appetite.

Chest X-Ray was normal, HIV tests were negative, Completehaemogram and urine routine were within normal limits. Serum immunoglobulin assay revealed increased IgG 27.0 gr/L (5-12) and Ig A- 5.42 gr/L (0.5-3.5),IgM was within normal limits 2.15 gr/L (0.3-2.3)

Fine needle aspiration cytology from different sites revealed similar cytological material. Aspirate yielded thick blood mixed necrotic material. Both air dried and wet smears were prepared. Direct examination of unstained smears revealed well circumscribed spherules with several brown endospores within. Air dried smears were stained with Giemsa stain and wet smears with papanicolaou stain. Microscopic examination revealed spherules in different stages of maturation and exhibiting great variability in size ranging from 50 to 300 µm. Many ruptured sporangia and released spores were also seen. The spherule was refringent, the chitinous wall was unstained and the endospores were light blue or light green depending on stain. (Figure 2) Background showed dense acute inflammatory exudate with polymorphs arranged in rosette-like pattern around most of the spores. Foreign body type of giant cells and granulomatous response was seen.

UNDER PEER REVIEW

methodology missing????

Air dried smears were also stained with other cytochemical stains like Gridley, Toluidine blue and Periodic acid Schiff (PAS). Gridley stain showed the chitinous wall bright purple, and endospores brown. PAS stain showed positivity for the chitinous wall and endospores outline. Toludine blue also stained both the spherules and the endospore wall.

Concentration by 10% KOH solution showed presence of multiple sporangia filled with endospores in various sizes. This destroys the epithelial cells but does not affect mycotic cells coated with chitin. However, fungal culture of the aspirated material did not show any growth.Based on all the morphological features and findings of cytochemical stains cytological diagnosis of disseminated rhinosporidiosis was made.

what type of medium??/

results???// misssing

Discussion

Disseminated rhinosporidiosis is rare.5 However, review of published data reveals that the frequency of disseminated Rhinosporidiosishas increased in the last 20 years duration since first published case in 1955.

Cutaneous lesions may occur due to autoinoculation or due to hematogenous spread and are described to be of three types: Satellite lesions around the nasal polypoidal lesions,disseminated lesions with visceral involvement and primary cutaneous lesions without internal organ involvement.[6,7] Our case showed a nasal polypoidal mass with satellite lesions, muco-cutanenous lesions involving the oral cavity, and cutaneous nodules over neck, chest wall forearm and right leg mimicking soft tissue tumour. Generalised involvement of skin is probably due to autoinfection caused by scratching the skin with fingers contaminated from infection site. Hematogenous spread produces visceral involvement. [8]

where these features seen?

UNDER PEER REVIEW

The first case of visceral involvement of Rhinosporidiosis was reported by Ranjam et al in 1955 followed by Agarwal et al in 1959 from India. Later there were few more reports of widespread cutaneous nodules together with nasal lesion.Nayak et al reported one case of disseminated cutaneous rhinosporidiosis presenting with numerous subcutaneous swellings mimicking lipomas. [9] Since then various authors have reported similar cases on histopathological examination. But number of cases reported on cytology is few in literature.

The cytologic features are typical. On direct examination the spherules are well-circumscribed, globular structures with several endospores within. The spherules show great variability in size, up to 10-fold. The diameter ranges from 30 to 300 microns. Commonly used stains for detecting R. seeberi include Giemsa, Gridley and PAS stain. [10,11] Similar findings were observed in the present case. In addition we found that routinely done papanicolaou stain was also useful in demonstration of spherules and different stages of maturation. Documentation of definite findings on cytological examination may alleviate the need for histopathology especially in cases with dissemination.

The morphologic characteristics of Rhinosporidiumseeberiresemble those of Coccidioidesimmitis. Both organisms have mature stages that consist of large, thick-walled, spherical structures containing smaller daughter cells (endospores) in a background of granulomatous reaction. Microscopically, rhinosporidium has sporangium of 50-1000 µm with endospores of 5-10 µm in the cytological smearsand its inner sporangial wall stains with mucicarmine and PAS. In contrast Coccidioidesimmitis are usually 20-80 µm in diameter, with thick, double refractile wall. The spherules are filled with small (2-4 µm in diameter) endospores. [4]

Rhinosporidiosis remains a therapeutic challenge amenable only to surgical excision with a high risk of recurrence and occasional widespread and fatal complications.Surgical

UNDER PEER REVIEW

removal and electrodesiccation are the treatments of choice. Dapsone may arrest the maturation of sporangia and accelerate degenerative changes in them. [12]

CONCLUSION

Disseminated Rhinosporidiosisis a rare presentation. Fine needle aspiration cytology serves as a useful tool in early diagnosis and may avoid surgical procedures especially in recurrent cases. Cytomorphological findings are distinctive and may be improved by use of various special stains.

REFERENCES

1. Deshpande AH, Agarwal S, Kelkar AA. Primary cutaneous rhinosporidiosis diagnosed on FNAC: a case report with review of literature DiagnCytopathol. 2009;37(2):125-7.
2. Sengupta S, Pal S, Biswas BK, Jana S, Biswas S, Minz RS. Clinico-pathological study of 273 cases of rhinosporidiosis over a period of ten years in a tertiary care institute catering predominantly rural population of tribal origin. Bangladesh Journal of Medical Science 2015;14(2):159-164.
3. Pal S, Chakrabarti S, Biswas BK, Sinha R,Rakshit A, Das PC.Cytodiagnosis of Extra-nasal Rhinosporidiosis: A Study of 16 Cases from Endemic Area. J Lab Physicians. 2014; 6(2): 80–83.
4. Sinha A, Phukan JP, Bandyopadhyay G, Sengupta S, Bose K, Mondal RK, et al. Clinicopathological study of rhinosporidiosis with special reference to cytodiagnosis. J Cytol 2012;29:246-9.
5. Mohanty RC, Khalkho J, Sahu A. Diagnosis of Disseminated Rhinosporidiosis by Fine Needle Aspiration Cytology. ActaCytol. 2006; 50(2):234.
6. Hadke NS, Ananthkrishnan N, Ratanakar C, Baruah MC. Primary cutaneous rhinosporidiosis. Indian J DermatolVenerolLeprol 1990;56:61-3.

UNDER PEER REVIEW

7. Tolat SN, Gokhale NR, Belgaumkar VA, Pradhan SN, Birud NR. Disseminated cutaneous rhinosporidiomas in an immunocompetent male. Indian J DermatolVenereolLeprol 2007;343-5.
8. Agrawal S, Sharma KD, Shrivastava JB. Generalized Rhinosporidiosis with Visceral Involvement Report of a Case. AMA Arch Derm. 1959;80(1):22-26.
9. Nayak S, Acharjya B, Devi B, Sahoo A, Singh N. Disseminated cutaneous rhinosporidiosis. Indian J DermatolVenereolLeprol 2007;73:185-7.
10. Gori S, Scasso A. Cytologic and differential diagnosis of rhinosporidiosis. ActaCytol. 1994;38(3):361-6.
11. Pathak D, Neelaiah S, Disseminated cutaneous rhinosporidiosis diagnosis by fine needle aspiration cytology. Actacytol 2006;50(1):111-2.
12. Das S, Kashyap B , Barua M, Gupta N, Saha R, Vaid L, Banka A. Nasal rhinosporidiosis in humans: new interpretations and a review of the literature of this enigmatic disease. Medical Mycology 2011; 49: 311–315.

FIGURES

Figure 1: Multiple subcutaneous swellings on neck (A), oral cavity (B) and lower limb (C)

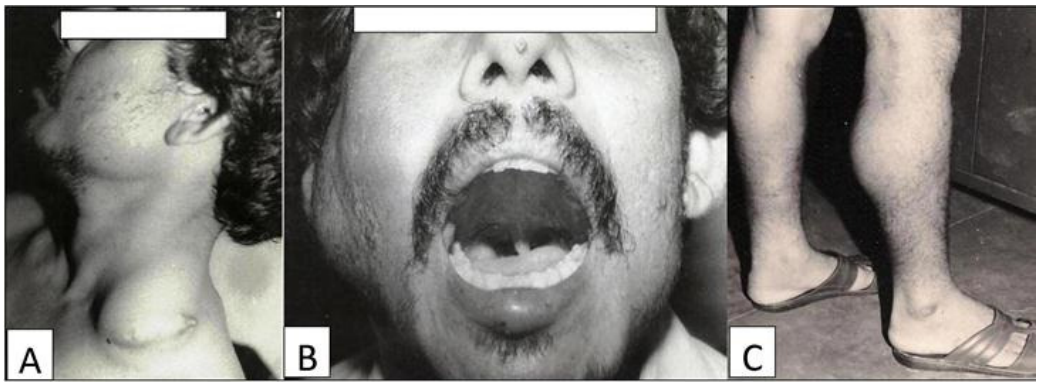

Figure 2: Sporangia at various stages of maturation. A. Globular sporangia containing endospores. Inset - young trophic form.(Pap, 400X) B. Ruptured sporangia releasing the endospores. Inset - sporangium with chitinous wall (MGG, 400 X). C. Giant cell engulfing

UNDER PEER REVIEW
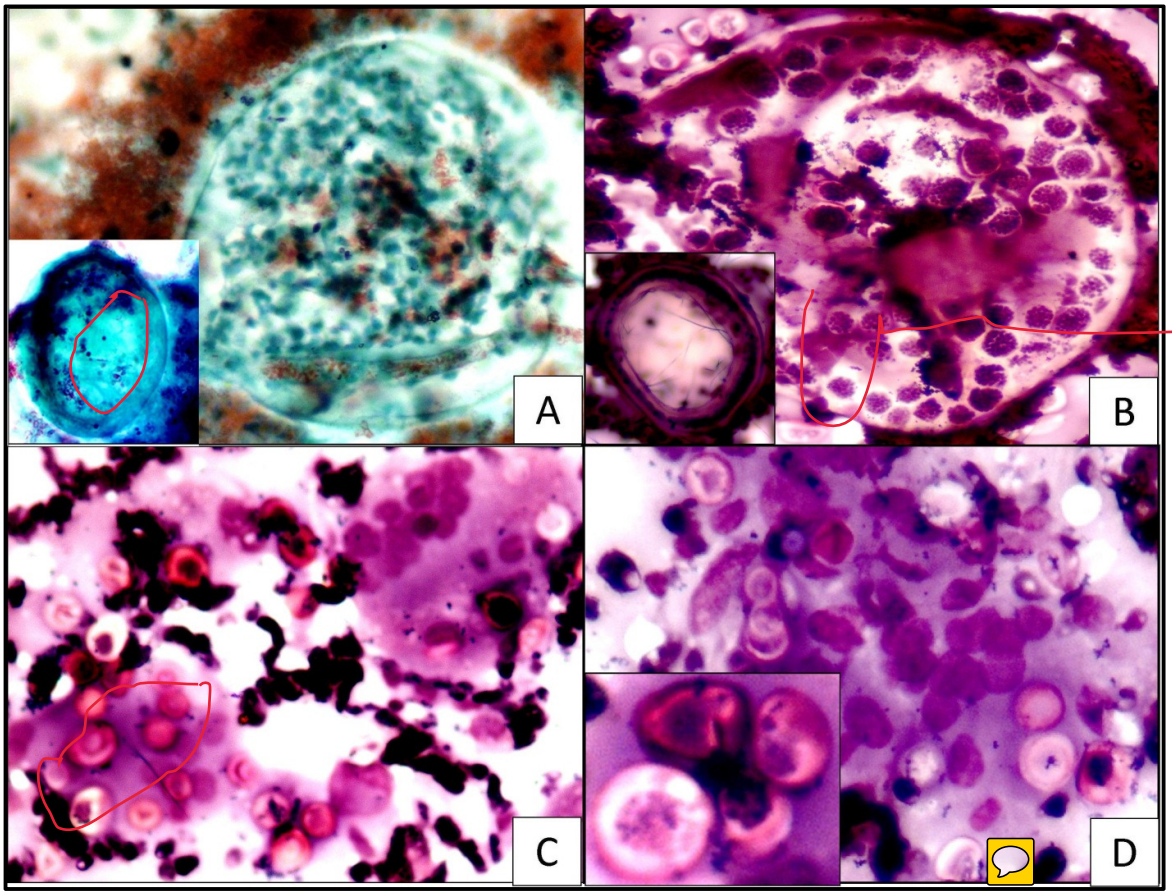
endospores. (MGG, 100X) D. Singly scattered endospores with an epithelioid, granulomatous reaction. (MGG, 400X) Inset –Endospores (MGG , 1000X)