Original Research Article

PLAIN RADIOGRAPHIC PATTERNS OF PELVIC FRACTURES IN PUBLIC HOSPITALS IN SOUTH WEST NIGERIA.

ABSTRACT

Aim and objectives: The purpose of this study was to evaluate the various pelvic fracture types seen in Lagosand its environs, with their accompanying lesions, and compare them to previous works done in literature.

Study design: Prospective, Cross Sectional, Descriptive Study.
Place and Duration of Study:Material and method: Study was carried out in the Radiology departments of three public hospital in South west Nigeria from January to December 2009.
Methodology: Ethical approval was obtained from the Research and Ethics committee of the Lagos State Health Service Commission. The x-rays of one hundred consecutive patients admitted in three tertiary hospitals in Lagos metropolis, diagnosed as traumatic pelvic injuries were documented, analyzed and reported. Statistical analysis was done using Epi Info Version 6 Statistical Software on an IBM- Compatible computer
Results: Out of the One hundred (100) patients recruited, the age ranged from 6 to 69 years with a mean of 31.5 ±2 SD years. Females were slightly more than males, with a M: F ratio of 1.04:1.00. Generally, various types of pelvic ring fractures were seen and they included, Lateral compression fracture (LCF) 45.22%, Anterioposterior compression fracture (APCF) 26.96%, Vertical shear fracture (VSF) 13.04%, Combined / Complex fracture (CCF) 11.30%, and Avulsion fracture (AF) 3.48% in that order.

The acetabular fractures that also occurred included; Central / Combined 38.4%, equal Anterior and Posterior columns 23.1% each and Transverse Acetabular fracture 15.4%.

The appreciable concomitant lesions found in the patients were: soft tissue clinical complications; vascular (28), urogenital (23), neurological (18), infective (6), skeletal (42), degenerative (3) and morphological / structural (11).

Conclusion: In a limited resource country like Nigeria, with limited availability of high end functional imaging facilities, plain radiography as diagnostic imaging tool produced favorably comparable results as found by previous workers in classifying pelvic ring fractures. Its utilization afforded clinically valuable results sparing the patients additional radiation, exorbitant costs and contributed immensely to the early and prompt diagnoses of these fractures.

Keywords: Pelvic trauma, Fracture, Plain Radiography

1. INTRODUCTION

Pelvic ring fractures typically follow high energy trauma from motor vehicular accidents, fall from a significant height and or ground level in the geriatrics and from crush injuries. These are common occurrences in developing countries which have limited, inadequate functional health care facilities. Traumatic injury to the pelvis invariably results in fractures, single, sometimes multiple, subsequently causing immobility. A good number of these accident victims end up in the 'traditional bone setters' home for treatment, a much significant number however receive orthodox treatment. Plain radiographs were the most readily available, accessible and comparatively affordable imaging modality in our environment and is of relatively less radiation, when compared to CT scan.

The bony pelvis is made up of the ilium, ischium and pubis which fuse together as a unit known as the pelvic girdle, attached to both sides of the spine to form an anatomic ring with the sacrum and sockets for the hip bones. It plays a significant role in the stability and transmission of weight from and through the trunk and the legs. It also cradles many internal organs and neurovascular trunks, muscles and ligaments[1,2].

Until recently, the pelvic ring fracture, including acetabular fractures, had traditionally been initially solely diagnosed and classified using conventional plain radiographs (shortly after the discovery of X-rays). But with the advent of modalities such as the Computed tomography[3],plain radiographic use has been down played.

Recent studies however suggest that CT scan images have higher diagnostic accuracy than conventional plain radiographs in classifying acetabular fractures. Conventional plain radiographs had been the mainstay imaging modality because of its affordability, availability, easy accessibility and relatively less radiation. Both CT and MRI scans produce detailed cross section analysis, exhibit the degree of soft tissue injury and reveal inflammation of subchondral region and bone marrow[4]. It is opined that CT scan images are diagnostically beneficial for less experienced surgeons; are at least as good as conventional plain radiographs for experienced surgeons; and spare the patients the discomfort of repeat exposures, consequent to initial poor quality plain radiographs[5]. However, CT scan exposes the patient to additional radiation when compared to plain radiography. CT scan however requires expertise for its interpretation and this is still limited in our environment.

The pelvis, as a lower border to the abdomen, is a complex entity with close interplay of soft tissue structures and conduit of vital structures to the legs, e.g. blood vessels, nerves and lymphatics. Disruption of the pelvic ring by potent life threatening injuries, often require multidisciplinary medicare[6].

Pelvic fracture though essentially minor in up to 75% of cases, ranges from simple pubic rami fracture, to complex pelvic ring disruption after major trauma, invariably with other skeletal fractures in a remarkable proportion. The high incidence of associated soft tissue injuries, risk of severe blood loss, shock, sepsis and adult respiratory distress syndrome make the traumatic pelvic injuries very important[7,8].

Pelvic fractures may be complex, mostly orthopaedics. The assessment of the multiple traumatized patients can be quite enormous, present as complex clinical challenges and often ends up in disorganized evaluation and management. The radiologist more often than not contributes to patient's efficient care. His perceived critical opinion may be at variance with the referring emergency physician's, while the surgeon may not agree with either[9].

Classification of pelvic fractures has been based either on resultant stability / instability of the integrity of the posterior sacroiliac complex, mechanism of injury based on the works of Tileand Young-Burgess[5] respectively or both. However, currently a composite of both was developed by the Association of Orthopaedics and the Orthopaedics Trauma Association[10].The commonly found fracture types are, Anteroposterior compression, Lateral compression, Vertical shear or combination of types[11].

This study therefore aims at evaluating the classification of the various pelvic fracture types diagnosed by plain x-rays.

2. MATERIAL AND METHODS

This was a prospective, descriptive, hospital based study of the radiographic patterns seen in 100 consecutive pelvic x-rays of patients with radiographic diagnoses of pelvic fractures, seen at the accident and emergency departments of three public tertiary hospitals from January to December 2009. These hospitals include the Lagos State Accident and Emergency Services hospitals {LASEMS}, Lagos University Teaching Hospital (LUTH) and National Orthopaedics Hospital, Igbobi (NOHI), Lagos. Ethical approval was obtained from the Research and Ethics committee of the Lagos State Health Service Commission. Written informed consent was also obtained from each of the participants.

Radiological, clinical and socio-demographic data were retrieved from respondents' request forms, case notes and radiographs. Statistical analysis was done using Epi Info Version 6 Statistical

Software on an IBM- Compatible computer. Test of significance was performed using the Statcale Sub Programme Software by Dean A G et al[12]. A p-value of less than 0.05% was regarded as significant at95% CI.

3. RESULTS AND DISCUSSION

There were forty-nine (49%) males and fifty-one (51%) females, with a M:F ratio of 1.00:1.04 in the study group. Majority of the participants (89%) were below 50 years. Eighty-two percent (82%) of the patients received prompt medical attention, **Table 1**.

Table 1:Age group and sex distribution and Promptness of seeking medical attention, (n=100)

Age group in years/duration:	0-10	11-20	21-30	31-40	41-50	51-60	61-70	Total	%
Male	0	6	22	9	8	3	1	49	49
Female	2	10	19	7	6	4	3	51	51
Promptness of seeking Medical attention									
Immediately	2	13	32	14	12	6	3	82	82
1 week	0	1	8	1	2	1	1	14	14
1 week-1 month	0	1	1	0	0	0	0	2	2
1 month – 1 year	0	0	0	1	0	0	0	1	1
1 year and above	0	1	0	0	0	0	0	1	1

Trauma accounted for 99% cases, ninety percent (90%) of which were due to road traffic accident (RTA); domestic fall from a height, 9%; while childbirth labour of spontaneous vertex delivery caused 1%.

The mechanism of injury revealed in this study were attributed to 'Knocked down', 'Passenger – in-vehicle' and 'Crushed' injuries, indicating mode of injury, in that order as was demonstrated in **Table 2**.

Table 2. Aetiology and Mechanism of Injuries: Sex distribution (n= 100).

AETIOLOGY OF INJURY			**MECHNISM OF INJURY**		**SEX**		**TOTAL**	**%**
					MALE	**FEMALE**		
CAUSE	**NUMBER**	**%**						
Road Traffic Accident	90	90	**Knocked down**	**(K)**	15	23	38	38
			Crushed	**(C)**	8	6	14	14
Somersault	**(S)**	4	2	6	6			
Head-0n collision	**(Hc)**	4	4	8	8			
Passenger in vehicle	**(P)**	10	10	20	20			
Fall off vehicle (Fv)		2	2	4	4			
Domestic Accident/ Fall	9	9	**Domestic Accident/ Fall**		6	3	9	9
Labour (Vertex delivery)	1	1	**Child birth trauma**		0	1	1	1
Total	**100**	**100**			**49**	**51**	**100**	**100**

X^2 **=2.46, p> 0.05**

Lateral compression fracture (LCF) fracture, 45.22% was the commonest fracture seen, followed by Anterioposterior compression (APCF) fracture, 26.96%; Vertical shear (VSF) fracture, 13.04%; Combined / Complex (CCF) fracture, 11.30% and Avulsion (AF) fracture, 3.48% in that order, as displayed in **Table 3** and **Figures 1,2,3,4** respectively.

Table 3. Pelvic ring fracture: Types and Sex distribution (n=115).

Fracture types	Male	Female	Total (%)	p value
	N= 54	n =61	n=115	
Anterioposterior Compression (APCF)	13 (24.2%)	18(29.5%)	31 (26.96)	x^2=0.98, p>0.05
Lateral compression (LCF)	26 (48.5%)	26 (42.7%)	52 (45.22)	x^2=0.04, p >0.05
Vertical shear (VSF)	7 (13%)	8 (13.1%)	15 (13.04%)	x^2=0.66, P>0.05
Combined /complex (CCF)	5 (9.2%)	8 (13.1%)	13 (11.30%)	x^2=0.66, p>0.05
Avulsion (AF)	3 (6%)	1 (1.6%)	4 (3.48%)	x^2=0.3, p >0.05

- Note that there was more than one type of fracture in some people

Fig.1. X-ray of the Pelvis, AP View showing a Lateral compression pelvic fracture. Note the bilateral superior and inferior pubic rami oblique fractures (vertical arrows), left posterior acetabular column fracture (oblique arrow), and marginal pubic symphysial diastasis (arrowhead).

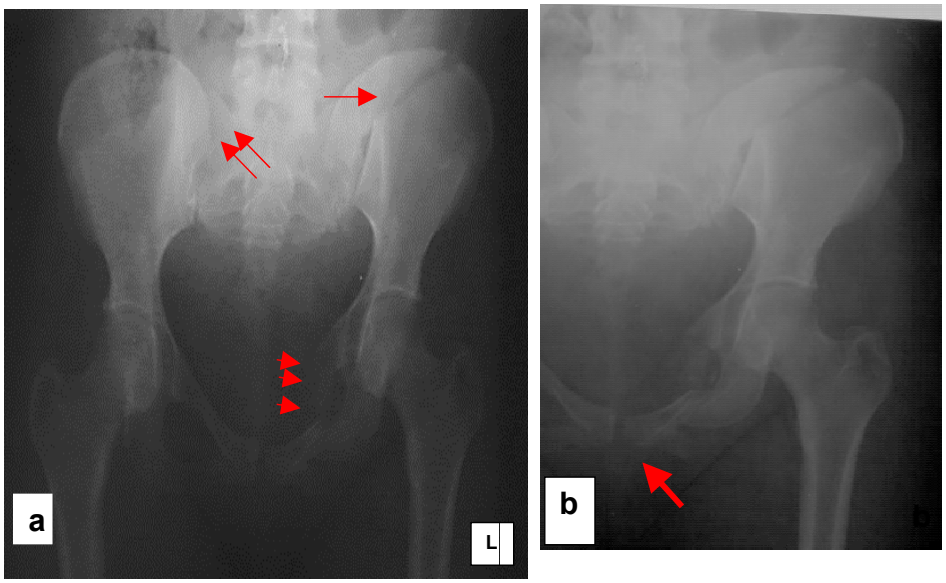

Figs. 2a & b. Plain x-rays of the Pelvis: AP view showing Lateral compression pelvic fracture shows left hemipelvis vertical shear, central acetabular fractures and positive obturator sign (horizontal arrows) (a, b). Note the trans iliac undisplaced fracture (oblique arrow), left superior and inferior pubic rami minimally displaced fractures (horizontal arrowheads). The right hemipelvis is intact.

Fig. 3.X-ray of the Pelvis AP view: Avulsion fractures of the left pubic tubercle and ischial tuberosity (horizontal arrow) (short arrows) respectively. Note sutural diastasis of the pubic symphysis (vertical arrows) and pelvic asymmetry, in keeping with vertical shear pelvic fracture.

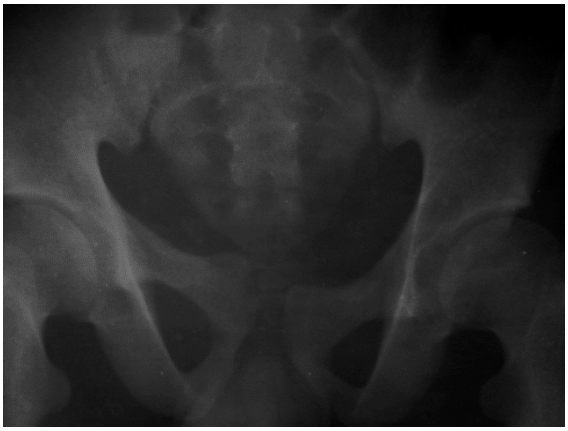

Fig.4. Plain x-ray of the Pelvis. AP View showing Bilateral sacroiliac joints (anterior and posterior) and pubic symphysis diastases (horizontal arrows) and minimal asymmetry of the pubic bones (arrowheads) indicating Vertical shear fracture.

The study further showed that pubic bone, sacroiliac joints and pubic symphysis demonstrated fractures and diastases in that order, **Table 4**.

TABLE 4. Frequency distribution of Sites of pelvic fracture (n=100).

FRACTURE SITES	MALE n=97	FEMALE n=105	TOTAL n=202	%	p Value
Sacral fracture	1 (1%)	1 (.9%)	2	0.9	x^2 =0.3, p.0.05
Iliac fracture	9 (9.3%)	6 (5.7%)	15	7.5	x^2 =0.66, p>0.05
Ischial fracture	2 (2.1%)	0	2	0.9	x^2 =0.3, p>0.05
Pubic fracture	38 (39.1%)	39 (37.1%)	77	38.1	x^2 =0.03,p>0.05
Pubic symphsis Joint diastases (PSJ)	15 (15.5%)	21 (21%)	36	17.9	x^2=0.88,p>0.05
Sacroiliac joint Diastases (SIJ)	17 (17.5%)	22 (20.9%)	39	19.3	x^2 =0.88,P>0.05
Acetabular fracture	12 (12.4%	14 (13.6%))	26	12.9	x^2 =2.46, p>0.05
Avulsion fracture	3 (3.1%)	2 (1.8%)	5	2.5	x^2 =0.06,p>0.05

Pubic rami fractures were found in the Left (29), Bilateral (25) and Right (23) sides in descending order, while combined (63), inferior (14) and superior (8) rami involvement were seen as highlighted in **Tables 5**.

Table 5: Pubic rami fractures: Age group, sex and side pattern (n=100).

Age group (in years)	Right			Left			Bilateral			Superior & Inferior Rami			Superior ramus			Inferior ramus		
	M	F	Total	M	F	Total	M	F	Total	M	F	Total	M	F	Total	M	F	Total
0-10	0	0	0	0	1	1	0	0	0	0	1	1	0	0	0	0	0	0
11-20	2	1	3	2	2	4	0	2	2	4	5	9	0	0	0	0	0	0
21-30	7	3	10	5	5	10	6	9	15	16	11	27	2	2	4	2	5	7
31-40	3	2	5	2	2	4	2	1	3	6	3	9	0	0	0	2	1	3
41-50	1	3	4	6	2	8	0	1	1	6	4	10	1	3	4	0	4	4
51-60	0	1	1	0	0	0	1	2	3	1	3	4	0	0	0	0	0	0
61-70	0	0	0	1	1	2	0	1	1	1	2	3	0	0	0	0	0	0
Total	13	10	23	16	13	29	9	16	25	34	29	63	3	5	8	4	10	14

X^2=1.36, p>0.05 x^2 =0.07,p>0.05 x^2=0.25,p>0.05 x^2=2.20,p>0.05

Joint diastasis was noted in the sacroiliac joint (39) and was marginally more than in pubic symphysis diastasis (36). However its range was wider in pubic symphysis (8– 40mm) than in the sacroiliac joint (6–10mm), **Tables 6, 7.**

Table 6: Pubic symphsis: Degree of diastasis (n=36).

DEGREE OF DIASTESIS	MALE N=16	FEMALE N=20	TOTAL N=36
Marked 11-40mm	9 (60%)	7 (33%)	16 (44%)
Mean =16mm	**Mean =**18.12mm		
Moderate 8 -10mm	6 (40%)	14 (67%)	20 (55.6%)
Total	15 (100%)	21 (100%)	36 (100%)
X^2 = 1.63, P>0.95			

Table 7: Sacroiliac joint involvement: Sex, Side and Site distribution (n=39).

Sex	Right n=12	Left n=10	Bilateral n=17	Diastases n=39
Male	8 (67%)	5 (50%)	4 (23.5%)	17 (43.6%)
Female	4 (33%)	5 (59%)	13 (76.5%)	22 (56.4%)
Total (n=39)	12 (30.8%)	10 (25.6%)	17 (43.6%)	39 (100%)
X^2 = 6.55, p>0.05.				

Acetabular fractures were found in 26 patients, with fairly equal sex distribution of 14F:12M, as Central / Combined, Anterior and Posterior and Transverse fractures 10, 6, 6, 4, in that frequency, **Tables 8** and **Figures 1, 2 a & b, 5 & 6.**

Table 8. Acetabular fractures: Category and Sex distribution (n=26).

FRACTURE TYPE	MALE N=12	FEMALE N=14	TOTAL	FREQUENCY %
Anterior column	2 (16.6%)	4 (28.6%)	6	23.1
Posterior column	5 (41.7%)	1 (7.1%)	6	23.1
Transverse acetabular	0	4 (28.6%)	4	15.4
Central / combined	5 (41.7%)	5 (35.7%)	10	38.4
Percentage overall	46 54	6	100	
X^2 = 7.22, p =0.065>0.05				

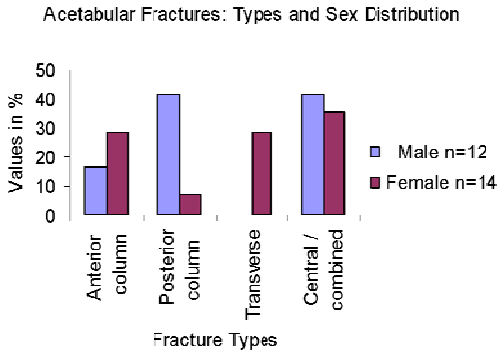

Fig. 5: Acetabular Fractures; Types and Sex distribution

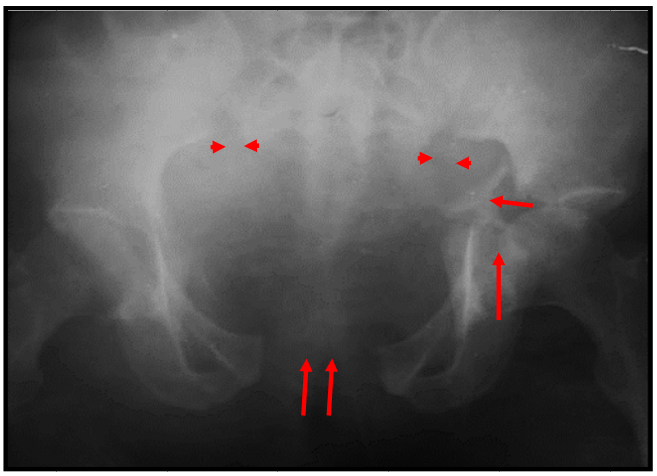

Fig 6: Plain x-ray of the Pelvis, AP view showing Anterioposterior compression fracture shows a Combined / Complex Acetabular fracture of the left hemipelvis (single vertical arrow), with detached fragment medially displaced into the pelvis (horizontal arrow), wide diastasis of the pubic symphysis (vertical arrows) and bilateral sacroiliac diastases (arrowheads) ”open book” fracture.

Other associated skeletal fractures and soft tissue complications encountered include, 42 Skeletal axial (cranial, ischial and iliac, Appendicular: Humerus, clavicle, ribs, radius and ulna, femur, tibia and fibula, hand and feet); 11 Morphologic / Structural (asymmetry, limb shortening and coxa vera); 28 vascular. Haemorrhage was the most perilous, and may occur as frank haemorrhage. Heamoperitoneum was more with lateral compression fracture while heamaturia was more in acetabular fractures. Others were, 23 urological co-morbidities (heamaturia, bladder laceration, urethral rupture and vesicovagina fistula). Eighteen neurological lesions which include radiculopathy, hemiplegia, paraplegia, paraparesis and enuresis were seen. Six infective cases were also seen in

form of osteomyelitis, myositis, cellulitis; and 3 degenerative cases in form of oesteoarthritis and spondylosis.

3.1 **Discussion**

Sampson et al's[13] report of 50% and 77% cases of pelvic fractures under 30 and 50 years respectively agrees with the present study's 59% and 89% respectively and 11% in the 51-70 years group. The bimodal distribution of age seen in pelvic injuries in this study occurred between the ages of 11 to 30 years and 31 to 50 years, whilst it was 15 to 30 years and 50 to 70 years in Gansslen et al's[14]done in Hannover, Germany. This might be attributed to the period when physical activities are maximal. The male to female ratio of 1:1.04 compares favorably with Ekwere's[6]study which showed equal sex distribution of accidental injuries, but is at variance with Sampson's[13]study with M:F ratio of 3:1. The sex distribution of participants in the index study was fairly equal, as shown in **Table 2.** These age groups are the active workforce, which thus placed them at the high risk for road traffic accident.

The present study's findings that road traffic accident accounted for ninety percent (90%), domestic accident; fall, nine percent (9%) was congruent with Dalal et al's[11]88% domestic and fall of nine (9%). This was corroborated in other studies by Pereira et al[7], Sandro et al[15]**,** Ekwere's[16] 71.3%, Heare's[17] 85%, Berquist's[18] 92%, Langford JR et al[19] and Solomon[20] 67%.

Depending on the type, magnitude and direction of the force, the mechanism of injury noted in this study were; ''Knocked down' (direct hit), 'Passenger-in- vehicle' group, 'Crush injury', 'Head-on collision', 'Somersault' and 'Fall-off ''a moving vehicle. These result in Compression fractures such as Anteroposterior /Lateral, Vertical shear and or any combination of fracture. This is in agreement with Sandro et al[15]**,** Dalal et al[21], Collinge[22], Depypere[23], and Burlew[25].

The Lateral compression fracture 45.2%, which was the index study's commonest fracture was similar to findings by Lee and Porter[26] and consistent with Young[27] finding of 50%. This type of fracture was also associated with central acetabular fracture in 19% as found by Berquist[18].

Anterioposterior compression fracture found in 31% of the present study group compares well with the 21% of other studies[18,19,20,21,28.29].

The index study's 15 % Vertical shear fracture agrees withKane's[30] 16%, but is at variance with Young's[31]et al study of6 % considering lack of and or noncompliance of available work sites safety measures in developing country as Nigeria. The lower finding of Young when compared to that of Kane is inferred from advancing technology and ergonomics obtainable in developed countries.

The 13% of the present study's complex / combined pelvic fractures compares well with 14% in Allison's study[32].

Acetabular fracture entity elicited bySampson and Berquist[18], Muller et al's [33] 50% and 77% respectively within the 0-30 years and 30 - 50 years age groups compare favourably with findings in the present study's 46% and 73% respectively. But their 3:1 male to female ratio is at variance with the present study's equal sex ratio concerning this fracture.

Harriset al's[34]findings of 16% in acetabular fractures compares favorably with our study's 26 %, without pelvic ring disruption. This is a seeming contradiction when indeed the acetabular fracture interrupts the continuity of the perimeter of the pelvic inlet to the true pelvis. This opinion is directly related to the definition of the pelvic ring disruption as interruption of the continuity of the pelvic ring at two or more sites on opposite sides of the pelvic inlet; acetabular fracture however fails to suit this definition[10].

The iliac fracture usually undisplaced and consequently hemodynamically stable as reported byMelton'set al[35]2.5 % is at variance with the index study's 16 %. This might be attributed to better attendant immediate medicare available abroad contrary to what obtains in Nigeria.

4. CONCLUSION

The commonest fracture in pelvic ring fractures are Lateral compression, Anterioposterior, Vertical shear, Combined / complex and Avulsion fractures in decreasing order.
Acetabular fracture is fairly commonly,seen as Central /Combined fracture type.

Pubic bone, sacroiliac and pubic symphysis joint fractures are found as fracture and diastases in that order.

COMPETING INTERESTS

The authors report no conflicts of interest and are responsible alone for the content and writing of the article.

CONSENT

Ethical approval was obtained from the Research and Ethics committee of the Lagos State Health Service Commission. Written informed consent was also obtained from each of the participants.

ETHICAL APPROVAL

Ethical approval was obtained from the Research and Ethics committee of the Lagos State Health Service Commission. Written informed consent was also obtained from each of the participants.

All authors hereby declare that all experiments have been examined and approved by the appropriate ethics committee and have therefore been performed in accordance with the ethical standards laid down in the 1964 declaration of Helsinki."

LIMITATIONS

The patients were exclusively limited to plain radiography diagnosed traumatic pelvic fracture.

RECOMMENDATIONS

Regardless of the aetiology of the pelvic injury either in paediatrics, adult or geriatrics patients, the eventual outcome rests majorly on the early recognition, stabilization, early fixation and rehabilitation. These patients especially the multi traumatised need collaborated multidisciplinary approach throughout the trajectory of care, and follow up rehabilitation. This protocol is aimed at returning the patient with reasonably minimized or devoid of untoward disability with a view to ensure optimal functional responsibility. Aggressive competent multidisciplinary approach cannot be over emphasized in achieving the desired goal.

REFERENCES

1. Theodore Dimon Jr (2010). The body in motion: its evolution and design. Berkeley, Calif.: North Atlantic Books. pp.49-56. ISBN 978-1556439704.
2. Dunn J. Pelvic fracture: The American Association for the Surgery of Trauma Accessed on 20th May 2017. Available at http://www.aast.org/Print.aspx April 30:2012.
3. Roult Jr MLC, Agarwal A. Acetabular fractures: definitive treatment and expected outcomes. In: Teague D, Schmidt A, editors. Orthopaedic knowledge update: trauma 4, Rosemont: American Academy of Orthopaedic Surgeons, vol. 2010. 2010: 323-35.
4. O'Toole RV, Cox G, Schnmuganathan K, Castilo RC, Turen CH, Sciadini MF, et al . Evaluation of computed tomography for determining the diagnosis of acetabular fractures. J Orthop Trauma. 2010; 24: 284-290.
5. Abdelfattah AA, Moed BR. CT-generated radiographs in patients with pelvic ring injury: can they be used in lieu of plain radiographs? Journal of Orthopaedic Surgery and Research 2016 11:26.

6. Figler BD, Hoeffler CE, Reisman W. Multi-disciplinary update on pelvic fracture associated bladder and urethral injuries. Injury 2012; 43:1242.

7. Pereira SJ, O'Brien DP, Luchette FA. Dynamic helical computed tomography scan accurately detects hemorrhage in patients with pelvic fractures. Surgery 2000; 128:678.

8. Vaidya R, Scott AN, Tonnos F. Patients with pelvic fractures from blunt trauma. What is mortality and when? Am J Surg 2016; 211:495.B7.

9. Stahel PF, Mauffrey C, Smith WR. External fixation for acute pelvic ring injuries:decision making and technical options. J Trauma Acute Care Surg 2014; 76:134.

10. Marsh JL, Slongo TF, Broderick JS, Creevey W, DeCoster TA. Fracture and dislocation classification compendium—2007: Orthopaedic Trauma Association Classification, database and outcomes committee.J Orthop Trauma. 2007;21(10 Suppl):S1-133.

11. Sagi HC. Pelvic ring fractures. In: Bucholz RW, Court-Brown CM, Heckman JD, and Tornetta P111, Editors. Rockwood and Green's fractures in adults. 7th ed. Philadelphia: Lippincott Williams &Wilkins, 2010; pp.1415-1462.

12. Dean AG, Dean J A, Coulombier D, Brendel KA, Smith DC, Burton AH, et al. Epi Info, Version 6: A word-processing, Database, and Statistics Program for Public Health on IBM-compatible Microcomputers. Centers for Disease Control and Prevention, Atlanta, GA, U.S.A.1996: pp. 1-603.

13. Sampson J, Berquist TH. Pelvic fractures: A review of 750 cases; A study presentation to the American Roentgen rays society. Las Vegas, USA 1981.

14. Gansslen A, Pohleman T, Paul C, Lobenhoffer P, Tscheme H. Epidemiology of pelvic ring fractures. Injury 1996; 27 (Suppl 1: SA):13-20.

15. Sandro CT, Chew FS, Coombs BD, Keats TE, Gentili A, Thorton DD. Pelvic fracture Imaging. Accessed on10/11/2016. Accessed on 20th May 2017. Available at http://emedicine. Medscape.com/article/394515-overview

16. Ekwere P.D. The clinical pattern of Urogenital Trauma in a Nigerian Hospital. The Nig. Post-Grad. J. 2000; 7.4: 171-176.

17. Heare MM, Heare TC and Gillepsy 111 T. Diagnostic Imaging of Pelvic and Chest Wall Trauma. Radiologic Clinics of North America1989; 27(5): 873-889.

18. Berquist TH. The Pelvis and Hips: In: Berquist TH, ed. Imaging of Orthopaedic trauma. 2nd Edition, Raven press Ltd. New York, 1992; pp. 207-310.

19. Langford JR, Burgess AR, Liporace FA. Pelvic Fractures; part1. Evaluation, classification, and resuscitation. J. Am Acad Orthop Surg. 2013; 21(8): 448-457. Doi: 10.5435/JAAOS-21-08-448

20. Solomon L: Injuries of the pelvis. In: Solomon L, Warwick D, Nayagam S (eds.): Apley System of orthopaedics and fractures. 9th edition, Butterworth and Heinemann, London, 2010; pp. 828-841.

21. Dalal SA, Burgess AR, Siegel JH, Young JW, Brumback RJ, Poka A, et al. Pelvic fracture in multiple trauma: classification by mechanism is key to pattern of organ injury, resuscitative requirements, and outcome. J Trauma.1989; 29:981-1000.

22. Collinge C and Tornetta111 P. Soft tissue injuries associated with pelvic fractures. Orthop Clin N Am 2004; 35: 451-456.

23. Depypere L and Broos PLO. Acute assessment of pelvic fractures and their associated soft tissue injuries. In: Folia Traumatologica Lovaniensia 2007. Eds.: Reynders P., Broos P., Bellemans J.: 21-29.

24. Wikipedia. Pelvic_ fracture&oldid=7238140414. Accessed on 5th June 2016. Accessed on 20th May 2017. Available athttps://en.wikipedia.org/w/index.php?

25. Burlew CC, Moore EE, Smith WR. Preperitoneal pelvic packing/external fixation with secondary angioembolization: optimal care for life-threatening hemorrhage from unstable pelvic fractures, J Am Coll Surg 2011; 212:628.

26. Lee C, Porter K. "The prehospital management of pelvic fractures." Emergency medicine journal 2007; 24(2):130-133. Doi: 10.1136/emj.2006.041384. PMID 17251627

27. Young JWR, Burgess AR, Brumback RJ, Poka A. Lateral compression fractures of the pelvis: Importance of plain radiographs in diagnosis and surgical management. Skel Radiol. 1986; 15:103-109.

28. Daffner RH. Pelvic trauma. In: McCort JJ (ed). Trauma radiology.3rd edition, Churchill Livingstone, New York, 1990; pp. 78-93.

29. Furey AJ, O'Toole RV, Nascone JW: Classification of pelvic fractures: analysis of inter- and intraobserver variability using the Young- Burgess and Tile classification systems. Orthopedics. 2009; 32(6):401. Doi. 10.3928/01477447-20090511-05

30. Kane WJ. Fractures of the pelvis. In: Rockwood CA, Green DP (eds): Fractures in adults. 2nd edition, J.B Lippincott, Philadelphia, 1984: pp: 1093-1209.

31. Young JWR, Burgess AR, Brumback RJ, Poka A. Pelvic fracture:Value of plain radiography in early assessment and management. Radiology 1986;160: 445 - 451.

32.Allison Moriarty: Classification of Pelvic fracture. A Mechanistic Approach.Accessedon 09 March 2016.Retrieved from https://www.Dhsu.edu, Docslide.net.Document MAGX# 16/12/2006.

33. Muller ME, Nazzarin S, Koch P. Classification OA des fractures1; Les os long. Springer {verlag2, Berlin-Heidelberg} New York, AO Publishing 2006; pp 1-7.

34. Harris JH Jr., Harris WH, Novelline RA. The radiology of Emergency Medicine. 5th edition, Williams & Wilkins, Baltimore, 2013; pp. 693-818.

35. Melton LJ. Epidemiologic features of pelvic fractures .Clin Orthop 1981; 155: 43-47.