Original Research Article

TUBERCULOSIS IN THE HEAD AND NECK REGION: EXPERIENCE IN THE EASTERN TERTIARY CARE CENTRE OF NEPAL

Abstract:

Introduction: Tuberculosis (TB) primarily affects lungs, however extra pulmonary tuberculosis (EPTB) is also common, especially in high disease load areas and mainly manifests in head and neck region.

Objective: To study the otorhinolaryngological manifestations of tuberculosis in eastern tertiary care centre of Nepal and its relationship with primary tuberculosis of lung and human immunodeficiency virus infection.

Methods: This is a retrospective study conducted in the Department of Otolaryngology and Head and Neck Surgery in B.P.Koirala Institute of Health Sciences, Nepal. Our study group comprised of 85 patients diagnosed with extrapulmonary manifestations of tuberculosis in the head and neck region from 2012-2014 over the period of 2 years. Records of patients diagnosed and treated for tuberculosis in the head and neck region at our institute for two year period were analysed for presenting complaints, examination findings, diagnostic features, treatment modes and outcome. Pulmonary tuberculosis was screened in all patients by doing chest radiography and sputum AFB (Acid Fast Bacillus). HIV (Human Immunodeficiency Virus) screening was also done in all patients.

Results: 85 cases showed extrapulmonary otorhinolaryngological manifestations of tuberculosis. Majority of the cases were male and in the third decade of life. Commonest manifestation was cervical lymphadenopathy. Fine needle aspiration cytology (FNAC), histopathological diagnosis and Acid Fast Bacilli (AFB) staining were used to confirm the diagnosis. All patients were treated with category I anti TB treatment (ATT) in the DOTS (Direct Observed Treatment Shortcourse) clinic which achieved cure in all cases.

Conclusion: Extrapulmonary manifestations of tuberculosis in the head and neck region is a frequent, clinical entity encountered especially in developing countries like Nepal. It should always be kept as one of the differential diagnosis in the pathology of head and neck region. High degree of suspicion is necessary to reach diagnosis. Category I ATT is effective for treatment.

Keywords: *Tuberculosis, Cervical lymphadenopathy, Acid Fast Bacilli (AFB), Fine Needle Aspiration Cytology (FNAC)*

INTRODUCTION

As per WHO data there were nearly nine million new cases of Tuberculosis in 2011 and 1.4 million tuberculosis related deaths (990,000 among Human Immunodeficiency Virus (HIV) negative people and 430,000 TB deaths associated with HIV). The disease is more common in males affection mostly adults of economically productive age groups. Most of the cases are seen in Asia (59%) and Africa (26%). Small percentage of cases are seen in Eastern Mediterranean Region (7.7%), Europe (4.3%) and the Americas (3%).[1] As per WHO data the largest series of new TB cases was reported from South East Asia region. Tuberculosis is still considered as an execration because of increasing reports of drug resistance of tubercle bacilli and wide prevalence of HIV infection.[2]

Tuberculosis has been a curse for mankind. In spite of effective free drug treatment under DOTS (Directly Observed Treatment Shortcourse) and government policy, a huge number of morbidity and mortality occurs in countries like Nepal where the load of the disease is high. According to WHO report of 2013, the prevalence of tuberculosis in Nepal is 66,000 per year (241/1, 00,000) and incidence is 45,000 per year (163/1, 00,000).The prevalence of HIV in Nepal is 0.3% and the prevalence of HIV infection among tuberculosis patients is 2.4%. [3] The lung is the most common organ affected but no part of the body is immune to this condition. A large proportion of extra pulmonary tuberculosis (TB) occurs in the ear, nose and throat and head and neck region in the form of cervical lymphadenopathy, otitis media, laryngitis, pharyngitis and nasal tuberculosis. Atypical manifestation of tuberculosis may lead to diagnostic dilemma which lead to delayed diagnosis and sometimes wrong treatment plans. Hence it is very important that in countries like Nepal where there is a high disease load, the medical practitioner should be well versed about the extra pulmonary manifestations of tuberculosis, should confirm the diagnosis by either sputum test, FNAC, or histopathology whichever is appropriate and initiate proper treatment at the earliest.[4]

MATERIALS AND METHODS

This is a retrospective study. Records of all patients registered at the DOTS (Direct Observed Treatment, Short Course) center at our institute during the period April 2012 to June, 2014 were studied. All cases with TB in ENT region were considered for the study. Details regarding demographic data, presenting complaints, examination findings, investigation reports, treatment given and outcome were recorded. All data were collected, tabulated and analysed.

Both informed and written consent were taken from the patient who were participating in the study.

Diagnosis of tuberculosis was based on the following features.

Laryngeal Tuberculosis: The patient with laryngeal tuberculosis typically presents with hoarseness of voice, dysphagia and stridor along with loss of weight and appetite. The fibreoptic laryngoscopic examination shows pale granulation tissue and erythema mostly in the glottis region. Then biopsy is taken under general anaesthesia and the tissue is sent for histopathological examination, mycobacterial culture and staining and susceptibility testing.

Tuberculosis of the Ear: The patient presents with persistent otorrhoea not responding to antibiotics, hearing loss and sometimes facial palsy. Otoscopic examination reveals multiple perforation of the drum with pale granulation tissue. Acid fast bacillus staining of the discharge confirms the diagnosis.

Tuberculosis of the Nose and Paranasal Sinus: The patient presents with nasal obstruction and blood stained discharge. On examination granular lesions in the nose and nasopharynx can be seen. Histopathology examination and mycobacterial culture and susceptibility testing helps in establishing the diagnosis and management.

Tuberculosis of Neck Nodes: Any non-tender cervical lymph nodes not responding to conservative antibiotic treatment for 2 weeks was sent for fine needle aspiration cytology which shows whether the

patient has cervical lymph node tuberculosis or not. If the fine needle aspiration report is inconclusive then biopsy of the lymph node was taken to establish the diagnosis.

Laboratory Diagnosis. Tissue samples were sent for laboratory investigations to both the Histopathology Laboratory and the Microbiology Laboratory for mycobacterial smear and culture. Culture was done in Löwenstein–Jensen medium. Chest radiography and three consecutive sputum samples for mycobacterial smear was done in all patients to rule out coexisting pulmonary tuberculosis. All patients were screened for HIV. The site and severity of extrapulmonary tuberculosis like tuberculous lymphadenitis, deep neck abscess, laryngeal tuberculosis and salivary gland tuberculosis were assessed by radiological evaluation either by ultrasound or computed tomography of neck.

After the diagnosis had been established all patients were started on six months of anti-tubercular therapy.

Data was analysed using Fishers exact test and p value less than 0.05 is considered as significant.

RESULTS

The study includes 85 patients with extrapulmonary manifestations of tuberculosis in the head and neck region. Among them, 60 patients (70%) were males and remaining 25 (30%) were females. Patients aged 14 to 65 years were included in the study. The most common age group was of 31-40 years. In the head and neck region, cervical lymph nodes (65.88%) was observed to be the most common area for extrapulmonary manifestations of tuberculosis. This was followed by deep neck space abscess (11.76%). The most common presentation was neck swelling seen in 65 patients (78.82%). All patients were given anti-tubercular therapy for 6 months under DOTS program with 100% success rate. The success rate is comparable to the success of National Tuberculosis Program of Nepal which is around 90%.[3] All patients (11.76%) with deep neck abscess underwent surgical intervention. 13 patients (15.29%) had coexisting HIV infection and 26 patients (30.59%) had associated pulmonary tuberculosis.

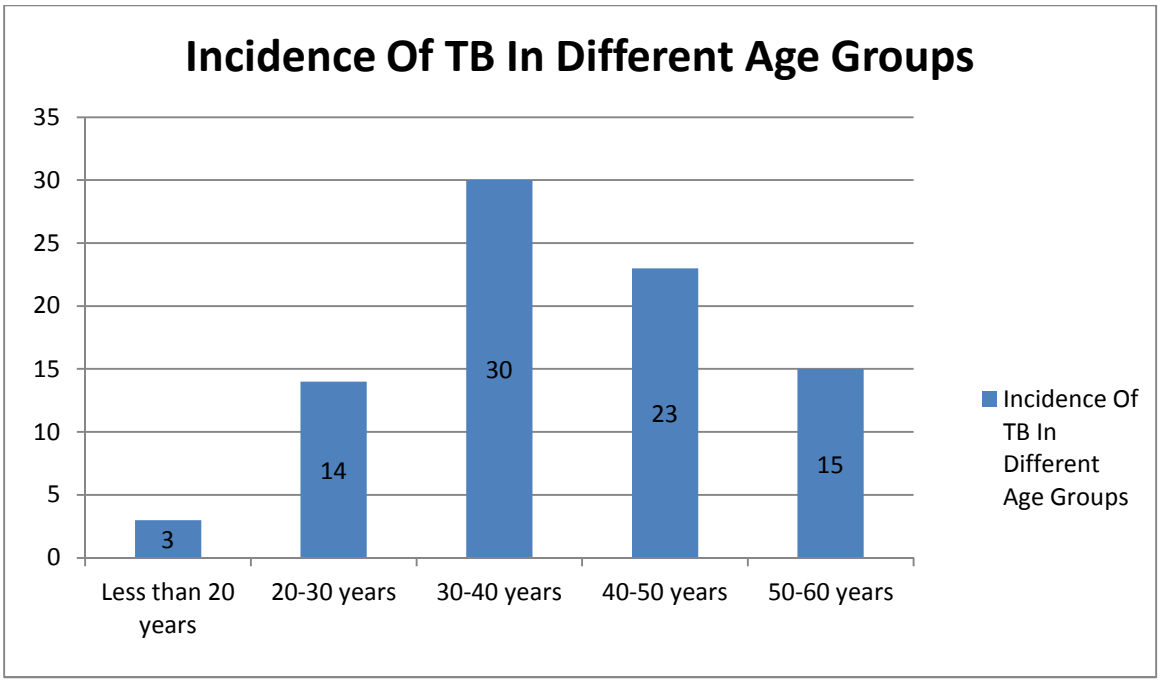
Incidence Of TB In Different Age Groups
35
30
25
20
15
10
5
0
3
14
30
23
15
Less than 20 years
20-30 years
30-40 years
40-50 years
50-60 years
Incidence Of TB In Different Age Groups

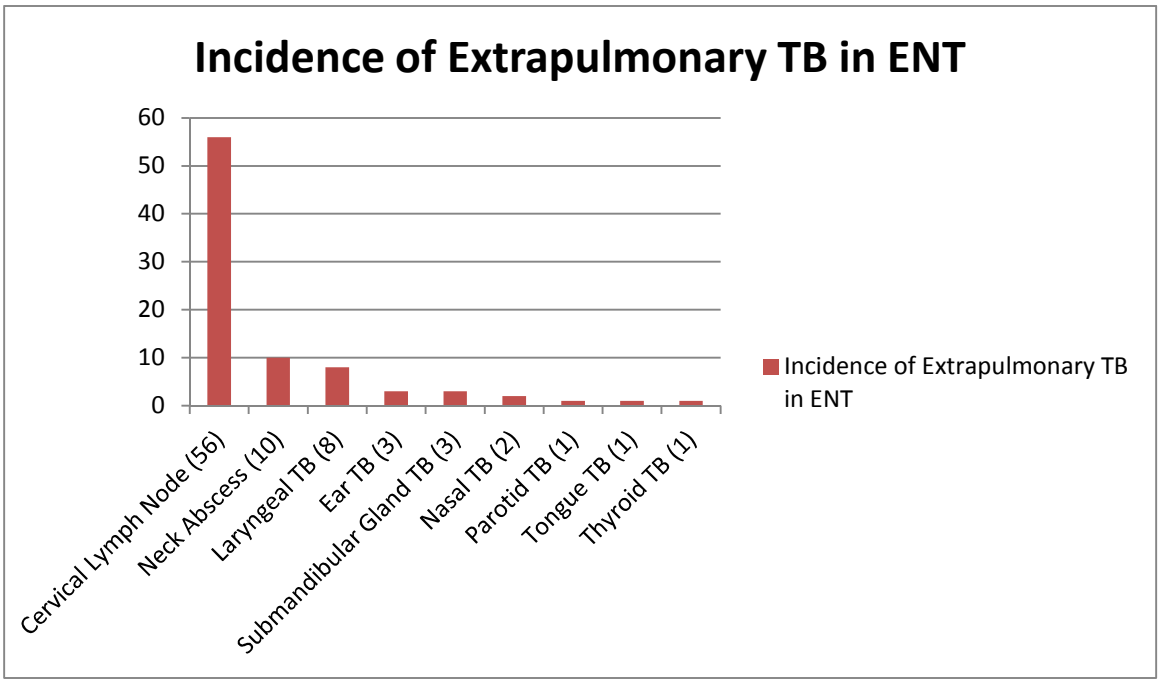
Incidence of Extrapulmonary TB in ENT
60
50
40
30
20
10
0
Cervical Lymph Node (56)
Neck Abscess (10)
Laryngeal TB (8)
Ear TB (3)
Submandibular Gland TB (3)
Nasal TB (2)
Parotid TB (1)
Tongue TB (1)
Thyroid TB (1)
Incidence of Extrapulmonary TB in ENT

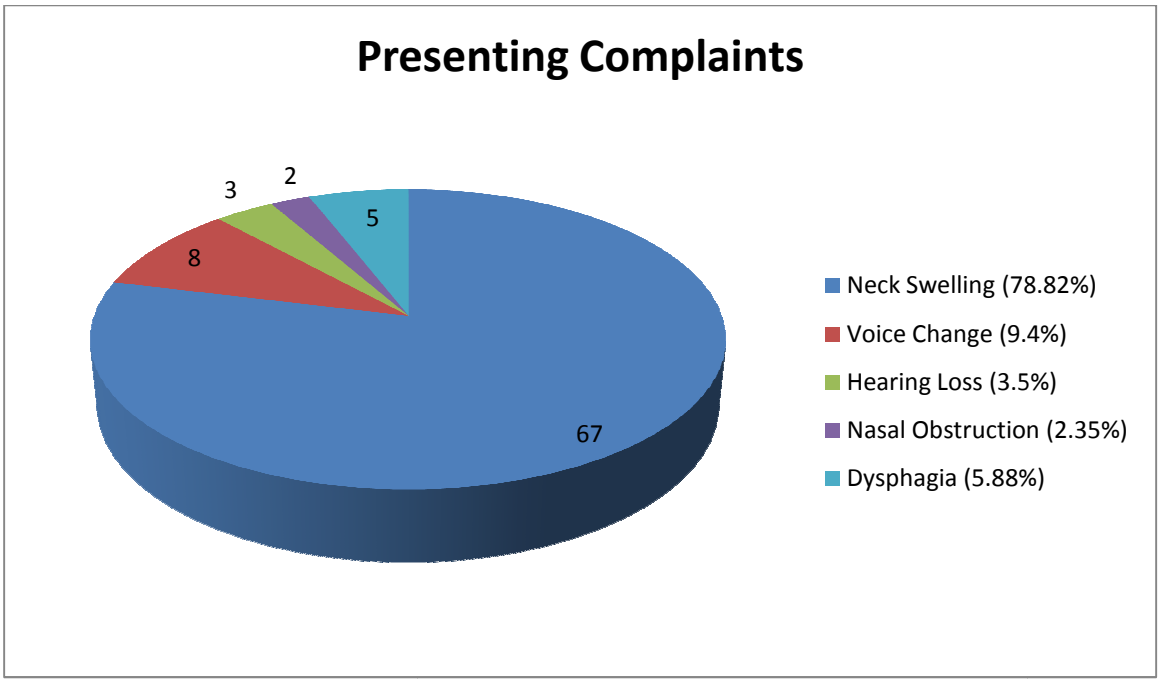
Presenting Complaints
67
8
3
2
5
Neck Swelling (78.82%)
Voice Change (9.4%)
Hearing Loss (3.5%)
Nasal Obstruction (2.35%)
Dysphagia (5.88%)

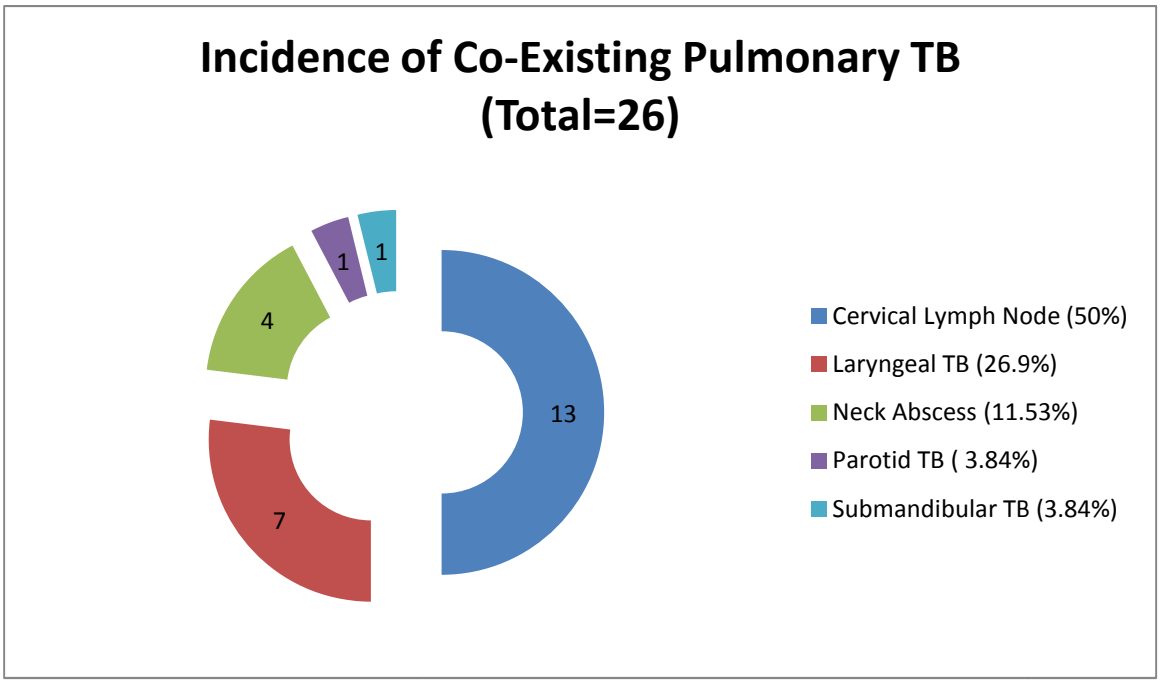
Incidence of Co-Existing Pulmonary TB
(Total=26)
13
7
4
1
1
Cervical Lymph Node (50%)
Laryngeal TB (26.9%)
Neck Abscess (11.53%)
Parotid TB (3.84%)
Submandibular TB (3.84%)

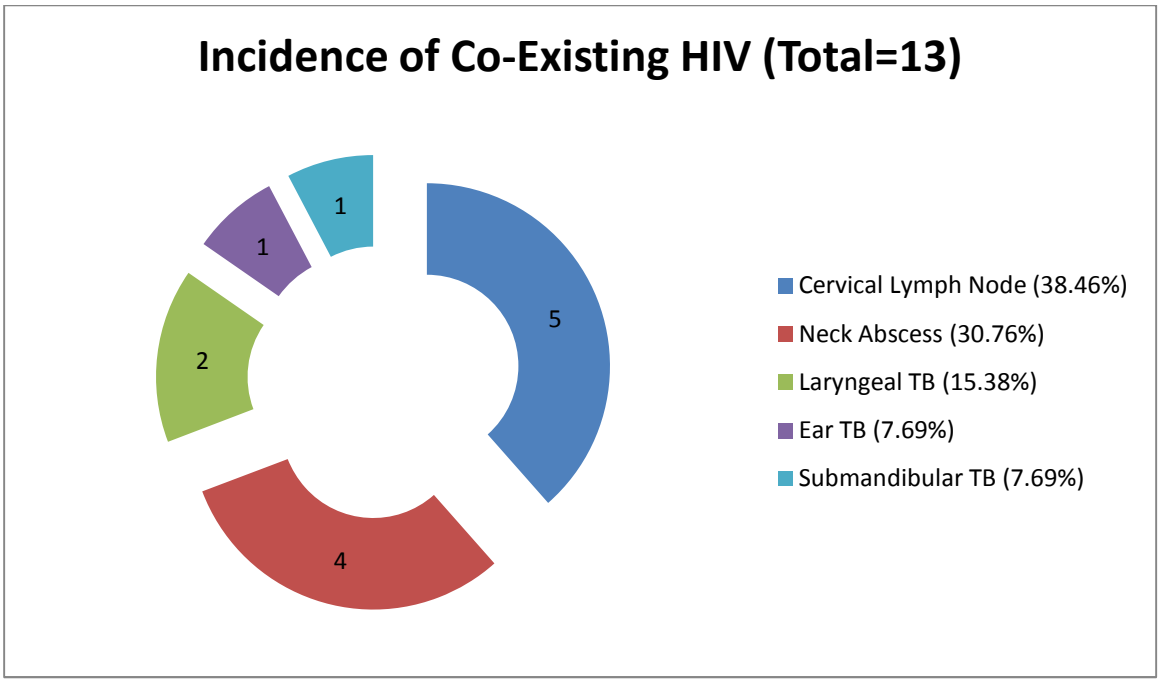

Tubercular Lymphadenitis

Out of 85 patients, 56 patients presented with tuberculous lymphadenitis (65.88%). 38 patients were males and remaining 18 were females. Among 56 patients, discrete cervical node swelling was seen in 40 patients, matting of the lymph nodes was seen in 15 patients and 1 patient presented with ulceration and discharge. Level 2 cervical lymph node was most commonly involved. Co-existing pulmonary tuberculosis was present in 13 patients as diagnosed by chest radiography and sputum examination for AFB. The incidence of coexisting pulmonary tuberculosis and TB lymphadenitis (13/56=0.232) and TB lymphadenitis alone (43/56=0.767) was statistically significant (p value<0.001). 5 patients were diagnosed as HIV positive. The incidence of coexisting HIV and TB lymphadenitis (5/56=0.089) and TB lymphadenitis alone (51/56=0.91) was statistically significant (p value<0.001). The diagnosis of tuberculous lymphadenitis was made by Fine needle aspiration cytology. However in 10 patients, non-specific lymphadenitis came in FNAC report. These patients were started on two weeks course of antibiotics. After two weeks, the patients were followed up to see the size of the node. Excision biopsy was performed when the lymph node did not respond with antibiotic therapy. Their biopsy report came as tuberculous lymphadenitis. All patients were then started on anti-tubercular therapy in DOTS clinic.

Deep Neck Space Abscess

Tubercular deep neck space abscess was seen in ten patients. All deep neck abscess underwent imaging either ultrasound, CT scan neck or neck X-ray. All patients went incision and drainage. Pus was sent for AFB staining and culture. Among these, 4 were submandibular abscess, 3 were retropharyngeal

space abscess, 1 was parapharyngeal space abscess, 1 was suprasternal abscess and 1 was submental space abscess. All patients with retropharyneal abscess had a history of spine tuberculosis. 6 were males and 4 were females. Six patients presented with neck swelling and in four patients, the primary complaints was dysphagia. 4 patients of deep neck space abscess had co-existing HIV infection, p value<0.001, significant. 4 patients of deep neck space abscess had co-existing pulmonary tuberculosis, p value<0.001, significant. All patients underwent serial aspiration of abscess followed by anti- tubercular therapy.

Figure 1. 23 year old male with Suprasternal Abscess

Figure 2. 62 year old female with Tuberculous Neck Abscess

Tubercular Laryngitis

Of the 85 cases, 8 cases (9.41%) had tubercular laryngitis. All patients were male. 7 patients had co-existing pulmonary tuberculosis. These patients presented with hoarseness of voice ranging from vocal fatigue to complete aphonia. True vocal folds were involved in 6 cases and in 2 patients, the interarytenoid region was involved. 2 patients have co-existing HIV infection. All patients were started on antitubercular therapy.

Salivary Gland Tuberculosis

Of the 85 cases, 4 cases had salivary gland tuberculosis, 3 in submandibular gland and 1 in parotid gland. All were males. They presented with neck swelling associated with pain. Ultrasonography of the neck was done for submandibular neck swelling and CT scan was done for parotid swelling. FNAC of the swelling was done which showed tubercular bacilli. All patients were started on antitubercular therapy.

Figure 3. 18 year old female with Parotid TB

Ear Tuberculosis

Of the 85 cases, 3 cases had tuberculosis of the ear. Two patients had disease in the bilateral ear and one patient had disease in the unilateral ear. Two patients were male and one was female. All patients had severe hearing loss. The tympanic membrane showed multiple perforations with pale granulation tissue. All patients had scanty ear discharge. None of the patient had facial nerve palsy. AFB staining of the discharge showed tubercle bacilli. All patients were started on anti-tubercular therapy.

Nose Tuberculosis

Two patients had nasal tuberculosis. Both patients were female. Both patients presented with bilateral nasal obstruction. There was no history of nasal discharge nor epistaxis. On examination pinkish friable mass was seen in the nasal cavity. Histopathology of the mass revealed tuberculosis. Both patients were started on anti-tubercular therapy.

Figure 4. 35 yr old male with nasal

Tongue Tuberculosis

One patient had tuberculosis of the tongue. The patient was male. The patient presented with dysphagia. On examination, a mass was seen on the base of tongue. Histopathology revealed tuberculosis. The patient was started on anti-tubercular therapy.

Thyroid Tuberculosis

One patient had tuberculosis of the thyroid gland. The patient was male. The patient presented with fluctuant swelling in the anterior neck. Ultrasound of the neck showed thyroid abscess. AFB staining of aspirated pus from neck showed tubercle bacilli. Serial aspiration of the abscess was done and the patient was started on anti-tubercular therapy.

DISCUSSION

Primarily tuberculosis is the disease of the lung. The head and neck region is a site for extrapulmonary tuberculosis, especially in the developing countries like Nepal. Because it is difficult to recognize, often neglected and have delayed treatment, tuberculosis has now become an epidemiological threat. So a sound knowledge of its manifestations in head and neck region is required for correct diagnosis and treatment.

The male to female ratio in this whole study was 2.4:1. When each group was analysed, the ratio was seen to be further higher in laryngeal tuberculosis, tuberculous cervical lymphadenitis, and salivary gland tuberculosis. These findings were in contrast to observations by K. Akbar khan et al., where cervical lymph node involvement in tuberculosis was seen more commonly in females.[5] In our opinion our findings were differing because men are more exposed to additional risk factors like smoking and alcohol in Nepal. For all patients, the mean time interval between the onset of signs and symptoms of tuberculosis and treatment was 4 weeks and it was longest in tuberculous lymphadenitis group.

Cervical lymph nodes involvement in tuberculosis was the most common findings. The lymph nodes presented as non-tender, variable sizes mass on the neck. Most of the patients had unilateral disease with only single group of lymph node involved. The most commonly involved lymph nodes was deep jugular lymph nodes. In the present study, tuberculosis infection was also seen in cervical lymph nodes of the posterior triangle. This is in contrast to the study of Antoni et al., where it was reported that no case of posterior cervical lymph node tuberculosis was seen.[6]

An effective way to diagnose tuberculous lymphadenitis was to do Fine needle aspiration cytology (FNAC). In this study FNAC could diagnose 88.24% cases. However in 10 patients, non-specific lymphadenitis came in FNAC report. These patients were started on two weeks course of antibiotics. After two weeks, the patients were followed up to see the size of the node. Excision biopsy was performed when the lymph node did not respond with antibiotic therapy. Their biopsy report came as tuberculous lymphadenitis. All patients were then started on anti-tubercular therapy in DOTS clinic. This result showed similarities to studies like Maharajan et al., that the most reliable and confirmatory method for the diagnosis of the tuberculous lymphadenopathy is excision biopsy.[7]

In our study, deep neck abscess was the second most common site for head and neck tuberculosis; but in a study done by Choudhury et al., laryngeal tuberculosis was found to be more common than deep neck abscess. [8] Deep neck space abscess can lead to complications like mediastinitis, airway obstruction, septic shock, involvement of carotid sheath, etc. Such life threatening complications have high mortality rate upto 40-50%. So early diagnosis plays a crucial role to prevent such complications.

Tuberculous retropharyngeal abscess is often secondary to tuberculosis of the cervical spine.[9] In the present study 3 patients had retropharyngeal abscess. Contrast enhanced computed tomography was done which showed central low density area with peripheral ring enhancement indicating the presence of abscess. All patients underwent intraoral drainage.

According to Agarwal and Bais, the greatest incidence of laryngeal tuberculosis is in young adults between 20 to 30 years of age; [10] however the present study shows that fourth and fifth decade of life was most commonly involved age for laryngeal tuberculosis. Similar to the study done by Yvette et al, males were more commonly involved in laryngeal tuberculosis in our study. In recumbent position, pooling of infected sputum in the posterior part of the larynx occurs. So laryngeal tuberculosis usually affects posterior part of the larynx i.e., interarytenoid area. [11] However in the present study vocal cords were

most commonly affected followed by interarytenoid area. Among the 8 cases of laryngeal tuberculosis, 7 patients had pulmonary tuberculosis (87.5%), which is statistically significant. This infers that patients with laryngeal tuberculosis usually have history of co-existing pulmonary tuberculosis as well. This is in contrast to the study by Yvette et al. Only 2 patients of laryngeal tuberculosis were HIV positive. This findings is in contrast to study by Antoni et al., which suggest that laryngeal tuberculosis is found more commonly in immunocompromised patients.[6]

The vulnerable group for salivary gland tuberculosis are people of low socioeconomic status, immunocompromised, malnourished and are found in endemic area of tuberculosis. This study shows all patients with salivary gland tuberculosis had complaints of non-tender swelling in the neck. If the suspicion of tuberculosis was there, surgery should be avoided. FNAC was done which confirmed the diagnosis. [12]

Painless ear discharge, pale granulation tissue, and profound hearing loss disproportional to symptoms were common clinical findings of aural tuberculosis. Young adults were more commonly affected.

CONCLUSION

Tuberculosis can have atypical presentations in an endemic country like Nepal and the diagnosis can be extremely challenging without pulmonary involvement. However with a strong clinical suspicion and careful systematic investigations we can avoid unnecessary delay in diagnosis and intervention.

REFERENCES

1. World Health Organization. Global Tuberculosis Control Report 2012.
2. Johnson R, Streicher EM, Louw GE, Warren RM, Van Helden PD, Victor TC. Drug resistance in M. tuberculosis. Understanding the mechanisms of drug resistance in enhancing rapid molecular detection of drug resistance in Mycobacterium tuberculosis. 2007 Dec; 7.
3. Epidemiology of Tuberculosis in Nepal. National Tuberculosis Programme-Annual Report. 2013; 4-6.
4. de Sousa RT, Briglia MFS, de Lima LCN, de Carvalho RS, Teixeira ML, Marcia˜o AHR. Frequency of Otorhinolaryngologies'manifestations in patients with pulmonary tuberculosis. Int Arch Otorhinolaryngol.2010; 14 (2):156–162.
5. Akbar Khan K, Nazir Ahmed Khan, Mohammed Maqbool. Otorhinolaryngological manifestation of tuberculosis. JK Science Journal of Medical Education and Research. 2002;4(3):115-118
6. Bruzgielewicz A, Rzepakowska A, Osuch-Wójcikewicz E, Niemczyk K, Chmielewski R. Tuberculosis of the head and neck–epidemiological and clinical presentation. Arch Med Sci 2014; 10(6): 1160–1166.
7. Maharjan M, Hirachan S, Kafle PK, Bista M, Shrestha S, Toran KC, Lakhey M. Incidence of tuberculosis in enlarged neck nodes, our experience. Kathmandu University Medical Journal. 2009; 7(1):54-8.
8. Choudhury N,Bruch G, Kothari P, Rao G, Simo R 4 years' experience of head and neck tuberculosis in a south London hospital. J R Soc Med.2005; 98: 267-269.
9. Singh J, Velankar H, Shinde D, Chordia N, Budhwani S Retropharyngeal cold abscess without Pott's spine. S Afr J Surg.2012; 50: 137-139.
10. Agarwal P, Bais AS. A clinical and videostroboscopic evaluation of laryngeal tuberculosis. J Laryngol Otol.1998; 112: 45-48.
11. Kakar PK, Singh IKK, Lahiri AK. Laryngeal tuberculosis. Ind J Otolaryngol.1971; 23: 70.

12. Lau SK, Wei WI, Hsu C, Engzell UC. Efficacy of fine needle aspiration cytology in the diagnosis of tuberculous cervical lymphadenopathy. J Laryngol Otol. 1990; 104: 24-27.