UNDER PEER REVIEW

Review papers

Clinical profile of Cysticercosis in Head and Neck

ABSTRACT

Objectives:

Review of the various clinical presentations of cysticercosis in head and neck and its diagnosis.

Materials and Methods:

Data Sources

PubMed was searched with MeSH terms Cysticercosis, Oral cavity, Tongue, Buccal, Lip Cheek, Neck, Muscle neck, Muscle head, Parotid, gland, Fnac, Larynx, Pharynx, Nose, Ear, Orbit, Ocular. The results were extensively reviewed to select relevant articles of isolated lesions of head and neck (other than brain) which present to clinician as a diagnostic dilemma.

Review methods

Articles generated were oral cavity(98), Tongue(128), Buccal(12), Lip(20), Cheek(9), Neck(58), Muscle neck(21), Muscle head(26), masseter(29), Temporalis(6), Parotid(11), gland(38), Fnac(19), Larynx(3), Pharynx(6), Nose(9), Ear(20), Orbit(59), Ocular(166). Out of these, 118 unique articles were selected, accessed, references reviewed to finally study 109 relevant articles. These have been studied for clinical presentation and how clinical problem was solved.

Implications for Practice

Cysticercosis is usually a diagnostic dilemma in head and neck, and the diagnostic tools used in such clinical scenario, are well known, easily available and dependable. These tools like fine needle aspiration cytology and sonography, however are not a part of diagnostic criteria. Their accuracy, utilisation, and vast availability suggest their role needs addition in present diagnostic criteria

Conclusion

Cysticercosis is the major neglected tropical disease. High vigilance and prompt diagnosis is required for adequate management of this eradicable disease. Various presentations in head

UNDER PEER REVIEW

and neck have been described. Diagnosis based on present criteria is not always possible. Well known investigations are helpful in early and accurate diagnosis.

KEYWORDS: *Cysticercosis; oral cavity; Tongue; Buccal; Lip; Cheek; Neck; Muscle neck; muscle head; Parotid; gland; Larynx; pharynx; Nose; Ear; Orbit; Ocular*

Clinical profile of Cysticercosis in Head and Neck

Introduction

Extra cranial cysticercosis is a well known entity with increased incidence due to global migration of disease. Further, increased awareness and health seeking behaviour brings more such presentations to physician. Its clinical presentation always has a huge differential diagnosis including neoplastic lesions. Lack of awareness about various clinical presentations increases the diagnostic dilemma. Diagnostic criteria used for management is same for neurocysticercosis and extra cranial lesions. Fine needle aspiration cytology (FNAC) and sonography are not done in neurocysticercosis, whereas they are frequently used modality in extracranial lesions. This increases management problem, as they are not a part of diagnostic criteria, yet they can give definite diagnosis.

Objective

Review the spectrum of presentations of cysticercosis and its diagnosis in head and neck.

Materials and Methods

Search made in PubMed with MeSH terms Cysticercosis, oral cavity, Tongue, Buccal, Lip Cheek, Neck, Muscle neck, muscle head, Parotid, gland, FNAC, Larynx, pharynx, Nose, Ear Orbit, Ocular of all time (Till 30-12-2014). Only articles related to humans of English literature were selected. These results were extensively reviewed to select only articles of isolated lesions of head and neck (other than brain) which present to clinician as a diagnostic dilemma. Disseminated lesions and articles with associated multiple subcutaneous nodules, known neurocysticercosis have been excluded. Also articles lacking the above details were excluded.

Results

Articles generated were Oral cavity(98), Tongue(128), Buccal(12), Lip(20), Cheek(9), Neck(58), Muscle neck(21), Muscle head(26), Masseter(29), Temporalis(6), Parotid(11), gland(38), FNAC(19), Larynx(3), Pharynx(6), Nose(9), Ear(20), Orbit(59), Ocular(166). Out of these, 118 unique articles of diagnostic dilemma were selected, accessed, references reviewed to finally study thoroughly 109 relevant articles (see Fig1,2).

UNDER PEER REVIEW

Pubmed search (English Literature-all time till December 30,2014)

MeSH Term	Articles	MeSH Term	Articles
Tongue cysticercosis	128	Oral cavity cysticercosis	98
Gland cysticercosis	38	Neck cysticercosis	58
Muscle Neck cysticercosis	21	Muscle head cysticercosis	26
Buccal cysticercosis	12	FNAC cysticercosis	19
Lip cysticercosis	20	Cheek cysticercosis	9
Masseter cysticercosis	29	Temporalis cysticercosis	6
Parotid cysticercosis	11	Larynx Pharynx cysticercosis	9
Nose cysticercosis	9	Ear cysticercosis	20
Orbit cysticercosis	59	Ocular cysticercosis	166

Fig-1

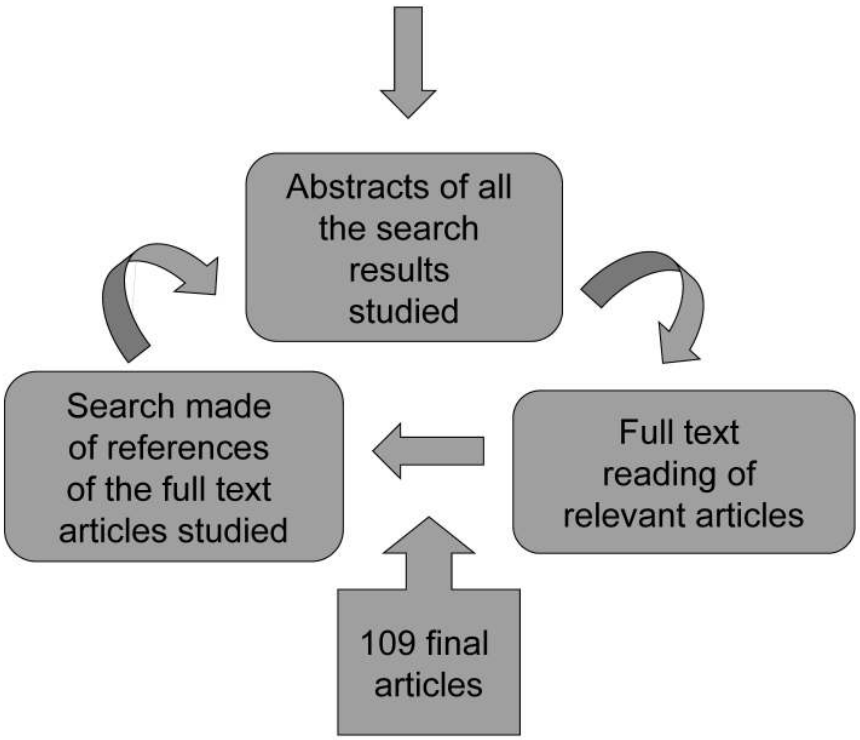

Fig-2

UNDER PEER REVIEW

Discussion

Cysticercosis is the infection caused by *Cysticercus cellulosae*, the larval stage of the cestode *Taenia solium,* the pork tapeworm. Worldwide estimates suggest that there are at least 50 million people infected with cysticercosis. Endemicity has been demonstrated in areas of pork consumption in Latin America, Bhutan, India, Nepal, Thailand, Cambodia, China, New Guinea, Vietnam, and various other parts of South East Asian region, western pacific region, non-Muslim populations of Africa, and other European countries [1].

It was declared eradicable by the International Task Force for Disease Eradication in 1993, but still remains a neglected disease and was added by World Health Organization (WHO) to the list of major neglected tropical diseases in 2010 [2]. Experience at Peru shows detection and treatment forms one of the main component for control and interruption of transmission of cysticercosis. Thus practising otolaryngologist becomes a part of eradication team by helping diagnosis and adequate treatment. Therefore awareness of spectrum of cysticercosis is important, which is not much reported in the literature.

Human beings become either definitive or intermediate host of parasite accidentally or incidentally in three ways: 1) Faecal-oral infection - ingestion of food or water contaminated by human faeces containing *Taenia Solium* eggs. 2.) Faecal-oral autoinfection - Oral ingestion of eggs via the hands of carriers of the adult worm; and 3) Internal autoinfection - by regurgitation of eggs into the stomach which occurs due to reverse peristalsis.

These eggs are partially digested in the stomach, evolve into oncospheres and subsequently penetrate the small intestinal mucosa to disseminate throughout the body via bloodstream to sites like subcutaneous tissue, striated muscles, brain and ocular tissue where they eventually form cyst [3].

Almost all age groups are affected ranging from 2 to 78 years, although less than 30 years is considered at more risk. No sex predilection is noted with equal incidence in males and females. Data analysis of minimum five years duration from endemic areas shows incidence of cysticercosis in head and neck (H&N) ranging from 24.08% - 27.2% on FNAC studies and 9.5 % - 22.23 % on Histopathological examinations (HPE) [4-7]. Most common site in H&N is neck followed by oral cavity.

Though cysticercosis is more common in non-vegetarians (pork-eaters), it is also seen in vegetarians. History of residence or travel in an endemic area is usually present. Symptoms due to neurocysticercosis or disseminated cysticercosis; if present help in diagnosis. An asymptomatic, isolated cyst may remain undetected until it enlarges, migrates and dies and produces symptoms or may be incidentally detected.

Neurocysticercosis has no specific symptom or sign; however epilepsy is the most common manifestation. Others include headache, hydrocephalus, chronic meningitis, focal neurological deficits, psychological disorders, and dementia. Extracranial cysticercosis

UNDER PEER REVIEW

commonly involves subcutaneous tissues and muscles which present as nodules clinically, usually of size few millimetres to 2 cm [7]. Extracranial presentation depends on number, size, location and host immune response [8].

Neck

Head and Neck is second most common site for cysticercosis presenting as subcutaneous nodules (Table 1). It presents as soft-firm, mobile, non-tender nodule which is clinically diagnosed as lipomas, neurofibromas, or lymphadenopathy [5].

Table 1.

Relative involvement of cysticercosis in various anatomic sites in Head & Neck

Anatomical Site	Percentage	Reference	Study Material
Scalp	**1.5**	Kala P, Khare P [4]	FNAC
Face	**7.3**	Kala P, Khare P [4]	FNAC
Oral cavity	**10**	Amatya BM et al [7]	HPE
- Tongue	41.1	Delgado-Azanero WA et al [24]	FNAC/HPE
- Labial mucosa	25.2	Delgado-Azanero WA et al [24]	FNAC/HPE
- Buccal mucosa	22.4	Delgado-Azanero WA et al [24]	FNAC/HPE
- Other sites (oral cavity)	11.2	Delgado-Azanero WA et al [24]	FNAC/HPE
Neck	**13.1**	Kala P, Khare P [4]	FNAC
Multiple sites	**3.6**	Kala P, Khare P [4]	FNAC

On FNAC identification of larvae by different workers, has made it first investigation of choice in skin nodules. It may present as single or multiple nodules increasing the list of differential diagnosis. Solitary lesions in midline or lateral part of neck are also known involving lymph nodes and muscles like sternothyroid, SCM, trapezius, mylohyoid. Involvement of sub-mental region and sub-mandibular region including sub-mandibular gland and duct is also reported [9-18].

Involvement of thyroid has been reported along with other systems, although Pradeep PV et al reported presentation as thyroglossal duct cyst which was diagnosed post operatively [19-21].

Uledi SJ reported a case presenting as long standing giant solitary pseudotumor of neck which was diagnosed as cysticercosis [22]. Jain S et al reported a racemose form of cysticercosis in neck presenting as soft cystic swelling of size 6 cm× 7 cm in the right supraclavicular region [23].

Oral Cavity and Pharynx

Muscles of oral cavity are most commonly involved than other masticatory and neck muscles. A total of 94 cases of cysticercosis involving various sites of oral cavity were found in English literature, excluding cases in which cysticercosis was suspected clinically due to involvement

UNDER PEER REVIEW

of other sites, and cases without adequate data. Previous study including other language searches showed 97 overall cases reported in literature [24].

For a clinician, cysticercosis of oral cavity is constantly a diagnostic problem because of its rarity. It is seldom a provisional diagnosis by the treating physician. When present, it frequently involves tongue, labial or buccal mucosa and floor of mouth, although gingival, retromolar trigone are also reported [25]. Intraorally, they present as painless, submucosal nodules or cystic mass, usually progressively increasing, tongue being most commonly involved. On examination a solitary, firm or cystic, non-tender, non fluctuant nodular mass is usually noted with overlying normal mucosa. Movements of tongue are usually preserved without any difficulty in eating or swallowing. Rarely, large lesions on dorsal aspect of tongue or inner aspect of lip can cause discomfort [3].

Though pain is not a frequent feature, it had been reported in secondarily infected cases. Cervical nodes are not involved in isolated cases. Mucous retention cyst is usually the first differential diagnosis, others being fibroma, leiomyoma, dermoid cyst, lipoma, a benign lesion of salivary gland or neural origin [24].

Pharynx

Mahindra S et al reported an adult female who presented with pain in throat with a swelling on left side of soft palate, without systemic involvement [14]. Sobnach S et al reported an elderly female who presented with altered speech and multiple subcutaneous nodes [26].

Muscles of Head and neck

Cysticercosis cellulosae, the encysted larval form of T. solium can remain viable in various sites for as long as 10 years in humans [27]. Living larvae escape immune recognition and do not elicit inflammation. However when the larva dies, a vigorous granulomatous inflammatory response is induced comprising predominantly of plasma cells, lymphocytes, eosinophils and macrophages [28]. Later, in long standing cases, the dead cyst is surrounded by a dense layer of fibrosis or calcification.

In muscular involvement, three distinct types of clinical manifestations have been described: the myalgic type; the mass-like, pseudo-tumour or abscess-like type; and the rare pseudo-hypertrophic type. Leakage of fluid from the cyst during death of larva induces acute inflammation resulting in local pain and myalgia. Alternatively, degeneration of the cyst may result in intermittent leakage of fluid, eliciting a chronic inflammatory response, with collection of fluid around the cyst resulting in the mass-like type, the pseudo-tumour type or the abscess-like type [29].

Masticatory muscles

A total of 17 cases have been reported till date involving masticatory muscles of which 10 has been diagnosed by radiology alone and other 5 have been supported by pathology, 2 by serology (Table 2).

Table 2. Cysticercosis of masticator muscles & its diagnosis

UNDER PEER REVIEW

S.no	Author(s)	Year	Site	Diagnosis by
1	Singh S et al	2013	Temporalis	USG + MRI
			Temporalis	USG + MRI
2	Rastogi S et al	2013	Temporalis	USG + MRI
3	Kumar V et al	2011	Temporalis	CT + ELISA
4	Sethi PK et al	2007	Temporalis	MRI + ELISA
5	Tewari S et al	2014	Masseter	USG
6	Gupta S et al	2014	Masseter	USG
7	Chaurasia RN et al	2013	Masseter	MRI + HPE
8	Ramakrishnan P et al	2012	Masseter	USG + FNAC
9	Gokarn A et al	2011	Masseter	USG + MRI
			Masseter	USG
10	Kumar BD et al	2011	Masseter	USG + FNAC
11	Naik D et al	2011	Masseter	USG
12	Mittal A et al	2008	Masseter	USG
13	Sidhu R et al	2002	Masseter	USG + FNAC
14	Reddi SP et al	2001	Masseter	CT + HPE
15	Virk et al	2015	Pterygoid	MRI

Masseter: Solitary involvement of masseter muscle presents as bimanually palpable non-tender, nodular, firm, mobile, gradually increasing swelling. Facial symmetry is undisturbed unless swelling becomes large. It may present as acute inflammation with tender swelling [30]. It is usually diagnosed as inflammatory lesion of salivary gland or salivary neoplasm, with differentials including primary and metastatic tumours of masseter muscle, sarcoidosis, lipomas, solitary neurogenic tumours and vascular lesions. In fact we had a case with clinically palpable nodule in parotid region diagnosed as cysticercosis on FNAC but turned out as masseter lesion on radiological work up. Therefore we suggest compulsory radiological work up in cysticercosis nodules for definite anatomical site [31-33]. Gupta S et al reported a rare presentation of masseter involvement with generalised on and off urticaria [34].

Temporalis: Isolated involvement of temporalis usually presents as painful tender swelling with associated headache. Pain may aggravate on chewing and or application of pressure. History of gradually increasing chronic swelling is usually elicited [35-37].

Pterygoid: Virk et al [38] noted isolated involvement of pterygoid muscle, which presented with trismus due to pain.

Though patients of cysticercosis of masticatory and other deep seated muscles are not aware of lesion, asymptomatic presentation of a muscle swelling, usually masseter is noted due to visibility, increasing health awareness and health seeking behaviour of people.

Salivary Gland

UNDER PEER REVIEW

Signs and symptoms of cysticercosis depend on the site of involvement and the stage of evolution. However, the most common presentation is swelling at the affected site. Solitary parotid lesion may present as slowly growing mass soft-firm in consistency in the pre-auricular region and cheek, which can also be due to masseter involvement. It is commonly misdiagnosed as soft-tissue tumor. When symptomatic, differential diagnosis includes acute parotitis, parotid abscess, parotid sialadenitis, subcutaneous tissue abscess, pyomyositis or lymphadenitis [32]. Submandibular gland and lymph node when involved can present as painful swelling or may be diagnosed accidentally. Swelling in this area due to muscle involvement may be misdiagnosed, again citing the importance of radiological investigations [16].

Ear

A person presenting with sensory neural type hearing loss with headache may have cysticercosis involving cerebellopontine angle [39]. Post aural gradually increasing swelling close to mastoid tip has been reported without any other symptoms [14].

Nose and Paranasal sinuses

It can present as chronic swelling over nasal dorsum, without any symptoms which may be diagnosed as Nasal dermoid [40]. Though many cases have been reported for isolated eyelid involvement presenting as swelling, these can be due to involvement of supra-orbital frontal bone [41].

Larynx

Only two cases reported with presentation of progressive hoarseness with cystic mass bulging from false and true vocal cords which were diagnosed postoperatively as cysticercosis [42,43].

Orbit

Ocular and adnexal cysticercosis represents 13-46% of systemic disease with prevalence of 0.10%. Unilateral involvement with predilection for left eye has been observed more commonly [44,45]. Spectrum of clinical presentations depend on the site of lodgement, size of cyst, host immune status and level of inflammatory reaction. Primary site of involvement varies with intraocular being predominant in western countries, whereas extraocular more common in Indian population [45]. Most favoured sites for intraocular cysticercosis are subretinal and vitreous cavity where they gain access through posterior ciliary arteries while orbital cysticercosis commonly shows subconjunctival space and extraocular muscle involvement [44,45]. Various clinical symptoms of ocular cysticercosis can be either due to inflammatory reaction evoked by viable cyst or due to compression of surrounding structures by mature cyst. Most commonly described are blurring of vision, restriction of ocular motility, proptosis, diplopia, acquired ptosis, strabismus, subconjunctival cyst, eyelid erythema and

UNDER PEER REVIEW

nodule [44,45]. There can be direct visualization of clinically evident cyst in anterior chamber and vitreous cavity or ultrasonographic evidence of characteristic appearance of the cyst [47]. In earlier stages in intraocular disease, signs of severe uveitis, retinal edema, haemorrhage, retinal & vitreous proliferation, exudative retinal detachment are present while retinal necrosis and atrophy are noted in later stages [44-47]. Unusual presentations of cysticercosis described in the literature are pupillary block glaucoma, endogenous endophthalmitis, orbital cellulitis, pseudotumour, subperiosteal cyst, atypical optic neuritis involving optic disc and optic canal, obstruction of lacrimal gland as well as lacrimal canaliculi and masquerading as retinoblastoma or optic nerve glioma [48-57]. Bilateral multifocal involvement or brown syndrome with bilateral superior oblique muscle involvement has also been described in literature [58-59].

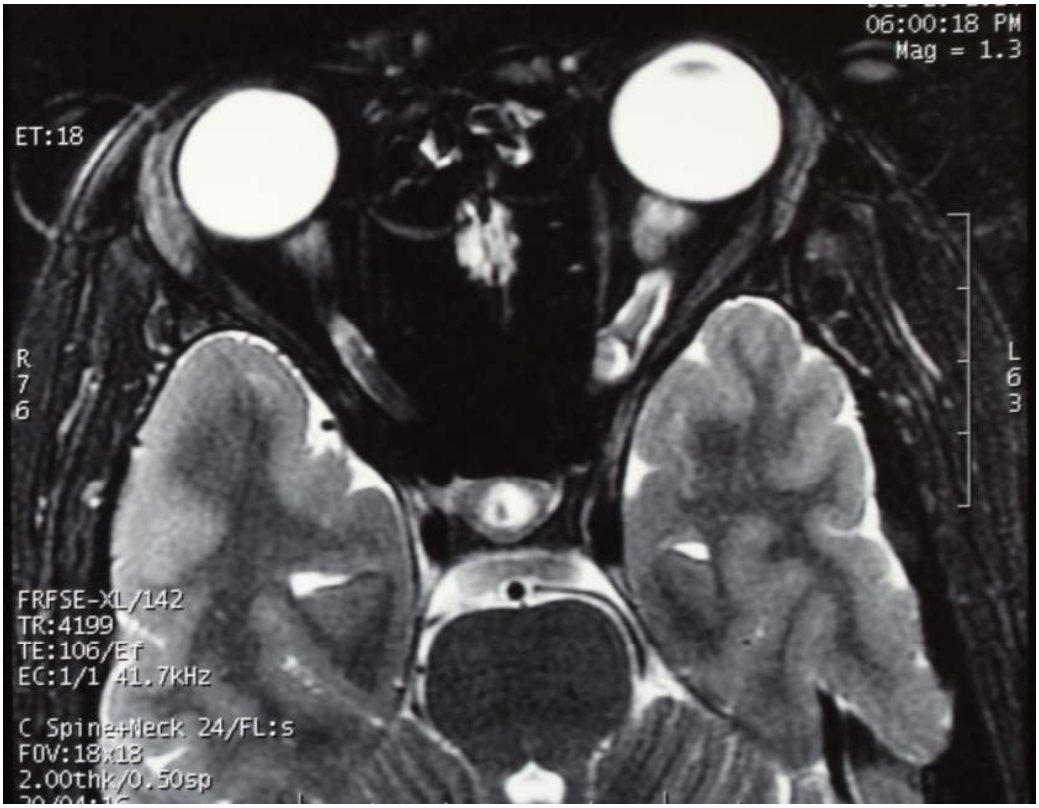

Fig3 Cysticercosis optic canal compressing optic nerve in an young adult, presented with decreased vision, diagnosed radiologically, managed medically and optic nerve decompression

An increased awareness of the typical and atypical presentations coupled with high index of clinical suspicion, may help in early diagnosis. Early presentation to the ophthalmologist and early intervention with extremely effective treatment while inflammation is relatively mild leads to resolution in most patients and more favourable visual outcome.

Diagnosis

UNDER PEER REVIEW

Cysticercosis is rarely in the list of differential diagnosis due to its diverse non-specific presentations. The benign behaviour of such lesions seldom present to clinician unless lesions increases in size or cause symptoms due to various reasons. It may also be detected accidentally while investigating for other purpose.

Del brutto et al gave criteria for diagnosis of Human cysticercosis (HC) to aid in its diagnosis in endemic areas, where modern diagnostic techniques are infrequently available [60]. They suggested four degrees of criteria based on clinical, radiological, immunological and epidemiological data, with three diagnostic possibilities a) definitive b) probable c) possible.

Sonography

Sonography is initial modality of choice for soft tissue swelling, more so in resource limited countries. HC is being increasingly diagnosed reliably with easily available high frequency ultrasonography. This is based on demonstration of sonographic features especially scolex in the lesion, sensitivity and specificity of which depends on expertise, thorough scanning, and stage of disease. On sonography four appearances have been described [29]. These include (a)cysticercus cyst with surrounding inflammatory mass, (b) an irregular cyst with very minimal fluid on one side, (c) a large collection of exudative fluid, with the typical cysticercus cyst containing the scolex, (d) calcified cysticercosis.

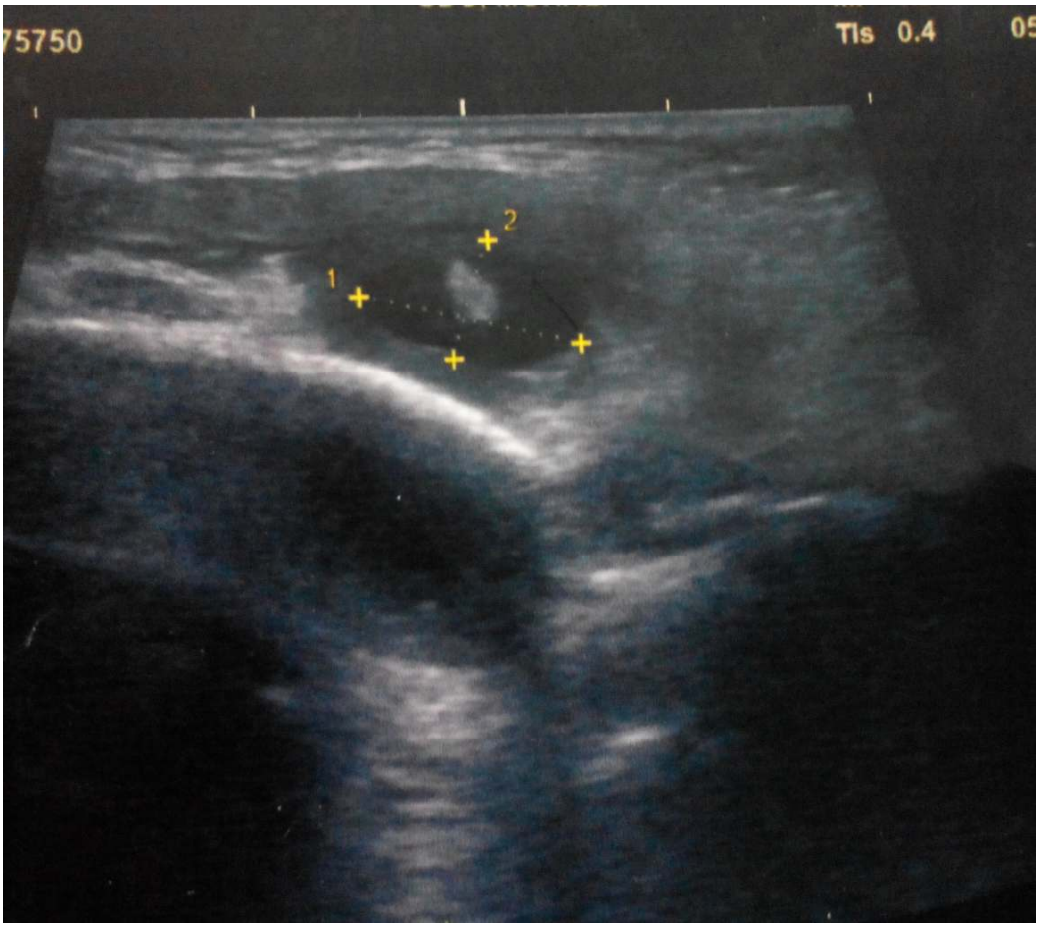

UNDER PEER REVIEW

Fig4 Cysticercosis-right masseter in a child, presented with cheek pain and tender swelling, diagnosed sonographically, managed medically [63]

FNAC

FNAC is diagnosis of choice for subcutaneous nodules, where there are many differential diagnoses. Considering series of more than hundred cases arbitrarily, using FNAC for definitive diagnosis has shown sensitivity from 46.4% to 94.2% [4,5]. Rest cases were diagnosed as suspicious of parasitic infestation, which on histopathological examination has very high sensitivity though never 100%. The reason for this may be due to variations in host-body reactions and stage of evolution of cyst. Various spectrums have been described though FNAC or biopsy require visualisation of the detached hooklets, scolex, and fragments of the bladder wall of *Cysticercosis cellulosae* [5].

Serology

Hematological profile often remains unaltered though eosinophilia may be noted when there is leakage of parasitic antigen into surrounding tissues. Using serological methods sensitivity of antibody testing tends to be high for cases with multiple cysts (94%) but lower for patients with single or calcified cysts (28%) giving false negative result. Serology may show false positive result due to prior exposure of *T. solium* antigens. Taeniasis can be diagnosed with examination of stool samples taken on several different days, as egg release in the stool may be variable. Sensitivity for detection can be improved by various concentration techniques. Recently, detection of genus specific coproantigens in the stool has improved diagnosis of *Taenia* infection with a specificity of up to 95% to 98% [61].

Radiology

If the cyst has calcified, routine imaging (X-ray) can detect it. For soft tissue involvement, plain films reveal multiple calcified “puffed-rice” lesions [28]. Modalities like CT/MRI are increasingly being used for diagnosis with demonstration of scolex. Role of CT in neurocysticercosis is well known and characteristic or suggestive features on MRI are absolute or major criteria of diagnosis respectively on Del Bretto et al list. Starry sky appearance on MRI is known in disseminated cysticercosis. According to Jankharia BG et al soft tissue cysticercosis on MRI, usually displays low signal intensity on T1-weighted images and high signal intensity on T2-weighted images [62]. Scolex with in cyst with peripheral rim enhancement may be seen with a peculiar orientation of cyst in direction of muscle fibres.

UNDER PEER REVIEW

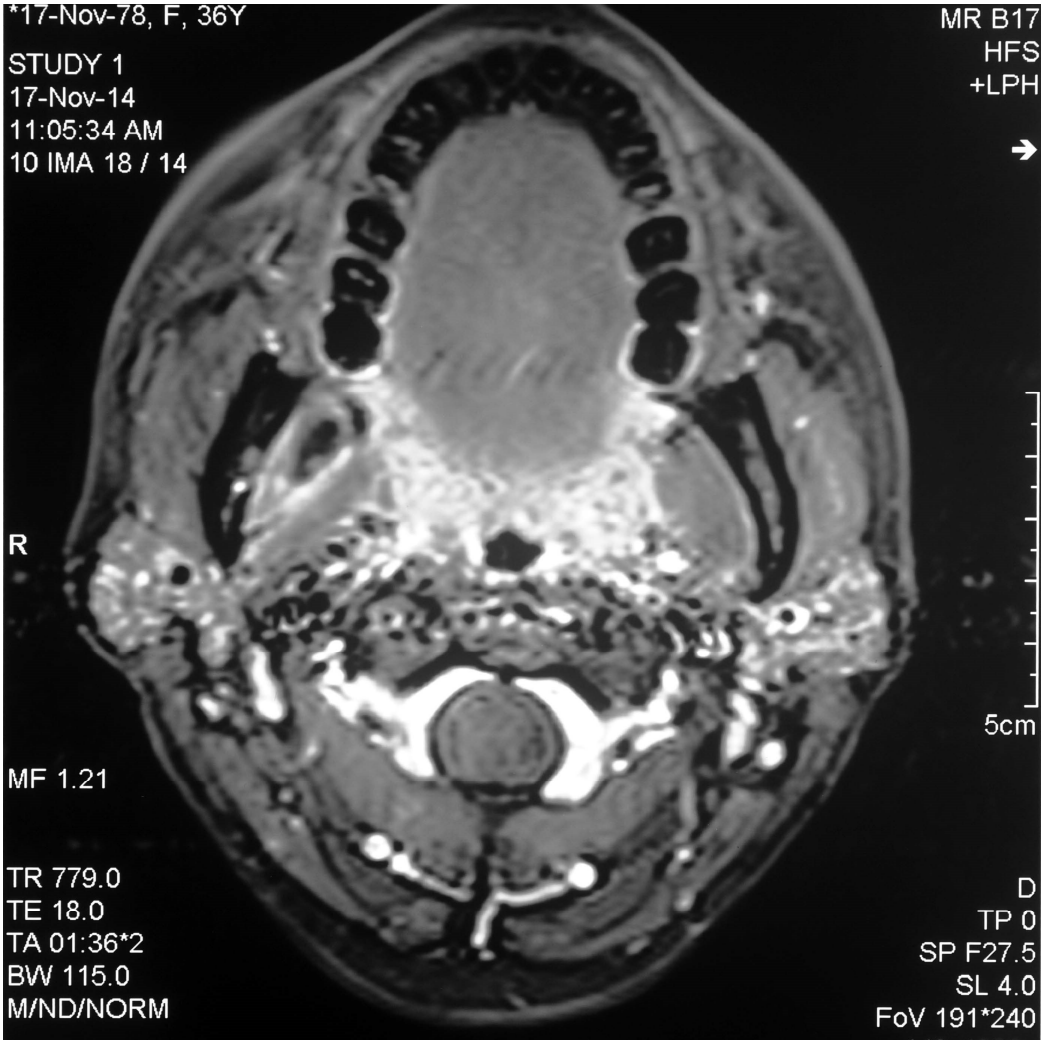

Fig5 Cysticercosis of right pterygoid muscle in an adult female, presented with trismus, diagnosed radiologically, managed medically [38]

Based on above observations of various modalities, increasing role of sonography and FNAC is suggested, especially in head and neck, complying with trends observed in recent literature [bansal 63]. Most important change is increasing experience of pathologists and radiologists in accurate diagnosis of this entity. Thus, the change in present diagnostic criteria of human cysticercosis is required considering the role of FNAC and sonography with ease of availability, low cost, accuracy and early diagnosis.

Management

Surgical excision is the treatment of choice in extracranial cysticercosis including intraocular lesions except intraorbital cysticercosis where medical treatment is preferred [43-45]. Excision clears the disease in isolated lesions and also provides specimen for definite diagnosis. On contrary, presence of intraocular cysticercosis is a contraindication for systemic antihelmenthic drugs as intraocular death of worm causes intense blinding panuveitis [64]. Medical management is given in inaccessible symptomatic lesions, with corticosteroids and

UNDER PEER REVIEW

antiparasitic therapy, though role of antihelminthic drugs is not proven in single extracranial cysticercosis [44]. Few authors even suggest wait and watch for asymptomatic lesions, however treatment is advised in insidious, silent but morbid course of disease. For cysticercosis, Praziquantel is given at 50mg/kg/day for 15 days and Albendazole at dose of 15mg/kg body weight for one month [2]. WHO recommends praziquantel (10mg/kg body weight orally) and niclosamide (2g orally) for human taeniasis with dexamethasone 0.1mg/kg/day for associated inflammation [1]. Ruling out neurocysticercosis is must, as antihelminthics can exacerbate seizures in silent lesions (known risk with praziquantel). Prognosis of head and neck soft tissue cysticercosis is excellent with no recurrence, in contrast to other cerebral, ocular, cardiac sites.

Implications for practice

Cysticercosis is usually a diagnostic dilemma in head and neck. High vigilance is required for its diagnosis and adequate management, to eradicate this neglected global disease. Sonography and FNAC are easily available, accurate, affordable, and solves clinical scenario in a better way. They are to be studied further, to define sensitivity and specificity, considering their role in diagnosis.

Conclusion

Cysticercosis, aptly said as modern day plague, is the major neglected tropical disease [65]. Soft tissue cysticercosis is known to be present in 54% of infected people, however neurocysticercosis presents more to the clinician [66]. High suspicion and prompt diagnosis is required for adequate management of this eradicable disease. Various presentations have been described and changes in diagnostic criteria have been suggested with reliable and easily available methods, which can even be used in resource limited endemic areas.

Ethical approval

For this type of study, formal consent is not required.

Bibliography

1. Report of the WHO Expert Consultation on Foodborne Trematode Infections and Taeniasis/Cysticercosis. Vientiane, Lao People's Democratic Republic 12-16 October 2009 Available at : http://apps.who.int/iris/bitstream/10665/75209/1/WHO_HTM_NTD_PCT_2011.3_eng.pdf. Accessed on 30.11.2014.

2. Taeniasis/Cysticercosis, Fact Sheets, Media Centre,WHO.Available at : http://www.who.int/mediacentre/factsheets/fs376/en/. Accessed on 30.11.2014

3. Baily, Guy; Garcia, Hector H. *Mansons's Tropical Diseases.* Published January 2, 2014. Pages 820-832.e1. © 2014

UNDER PEER REVIEW

4. Kala P, Khare P. Fine-needle aspiration cytology as a diagnostic modality for cysticercosis: A clinicocytological study of 137 cases. *Journal of cytology / Indian Academy of Cytologists.* 2014;31(2):68-72.

5. Handa U, Garg S, Mohan H. Fine needle aspiration in the diagnosis of subcutaneous cysticercosis. *Diagnostic cytopathology.* 2008;36(3):183-7.

6. Sirikulchayanonta V, Sirikulchayanonta C, Leopairat J. A descriptive study of 36 cases of solitary soft tissue cysticercosis at Ramathibodi Hospital from surgical specimens during 1990-2006. *The Southeast Asian journal of tropical medicine and public health*. 2007;38(3):420-3.

7. Amatya BM, Kimula Y. Cysticercosis in Nepal: a histopathologic study of sixty-two cases. *The American journal of surgical pathology*. 1999;23(10):1276-9.

8. Richa, Ray JG, Pattanayak S, Vibha. An asymptomatic tongue nodule. *Contemporary clinical dentistry*. 2012;3(4):464-6.

9. Elhence P, Bansal R, Sharma S, Bharat V. Cysticercosis presenting as cervical lymphadenopathy: a rare presentation in two cases with review of literature. *Nigerian journal of clinical practice*. 2012;15(3):361-3.

10. Kinnman J, Chi CH, Park JH. Cysticercosis in otolaryngology. *Archives of otolaryngology.* 1976;102(3):144-7.

11. Sharma R, Gautam P, Kumar S, Elhence P, Bansal R, Gupta G. Isolated cysticercosis cellulosae of sternocleidomastoid muscle: a case report with review of literature. *Indian journal of otolaryngology and head and neck surgery* : official publication of the Association of Otolaryngologists of India. 2011;63(Suppl 1):127-30.

12. Brown ST, Brown AE, Filippa DA, Coit D, Armstrong D. Extraneural cysticercosis presenting as a tumor in a seronegative patient. *Clinical infectious diseases* : an official publication of the Infectious Diseases Society of America. 1992;14(1):53-5.

13. Ramraje S, Bhatia V, Goel A. Solitary intramuscular cysticercosis-A report of two cases. *The Australasian medical journal*. 2011;4(1):58-60.

14. Mahindra S, Daljit R, Sohail MA, Maheshwari HB. Cysticercosis in the practice of otolaryngology. *Acta oto-laryngologica*. 1981;92(1-2):189-91.

15. Sodhi PK, Ratan SK. Submandibular lymph node enlargement due to cysticercosis infestation. *Scandinavian journal of infectious diseases*. 2004;36(3):227-9.

16. Virk RS, Panda N, Ghosh S. Mylohyoid cysticercosis: a rare submandibular mass. *Ear, nose, & throat journal*. 2009;88(11):1218-20.

17. Mahajan D, Khurana N, Setia N. Coexistence of salivary gland cysticercosis with squamous cell carcinoma of the mandible. *Oral surgery, oral medicine, oral pathology, oral radiology, and endodontics.* 2007;103(3):e47-50.

18. Sinha V, Raizada RM, Jain SK, Chaturvedi VN. Cysticercosis of submandibular duct. *Indian journal of otolaryngology and head and neck surgery* : official publication of the Association of Otolaryngologists of India. 1999;51(4):51-2.

UNDER PEER REVIEW

19. Leelachaikul, Chuahirun S. Cysticercosis of the thyroid gland in severe cerebral cysticercosis : report of a case. *Journal of the Medical Association of Thailand*. 1977;60(8):405-10.

20. Gupta S, Sodhani P. Clinically unsuspected thyroid involvement in cysticercosis: a case report. *Acta cytologica*. 2010;54(5 Suppl):853-6.

21. Pradeep PV, Shanthi V, Reddy KK, Mohan KV. Cysticercosis in the thyroglossal duct cyst: rare site for a common problem. *Pathology*. 2014;46(4):365-6.

22. Uledi SJ. A rare gigantic solitary cysticercosis pseudotumour of the neck. *Journal of surgical case reports*. 2010;2010(9):5.

23. Jain S, Kumar S, Joshi D, Kaushal A. Racemose cysticercosis presenting as cystic neck swelling. *Tropical parasitology*. 2012;2(1):55-7.

24. Delgado-Azanero WA, Mosqueda-Taylor A, Carlos-Bregni R, Del Muro-Delgado R, Diaz-Franco MA, Contreras-Vidaurre E. Oral cysticercosis: a collaborative study of 16 cases. *Oral surgery, oral medicine, oral pathology, oral radiology, and endodontics.* 2007;103(4):528-33.

25. Mazhari NJ, Kumar N, Jain S. Cysticercosis of the oral mucosa: aspiration cytologic diagnosis. *Journal of oral pathology & medicine* : official publication of the International Association of Oral Pathologists and the American Academy of Oral Pathology. 2001;30(3):187-9.

26. Sobnach S, Khosa SA, Pather S, Longhurst S, Kahn D, Raubenheimer PJ. First case report of pharyngeal cysticercosis. *Transactions of the Royal Society of Tropical Medicine and Hygiene.* 2009;103(2):206-8.

27. Despommier DD. Tapeworm infection--the long and the short of it. *The New England journal of medicine*. 1992;327(10):727-8.

28. Agrawal R. Soft tissue cysticercosis: study of 21 cases. *Journal of clinical and diagnostic research* : *JCDR*. 2012;6(10):1669-71.

29. Vijayaraghavan SB. Sonographic appearances in cysticercosis. *Journal of ultrasound in medicine* : official journal of the American Institute of Ultrasound in Medicine. 2004;23(3):423-7.

30. Mittal A, Das D, Iyer N, Nagaraj J, Gupta M. Masseter cysticercosis - a rare case diagnosed on ultrasound. *Dento maxillo facial radiology*. 2008;37(2):113-6.

31. Goyal P, Ghosh S, Sehgal S, Mittal D, Singh S. Solitary Cysticercosis of Parotid Gland Diagnosed on FNAC. *APSP journal of case reports*. 2014;5(1):11.

32. Tewari S, Singh S, Jaiswal V, Mishra AK. Myoparasitism mimicking parotid swelling: a rare presentation of cysticercosis. *BMJ case reports*. 2014;2014.

33. Natarajan A, Rameshkumar K, D'Souza RE. Cysticercosis masquerading as a salivary gland neoplasm. *Tropical doctor*. 2002;32(2):120-1.

34. Gupta S, Gupta S, Mittal A, Mahendra A, Aggarwal A, Batra R, et al. A rare manifestation of cysticercosis infestation. *Acta medica Indonesiana*. 2014;46(1):54-7.

UNDER PEER REVIEW

35. Sethi PK, Sethi NK, Torgovnick J, Arsura E. Cysticercosis of temporalis muscle: an unusual cause of temporal headaches. A case report. *The journal of headache and pain*. 2007;8(5):315-6.

36. Singh S, Sreenivasan V, Garg K, Wazir ND, Rajput JS, Sandhu Virk P. Cysticercosis involving muscle of mastication: a review and report of two cases. *Case reports in dentistry*. 2013;2013:814126.

37. Kumar V, Gulati A, Mehra B. Cysticercosis of the temporalis muscle causing temporal headache in a pregnant woman. *International journal of gynaecology and obstetrics*: the official organ of the International Federation of Gynaecology and Obstetrics. 2011;114(1):79.

38. Virk RS, Rathi A, Lokesh P, Gupta A, Bansal S. Cysticercosis of Lateral Pterygoid muscle- A case report. Ahead of print. Journal of Post graduate Medicine Education and Research

39. Song L, Guo F, Ma S, Song Z, Wu L, Sun H. A rare presentation of intracranial cysticercosis involving the cerebellopontine angle. *Journal of clinical neuroscience* : official journal of the Neurosurgical Society of Australasia. 2013;20(6):892-4.

40. Kuruvilla G, Job A, Thomas M. A rare case of nasal cysticercosis mimicking a nasal dermoid. *The Journal of laryngology and otology*. 2007;121(1):94-5.

41. Kaur A, Chaurasia S, Agrawal A. Cysticercosis of the bony orbit--a rare entity. *Orbit*. 2007;26(2):141-3.

42. Tami TA, Parker GS, Wong RT. Laryngeal cysticercosis. *Otolaryngology--head and neck surgery :* official journal of American Academy of Otolaryngology-Head and Neck Surgery. 1987;96(3):289-91.

43. Ghosh RN, Dandapath A, Maji PK, Dasgupta A, De G. Cysticercosis of larynx. *Indian journal of otolaryngology and head and neck surgery* : official publication of the Association of Otolaryngologists of India. 1997;49(3):282-3.

44. Ziaei M, Elgohary M, Bremner FD. Orbital cysticercosis, case report and review. *Orbit*. 2011 Oct;30(5):230-5.

45. Wender JD, Rathinam SR, Shaw RE, Cunningham ET Jr. Intraocular cysticercosis: case series and comprehensive review of the literature. *Ocul Immunol Inflamm*. 2011 Aug;19(4):240-5.

46. Rath S, Honavar SG, Naik M, Anand R, Agarwal B, Krishnaiah S, Sekhar GC. Orbital cysticercosis: clinical manifestations, diagnosis, management, and outcome. *Ophthalmology*. 2010 Mar;117(3):600-5, 605.e1.

47. Sekhar GC, Honavar SG. Myocysticercosis: Experience with imaging and therapy. *Ophthalmology* 1999; 106:2336– 2340.

48. Chandra A, Singh MK, Singh VP, Rai AK, Chakraborty S, Maurya OP. A live cysticercosis in anterior chamber leading to glaucoma secondary to pupilary block. *J Glaucoma*. 2007 Mar;16(2):271-3.

UNDER PEER REVIEW

49. Mulla MA, Banker AS, Rishi E, Biswas J. Degenerated intravitreal cysticercus cyst masquerading as endogenous endophthalmitis. *Ocul Immunol Inflamm*. 2012 Oct;20(5):378-80.

50. Kohli V, Gaur S, Deen M, Engel M, Shah K. Orbital cysticercosis presenting as recurrent periorbital cellulitis in a four-year-old child. *Pediatr Infect Dis J*. 2010 May;29(5):481.

51. Chaudhary V, Bano S, Parmar PR, Bidasaria N, Bajaj S. Extraocular muscle cysticercosis mimicking as pseudotumor orbit: a clinical dilemma. *Neurol India*. 2013 Nov-Dec;61(6):665-7.

52. Singh U, Gupta P, Bansal R. Unusual presentation of orbital cysticercosis in subperiosteal space. *J Pediatr Ophthalmol Strabismus*. 2008 Nov-Dec;45(6):379-80.

53. Tandon R, Sihota R, Dada T, Verma L. Optic neuritis following albendazole therapy for orbital cysticercosis. *Aust N Z J Ophthalmol*. 1998 Nov;26(4):339-41.

54. Madan VS, Dhamija RM, Gill HS, Boparai MS, Souza PD, Sanchete PC, Bhardwaj JR. Optic nerve cysticercosis: a case report. *J Neurol Neurosurg Psychiatry*. 1991 May;54(5):470-1.

55. Kaur A, Agrawal A, Agrawal PK, Goel MM. Lacrimal canalicular obstruction by cysticercus cellulosae. *Orbit*. 2006 Jun;25(2):163-5.

56. Agarwal B, Vemuganti GK, Honavar SG. Intraocular cysticercosis simulating retinoblastoma in a 5-year-old child. *Eye* (Lond). 2003 Apr;17(3):447-9.

57. Goyal JL, Das S, Kumar S, Chauhan D, Baheti U, Sangit V. Retrobulbar cysticercosis masquerading as optic nerve glioma. *Orbit*. 2007 Mar;26(1):61-3.

58. Topilow HW, Yimoyines DJ, Freeman HM, Young GA, Addison R. Bilateral multifocal intraocular cysticercosis. *Ophthalmology*. 1981 Nov;88(11):1166-72.

59. Pandey PK, Chaudhuri Z, Bhatia A. Extraocular muscle cysticercosis presenting as Brown syndrome. *Am J Ophthalmol*. 2001 Apr;131(4):526-7.

60. Del Brutto OH. Neurocysticercosis: A Review. *The Scientific World Journal*, 2012. 2012: p. 8.

61. King, Charles H.; Fairley, Jessica K. *Mandell, Douglas, and Bennett's Principles and Practice of Infectious Diseases*. Published January2,2015.Pages 3227-3236.e.1. ©2015.

62. Jankharia BG, Chavhan GB, Krishnan P, Jankharia B. MRI and ultrasound in solitary muscular and soft tissue cysticercosis. *Skeletal radiology*. 2005;34(11):722-6.

63. Cysticercosis - Is it a pathological or Radiological diagnosis. International Journal of Tropical Disease and Health. 11(4): 1-4, 2016; Article no.IJTDH.20362

UNDER PEER REVIEW

64. Singhi P. Neurocysticercosis. *Therapeutic Advances in Neurological Disorders.* 2011;4(2):67-81.

65. Brown WJ, Voge M. Cysticercosis. A modern day plague. *Pediatr Clin North Am*. 1985 Aug;32(4):953-69.

66. Dixon HBF, Lipscomb FM. Cysticercosis: An Analysis and Follow-up of 450 Cases. *Proceedings of the Royal Society of Medicine* 1962;55(3):242.