Lesion aspirate isolation, culture, diagnosis and Molecular identification of Cutaneous leishmaniasis in district Kohat, Khyber Pakhtunkhwa, Pakistan

Abstract

Leishmaniasis is a poverty-associated zoonotic tropical disease transmitted by the bite of infected female sand fly. Diagnosis and recognition of clinical manifestation and morphological features of *Leishmania* parasites involved in the spread of disease is mandatory to design appropriate strategies for ecologic control and preventive plans. Although clinical investigations are necessary to estimate and help define about epidemiological findings but they are not sufficient for identification and characterization of the particular parasite, as the transmission of the disease especially in endemic areas is manifested by various *Leishmania* species. Samples from 41 patients of both gender (22 males and 19 females) with variable age groups (median age was 27) irrespective of location and immune status suggested with suspected cutaneous leishmaniais lesions fulfilling the inclusion criteria were enrolled and examined. Aspirate smears and skin scrapings collected from the active edge of the lesion were stained with Giemsa and confirmed *via* microscopy using fine needle aspirate biopsy and/or lancet. Productivity and potential isolates of *Leishmania* samples inoculated in Biphasic Novy-MacNeal- Nicolle (NNN) and cultured in Monophasic Roswell Park Memorial Institute (RPMI) 1640 media were used in evaluating the efficiency for each sample under study. In order to identify *Leishmania* specie a definite molecular technique, Polymerase Chain Reaction (PCR) product analyzed by gel electrophoresis using 2% agarose was adopted. Genomic DNA was extracted using proteinase k and amplified by specific primers of kinetoplast DNA. Gel staining was performed using ethidium bromide. The presence of 186bp fragment indicated *L. tropica* confirming it as the prevalent species in Khyber Pakhtunkhwa, Pakistan, which has immense importance from an epidemiological, transmission and treatment point of view. PCR is a very reliable and sensitive method to detect *Leishmania* DNA as compared to Giemsa and culture techniques.

Keywords: Cutaneous Leishmaniasis, Giemsa stain, Microscopy, Polymerase chain reaction

Introduction

Leishmaniasis is caused by single cellular, heamoflagellate protozoan parasite of the genus *Leishmania* and family *Trypanosomatidae* (order kinetoplastida). Only 60 of about 600 species are vectors for *Leishmania*, around which 20 *Leishmania* species are described as human pathogens (Vannier *et al*., 2002). Leishmaniasis depends on the *Leishmania* spp. involved, site of bite, number of bites, type of sandfly, genus of parasite and acute predisposition of the host's genetic potential (Markle and Makhoul, 2004). Worldwide prevalence is about 12 million, endemic in 90 tropical and subtropical countries threatening approximately 350 million people each year approximately (Desjeux, 2001).

Categorically, leishmaniasis is classified into three different clinical forms: cutaneous, mucocutaneous and visceral leishmaniasis (Hamid *et al*., 2012). Cutaneous leishmaniasis (CL) represents up to 75% of all the new cases with 1-1.5 million annual incidences commonly caused by *Leishmania major, L. tropica, L. aethiopica* and *L. braziliensis* particularly in sub-continent and middle east (Hailu *et al*., 2006). CL is characterized by a small red papule which becomes darker and turn into ulcer with raised edges after several weeks. Ulcers can be moist and exude pus with a crusted scab; sores usually appear on exposed body parts of the skin, especially on the face and extremities (Markle and Makhoul, 2004). Localized cutaneous leishmaniasis is characterized by lesions on face, nose, forehead and lower limbs that usually heal naturally. Another type of CL is the diffuse cutaneous leishmaniasis that produces symptoms like nodules, plates or lumps on the face, arms and legs and relapse after treatment (Davies *et al.*, 2003). The currently used parasitological diagnostic routine procedures involved the direct examination of amastigotes using stained smears via microscopic examination obtained from tissue lesions are based on clinical signs and symptoms and history of exposure to the disease (Culha *et al*., 2006). Morphologically 2 forms of the parasite; (1) the amastigote form responsible for disease pathogenicity is found intracellularly in the vertebrate hosts including humans, and (2) the promastigote form, found predominately in the insect vector (Mohammed, 2008). Studies using axenically grown amastigotes are becoming an acceptable alternative as they combine the advantages of being rapidly screened using the clinically relevant stage of the parasitic life cycle (Romero *et al*., 2009).

Pakistan is an important geographical location for the disease as it is located and surrounded by nations like Afghanistan, India and Iran where different forms of leishmaniasis

have been endemic for many years. Most identification studies in Pakistan on *Leishmania* spp. have been carried out in Baluchistan, Sindh and Azad Kashmir. However in KPK region very limited work has been done. Keeping in view the importance of disease severity and negligence of symptomatic approach in district Kohat, KPK region, the present study was taken into consideration to identify the causative agent of cutaneous leishmaniasis aiming to take attention on this serious health problem.

Materials and Methods

All experimental procedures involving human tissue samples were obtained and conducted in accordance with the Code of ethics and Practice for Scientific purposes as approved by the Human Research Ethics Committee Centre guidelines for biomedical research centre. All chemicals, reagents, solvents purchased were of high-performance liquid chromatography (HPLC) analytical grade and maintained at given temperature and pH at given concentrations for reaction mixture as indicated by suppliers without further purification.

Patient's history and study site

A descriptive, cross-sectional, prospective study based on patient's consent and history of both gender of age groups (11 years to 43 years) irrespective of location, immune and financial status were approached to participate and screened for eligibility criteria. Altogether, 41 clinically suspected patients met the reference standard for cutaneous leishmaniasis were referred to the Molecular Parasitology and Virology Research Laboratory, Department of Zoology, Kohat University of Science and Technology, Kohat where investigations were carried out to diagnose and identify the causative agent of the disease after the collection of sample specimen using protocol as follow.

Isolation of sample Lesion from Leishmania patients

Aspirate lesions of *Leishmania* infected tissues were made clean, sterilized with topical antiseptic and air dried. Dermal smear, ulcer scrapings were taken from nodular raised part by making a small incision near the margin the active edge of a lesion with the help of sterilized lancet as shown in figure 1a. Insulin syringe (1cc) containing 0.9 percent sterilized normal saline tightly connected to a 0.5mm diameter needle syringe and slowly advanced with a negative pressure near the ulcer margin penetrating into the subcutaneous tissue in the direction of the ulcer. Suction was applied when the needle reached below the ulcer margin of the lesion and

injected normal saline inside. The needle was detached, syringe was filled with air, needle was reattached and inserted again until the blood containing stinged fluid oozed out from the lesion and contents were blown into the eppendorf and rapidly onto clean alcohol-free microscopic slides for further examination as shown in figure 1b (Mashhood *et al*., 2005).

The following diagnostic investigations were performed for each case;

1-Microscopic examination using Geimsa stained smears from the lesion border

Smears were fixed in methanol and stained with Giemsa after application with a cover slip and examined under light power (40x) microscope and then finally moved to oil immersion lens (100x) to quantify the burden of *Leishmania* parasites (amastigotes and promastigotes) based on their morphology with maximum cellular yield to look either for large macrophages containing the parasite or areas with predominance of mononuclear inflammatory cells (Sharquie *et al*., 2002).

2-Culture from skin lesion scrapes

Similar to the preparation of the slide smears, scraped tissue was inoculated on the liquid phase of Novy- McNeal-Nicolle (NNN) medium and cultured in RPMI 1640 (supplemented with 10% fetal calf serum plus 200 µg/ml streptomycin and 200 U/ml penicillin) of antibiotics. The cultures were incubated at 26 ^{0}C and examined for parasite growth under optic microscope use every 4th day until promastigotes were seen or up to one month before being discarded as negative. The cultures were made at least in duplicates for each case. Slides were labeled accordingly to identify the patient and the sampling technique used.

3- DNA extraction and PCR amplification of stained specimens

The target DNA was extracted from exudate/skin scrapings using DNA zole kit (Trizole USA) and amplified in 20µl reaction mixture containing 10x PCR buffer 2µM, 1µM deoxynucleosidetriphasphate (500µM), 2.4µM $MgCl_2$, 1 µM primers (10pmol), target DNA 5 µl, and 0.3 unit of *Taq* DNA polymerase in a thermal cycler (Nyxtech USA) using Oligonucleotide, LSa (5´ TCTTGCGGGGAGGGGGTG-3´) and LSb, (5´ - TTGACCCCCAACCACATTTTA-3´) specific to kDNA of *L. tropica.* (Machado EMM, 2000). Reaction buffer without Leishmanial DNA was also included as a negative control. DNA amplification was initiated at temperature of 92°C for 180 sec for denaturing and annealing at 92°C for 40 sec and extension at 72°C for 60 sec.

The designed program was carried out in Thermal Cycler (Nyxtech USA) for 2-3hrs and saved as CL PCR. PCR was conducted in a 25 µl of reaction mixture containing $MgCl_2$, 10 mM dNTPs and 2U of *Taq* DNA polymerase (Fermentas USA). The amplified product was run for 25 mins at 130 volts and 500 ampere current on 2% agarose gel poured into gel tray in a gel tank consisting of 1000 ml of 0.5x TBE buffer, 15µl of DNA Ladder (100 bp) visualized under UV transilluminator using ethidium bromide (0.5 mg/ml). The CL specific band 186 bp was compared with 100 bp DNA ladder marker (Fermentas USA) (Romero *et al*., 2001).

Results and Discussion

Isolation and identification of the *Leishmania* parasite from the specimen is not only specific diagnostic criteria for better understanding of clinical and eco-epidemiological studies but also imperative to characterize the organisms up to species or genus level.

To test the hypothesis, 41 patients fulfilling consensus criteria with clinical history suggesting cutaneous leishmaniasis were confirmed by at least one of the following diagnostic tests: Giemsa stained preparation, isolation of parasites in culture, detection of parasite by PCR. For technical reasons, it was not possible to use all methods to diagnose all patients in the study. Our results show that, patients with active skin lesions having ulcer (79%) and nodular presentation (17%) were located primarily on the lower extremity (40%), face (28%), or upper extremity (23%). Of these patients, 29 (70.7%) showed positive results in Giemsa stained preparation and 12 patients presented with negative results. Negative results of tests may be influenced by secondary bacterial or fungal infections and/or due to the presence of old lesions, since most of the methods to test for parasites (Giemsa stain, culture and PCR) are significantly less sensitive in lesions that have been present for longer than 4-6 months. In our study, the clinical diagnosis of cutaneous leishmaniasis was confirmed by direct microscopic examination of lesion aspirate as intracellular or extracellular amastigotes observed as colorless, round to oval small bodies containing nucleus and/or kinetoplast as shown in figure 2. These amastigotes which measure about 2-5um are intracellularly present mostly in monocytes and macrophages of infected vertebrate hosts and rarely in other cell types; i.e dendritic cells and fibroblasts (Sharquie *et al*., 2002). Promastigotes cultured from amastigotes were observed in 21/41 (51%) aspirate culture as a single anterior flagellum emerging from the cell body running parallel to the

microtubules of the axoneme making these organisms functional and motile as shown in figure 3. Culture methods make possible diagnoses by isolation of biopsies or aspirate lesions in patients with the reproduction of the parasite which can be overlooked by the staining method depending on the handling and experience of laboratory technicians (Pratlong *et al*., 2009). Likewise, the percent success for microscopic identification of amastigotes in stained preparations and productivity of culture varies depending on the number of parasites present and/or the experience of the person examining the slide. In those cases where promastigotes were cultured, additional serological, biochemical, biological and other techniques had to be used to characterize the parasites (Singh and Sivakumar, 2003).

Precise identification of the *Leishmania* species is important for epidemiological and clinical reasons to help investigate the pathogenesis of the tegumentary leishmaniasis in areas of endemnicity. Therefore, differentiations among species require a more sensitive method for diagnosis and confirmation of the infection such as polymerase chain reaction (Murray *et al*., 2005). Stained smears from confirmed patients were evaluated using PCR to classify the parasite. In this study, we evaluated PCR potential in the identification and molecular characterization of cutaneous leishmaniasis and showed the presence of 186bp fragment confirming *Leishmania tropica*, as the causative agent in 76% observed cases of cutaneous leishmaniasis examined in district Kohat, KPK, Pakistan as shown in figure 4.

In our study, the better detection rate by Giemsa stain as compared to culture for parasitologic diagnosis was in agreement with the results reported by some investigators (Ramirez *et al*. 2000) and in contrast with the findings of others who reported higher sensitivity for culture as compared with Giemsa stain (Sharquie *et al*. 2002). In contrast to our study, culture of promastigotes from infected tissues and/or direct identification of amastigotes in microscope smears have long been considered as the gold standard for diagnosis (Liarte *et al*., 2001). Even though the disease is usually diagnosed with microscopic examination of a dermal scraping or biopsy, molecular techniques such as PCR was found to be a more sensitive promising method for diagnosis and confirmation of the parasites in acute and chronic lesions.

Conclusion

Histopathological and serological methodologies have limited the diagnostic criteria due to their low sensitivity when employed in areas of endemnicity. As the diagnosis is more challenging,

enhanced PCR technique in chronic biopsies should be considered the preferred diagnostic method for evaluating prognosis. Vectors recognition by clinicians and pathologists need to rely on advanced techniques to identify clinical and morphological features of the infection remain of prime importance as they are directly related to crucial value of disease containment. In addition, study of species distribution can help us to design prophylactic preventive plan for disease control and effective therapy.

Source of Support: Nil

Conflict of Interest: None declared

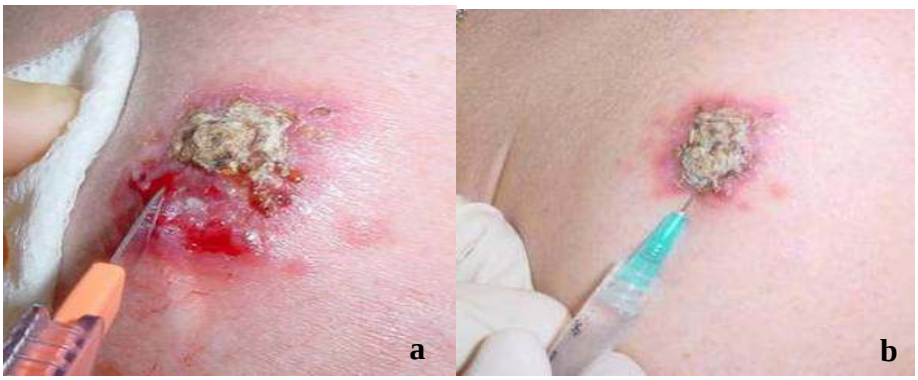

Figure 1. Tissue aspirate isolation of *Leishmania* infected patients with cutaneous leishmaniasis using (a) sterilized scalpel and (b) insulin syringe containing sterilized 0.9 % normal saline is used.

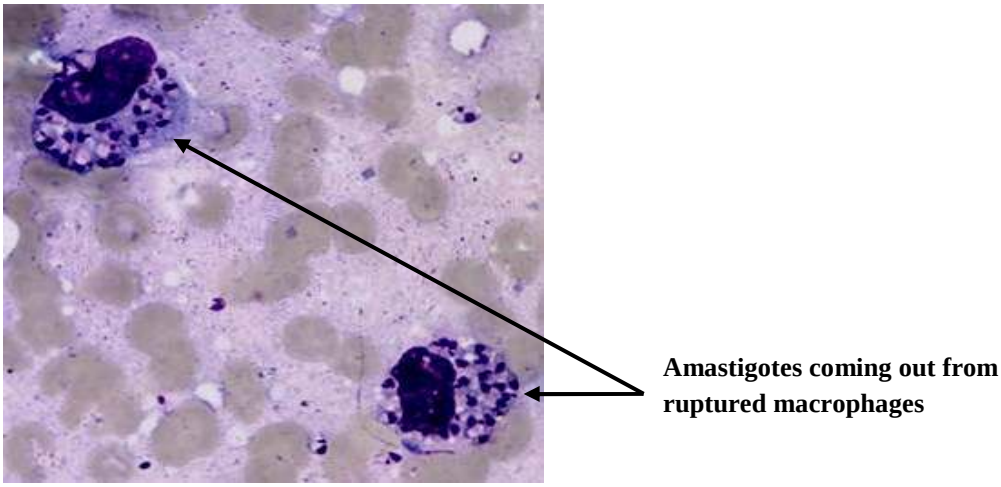

Figure 2. Intracytoplsmic amastigotes form of *Leishmania* organism in tissue smear (stain Giemsa, x100)

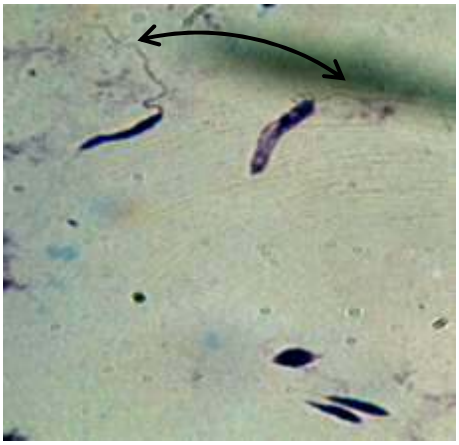

Figure 3. *In vitro* cultured promastigotes with the emersion of single anterior flagellum inoculated in Novy- McNeal-Nicolle (NNN) medium (stain Giemsa, x 40)

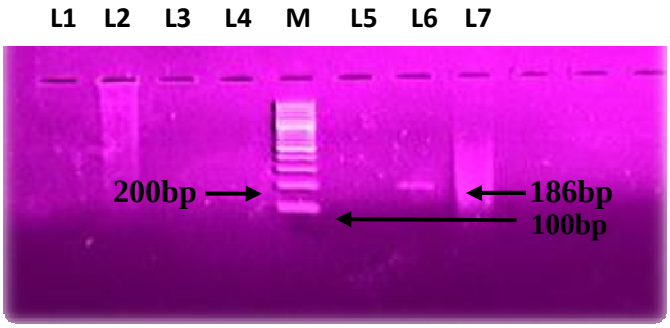

Figure 4. PCR-based amplification of kinetoplast DNA extracted from skin lesions of the patients. The bands shown on 2% agarose gel stained with ethidium bromide correspond to molecular weight markers. PCR amplified product of *L. tropica* in biopsy samples obtained from patients with Lanes 1, 3 and 4 = negative samples, lane 5= negative control, lane 6 = positive sample, lane 2 and 7 = positive control, M = Marker 100bp DNA ladder

References

Culha, G., Uzun, S., Ozcan, K., Memisoglu, H. R., Chang, K. P. 2006. Comparison of conventional and polymerase chain reaction diagnostic techniques for leishmaniasis in the endemic region of Adana, Turkey. *Int J Dermatol*. 45: 569-72.

Davies, C.R., Kaye, P., Croft, S.L. and Sundar, S. 2003. Leishmaniasis: new approaches to disease control. *Brit. Med. J.* 326: 377-382

Desjeux, P. 2001. The increase in risk factors for leishmaniasis worldwide. Trans. R. Soc. *Trop. Med. Hyg*. 95: 239–243.

Hailu, A., Trentina D. M., Tamrat, A., Mesfin, H., Piet, A. K., and Marina, G. 2006. Isolation of *Leishmania tropica* from an Ethiopian cutaneous leishmaniasis patient. *Trans R Soc Trop Med Hyg*. 100: 53–58.

Hamid, I., Baharullah, K., Sultan, A., Ali, R., Muhammad, I., Muhammad, N., A., Hameed, U.,R., Saqib, W and Abdul, W. 2012. Comparative efficacy of *Aloe vera* and *Tamarix aphylla* against cutaneous leishmaniasis. *IJBMSP*. 2: 42-45

Liarate, D. B., Mendonca, I. L. Luz F. C., Abren, E. A., Mello, G. Farias, T. J., Ferreira, A. F., Millington, M. A. and Costa, C. H. 2001. QBC for diagnosis of human and American visceral Leishmaniasis preliminary data. *Soc.Bras, Med.Trop*. 34: 577-81.

Markle, W. H., and Makhoul, K. 2004. Cutaneous leishmaniasis: recognition and treatment. *Am Fam Physician.* 69: 1455-60.

Mashhood, A. A., Khan, I. M., Nasir, S., Agha, H., Saleem, M., Imran, A. 2005. Fine needle aspiration cytology versus histopathology in the diagnosis of cutaneous leishmaniasis in Pakistan. *J Coll Physicians Surg Pak.* 15: 71–73.

Mohammed, W. D. 2008. Is the Amastigote Form of *Leishmania* the Only Form Found in Humans Infected With Cutaneous Leishmaniasis? *(Central Committee of the General Health Laboratories, Ministry of Health, Damascus, Syria). Labmedicine*. 38-41.

Murray, H. W., Berman, J. D., Davies, C. R., and Saravia, N. G. 2005. Advances in leishmaniasis. *Lancet*. 366: 1561–77.

Pratlong, F., Dereure, J., Ravel, C., Lami, P., Balard, Y., Serres, G., Lanotte, G., Rioux, J. A., and Dedet, J. P. 2009. Geographical distribution and epidemiological features of Old World cutaneous leishmaniasis foci, based on the isoenzyme analysis of 1048 strains. *Trop. Med .Int Health.* 14: 1071-1085.

Ramirez, J. R., Agudelo, S., Muskus, C., *et al*. 2000. Diagnosis of cutaneous leishmaniasis in Colombia: the sampling site within lesions influences the sensitivity of parasitologic diagnosis. *J Clin Microbiol*. 38: 3768-3773.

Romero, G. A., Guerra, M. V., Paes, M. G., *et al.* 2001. Sensitivity of the polymerase chain reaction for the diagnosis of cutaneous leishmaniasis due to *Leishmania* (Viannia) *guyanensis*. *Acta Trop*. 79: 225-9.

Romero, G. A., Noronha, E. F., Pirmez, C., Pires, Fdo. E., Fernandes, O., Nehme, N., Cupolillo, E. *et al*. 2009. Sensitivity and reproducibility of a PCR assay for *Leishmania* detection using skin biopsy imprints on filter paper. *Acta Trop*. 109: 74-77.

Sharquie, K. E., Hassen, A. S., Hassan, S. A., Al-Hamami, I. A. 2002. Evaluation of diagnosis of cutaneous leishmaniasis by direct smear, culture, and histopathology. *Saudi Med J*. 23: 925–928.

Sing, S., and Sivakumar, R. 2003. Recent advances in the diagnosis of Leishmaniasis. *J. Postgrad. Med*. 49:55-60.

Vannier-S. M. A, Martiny, A., De Souza W. 2002. Cell biology of *Leishmania* spp. invading and evading. *Curr Pharm Des.* 8: 297-318.