UNDER PEER REVIEW

Case Study

BILIARY ASCARIASIS : OUR EXPERIENCE AND REVIEW OF LITERATURE.

ABSTRACT:

Background/Aim: Ascariasis is endemic in the tropics especially amongst those living in poor sanitary conditions. Although most commonly it infests the small intestine, it can sometimes migrate to the biliary tract. We herein aimed to study the clinical manifestations, complications, diagnostic modalities and the most appropriate treatment modality for this condition.

Materials and Methods : Fifteen cases of hepatobiliary ascariasis presenting over a period of 1.5 years were studied. All the patients were adults and presented to the emergency with acute biliary symptoms.

Results: In this study, biliary ascariasis was found to be more common in middle aged females. The common presentations included upper abdominal pain and jaundice. Complications observed included acute pancreatitis and cholangitis. Ultrasonography could establish the diagnosis in 86.67 % cases. Medical management could successfully treat 86.67 % patients with ERCP being required in the remainder.

Conclusion: In endemic countries, ascariasis should be considered as a differential diagnosis in patients presenting with acute biliary symptoms. Ultrasonography is a useful non invasive test to diagnose the condition and medical management remains a reasonable first line treatment option.

KEY WORDS: ultrasonography, biliary ascariasis, ERCP.

UNDER PEER REVIEW

INTRODUCTION

Intestinal worm infestation with ascariasis is seen commonly in endemic areas like India. However, uncommonly it may present with acute biliary symptoms due to migration of the worm into the biliary tree. Various modalities like expectant management, endoscopic removal of worm and open surgical interventions have been used for treatment of biliary ascariasis. We have reviewed our experience of this condition over the last 1.5 years to study the clinical manifestations, complications, diagnostic modalities and the most appropriate treatment modality for this condition.

MATERIAL AND METHODS:

The study was carried out prospectively from December 2012 to June 2014 at a university college hospital in Delhi, India. It included all patients presenting with right or central upper abdominal pain, jaundice with or without fever, which on further investigations had a worm in the CBD as the aetiology of these symptoms. Haemogram, liver & renal function tests, blood sugar and serum amylase along with a chest radiograph and ultrasonogram of abdomen were done in all patients. In patients suspected of having cholangitis, blood cultures were sent. Further a magnetic resonance cholangiopancreatography (MRCP) was done only in those patients wherein the diagnosis could not be made on ultrasonography. All patients were given tablet albendazole 400mg bid for three days, alongwith an antispasmodic (hyoscine 10 mg tid). Patients with cholangitis/ raised total leucocyte count (TLC) were started on antibiotics. A repeat ultrasound scan was done after three and six days to see for bile duct clearance. Patients with cholangitis who did not improve on expectant management after 48 hours, or those with worm persisting in the bile duct at one week on ultrasonogram underwent endoscopic retrograde cholangiopancreatography (ERCP) and worm extraction.

For the purpose of this study, cure was defined as resolution of symptoms, normalization of laboratory parameters and demonstration of clearance of bile duct on ultrasonogram /ERCP at or within four weeks of admission.

UNDER PEER REVIEW

RESULTS

There were 15 patients who presented with biliary symptoms of average duration 3 days and had worm in their CBD as the cause of their symptoms (fig1). All were emergency admissions. Thirteen of these fifteen patients were female. The mean age was 45 years (35-55years). All patients presented with right or central upper abdominal pain. Jaundice was associated symptom in five patients. Cholangitis was present in one patient. On examination, all but one patient had tenderness in RHC. One patient had epigastic tenderness and guarding to raise suspicion of acute pancreatitis.

The total leucocyte count was raised in eight patients, serum bilirubin was raised in five patients, alkaline phosphatise in eleven patients, and serum amylase in one patient. The diagnosis could be established on ultrasound in all but two patients who required a MRCP in view of presence of dilated CBD on ultrasound. Cholangitis and acute pancreatitis were the complications observed in one patient each. Two patients required ERCP for CBD clearance (fig2). One of these had cholangitis which did not respond to expectant management and the other had persistence of worm in CBD on ultrasonogram at one week (table1,2).

All patients had resolution of symptoms, normalization of laboratory parameters and documentation of clearance of CBD on USG at four weeks post discharge.

UNDER PEER REVIEW

94

95 **Table one : data of fifteen patients (RHC: right hypochondrium).**

Case no	Age/gender	Duration of symptoms	Clinical presentation	h/o previous surgery	Final treatment modality
1	35 years / F	01 Day	Pain RHC	None	Medical treatment
2	38 years/F	04 days	Pain RHC	none	Medical treatment
3	45 years/F	04 days	Pain RHC	none	Medical treatment
4	50 years/F	02 days	Pain epigastrium, jaundice	cholecystectomy	Medical treatment
5	43 years/F	04days	Pain RHC, jaundice	None	Medical treatment
6	52 years/M	03 days	Pin RHC, jaundice	none	Medical treatment
7	40 years/F	02 days	Pain RHC&epigastrium, fever, jaundice	Open cholecystectomy with choledochoduodenostomy	**ERCP**
8	48years/M	01day	Pain epigastrium	none	Medical treatment
9	40 years/F	05 days	Pain RHC, jaundice	Cholecystectomy	**ERCP**
10	38 Years/F	04 days	Pain RHC	none	Medical treatment
11	45 Years/F	02 days	Pain RHC	none	Medical treatment
12	43 Years/F	03 days	Pain RHC	none	Medical treatment
13	34 Years/F	04 days	Pain RHC	none	Medical treatment

UNDER PEER REVIEW

14	55 Years/F	04 days	Pain RHC	none	Medical treatment
15	35 Years/F	04 days	Pain RHC	none	Medical treatment

Table two: depicting summary for patient findings (CBD: common bile duct, ERCP: Endoscopic retrograde cholangio pancreatography, MRCP : Magnetic resonance cholangio pancreatography, LFT: Liver function tests, USG: ultrasonogram, ALP: alkaline phosphatise).

Duration of symptoms	03 days(1-5 days)
Presenting symptom • Abdominal pain • Jaundice • cholangitis	 15(100%) 05 (33.33%) 01
Laboratory parameters • Leucocytosis • Raised bilirubin • Raised ALP	 8 (53.3 %) 5 (33.33%) 11 (73.33%)
Diagnosis confirmed on • USG • MRCP	 13 (86.67%) 02 (13.33)
Medical treatment success (resolution of symptoms , normalization of LFT,documentation of CBD clearance)	13 (86.76)
ERCP (indication)	

UNDER PEER REVIEW

• Cholangitis • Persistence of CBD worm	01 01

DISCUSSION

Ascariasis is commonly seen in endemic regions like India wherein it is common in those living in poor sanitary conditions.

In humans, the usual site of infestation by *A. lumbricoides* is the small intestine. However, it may migrate to unusual sites like biliary tree when the worm load is high like more than 1000 worms. Also, previous surgery on the biliary tract like cholecystectomy, hepaticojejunostomy, cholecystectomy predisposes the patient to biliary ascariasis, probably due to dilatation of common bile duct and rise of cholecystokinin levels leading to further sphincter of oddi relaxation.Gonzalez et al reported an incidence of 30% of their patients having history of cholecystectomy. [1]

Patients with biliary ascariasis usually present with symptoms of biliary colic as the worm migrates across the papilla. If the worm remains in the bile duct and gall bladder complications ensue like acute cholecysytitis, cholangitis, secondary choledocholithisis, biliary strictures and pancreatitis.[2] Some worms may travel up and colonize in the liver parenchyma forming liver abscess. [3]

The diagnosis of biliary ascariasis should be suspected in patients presenting with biliary symptoms especially in endemic regions. It is confirmed usually by the demonstration of worms in the biliary tract by imaging. Ultrasonography has a high accuracy in the diagnosis of biliary ascariasis. Inner tube sign (round worm is seen as a thick echogenic stripe with acentral anechoic tube in the gall bladder or common bile duct), stripe sign (thin non shadowing stripe without an inner tube within the gall bladder or common bile duct) and spaghettli sign (overlapping longitudinal interfaces in the main bile duct due to coiling of a single worm or several worms in the common bile duct) are commonly described signs. The mobility of the worm within the biliary tree unequivocally confirms the diagnosis. Apart from the diagnosis, USG also helps in monitoring choledochal clearance post treatment. [4]

UNDER PEER REVIEW

Magnetic resonance cholangio pancreatography (MRCP) may be used as another non invasive test in cases presenting with jaundice, cholangitis, pancreatitis that are not diagnosed on ultrasonography.

Endoscopic retrograde cholangio pancreatography (ERCP) usually shows the worm as a long filling defect. Successful extraction of the worm from the common bile duct via endoscope has been reported in the literature. [5]

Treatment options for CBD worm include medical management which includes anti helminthic and watchful waiting for the worm to return to intestine, endoscopic extraction of worm via ERCP and surgical exploration and removal of worm. [5] Medical management of biliary ascariasis is successful in over 85 % cases and had has been recommeneded as the preferred modality of treatment in various studies.[6] Also as stated by khan et al “the use of ERCP must be balanced against potential complications of the procedure. Moreover, sphincterotomy performed during ERCP for worm extraction predisposes to recurrent worm infestation. ERCP as a therapeutic intervention should be considered if a patient fails to respond to conservative treatment or the worm persists (serial sonograms).” [7]

In the present study, biliary ascariasis was more commonly seen in the middle aged females with all presenting with acute biliary symptoms. Previous surgery of biiary tract were present in three (33.33%) patients. Complications noted were acute cholangitis and pancreatitis. Ultrasonography diagnosed the condition in 86.67 % cases. Intervention in the form of ERCP was required in 13.333% cases only due to persistence of CBD worm and presence of cholangitis. There was no mortality.

CONCLUSION

Biliary ascarisis should be considered as a differential diagnosis of acute biliary symptoms especially in endemic areas. Ultrasonography is a useful non invasive test with a high diagnostic accuracy. Medical management should be the preferred initial treatment modality with more invasive procedures like ERCP being reserved for patients failing medical management or developing complications like cholangitis/ secondary choledocholithiaisis.

UNDER PEER REVIEW

REFERENCES:

1. González AH[1], Regalado VC, Van den Ende J. Non-invasive management of Ascaris lumbricoides biliary tact migration: a prospective study in 69 patients from Ecuador. Trop Med Int Health. 2001 Feb;6(2):146-50.

2. Louw JH. Biliaray ascariasis in childhood. S Afr J Surg 1974;12:19-25.

3. Lloyd DA. Massive hepatobiliary ascariasis in childhood. Br J Surg 1981;68:468-73.

4. Jamsheer NS, Malik N, Al-Qamish J. Biliary ascariasis: Sonographic diagnosis. Saudi J Gastroenterol 2001;7:69-70.

5. Sanai FM, Al-Karawi MA. Biliary acsariasis: Report of a complicated case and literature review. Saudi J Gastroenterol 2007;13:25-32.

6. Wani MY, Chechak BA, Reshi F, Pandita S, Rather MH, Sheikh TA, *et al* . Our experience of biliary ascariasis in children. J Indian Assoc Pediatr Surg 2006;11:129-32.

7. Khan, A., Bhowmik, B., Hakim, H., Islam, M.. Outcome of conservative management in biliary ascariasis - a study of 98 cases. **Journal of dhaka medical college**, 19, oct. 2010. Available at:<http://www.banglajol.info/index.php/jdmc/article/view/6247>. date accessed: 17 aug. 2014.

FIGURE LEGENDS:

Fig1: ultrasonography showing worm in common bile duct.

Fig 2: ERCP image showing worm protruding through the ampulla.

UNDER PEER REVIEW

Fig-1

UNDER PEER REVIEW

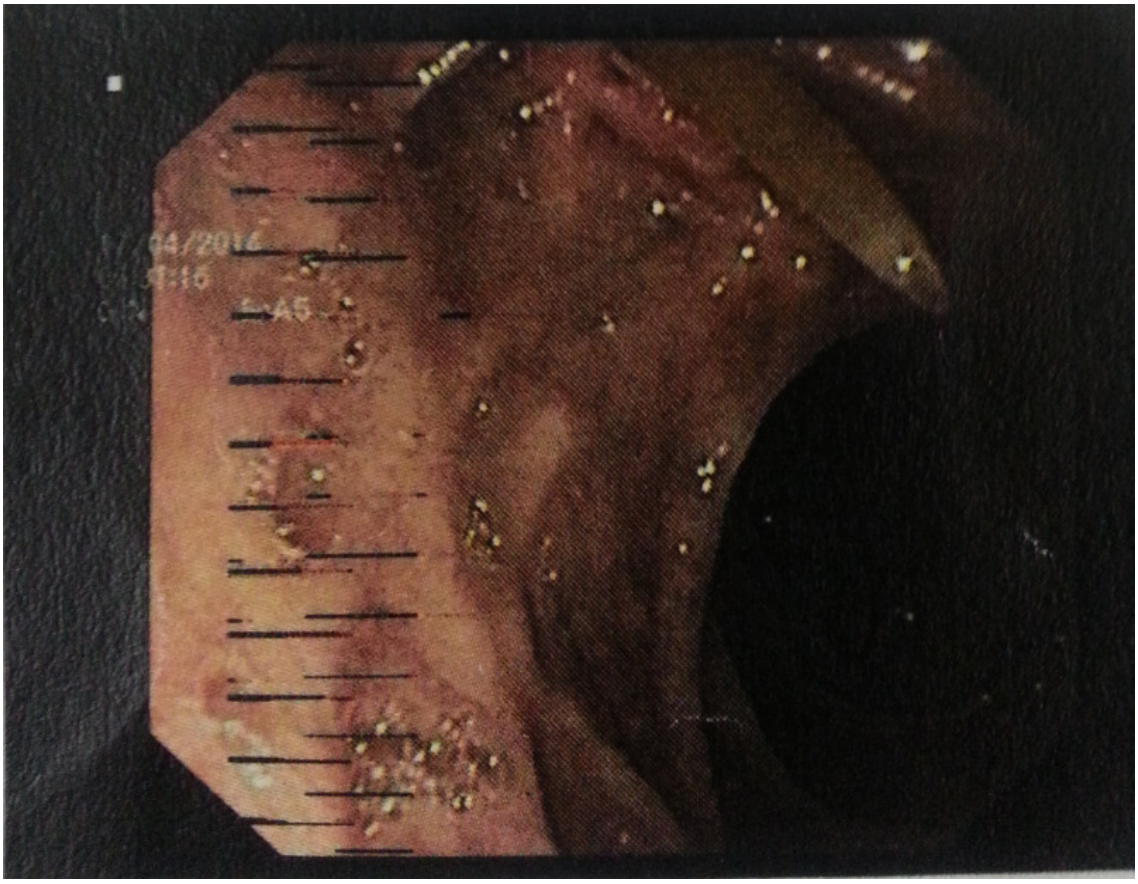

Fig-2