UNDER PEER REVIEW

Performance of Rapid Diagnostic Test for Malaria Diagnosis at the Different Specialized Hospitals in Wad Medani, Gezira State, Sudan

Abstract:

Background

Malaria may be overestimated if the diagnosis is based solely on clinical signs. Therefore, laboratory confirmation is essential. Rapid diagnostic tests (RDTs) have become an essential tool in malaria control and management programmes in the world. RDTs can offer a good alternative with the advantage that it is an easy and rapid method, and may assist in diagnosis and improving the practices prescription. This study aims to evaluate the performance of RDTs for malaria diagnosis.

Methods

In Wad Medani, Central Sudan. 931 patients with symptoms of malaria attended the outpatient clinics at the different specialized hospitals were enrolled in this study, RDT and blood smears methods were performed to diagnose *Plasmodium falciparum* malaria and blood drop spot were collected in filter paper for nested PCR technique as a confirmative diagnostic tool.

Results

The results obtained by this study revealed that, 131/931 (14.1%) and 63/931(6.7%) were positive when performed by microscopy and RDT respectively. While the result of the 131 microscopy positive samples showed that 63/131(47.3%) were positive by RDT and 68/131(52.7%) were negative. The 68 samples subjected to nested PCR, 6 samples gave an insufficient amount of DNA after extraction while all the 62 samples confirmed that they were infected with *P. falciparum* malaria, indicating that there is a significant difference between the rates of malaria cases diagnosed by microscopy and RDT ($P = 0.001$)

Conclusion

This study concluded that the implementation of RDT as a diagnostic tool could not be a merely an alternative method to diagnose malaria, and it does not replace malaria microscopy.

UNDER PEER REVIEW

Keywords: RDT, microscopy, malaria diagnosis, Sudan

Background:

Malaria diagnosis by microscopy or RDT are still not well identified although the evidence – based malaria parasite detection is recommend by the WHO prior to the treatment[1].
Microscopy is the common diagnostic technique and widely used to diagnose malaria, it is capable in plasmodium species differentiation, detecting all plasmodium stages and their quantities. This technique to be a good method it requires high skills of laboratory personnel, good quality of blood slides and microscope so as to achieve acceptable level of sensitivity[2-4].
The use of RDTs that are based on the detection of Plasmodium antigens in the blood stream, in particular Plasmodium histidine-rich protein II (HRP-II) or lactate dehydrogenase enzyme (LDH) forms a vital part of malaria diagnosis, case management and control strategy. But at low parasitemia < 100 parasites/ µ L, the sensitivity of these tests decreases markedly[5.6]. RDTs utilization in developing countries has increased, and all RDTs that detect plasmodium species are manufactured commercially with different target antigens and are available to enhance malaria control measures[7]..
RDTs should provide results similar to that detected by microscopy performed by expert laboratory personnel under routine field conditions[8]. Malaria diagnosis accuracy can be strengthened by using RDTs that have become very popular in endemic areas where a good quality of microscopic service is not available or feasible to maintain, and now they are essential tool in malaria elimination and eradication campaign[9,10]. Microscopy and RDTs are both adequate to diagnose or to exclude malaria in febrile patients, and they can enhance early diagnosis and appropriate management of other febrile illness[11]. The challenges for diagnostic laboratories in Africa, include defective microscopes and unavailability of other important good quality elements that offer adequate malaria microscopy service are well known. In 2010, many of malaria-endemic countries in Africa including Sudan adopted a policy of providing parasitological diagnosis for all and the RDTs are the tool to be offered for improving diagnosis of malaria[12]. In Sudan, the predominant human malaria parasite is *Plasmodium falciparum* with a prevalence of 94% while *P. vivax* is less common. Transmission is maintained largely by *Anopheles arabiensis*, with focal contributions by *An. gambiae* and *An. funestus*[13]. The estimated malaria incidence in Sudan was around 1000 cases per 100,000

UNDER PEER REVIEW

population annually with a case fatality rate of about 6 deaths per 100,000[14]. In Sudan malaria indicator survey in 2009, the results of microscopy showed that only 95/489 individuals who were RDT positive and an additional 20 who were RDT negative were positive indicating that the number of malaria cases detected by RDT less than that detected by microscopy[13]. In 2012 the prevalence of malaria was 2.3% and 3.3% by microscopy and RDT respectively[15]. There a series of problems with poor quality of slides and microscopy results which rendered their findings unreliable. Consequently the RDT results were used as the final measure of prevalence during the malaria indicator survey[13,15]. However, RDTs are simple to be used as a diagnostic kits which can detect the parasites that cause malaria from one drop of the patient's blood. They do not require laboratory facilities or extensive training, and can provide a simple positive or negative result within 20 minutes, making them suitable for use in endemic rural areas[16]. So, in this study the performance of RDT was evaluated and compared with that of microscopy for *P.falciparum* malaria diagnosis and to assess their effectiveness as a diagnostic tool.

Methods

Study area and population

This is a comparative cross-sectional study, was conducted in different specialized hospitals in Wad Medani the main city of Gezira state in central Sudan. Total of 931 patients suspected to have malaria attended the outpatient clinics of these hospitals were enrolled.

Sample collection and techniques:

Microscopic examination:

Using sterile lancets, finger prick was made for each patient as described in the WHO basic malaria microscopic examination guide[17]. Thin and thick blood films (BFs) were made in one slide and stained with the Giemsa standard techniques, and examined by expert malaria microscopist. The blood films were read using a light microscope with x 100 oil-immersion lens and x 10 eyepiece. The slide was considered negative if no parasites were found after 100 high power fields were scanned. In the positive slides, the asexual stage of Plasmodium parasites were counted against 200 leukocytes by multiplying this number by a factor of 40

UNDER PEER REVIEW

assuming a mean white blood cell count of 8000 cells/µl. and expressed as parasites/µl of blood. All slides were further reviewed by a third independent expert laboratory technologist.

RDT :

In pararral with the microscopic examination, RDT were performed using the paracheck *pf* manufactured in India by Orchid Biomedical System (Lot No. 31218, manufacturing date:11/2005, expiry date: 10/2007). The major target antigens of the paracheck test device is PfHRP2 which is specific for *P. falciparum*. According to the manufacturer's instructions, The pouch was opened just prior to the test and the device was removed. With applicator pipette or a micropipette , 5µl of whole blood sample was blotted on the sample pad in sample well 'A'. Then 6 drops of clearing buffer were dispensed into well 'B'. The results within 15 -20 minutes were read as follow: considered negative when only one coloured band appeared in the control window 'C', and counted positive when **i**n addition to the control band a distinct coloured band also appeared in the test window 'T'. The test was considered invalid if no band appeared on the device and the test was repeated with a new device. The reading of RDTs were blinded to the microscopic results.

Nested PCR

For molecular analysis, blood was blotted in whatman 3 filter paper, and air dried. Filter papers were wrapped separately in a plastic bag and stored at room temperature. Total DNA was extracted from 68 samples using the phenol/chloroform method[18]. PCR reactions was performed in a total volume of 30 µl containing 100 ng genomic DNA, 15-20 Pico moles of each primer, 200 µM dNTP (dATP, dTTP, dCTP and dGTP), 3µl from 10 x Taq Gold Buffer (100mM Tris HCl, pH 8.3, 500 mM KCl, 15 mM MgCl2 and 0.01 % (w/v) gelatin. 1.5 U AmpliTaq GoldTM polymerase and be completed to final volume with deionized water. The PCR program was optimized for each primer (primer P5001 sequence GGG-CCC-AAA-ATT-CTA-TAG and Primer P500A2 as reverse primer sequence TGG-CGG-TGG-ATA-CTC-ATC-ATA) pair before start screening for different polymorphisms among cases and their controls. The efficiency of the amplification was tested by electrophoresis in 1.5-2.5% agarose in 1.5x TBE at 100-140 Volts for about 30 minutes and visualized under gel documentation system (GDS) after being stained with ethidium bromide. Both The agarose concentration in gel

UNDER PEER REVIEW

electrophoresis and the current in the gel depended on the length of the electrophoresed DNA fragment. Any presence of 13bp fragments compared with the ladder marker and positive control indicate the presence of amplified DNA product (positive result). Any well with no running products lead to the absence of the DNA amplification reaction (negative results). Result of each well was recorded according to its corresponding sample and patient label.

Ethical considerations

The ethical approval was obtained from the Ethical Committee of the Blue Nile National Institute for Communicable Diseases/University of Gezira and permission was obtained from Gezira State Health Authorities. Informed consent was obtained from the participants and in simple words the objectives of this study was expressed to them.

Statistical analysis

Data were entered and verified and statistical analysis was performed using SPSS version 12.0. The RDT results were compared with the microscopy and PCR as a confirmative tool using cross tabulation and Chi-square test to determine the significance level that was set as < 0.05.

Results and discussion

In this study, 931 blood samples collected from suspected malaria cases attended the outpatient clinics at 7 specialized hospitals in Wad Medani town in Central Sudan. The 931 were males and females and their age ranging from 2 to 76 years with an average of 36.5 years age. As indicated in table 1, the result of microscopy showed that 131/931(14.1%) were positive and 800/931(85.9%) were negative, the result of RDT showed that 63/931(6.8%) were positive and 868/931(93.2%) were negative. The parasite count of the positive cases was ranging from 4o to 57600 parasites/µl with an average of 5800 parasites/µl. Table 2 indicates that the degree of parasitemia < 100 parasites/µl were found in 39 cases with only 2 of them were positive by RDT, and that ranging from 100 -1000 parasites/µl were found in 44 cases with 13 positive by RDT and all cases (48/131) that their parasites count was >1000 parasites/µl were positive by both microscopy and RDT.

UNDER PEER REVIEW

As revealed in table 1 and 2, and figure 1, 68 of the 131 microscopy positive samples were negative by RDT. These mismatch samples were subjected to PCR technique as a confirmative diagnostic tool. 6 of the 68 samples gave an insufficient amount of DNA after extraction and the rest of samples 62/68 were positive by PCR confirming that the result of the 62 samples by RDT were false negative estimating that the incidence of malaria was 125/925 (13.5%) with no significant difference when compared with microscopy result ($P < 0.05$) . The overall incidence of *P. falciparum* malaria among the enrolled suspected cases (931) was 14.1% and 6.8% by microscopy and RDT respectively with a significance difference between them ($P = 0.001$) .

The quality diagnostic services remain the major challenges of malaria diagnosis in control programme in Sudan, the prompt and reliable diagnosis and effective treatment could help to interrupt the malaria transmission and reduced malaria burden. In Sudan and many other malaria endemic regions, there are problems and limitations associated with reliance on microscopic diagnosis of malaria, but microscopy is still a reliable method in areas where malaria is prevalent, if the quality of microscopy is poor, the RDT offer an alternative with the advantage that it is an easy and rapid method. Molecular tests are more sensitive but difficult to implement in large scale in endemic areas. This study revealed that 131/931 (14.1%) were positive by microscopy and 63/931(6.8%) were positive by RDT. Out of 131 positive by microscopic examination there were only 63 (47.3 %) positive by RDT indicating that there were a significant differences between microscopy and RDT in diagnosis of malaria ($P = 0.001$) in this study. The degree of parasitemia < 100 parasites/µl were found in 39 cases with only 2 of them were positive by RDT, and that ranging from 100 -1000 parasites/µl were found in 44 cases with 13 positive by RDT and all cases (48/131) that their parasites count was >1000 parasites/µl were positive by RDT, indicating that the sensitivity of RDT were decreased when the parasitaemia is low as confirmed before by Moody A[6]. The high rates of false negative RDT is attributed to the low number of parasites and hence the antigen deletion although there are some samples with high number of parasites showed false negative by RDT. The similar results were reported by Daniel in Uganda[19] who indicates that the most causes of false negative RDT were linked to low parasitaemia and HRPII gene deletion as revealed in our studies in table 2. In contrast of a study conducted in Venezuelan by Rodulfo H[20] that showed high sensitivity and specificity of microcopy and RDT, also a study conducted in

UNDER PEER REVIEW

Ugunda revealed high sensitivity of the HRP2-based test was 97% when compared with microscopy and 98% when corrected by PCR, and the sensitivity of the pLDH-based test was 88% when compared with microscopy and 77% when corrected by PCR by Heidi Hopkins[21]. The decrease of sensitivity of RDT in our study may due to the quality of RDT products that used in Sudan. In this study two cases was positive by RDTs and negative by microscopy, and this results may due to the persistence of antigeneamia after the clearance of parasite its self as was reported by Daniel in Uganda[19] . In this study the sensitivity of PCR was 100% which was agree with Rodulfo H[20] and Heidi Hopkins[21]. The outcome of this study indicated that many malaria cases can be missed if the diagnosis merely depend on RDT as reported before by Amex M[22] that misdiagnosis often happens in samples with low parasitaemia, and the results obtained by RDT in this study rendered it unsuitable diagnostic tool to measure the prevalence of malaria as done before in Sudan during the malaria indicator survey[13,15].

Conclusion:

In this study, as evidenced by PCR concluded that the use of the RDT could not be able to detect some infections with low numbers of malaria parasites and hence lead to a result of a missed malaria diagnosis. So, evaluating the different RDTs brands used in Sudan is recommended to improve malaria diagnosis by good quality of RDTs.

References:

1-World Malaria Report 2010.Geneva, *World Health Organization*, 2010

2- WHO (2000). New perspectives in malaria diagnosis. Geneva: *World Health Organization*, WHO/CDS/RBM/2000.14

3- O'Meara WP, Barcus M, Wongsrichanalai C, Muth S, Maguire JD, Jordan RG, Prescott WR, McKenzie FE (2006). Reader technique as a source of variability in determining malaria parasite density by microscopy. *Malaria Journal*, 5: 118

4- Drakely CJ & Reyburn H (2009). Out with the old, in with the new: the utility of rapid diagnostic tests for malaria diagnosis in Africa. *Transactions of the Royal Society of Tropical Medicine & Hygiene*, 103: 333-337.

UNDER PEER REVIEW

5- Guidelines for the Treatment of Malaria, Second Edition. Geneva, *World Health Organization*, 2 010

6- Moody A. Rapid diagnostic tests for malaria parasites. *Clin Microbiol Rev* 2002; 15: 66–78.

7-Bell D, Wongsrichanalai C, Barnwell JW, 2006. Ensuring quality and access for malaria diagnosis: how can it be achieved? *Nat Rev Microbiol* 4: 682–695.

8-Kakkilaya BS. Rapid Diagnosis of Malaria. *Laboratory Medicine*. (2003); 8:602-608

9- Bisoffi Z. Gobbi F. Angheben A. Van den Enle J: The role of rapid diagnostic test in managing malaria. *PloS Med*. 2009, 6:e 1000053

10- Wongsrichanalai C, Barcus MJ, Muth S, Sutamihardja A, Wernsdorfer WH: A review of malaria diagnostic tools: microscopy and rapid diagnostic test (RDT). *American Journal of Tropical Medicine and Hygiene*. (2007); **77:**119-127.

11- Parasitological confirmation of malaria diagnosis: WHO technical consultation, Geneva, 6–8 October 2009. Geneva, *World Health Organization*, 2010.

12- Malaria Rapid Diagnostic Test Performance: Results of WHO product testing of malaria RDTs: Round 3 (2010-2011). Geneva, World Health Organization on behalf of the Special Programme for Research and Training in Tropical Diseases, 2011.

13-Federal Ministry of Health (2010). Malaria Indicator Survey 2009 in the Northern states of the Sudan. Submitted to the World Health Organization, Eastern Mediterranean Regional Office, Cairo, Egypt. March 201011.

14- World Malaria Report 2011. Geneva, *World Health Organization*, 2011.

15-Federal Ministry of Health (2013). Malaria Indicator Survey 2012 in the Republic of Sudan. National Malaria Control Programme, Federal Ministry of Health, Khartoum, Sudan, October 2013.

16- The feasibility of introducing rapid diagnostic tests for malaria in drug shops in Uganda.Mbonye AK, Ndyomugyenyi R, Turinde A, Magnussen P, Clarke S, Chandler C. *Malar J*. 2010 Dec 21;9:367. doi: 10.1186/1475-2875-9-367.

UNDER PEER REVIEW

17- WHO. Basic malaria microscopy: Part I Learner's guide; Part II Tutor's guide. Geneva, *World Health Organization*, 1991

18- Plowe CV , Djimde A, Bouare M, Doumbo O, Wellems TE, 1995. Pyrimethamine and proguanil resistance-conferring mutations in *Plasmodium falciparum* dihydrofolate reductase: polymerase chain reaction methods for surveillance in Africa. *Am J Trop Med Hyg* 52: 565 – 568.

19- Daniel J Kyabayinze**,** James K Tibenderana**,** George W Odong**,** John B Rwakimari **and** Helen Counihan . Operational accuracy and comparative persistent antigenicity of HRP2 rapid diagnostic tests for *Plasmodium falciparum* malaria in a hyperendemic region of Uganda, *Malaria Journal* (2008); 7:221.

20- Rodulfo H, De Donato M, Mora R, González L, Contreras CE Braz J Med Biol Res. Comparison of the diagnosis of malaria by microscopy, immunochromatography and PCR in endemic areas of Venezuela, *Braz J Med Biol Res.* 2007 Apr; 40(4):535-43.

21- Heidi Hopkins, Lisa Bebell, Wilson Kambale,Christian Dokomajilar, Philip J. Rosenthal1 and Grant Dorsey. Rapid diagnostic tests for malaria at sites of varying transmission intensity in Uganda. *J Infect Dis. (2008) 197 (4): 510-518.*)

22-Amex M, Tolhurst R, Bamish G. Bates I. Malaria misdiagnosis: effects on the poor and vulnerable, *Lancet* 2004, 364: 1896 -1898.)

Figure 1: Diagram showing the performance of microscopy, RDT and PCR for malaria diagnosis in this study (n = 931 cases)

931 blood samples

UNDER PEER REVIEW

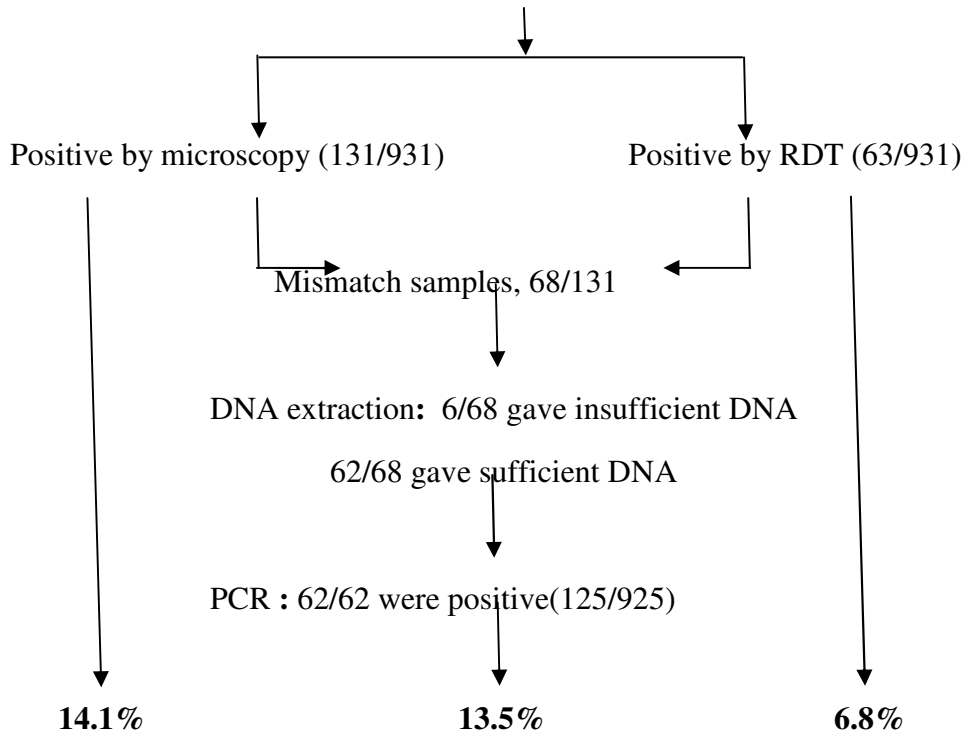

Table 1: The summery of study sites and their result by microscopy and RDT :

Study sites	No. of Cas	+ve BF	-ve BF	+ve RDT	-ve RDT
Military Wad Madani Hospital	95	25	70	10	85
Wad Madani Renal Hospital	95	11	84	3	92
Wad Madani Police Hospital	98	10	88	5	93
Wad Madani Pediatric Hospital	222	45	177	37	185
Gezira Radiotherapy Hospital	49	8	41	2	47

UNDER PEER REVIEW

Wad Madani Obstetric and Gynaecol Hospital	225	16	209	6	219
Wad Madani Teaching Hospital	147	16	131	0	147
Total	931	131	800	63	868
Result frequencies	100%	14.1%	85.9%	6.8%	93.3%

275

276 **Table 2: The parasites count of the 131 microscopic positive cases and their results by**
277 **RDT**

parasites/µl	Microscopic positive cases	+ve RDT	-ve RDT
< 100	39	02 / 39	37/39
100 – 1000	44	13 / 44	31/44
>1,000 – 10,000	28	28 / 28	00/28
>10,000	20	20 / 20	00/20
Total	131	63 / 131	68/131

278

279