

Iron Deficiency Anaemia Leading to Thrombocytopenia: A Case Report

Nataly Torrejon¹, Alejandro Calvo^{2*} and Stella Pak³

Please check corresponding author

¹School of Medicine, Universidad Privada del Valle, Cochabamba, Bolivia.

²Hematology and Oncology Division, Kettering Cancer Center, Kettering, Ohio, USA.

³Department of Graduate Education, Kettering Medical Center, Dayton, Ohio, USA.

Case Study

ABSTRACT

Iron deficiency anaemia is commonly associated with thrombocytosis, however cases of thrombocytopenia have been reported. Recurrent cases of iron deficiency with thrombocytopenia are even more unusual; therefore, we present a patient with recurrent thrombocytopenia in the setting of intermittent iron deficiency anaemia. The mechanism of platelet count variation in response to iron remains poorly understood. There are multiple possible explanations, including but not limited to the biphasic response of platelets to erythropoietin and the dual function of iron in platelet production. This case highlights the importance of an iron replacement trial for the individuals with documented iron deficiency and thrombocytopenia. An iron treatment trial could spare the patients with iron responsive thrombocytopenia from more invasive diagnostic modalities looking for primary bone marrow disorders.

Keywords: Thrombocytopenia; iron deficiency anaemia; menorrhagia.

*Corresponding author: E-mail: alejandro.calvo@icloud.com;

1. INTRODUCTION

In most cases of iron deficiency anaemia, the platelet count reactively increases or remains within the normal range [1,2]. Only a few cases in the literature report the association between severe iron deficiency anaemia and thrombocytopenia [3-11]. The exact mechanism of thrombocytopenia in this setting is not well understood. Herein, we present the case of a 30-year-old female with recurrent episodes of thrombocytopenia induced by severe iron deficiency anaemia that had a complete response to iron replenishment.

2. CASE PRESENTATION

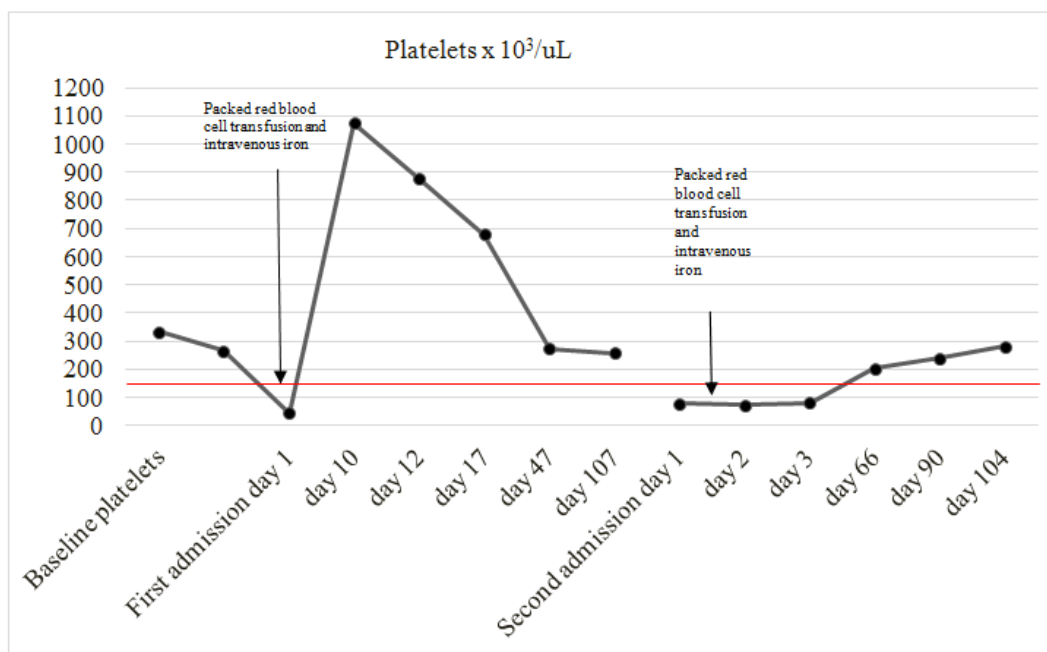
A 30-year-old African American female presented to the emergency department with generalised weakness, fatigue, pagophagia, and shortness of breath associated with heavy menstrual bleeding. She reported a 1-year history of menorrhagia secondary to uterine fibroid tumours, confirmed by pelvic ultrasonography and treated with oral contraceptives that had failed to control the heavy menstrual periods. She denied any other sources of bleeding. On physical examination, the patient was afebrile and her vital signs were normal, however, she did have significant pallor of the skin and conjunctival membranes. She did not have jaundice, petechia, ecchymosis or purpura. The cardiopulmonary exam was normal. There was no hepatomegaly, splenomegaly, or lymphadenopathy. Her complete blood count showed a red blood cell count of $2.27 \times 10^6/\text{ul}$ (normal range: 3.86 - 5.17), a hemoglobin of 4.9 g/dl (normal range: 12.1-15.8), a hematocrit of 16.4% (normal range: 35.8 - 46.5), a mean corpuscular volume of 72.4 fl (normal range: 80 - 99), a red cell distribution width of 33.2 % (11.7 - 15.2%), a platelet count of $77 \times 10^3/\text{ul}$ (normal range: 15 - 450), a white blood cell count of $3.6 \times 10^3/\text{ul}$ (normal range: 4 - 10.5), an absolute neutrophil count of $1.2 \times 10^3/\text{ul}$ (normal range: 2 - 7.3) and a corrected reticulocyte index 0.67 indicating a hypoproliferative anaemia. The results of the iron studies were consistent with profound iron deficiency anaemia. The patient had a ferritin level of 1.8 ng/ml (normal range: 12 - 150) and a total iron binding capacity of 478 ug/dl (normal range: 250 - 450). There was no laboratory evidence of hemolysis. The peripheral blood smear revealed microcytosis and hypochromasia with decreased but large

platelets. She was then admitted to the inpatient unit and treated with 2 units of packed red blood cells and intravenous iron. Work up for autoimmune diseases, infectious causes and hemoglobinopathies returned negative. Her vitamin B₁₂ and folate levels were within the normal limits and a computed tomography of the abdomen confirmed the absence of hepatosplenomegaly. A review of the patient's records revealed that 12 months before, she presented with another episode of iron deficiency anaemia associated with thrombocytopenia caused by menorrhagia. At that time, she underwent an upper endoscopy with biopsy which was negative for celiac disease and did not show other sources of bleeding. She did not agree to undergo a colonoscopy. In this previous hospitalisation, she was given a blood transfusion and 1 gram, single dose of intravenous iron which caused the patient's platelet to recover from $43 \times 10^3/\text{ul}$ to $1,017 \times 10^3/\text{ul}$ and her severe anaemia to resolve. Ultimately, her platelet counts stabilised to $258 \times 10^3/\text{ul}$.

Although the presence of both severe anaemia and thrombocytopenia raised the question of a primary bone marrow disorder, based on her previous history of low platelets and iron deficiency anaemia that responded to iron replenishment, we decided not to perform a bone marrow biopsy. After discharge, the patient continued to receive intravenous iron replacement in the outpatient setting until she completed a total IV iron dose of 1.5 grams, matching her estimated iron deficit. Menorrhagia was controlled with Depo-Provera and the patient returned to have normal menstrual periods. On a follow up visit approximately 2 months after discharge, the patient experienced complete recovery of all of her cytopenias. As the patient remained asymptomatic, intravenous iron replacement was discontinued but she continues to be monitored with complete blood counts, iron panels, and physical exams.

3. DISCUSSION

Iron deficiency anaemia has been typically associated with thrombocytosis, but some cases of thrombocytopenia have been reported [3-11], especially in pediatric cases [10,11]. Recurrent cases of this uncommon association are even fewer with only one case reported of a male with



Please check this figure

Fig. 1. Platelet production in response to iron replenishment

recurrent iron deficiency anaemia and thrombocytopenia [12].

The exact mechanism of platelet count variation with respect to iron remains unknown, it was hypothesised that the amino acid sequence similarity between erythropoietin (EPO) and thrombopoietin (TPO) could explain the more common presentation of reactive thrombocytosis [13], but this would fail to explain the presence of thrombocytopenia with iron deficiency anaemia and the lack of cross competition between these two cytokines in cells altered to express functional forms of both the Mp1 receptor and the EPO receptor [14]. A more plausible explanation for EPO induced platelet count variation is that thrombopoiesis may have a diphasic response to EPO, as models with moderate Epo stimulation obtained by the standard doses of recombinant human EPO cause a moderate elevation of platelet counts but intense EPO stimulation causes some degree of thrombocytopenia [15]. It has also been hypothesised that there is a two-compartment iron system in which iron can inhibit the rise in platelet count above steady-state levels via some inhibitory mechanism against thrombopoietin but at the same time, iron is required for the production of an integral portion of the platelet [16]. This model is further supported by the fact that iron is required for platelet protein synthesis

[17] and is a part of the elemental composition of platelets [18]. Iron deficiency stimulates thrombopoiesis, but only to the extent when sufficient iron is available for the synthesis of essential platelet components. In the present case, the variation of the platelet count in relationship to iron replacement supports this compartmental model in our case as shown in Fig. 1, in the presence of severe iron deficiency the platelet count is diminished, once iron stores are replenished, the platelet count overcorrects and then returns to baseline. 1 year later, when iron deficiency recurs, so does her thrombocytopenia. At that time, thrombocytopenia responded again to iron replacement therapy.

4. CONCLUSION

The association of iron deficiency anaemia with thrombocytopenia is uncommon. Clinicians should consider iron deficiency induced thrombocytopenia in the differential diagnosis when more common causes of thrombocytopenia have been ruled out. This case highlights the importance of an iron replenishment trial for the individuals with unexplained thrombocytopenia in the setting of iron deficiency. Iron replenishment trial could spare the patients with iron responsive thrombocytopenia from more invasive diagnostic modalities.

CONSENT

As per international standard or university standard, patient's consent has been collected and preserved by the authors.

ETHICAL APPROVAL

It is not applicable.

COMPETING INTERESTS

Authors have declared that no competing interests exist.

REFERENCES

1. Dan K. Thrombocytosis in iron deficiency anemia. *Internal Medicine*. 2005;44(10): 1025–6.
2. Schloesser LL, Kipp MA, Wenzel FJ. Thrombocytosis in iron-deficiency anemia. *The Journal of Laboratory and Clinical Medicine*. 1965;66(1):107–14.
3. Berger M, Brass LF. Severe thrombocytopenia in iron deficiency anemia. *American Journal of Hematology*. 1987;24(4):425–8.
4. Verma V, Ayalew G, Sidhu G, Ramnaraigh B, Cutler J, Khandekar S, et al. An analysis of the relationship between severe iron deficiency anemia and thrombocytopenia. *Annals of Hematology*. 2014;94(3):535–537.
5. Kuku I, Kaya E, Yologlu S, Gokdeniz R, Baydin A. Platelet counts in adults with iron deficiency anemia. *Platelets*. 2009;20(6): 401–405.
6. Kadikoylu G, Yavasoglu I, Bolaman Z, Senturk T. Platelet parameters in women with iron deficiency anemia. *Journal of the National Medical Association*. 2006;98(3): 398–402.
7. Ibrahim R, Khan A, Raza, S, et al. Triad of iron deficiency anemia, severe thrombocytopenia and menorrhagia- A case report and literature review. *Clinical Medicine Insights Case Reports*. 2012;5: 23–27.
8. Gupta M, Joseph G. Severe thrombocytopenia associated with iron deficiency. *Hospital Physician*. 2001;37: 49–54.
9. Shah B, Shah T. Iron deficiency thrombocytopenia: A case report. *Medical Principles and Practice*. 2011;20(5):483–484.
10. Morris VK, Spraker HL, Howard SC, Ware RE, Reiss UM. Severe thrombocytopenia with iron deficiency anemia. *Pediatric Hematology and Oncology*. 2010;27(5): 413–419.
11. Perlman M, Schwab J, Nachman J, Rubin C. Thrombocytopenia in children with severe iron deficiency. *Journal of Pediatric Hematology/ Oncology*. 2002;24(5):380–384.
12. Giordano L, Llanos-Chea A, Monde A, Mulinge I, Dighe D. Recurrent severe iron deficiency anemia and thrombocytopenia in an adolescent male. *Journal of Pediatric Hematology/Oncology*. 2018;1.
13. Bilic E, Bilic E. Amino acid sequence homology of thrombopoietin and erythropoietin may explain thrombocytosis in children with iron deficiency anemia. *Journal of Pediatric Hematology/Oncology*. 2003;25(8):675–676.
14. Broudy VC, Lin NL, Sabath DF, Papayannopoulou T, Kaushansky K. Human platelets display high-affinity receptors for thrombopoietin. *Blood*. 1997; 89(6):1896–904.
15. Beguin Y. Erythropoietin and platelet production. *Haematologica*. 1999;84(6): 541–7.
16. Karparkin S, Garg SK, Freedman ML. Role of iron as a regulator of thrombopoiesis. *Am J Med*. 1974;57(4):521–5.
17. Freedman M, Karparkin S. Requirement of iron for platelet protein synthesis. *Biochemical and Biophysical Research Communications*. 1973;54(2):475–481.
18. Kiem J, Borberg H, Iyengar GV, et al. Elemental composition of platelets. Part II. Water content of normal human platelets and measurements of their concentrations of Cu, Fe, K, and Zn by neutron activation analysis. *Clin Chem*. 1979;25(5):705–10.