

Case study**One Antiresorptive Too Many
A case report and clinical opinion****ABSTRACT**

A 70 year old Caucasian female had been prescribed alendronate for osteopenia 4 years earlier. While on an overseas vacation, the day after enjoying an ocean swim, she experienced a sudden displaced fracture of her right femur while walking across a room. This fracture was treated locally with a femoral nail but failed to heal and remained a source of pain. Ten months after the initial fracture, the rod was replaced. Teriparatide subcutaneous injections were begun and resolution of the pain and healing followed. At the end of her 24 month course of teriparatide, she was started on denosumab twice yearly injections for a total of 5 injections. About 6 weeks before the 5th injection, she experience a fall from a standing height, but her X-ray evaluation revealed no fracture. Three months after the injection, the pain increased and additional studies were done, eventually demonstrating an insufficiency fracture of the left femoral shaft. Six weeks later, another plain film still showed an “undisplaced insufficiency fracture” and a femoral nail was placed the next day. Subsequently, she started on a second course of teriparatide which is still ongoing. She has not had any subsequent fractures.

1. INTRODUCTION

The association between bisphosphonate (BP) treatment and unusual femoral fractures was first recognized in 2003 [1] and published in the general medical literature in 2005 [2]. The rapidly growing number of papers about this association which followed was reviewed by a committee appointed from the leadership of the American Society of Bone and Mineral Research (ASBMR). Summaries of this review were presented in two ASBMR opinion papers published in 2010 [3] and 2014 [4]. The second of these papers provided a consensus definition of the fractures. The fracture(s) must be located from just distal to the lesser trochanter to just proximal to the supracondylar flare. It must have at least 4 of the 5 major features: minimal trauma, lateral cortex origination, substantially transverse orientation,

18 non- or minimally-comminuted fracturing, incomplete fractures must begin laterally, and may have
19 localized periosteal or endosteal cortical thickening. Minor features of generalized increased cortical
20 thickness of the diaphysis, prodromal symptoms, bilaterality, and delayed healing may be present.
21 These fractures were termed atypical femoral fractures (AFFs). In the 2014 paper, the ASBMR
22 committee stated that “[a]lthough the task force still holds the opinion that a causal relationship
23 between BPs and AFFs has not been established, evidence for an association has continued to
24 accumulate in the 2 years since the first report was published and is quite robust”.

25 **2. PRESENTATION OF THE CASE**

26 A 70 year old Caucasian woman had been prescribed weekly alendronate four years earlier for the
27 DXA diagnosis of osteopenia. The drug label allowed for this use under the title “prevention of
28 osteoporosis”. She was on a vacation with friends outside the continental United States. On the day
29 following arrival, she was able to swim with the dolphins at an aquarium. On the third day, she was
30 walking in a room in her rented apartment when her right leg suddenly collapsed and she fell to the
31 floor. A diagnosis of fractured left femoral shaft was made and she underwent an orthopedic repair in
32 a local hospital. After 4 weeks of rehabilitation she was able to return home. However, pain and
33 disability persisted and 10 months after the fracture, she underwent surgical revision of the left
34 femoral repair with replacement of an intramedullary nail. She was started on daily teriparatide
35 subcutaneous 40 mcg doses and completed a 24-month course without further incidence.

36
37 Thereafter she consulted an osteoporosis specialty clinic and was advised to begin denosumab 60mg
38 subcutaneous injections twice yearly, presumably for preservation of her anabolic gains. About 3
39 months after the 4th injection, she fell from a standing height, incurring a periorbital ecchymosis and
40 some left hip pain. She was evaluated by a plain film of her left hip at that time. The film (Fig. 1)
41 shows femoral shaft cortical thickening but no evidence of pelvic or proximal femur fracture.

42

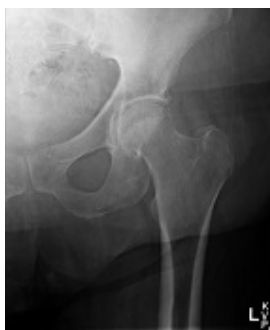

Figure 1

The fifth denosumab injection was given on schedule about 3 months later. At that time, note was taken of the fact that her DXA was “stable”, not “statistically different” compared to a DXA from a year earlier. The patient recalls that at that time she was still having some pain in her left hip but she continued a prescribed program of exercise. Three months later the pain became greater and she sought further evaluation. Figure 2 shows a slightly magnified portion of the plain film made at that time. The radiologist commented on a “suggestion of a slight break in the cortex at the superior lateral aspect of the *left femoral head/neck*” and recommended a CT scan for further evaluation. The CT report said “ There is no boney abnormality to suggest a displaced fracture” and attributed the plain film issue to a small osteophyte at the “lateral superior portion of the femoral head”. In fact the plain film does show a break in the cortex of the lateral femoral shaft below the lesser trochanter which is measurable on a high-resolution image as 127.9 mm below the top of the greater trochanter (Figs.2, 2a). This fracture was missed, but it is relatively easy to discern when, in retrospect,

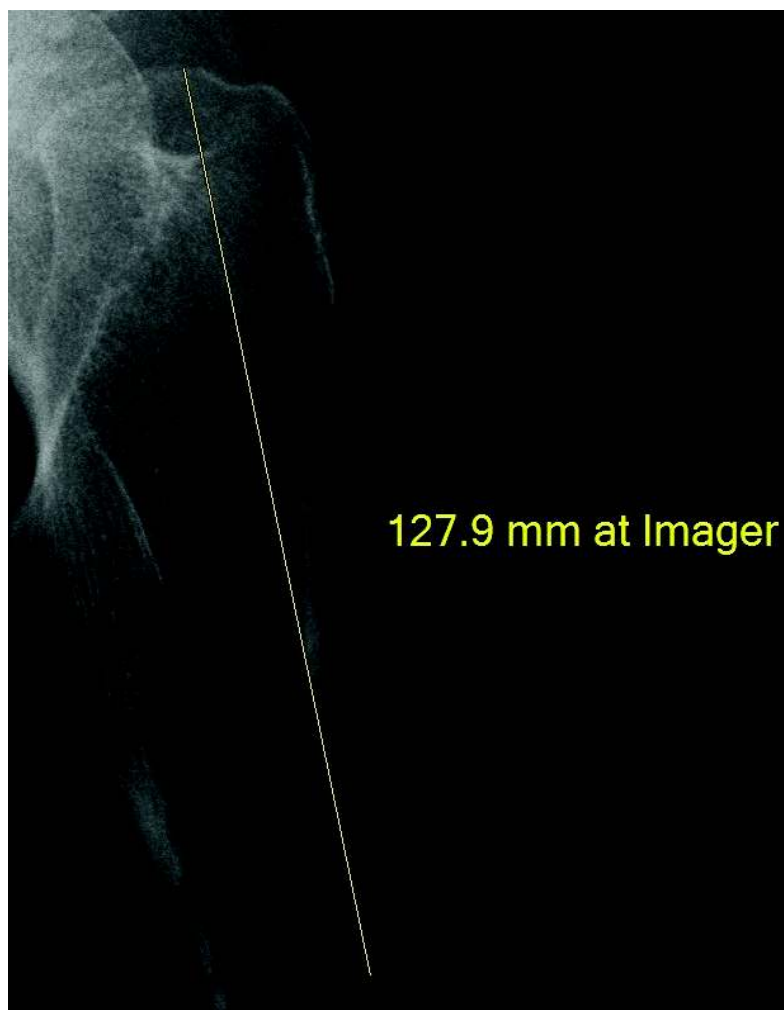


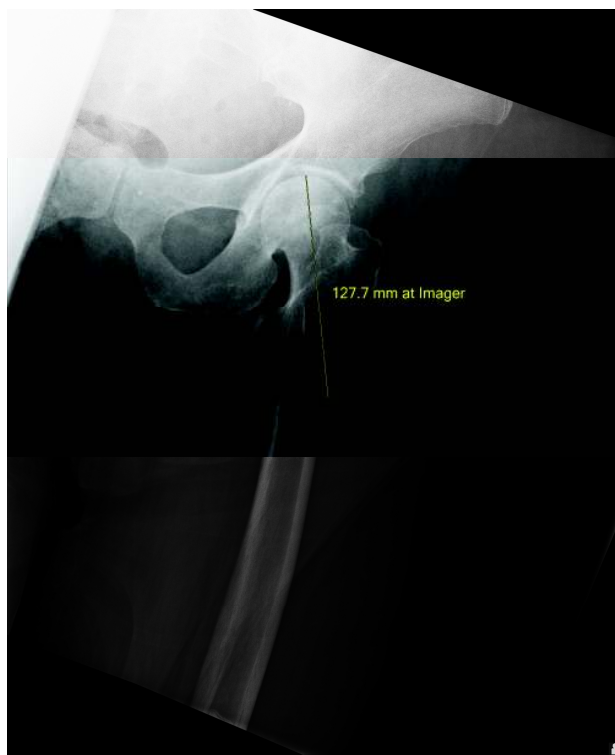Figure 2




Figure 2 a

75 it is compared to a film taken 3 months later when the fracture had progressed to a nearly complete
76 insufficiency fracture meeting the ASBMR definition at the same location (Fig. 3) However, due to the
77 persistence of pain after Fig 2 was assessed and the negative CT reported, another image was
78 obtained by MRI 3 days later and reported as “an acute nondisplaced fracture at the posterior aspect
79 of the proximal femoral shaft”. For some reason, conservative care must have been elected as the
80 next imaging was a plain film six weeks later reporting that “a non-displaced stress fracture is seen
81 through the left proximal femur lying 4.7 cm below the lesser tuberosity”. This is the image shown as
82 Figure 3 and 3a. Figure 3 confirms that the fracture was the same as that which appeared on the
83 earlier X-ray at 127.9 mm below the top of the greater trochanter as a very faint break in the lateral
84 cortex.

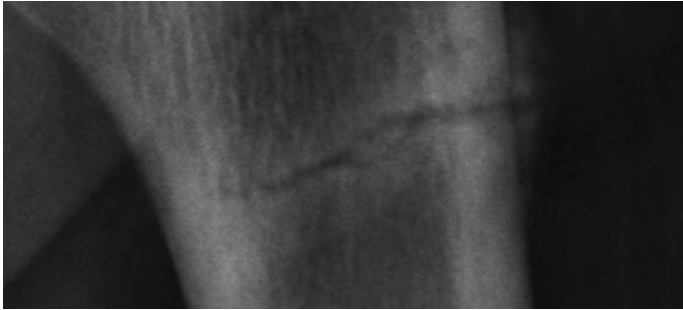
85 The next day an intramedullary nail was placed and the patient had an uneventful recovery. However,
86 because of concerns about the persistence of the antiresorptive effects of her bisphosphonate
87 medication, her doctors recommended beginning the denosumab treatment again. The patient
88 declined this option but began a second course of teriparatide about 6 months after her last femur
89 fracture based on the argument that she was “still fracturing”. She continues on that medication at the
90 time of this publication.



91
92

Figure 3

93



94

95

96

97

98

Figure 3a

99

3. DISCUSSION

100 The authors have participated for years in an international support group which was organized and
 101 led by Jennifer Schneider because of her early recognition [5] with what became known as the AFF.
 102 In 2012, we published a summary of 81 long-term histories of patients with AFFs who were members
 103 of the group [6]. The present membership exceeds 200. The mechanism of action whereby the
 104 bisphosphonate medications may predispose the femur to fracture is a matter of conjecture, debate,
 105 and contention. Perhaps the most persuasive theory has been derived from the general engineering
 106 principles of the strength of materials [7]. In any case, reports of the AFF have continued to
 107 accumulate. To these have been added reports of fractures, morphologically similar to the AFFs
 108 except in location, of bones other than the femur [8]. Our experience with these cases leads us to
 109 recite several of our guiding principles, many of which have been voiced by other clinicians.

110

111 #1. Patients who are taking the strong antiresorptive drugs alendronate, risedronate, ibandronate,
 112 zoledronic acid, and denosumab who complain of pain in the thigh, hip, knee, or back should have
 113 evaluation of the femur on the symptomatic side by MRI. The use of plain film radiographs has proved
 114 inadequate for this purpose [9,10]. Individuals with prostheses which preclude the use of MRI may be
 115 evaluated by isotopic bone scan.

116 #2. Patients who have sustained an AFF who then develop contralateral symptoms should be
 117 assumed to have sustained another AFF until proven otherwise. Again we emphasize that plain film
 118 radiographs are inadequate to exclude a second AFF.

119 #3. The half-life estimate of the persistence of bisphosphonates in cortical bone has been calculated
 120 to be as long as 40 years [11]. Children given IV pamidronate for osteogenesis imperfecta have

measurable renal excretion of the drug for up to 8 years after medication had been discontinued [12]. Once a bisphosphonate-associated fracture has been diagnosed, strong antiresorptive drugs should not be prescribed, as illustrated in the present case. It has been pointed out [13] that some 90% or more of patients treated in some of the so-called osteoporosis centers would have been excluded from osteoporosis clinical trials. Both the bisphosphonates [14] and denosumab [15] carry USFDA-approved warnings about atypical fractures. Surely a person with a prior AFF would not have been considered for a trial of denosumab.

#4 Atypical femoral fractures were documented in the denosumab pivotal trials, which were completed before the drug was given to the present patient [16]. Furthermore, on this industry-sponsored website about the trial, the followed recommendation is made: "During Prolia treatment, patients should be advised to report new or unusual thigh, hip, or groin pain. Any patient who presents with thigh or groin pain should be evaluated to rule out an incomplete femur fracture. **Interruption of Prolia therapy should be considered, pending a risk/benefit assessment, on an individual basis** [our emphasis]." Had this recommendation been followed, the second AFF in this patient might have been avoided. These fractures have also subsequently been reported in person who never took bisphosphonates.

4. CONCLUSIONS

The second fracture this patient incurred meets the precise ASBMR AFF definition, as it resulted from minimal trauma, was located on the femoral shaft below the lesser trochanter, progressed transversely in a medial direction over time, and was not comminuted. A very small zone of localized cortical hypertrophy can be appreciated in Fig. 3a. There was some generalized cortical thickening appreciated in the earlier radiographs and a history of several months of prodromal symptoms. Thus the fracture meets all five of the ASBMR major requirements and at least two of the minor ones. Thus the second fracture was an AFF associated with denosumab, an association which has been reported elsewhere [17,18] as well as in the pivotal trial.

We believe the lessons learned from the case suggest several valuable precautions which should not be ignored in the management of osteoporosis.

On October 13, 2010, the USFDA issued a Drug Safety Communication [19] which effectively summarized these lessons exemplified by this case. Testimony by Jennifer P. Schneider on May 24, 2010 helped prompt this FDA action. We note that this Communication, a portion of which is quoted below, was released at approximately the time that our patient suffered her first AFF.

- “Evaluate any patient who presents with new thigh or groin pain to rule out a femoral fracture.
- Discontinue potent antiresorptive medications (including bisphosphonates) in patients who have evidence of a femoral shaft fracture.”

CONSENT

The authors were originally contacted by the patient requesting information about her fractures. The patient voluntarily and without emolument provided her history and medical records which were used in the preparation of the manuscript and signed a release permitting us to use this information for an anonymous case history.

REFERENCES

1. Odvina CV, Rao DS, Pak CYC, Maalouf N, Zerwekh JE. Adynamic bone disease during bisphosphonate therapy: Should we be concerned? American Society of Bone and Mineral Research Annual Meeting, 2003, Presentation number SU344.
- 2.Odvina CV, Zerwekh JE, Rao DS, Maalouf N, Gottschalk FA, Pak CYC. Severely suppressed bone turnover: A potential complication of alendronate Therapy. J Clin Endocrinol Metab 2006 (3):1294–1301.
3. Shane E, Burr D, Ebeling PR, Abrahamsen B, Adler RA, Brown TD et al. Atypical subtrochanteric and diaphyseal femoral fractures: Report of a task force of the American Society for Bone and Mineral Research. J Bone Miner Res. 2010; 25(11):2267–2294.
- 4.Shane E, Burr D, Abrahamsen B, Adler RA, Brown TD, Cheung A, et al., Atypical subtrochanteric and diaphyseal femoral fractures: Second report of a task force of the American Society for Bone and Mineral Research. J Bone Miner Res 2014;29(1):1-23.
- 5.Schneider JP. “Should bisphosphonates be continued indefinitely? An unusual fracture in a healthy woman on long-term alendronate. Geriatr 2006;61(1):31-33.

- 178 6. Schneider JP, Hinshaw WB, Su C, Solow PJ. Atypical femur fractures: 81 individual personal
179 histories. 2012 J Clin Endocrinol Metab 2012;97(12):4324-4328.
180
- 181 7. Ettinger B, Burr DB, Ritchie RO. Proposed pathogenesis for atypical femoral fractures: Lessons
182 from material research. J Bone Miner Res 2013;55(2):495-500.
183
- 184 8. Cecchetti S, Soubrier M, Grobost V, Malochet-Guinamand S. Atypical insufficiency fractures
185 associated with long-term bisphosphonate therapy: 3 Case Reports. J Bone Biol Osteopor
186 2015;1(1):34-40.
187
- 188 9. Sholnikova J, Flynn J, Choong P. Burden of bisphosphonate-associated femoral fractures. ANZ J
189 Surg 2013;83:175-81.
190
- 191 10. La Rocca Viera R, Rosenberg ZS, Allison MB, Im SA, Babb J, Peck V. Frequency of incomplete
192 atypical femoral fractures in asymptomatic patients on long-term bisphosphonate therapy. Am J
193 Roent 2012; 198:1144-151.
194
- 195 11. Porras AG, Holland SD, Gertz BJ. Pharmacokinetics of alendronate, Clin Pharmacokinet
196 1999;36(5):315-328.
197
- 198 12. Papapoulos SE, Cremers S. Prolonged bisphosphonate release after treatment in children
199 [Correspondence]. N Eng J Med 2007;356(10):1075-76.
200
- 201 13. Watts NB, Lewiecki M, Bonnick SL, Laster AJ, Binkley N, Blank RD, et al. Clinical value of
202 monitoring BMD in patients treated with bisphosphonates for osteoporosis. J Bone Miner Res
203 2009;24(10):1643-1646.
204
- 205 14. See the Recast label including the Medication Guide rev. 4/2013 accessible at
206 http://www.accessdata.fda.gov/drugsatfda_docs/label/2013/021817s015lbl.pdf

207

208 15. See the Prolia label accessible at

209 http://accessdata.fda.gov/drugsat_fda_docs/label/2011/125320s5s61b1.pdf

210

211 16. See the manufacturer's advisory after the Phase 3 trial accessible at: [at:http://proliahcp.com/why-](http://proliahcp.com/why-prolia/phase-3-trial/)

212 [prolia/phase-3-trial/](http://proliahcp.com/why-prolia/phase-3-trial/)

213

214 17. Khaw KSF, Yong KY. Atypical femoral fractures with denosumab. J Bone Miner Metab. Published

215 on-line 05 July 2014. Doi: 10.1007/s00774-014-0606-6.

216

217 18. Thompson RN, Armstrong CL, Heyburn G. Bilateral atypical femoral fractures in a patient

218 prescribed denosumab – a case report. Bone 2014; 61:44-47.

219

220 19. FDA Communication accessible at www.fda.gov/Drugs/DrugSafety/ucm229009.htm