UNDER PEER REVIEW

Original Research Article

Ameliorative Potentials of *Solanum melongena* Linn Fruit Ethanol Extract on Monosodium Glutamate- Intoxicated rats' Lipid Profile, Haematology and Heart Histology

ABSTRACT

Aim: This study evaluated the ameliorative potentials of ethanol extract of Solanum melongena Linn fruit on monosodium glutamate-intoxicated rats' lipid profile, haematological parameters and heart histology using standard protocol. **Methodology**: Twenty four Wistar rats that weighed 105.00 ± 7.00 g. The rats were assigned into six groups and fed thus: Group 1 (control, feed and distilled water only), Group 2 (8000mg/kg body weight MSG), Group 3 (300mg/kg body weight the sample extract), Group 4(8000mg/kg body weight MSG+ 100mg/kg body weight the sample extract), Group 5(8000mg/kg body weight MSG+ 300mg/kg body weight the sample extract) and Group 6(8000mg/kg body weight MSG+ 500mg/kg body weight the sample extract) daily for 14 days. **Place and duration of study**: Department of Veternary Medicine, Michael Okpara University of Agriculture, Umudike, Nigeria and National root crop research institute, umudike, Abia state Nigeria, between May and June, 2016. **Results**: There were significant (P =.05) increase in total cholesterol, triacylglyceride (TAG), very low density lipoprotein (VLDL) and low density lipoprotein cholesterol (LDL-c) and significantly (P =0.05) decrease in high density lipoprotein cholesterol (HDL-c) in only MSG fed group compared to the control group. Interestingly, MSG co-administration with ethanol extract of solanum melongena Linn fruit for group 4, 5 and 6 showed reduced serum total cholesterol, TAG,VLDL and LDL-c and increased HDL-c. There was no significant (P =.05) difference in the haematological parameters (Red blood cell, hemoglobin and hemacrit) for group 3,4,5,6 and the control group, except for white blood cell count which was significantly (P =.05) reduced in the MSG fed group. The histological results revealed that MSG ingestion in rats induced toxic injuries in their hearts at 8000mg/kg body weight and effects were slowly being ameliorated as the concentration of the ethanol extract of Solanum melongena Linn fruit increased. **Conclusion**: This study confirmed general adverse influence of MSG at a high concentration (8000mg/kg body weight) and demonstrated the ameliorative role of ethanol extract of *Solanum melongena* Linn fruit, notably at 500mg/kg of body weight, on the studier monosodium glutamate-intoxicated biofuntions in rats.

Keywords: *Solanum melongena Linn fruit, MSG –intoxication, lipid profile, haematology and heart histology*.

1. INTRODUCTION

Monosodium glutamate (MSG) is a food additive comprising glutamate, an amino acid, and a sodium salt. MSG is produced through fermentation of molasses [1]. MSG is subject to abuse. MSG has been accepted world wide as a flavor enhancer approves without a daily recommended range as it is generally regarded as a safe product by regulatory bodies. Geha *et al*. [2] reported that the estimated average daily intake per person in industrialized countries ranges from 0.3-1.0g. This report is dependent on individual preference. Another report by Shi *et al. [3]* read that daily MSG consumption ranges from 0.5mg/kg to 3g/kg body weight. Reports indicated that MSG consumption could alter cardiac function [4, 5]. This effect is shown experimentally on animals. However, the actually mechanism has not been fully elucidated. MSG catabolic intermediate could play pivotal role in inducing toxicity in rats [6].

Solanum species (eggplants) belong to the family of *Solanaceae* and the plant genus *Solanum*. *Solanum*

UNDER PEER REVIEW

melongena is an economically important vegetable crop that is widely cultivated in the tropical region and a good source of minerals, vitamins, protein, carbohydrate and moisture [7]. About 25 species have been reported in Nigeria, each based on fruit colour, shape and size [8]. The leaves and fruits serve as vegetables and are used in traditional medicine [9]. *Solanum* species includes *S. tuberosum, S. aethiopicum, S. carolinense, S. lycopersicum, S. macrocarpon* and *S. Nigrum* [8]. *Solanum melongena* fruit is usually cooked to make soup or stew, especially in the southern and western parts of Nigeria [8]. The extracts of *Solanum melongena* were effective against a number of diseases, including high blood pressure, hepatosis and microbes (10;11], and acts as an antioxidant [12], analgesic [13], antidiabetic [14], antipyretic [15], hypolipidaemic agent [16] and as well as blood purifier [17], owing to its phytonutrient content. Hence, the needs to evaluate the possible ameliorative roles of ethanol extract of *Solanum melongena* Linn fruit in MSG- intoxicated animal model in high concentration

The heart as an organ pumps blood through the blood vessels, provide oxygen to the cells and mediate the removal of metabolic waste [18]. Lipid profile parameters are essential in the assessment of the heart function as they reflect the nature of the activities going on the cardiovascular system in relation to lipid/ lipoprotein related causes of cardiovascular diseases; artherosclerosis, hyperlipidaemia, myocardiac infarction etc [18]. Cardiovascular disease is among the leading cause of death in the world. MSG could cause the above mentioned metabolic disorders. Hence the need to investigate the possible ameliorative potentials of ethanol extract of Solanum melongena Linn fruit on MSG intoxicated rats' lipid profile, haematological and heart histological changes. The outcome of the findings will contribute to knowledge that may be viable to the management of diseases related to these bioindicators.

2. MATERIALS AND METHODS

2.1 Plant materials and preparations

Matured egg plant fruits were bought in a local market: Ehere market in Aba, Abia State in the fruiting season of May, 2016. The fruit was identified as Solanum melongena Linn in the Plant Science Department, Michael Okpara University of Agriculture, Umudike, Abia State, Nigeria. The fruits were washed with clean tap water, crushed into smaller pieces using a knife and were sun-dried for two weeks. The sun-dried fruits were milled into powder using a laboratory miller (Author Thomas Lab. mill, crypto Model, USA) and stored in an air tight container.

2.2 Extraction and concentration

The powder (4kg) was immersed in absolute ethanol (98%) for 72 hours with interval shaking. The extract was filtered with No 1 Whatmann filter paper. The filtrate was concentrated using water bath at 60°c and was further dried in an oven set at 50°c. The extract was placed into a sample bottle and stored at a room temperature until it was required for experiment. The ethanol extract of *Solanum melongena* Linn fruit was then dissolved in water and prepared into three different doses (Low dose; 100mg/kg body weight of the extract; Middle dose; 300mg/kg body weight of the extract, High dose; 500mg/kg body weight of the extract) for administration while monosodium glutamate was also dissolved in distilled water to make an aqueous solution. The previous report by Thomas et al [19] formed the basis for the chosen dose of 8000mg/kg body weight MSG for the intoxication of the rats for 14 days.

2.3 Animal study design

Twenty-four adult Wistar rats of mean body weight 105.00 ± 8.00 g, was obtained from the animal breeding unit of the College of Veterinary Medicine, Michael Okpara University of Agriculture, Umudike. The animals were kept in appropriate cages and in a well ventilated room with free access to standard

UNDER PEER REVIEW

feed and clean tap water under room temperature with a 12 hour day/night cycle throughout the period of experiment. All the animals received humane care in accordance with the guidelines of the National Institute of Health, USA for ethical treatment of laboratory animals [20]. This guideline was approved by the ethical committees of the department of Biochemistry and college of Natural science Michael Okpara university of Agriculture, Umudike, Nigeria.

After one week of acclimatization, the animals were randomly grouped into six groups of four animals, as shown in the table below. The rats were fed with Vital feed grower mash and were given water ad libitium during acclimatization and through the exposure duration. The MSG (99% min) FCC grade E621 a product of meihua group, China.

The animals received the treatment as given below;

Group 1: Feed + 1ml/kg body weight of distilled water only.

Group 2: 8000mg/kg body weight of MSG only.

Group 3: 300mg/kg body weight of ethanol extract of *Solanum melongena* Linn fruit.

Group 4: 8000mg/kg body weight of MSG + 100mg/kg body weight extracts of *Solanum melongena* Linn fruit.

Group 5: 8000mg/kg body weight of MSG + 300mg/kg body weight extracts of *Solanum melongena* Linn fruit

Group 6: 8000mg/kg body weight of MSG + 500mg/kg body weight extracts of *Solanum melongena* Linn fruit.

The treatment was per-oral (using orogastric tube) and was administered daily for 2 weeks (fourteen days).

2.4 Blood and organ harvesting for histological studies

The rats were sacrificed on the 15th day after overnight fast by decapitation and the blood sample collected respectively into clean heparin bottles for hematological study and polystyrenes tubes. The blood in the polystyrene tubes were centrifuged at 4000rpm for 10minutes respectively and the respectively sera were used for the lipid profile assessment. The heart was excised and the histological examinations of the heart were done using the method of Drury et al. [21].

2.5 Determination of serum total cholesterol

Serum total cholesterol concentration was determined using the method of Allain *et al*. [22]. The method is based on the principle that total cholesterol is determined after enzymatic hydrolysis and oxidation of cholesterol to free fatty acids by cholesterol esterase and to cholest-4-en-3-one and hydrogen peroxide by cholesterol oxidase. The hydrogen peroxide combines with 4-aminoantipyrine to form a chromophore (quinoneimine dye). The absorbance is read at 505 nm using labomed spectrophotometer Model UV-2502.

2.6 Determination of serum triacylglycerol concentration

Serum triacylglycerol concentration was determined using the method of Albers *et al*. (1978). This method is based on the principle that triglycerides are determined after enzymatic hydrolysis with lipases. The

UNDER PEER REVIEW

indicator is a quinoneimine formed from hydrogen-peroxide, 4-aminophenazone and 4-chlorophenol under the catalytic influence of peroxidase.. the absorbance is read at 540nm using labomed spectrophotometer Model UV-2502.

2.7 Determination of serum high density lipoprotein-cholesterol concentration

Serum HDL-cholesterol concentration was determined using the method of Albers *et al*. [23]. This method is based on the principle that low density lipoprotein (LDL-c) and very low density lipoproteins (VLDL) are precipitated from serum by the action of polysaccharide in the presence of divalent cation. Then, high density lipoprotein-cholesterol (HDL-cholesterol) present in the supernatant is determined. The HDL-cholesterol is then measured using labomed spectrophotometer Model UV-2502 by means of the coupled reaction.

2.8 Determination of serum Low density lipoprotein-cholesterol concentration

According to the Friedeward formula [24].

LDL-Cholesterol =

$$\frac{\text{Total cholesterol - HDL-c - TAG}}{5}$$

2.9 Determination of serum very low density lipoprotein-cholesterol concentration

According to the Friedeward formula [24].

VLDL-Cholesterol = TAG/5

2.10 Determination of haematological parameters using impedance method on Diatron Abacus Junior haematology analyzer

Diatron Abacus Junior Haematology Analyzer was used for the haematological analysis. This machine operates by Impedance method for the determination of volume and number of cells. In this method a known volume of dilution is drawn through a small aperture. Constant current is passed through the aperture from one side to the other. When a cell passes through the aperture, it causes a change in resistance, which generates a voltage pulse. The amplitude of the voltage pulse is proportional to the ratio of cell volume per aperture volume. This is used to determine the volume of cells. The number of cells can be obtained by counting the pulses. In the instruments there is one cell-counter probe: the aperture size is 80 µm and has a reference electrode assembly.

2.11 Statistical Analysis

Collected data were subjected to statistical Analysis of Variance (ANOVA) with the statistical package for social sciences (SPSS) for Windows version 22.0. The Duncan post hoc test was used to identify the means that differ significantly at P=.05. Results were expressed as Mean ± standard error of the mean (SEM).

UNDER PEER REVIEW

3. RESULTS AND DISCUSSION

Table 1: Effects of daily treatment of rats with mono-sodium glutamate and ethanolic extract of *Solanum melongena* Linn fruit on some lipid profile parameters

PARAMETERS	TOTAL CHOL (mg/dl)	TAG (mg/dl)	HDL-C (mg/dl)	LDL-C (mg/dl)	VLDL-C (mg/dl)
Group 1 (Feed + water)	67.59±3.69	92.84±1.63	12.45±0.41*	39.69±0.70	18.57 ± 0.33
Group 2 (8000mg/kg bw MSG)	80.14±1.70*	113.54±2.83*	7.41±0.18	47.55±2.13*	22.71 ± 0.57*
Group 3 (300mg/kg bw Extract)	70.76±1.53	92.94±2.10	12.23±0.12*	38.03±0.58	18.56 ±0.42
Group 4 (8000mg MSG + 100mg/kg bw Extract)	69.59±2.04	95.81±2.21	12.04±0.32*	39.03±1.36	19.16 ±0.44
Group 5 (8000mg MSG + 300mg/kg bw Extract)	73.16±1.17	92.09±1.71	12.49±0.44*	37.56±0.45	18.42 ±0.34
Group 6 (8000mg MSG + 500mg/kg bw Extract)	75.11±2.30	86.32±2.71	12.75±0.15*	35.31±1.02	17.26 ±0.54

Values are expressed as mean ± SEM for four replications. *values are significantly different at ($P<0.05$).

The determination of the serum cholesterol concentration, serum TAG concentration and serum LDL concentration in Table 1 revealed that rats fed with MSG alone (group 2) with 80.14±1.70mg/dl, 113.54±2.83mg/dl and 47.55±2.13mg/dl respectively are significantly higher ($P<0.05$) compared to the group 3, 4, 5, 6 (which were either fed with ethanol extract and/or with MSG) and the control group while the serum HDL decreased significantly ($P<0.05$) in the same group 2 (7.41±0.18mg/dl) compared to the group 3,4,5,6 and control group. Furthermore, the data for group 3, 4, 5 and 6 showed no significant differences ($P\leq0.05$) among them.

UNDER PEER REVIEW

Table 2: Effects of daily treatment of rats with mono-sodium glutamate and ethanolic extract of *Solanum melongena* Linn fruit on some haematological parameters

PARAMETERS	WBC ($\times 10^9$ cell/L)	RBC ($\times 10^{12}$ cell/L)	HGB (g/l)	HCT (%)
Group 1 (Feed + water)	10.19±0.92*	6.99±0.10	127.00±2.80	41.19±1.07
Group 2 (8000mg/kg bw MSG)	8.44±0.30	7.00±0.32	123.75±5.09	39.98±2.05
Group 3 (300mg/kg bw Extract)	12.55±0.78*	7.64±0.25	121.75±4.87	39.26±1.05
Group 4 (8000mg MSG + 100mg/kg bw Extract)	10.45±1.26*	7.49±0.26	129.75±3.88	41.32±1.08
Group 5 (8000mg MSG + 300mg/kg bw Extract)	12.81±1.67*	7.22±0.09	123.5±1.66	40.57±0.92
Group 6 (8000mg MSG + 500mg/kg bw Extract)	11.72±1.44*	6.99±0.16	118.75±1.49	37.90±0.94

Values are expressed as mean ±SEM for four replications. *values are significantly different at ($P<0.05$). The haematological assessments of the rats fed groups presented in Table 2 above revealed no significant difference ($P>0.05$) for the RBC ($\times 10^{12}$ cell/L), HGB (%) and HCT (%) except for WBC($\times 10^9$ cell/L) which showed significant ($P<0.05$) decrease for the group 2 (8.44±0.30 10^9 cell/L) compared to the group 3,4,5,6 and the control group which recorded ranges of 10.19±0.92 ($\times 10^9$ cell/L) to 12.81±1.67 ($\times 10^9$ cell/L).

UNDER PEER REVIEW

3.1 Histological changes ((H&E × 400)

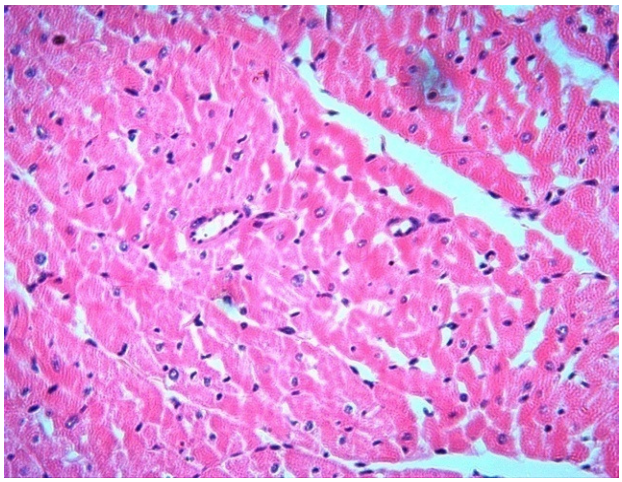

Plate1: Photomicrograph of the **heart** section of rats in normal control (Group 1), showing compact myocardial muscle bundles with thin fibrocollagenous stroma and narrow lumina blood vessels.

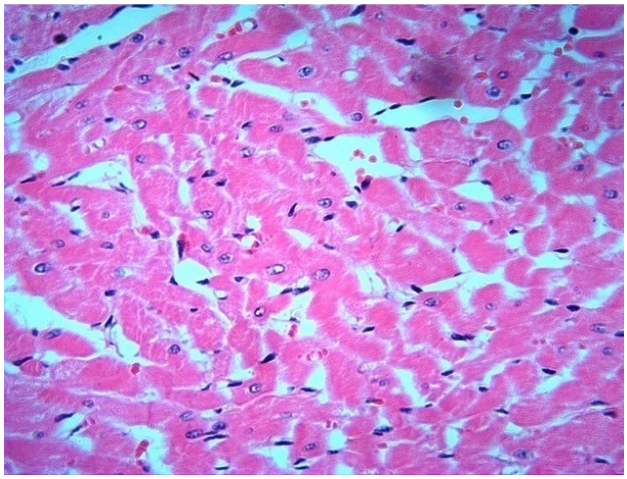

Plate 2: Photomicrograph of the **heart** section of rats treated with MSG (Group 2) showing compact myocardial muscle bundles with thick fibrocollagenous stroma, mild plumpy myocytes and narrow lumina blood vessels lined by endothelial cells.

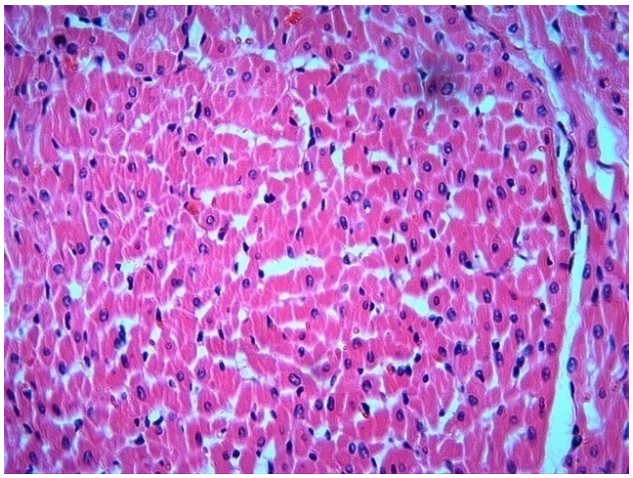

Plate 3: Photomicrograph of the **heart** section from rats treated with plant extract (Group 3) showing loosely arranged myocardial muscle bundles with thin fibrocollagenous stroma. The myocytes are plumpy with narrow lumina blood vessels lined by endothelial cells.

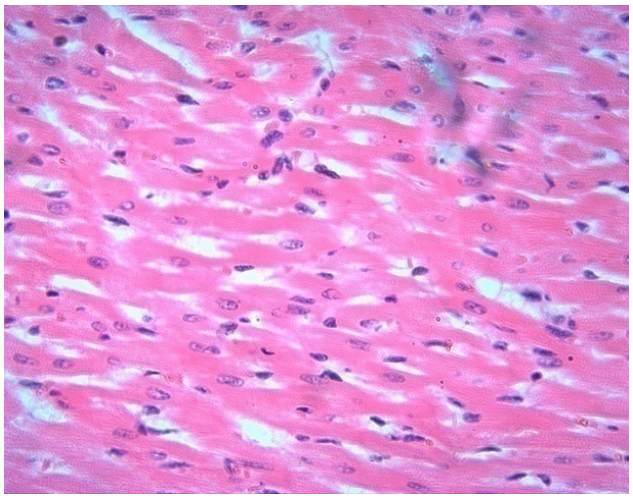

Plate 4: Photomicrograph of the **heart** section from rats treated with MSG and 100mg/kg of the plant extract (Group 4) showing compact myocardial muscle bundles with thick fibrocollagenous stroma. The myocytes are mildly plump with narrow lumina blood vessel lined by endothelial cells.

UNDER PEER REVIEW

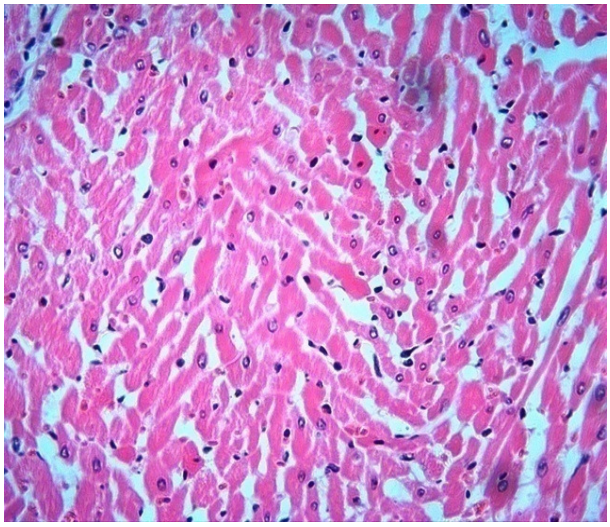

Plate 5: Photomicrograph of the **heart** section from rats treated with MSG and 300mg/kg of the plant extract (Group 5) showing compact myocardial muscle bundles with thick fibrocollagenous stroma. The myocytes are plump and narrow lumina blood vessel lined by endothelial cells.

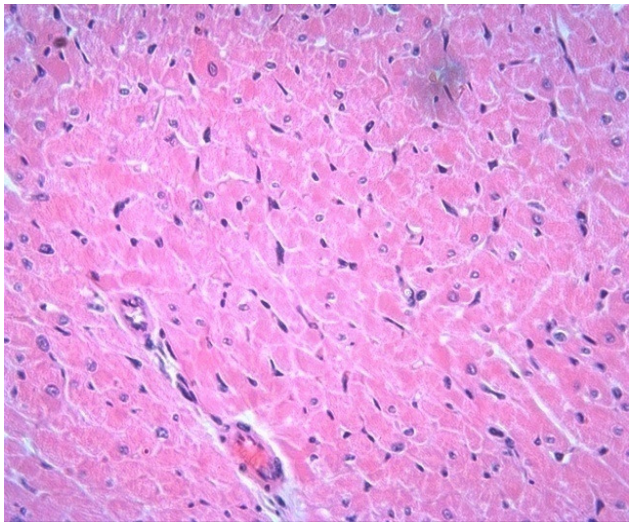

Plate 6: Photomicrograph of the **heart** section from rats treated with MSG and 500mg/kg of the plant extract (Group 6) showing loosely arranged myocardial muscle bundles with thin fibrocollagenous stroma. The myocytes are mildly plump with narrow lumina blood vessel lined by endothelial cells.

MSG treatment for 2 weeks significantly (P=.05) increased the cholesterol, TAG and LDL-cholesterol concentration, as shown in Table 1, an apparent indication that cholesterol metabolism was altered. These increases may lead to cardiovascular diseases (CVD) on the rats [4]. However, this study revealed an increased TAG concentration compared cholesterol in all the groups. TAG is the more concentrated form of energy storage and circulates in the plasma via lipoproteins (very low density lipoprotein (VLDL))/ or in lipid droplets or both. This elevation implies that TAG and Cholesterol in MSG treatment groups may have shifted their energy source from glucose to other sources (gluconeogenesis) possibly lipogenesis. This suggests an impairment of VLDL to transport TAG which may lead to hyperlipidemia and concomitant reduction in cholesterol level [25], and may have resulted from MSG-induced physiological stress. Again, increase in 5-hydroxy-3-methylglutaryl-Coenzyme A (HMG-CoA) reductase: the rate determining enzyme in biosynthesis of cholesterol and/or a decrease in cholesterol catabolism that may result to alteration in bile production [26]. Furthermore, there is a significant (P =.05) increase in LDL-cholesterol. This suggests an increased risk of CVD as associated with artherosclerosis [27]. This implies that MSG feed rats would be at risk of CVD. This may have occurred via induced alterations in metabolic organs (heart). Interestingly, the extract at 500mg/kg bw appears to have shown the best ameliorative results among the experimented doses. This result is comparable to the findings reported by Azab et.al. [26] on sodium nitrate induced hyperlipidemia in guinea pig. A significant (P =.05) decrease in HDL-cholesterol was observed for the MSG fed group compared to the control group. However, a marked increase was observed for group 3, 4, 5 and 6 compared to group 2. This suggests that the plant extract posses the potentials to reduce the risk of artherosclerosis. This could be attributed to its antioxidant potential to scavenge free radical that may be generated during cholesterol metabolism. This reduction may have been through the ability of increased HDL-c to transport cholesterol away from the heart to the liver were it is broken down to bile [4].

UNDER PEER REVIEW

Haematological studies are useful in the diagnosis of many diseases and in determining the physiological status of animals [28]. From the results in Table 2 in this study, no significant difference (P =.05) was observed for red blood cell count (RBC), haemoglobin (HGB) and haemacrit (HCT). MSG and the extract did not cause any observable changes in the rats as it appears. The function of RBC to transport oxygen via haemoglobin was not interfered with. Again, the iron content of *Solanum melongena* Linn fruit as reported by Agoreyo et al. [7], may have played physiological roles in the maintenance of RBC, HCT and HGB in the rats fed groups. Furthermore, the ethanolic extract could have blood purifying potentials [17]. This is in line with the report by Elatrash and El-haleim, [29], on protective role of Ginkgo biloba on MSG-induced liver and kidney toxicity in rats.

For the serum WBC, the results were significantly (P=.05) different for the MSG group compared to the control group. This suggests that MSG may have induced significant toxic effect that altered the immune function of the Wistar rats. This finding agrees with the reported findings by Egbuonu et.al. [30] on sub-chronic esculetin-induced alteration in some haematological parameter. Again, previous studies on MSG induced toxicity in rats have shown reduced WBC count for the MSG feed groups [29;31]. The group 3, 4, 5 and 6 showed an increased concentration for WBC compared to group 2. This reveals an interestingly outcome as the extracts appears to improve immune response to fight infection and defend the body against invasion by foreign organisms and thus, improves wellbeing.

The histological results provided insight into the oxidative stress condition that may have affected the examined organs (heart). In the present study photomicrographs revealed distorted compact myocardial muscle bundles with thick fibrocollagenous stroma, mild plumpy myocytes and narrow lumina blood vessels lined by endothelial cells in plate 2 compared to plate 1, 3,4,5 and 6. This result is comparable to the study by Zahkouk et. al. [32], on the physiological and histological studies on the heart of male albino rats exposed to electromagnetic field and the protective role of silymarin and/or vitamin e. The mild plump observed in this study may be due to increased total cholesterol, TAG and possibly LDL-c oxidation. The thick fibrocollagenous stroma observed could have resulted from the decreased in the synthesis of fibrocollagenases [33]. However, these effects were ameliorated gradually upon administration of ethanol extract of *Solanum melongena* Linn fruit.

CONCLUSION

This study confirmed general adverse influence of MSG at a high concentration (8000mg/kg body weight) and indicated the ameliorative role of ethanol extract of *Solanum melongena* Linn fruit notably at 500mg/kg of body weight in rats. Thus, ethanol extract of *Solanum melongena* Linn fruit may be useful in the management of MSG intoxication related to the studied parameters in the rats, warranting further studies.

ETHICAL APPROVAL

The procedure for this study was in accordance with the guidelines on the care and wellbeing of research animals (NIH, 1985) and was approved by the Ethics Committee of Department of Biochemistry, Michael Okpara University of Agriculture, Umudike,Nigeria.

UNDER PEER REVIEW

REFERENCES

1. Walker R, Lupien JR. The safety evaluation of monosodium glutamate. J Nutrition. 2000;130: 1049-1052.

2. Geha RS, Beiser A, Ren C, Patterson R., Greenberger PA,Grammer LC. Review of alleged reaction to monosodium glutamate and outcome of a multicenter double-blind placebo-controlled study. J Nutrition. 2000; 130(4): 1058-1062.
3. Shi Z, Luscombe-Marsh ND, Wittert GA, Yuan B, Dai Y, Pan X, Taylor AW. Monosodium Glutamate is not associated with obesity or a greater prevalence of weight gain over 5 years: findings from the Jiangsu Nutrition Study. British Journal of Nutrition. 2010;104 (3):457-463.

4. Egbuonu ACC, Osakwe ON. Effects of high monosodium some serum markers of lipid status in male wister rats. Int J Med Med Sci. 2011; 2(1):653-656.

5. Sharma V, Deshmukk R. Ajimomoto (MSG): a fifth taste or bio bomb. Euro J Pharma Med Res 2015; 2(2): 381-400.

6. Egbuonu ACC, Oriji OS. Pulverized mangifera indica (mango) seed kernel mitigated monosodium glutamate-intoxicated rats' kidney histology and bio-functions. J Nut Health Food Sci. 2017;5(1):1-7.

7. Agoreyo BO, Obansa ES, Obanor EO. Comparative nutritional and phytochemical analysis of two varieties of Solanum melongena. Sci World J. 2012; 7(1): 5 – 8.

8. Chinedu SN, Olasumbo AC, Eboji OK, Emiloju OC, Arinola OK, Dania DI. Proximate and phytochemical analysis of Solanumaethiopicum L andSolanum macrocarpon L. fruits. Res J Chem Sci.2011; 1: 63-71.

9. Bonsu KO, Fontem DA, Nkansah GO, Iruome RN, Owusu EO, Schippers RR. Diversity within the gboma eggplant (Solanum marcocarpon), an indigenous vegetable from West Africa. Ghana J Horticulture. 2008; 1:50-58.

10. Magioli C, Mansur E. Eggplant (Solanum melongena L.): Tissue culture, genetic transformation and use as an alternative model plant, Acta Botanica Brasilica.2005; 19(1):139-148.

11. Amutha S. Screening of antibacterial activity of Solanum melongena seed extracts on selected human pathogenic bacteria. *Int J Pharma Bio* Sci. 2014; 5(4):208 - 213.

12. Umesh KK, Vijay KB, Nikunj KB, Neha PB, Baljibhai AG. Antioxidant and nutritional components of egg plant (Solanum melongena L) fruit grown in Saurastra region. Int J Curr Microbiol Applied Sci. 2015; 4(2): 806-813.

13. Ashish, S. and Yadav, S.(2011). Analgesic activity of root extract of Solanum melongena Linn root. Int J Res Ayurveda Pharma. 2011; 2(5): 1615 – 1617.

UNDER PEER REVIEW

14. Kwon YI, Apostolidis E, Shetty K. In vitro studies of eggplant (Solanum melongena) phenolics as inhibitors of key enzymes relevant for type 2 diabetes and hypertension. Bioresource Technology. 2007; 99(8): 2981- 2988.
15. Srivastava A, Yadar S. Analgesic activity of root extract of Solanum melongena Linn fruit. Int J Res Ayurveda Pharmacy. 2011; 2(5)1615 – 1617.

16. Ossamulu IF, Akanya HO, Jigam AA, Egwin EC, Adeyemi HY. Hypolipidemic properties of four varieties of egg plants (Solanum melongena L.). Int J Pharma Sci invention. 2014; 3(8): 47-54.

17. Gracelin DHS, Britto AJ, Stephan RTL, Rathnakumar PBJ. Assessment of genetic relationships among five species of Solanum as revealed by RAPD markers. Life Sci Leaflets. 2011; 19: 809 – 814.

18. Marieb EN, Hoehn K. Human Anatomy and Physiology.9th ed. San Francisco, CA: Pearson; 2013.

19. Thomas M, Sujatha KS,George S. Protective effect of Piper longum Linn on monosodium glutamate induced oxidative stress in rats. Indian J Exp Biol. 2009; 47:186-192.

20. National Institute of Health, Office of Laboratory Animal Welfare health research extension act. "animals in research";1985.

21. Drury RAB, Wallington EA, Cameron R. Carleton's Histological Techniques. 4th ed, Oxford University Press, NY, USA; 1967.

22. Allain CC, Poon IS, Chan CHG, Richmond W, Fu PC. Enzymatic determination of serum total cholesterol. Clin Chem. 1974; 20: 470- 471.

23. Albers JJ, Warmick GR, Cheng MC. Determination of high density lipoprotein (HDL)–cholesterol. Lipids. 1978; 13:926-932.

24. Friedeward W, Levy J, Fredrickson DS. Estimation of the concentration of low density lipoprotein cholesterol in plasma, without use of the preparative ultracentrifuge. Clin Chem.1972; 18: 499-502.

25. Lernandez M, Webb D. The LDL to HDL cholesterol ratio as a valuable tool to evaluate coronary heart disease risk. J Am Col Nutrition. 2008; 27, (1): 1-5.

26. Azab AE, Lashkham NM, Albasha OM. Haemato-protective and hypolipidemic effects of aqueous extract of Libyan propolis against sodium nitrite induced haematotoxicity and hyperlipidemia in guinea pigs. Am J Biosci Bioeng. 2015; 3(4): 22-32.

27. Egbuonu ACC. Sub-chronic concomitant ingestion of L-arginine and monosodium glutamate improves feed efficiency, lipid metabolism and antioxidant capacity in male Wistar rats. Pakistan J Biol Sci. 2012; 15(6):301–5.

28. Khan TA, Zafar F. Haematological study in response to varying doses of estrogen in broiler chicken. Int J Poultry Sci. 2005; 4(10): 748-751.

UNDER PEER REVIEW

29. Elatrash AM, El-Haleim SZ. Protective role of ginkgo biloba on monosodium glutamate: induced liver and kidney toxicity in rats. Res J Pharma Biol Chem Sci. 2015; 6(1): 1433-1441.

30. Egbuonu ACC, Ogbu AE, Ijeh II, Ezeanyika LUS. Sub-chronic esculetin (6,7-Dihydroxy-Coumarin)-induced alteration in some haematological and serum parameters in normal male wistar rats. Asian J Biochem. 2015; 10 (6): 306-311.

31. Anwar MM, Mohamed NE. Impact of flax seed and canola oils mixture supplementation on the physiological and biochemical changes induced by monosodium glutamate in rats. J Rad Res Applied Sci. 2010; 3(3B): 943-964.

32. Zahkouk SA, El- Gendy AM, Eid AF, El-Tahway AN, El-Shamy SA. Physiological and histological studies on the heart of male albino rats exposed to electromagnetic field and the protective role of silymarin and/or vitamin E. Eygptian J Hospital Med. 2015; 58: 94 – 108.

33. George F, Zohar K, Harinder PS, Klaus MB. The biological action of saponins in animal systems: a review. British Journal of Nutrition 88: 587–605. George, F., Zohar, K., Harinder, P.S, Klaus, M.B.(2002). The biological action of saponins in animal systems: a review. British J Nutrition. 2002; 88: 587–605.