Original Research Article

Growth Factor Receptors and Liver Injury

ABSTRACT

Aims: The aim of this study is to investigate the expression pattern of transforming growth factor β receptor I(TGFβRI) and fibroblast growth factor receptor 3 (FGFR3) at the different stages of liver injury including acute injury, fibrosis and cirrhosis

Study design: Controlled experiment

Place and Duration of Study: Department of Biochemistry and Department of Pharmacology and Toxicology, Faculty of pharmacy (boys) Al-Azhar University, between February 2015 and June 2015.

Methodology: Four Sprague-Dawley rats groups were used for the experiment. **Control group**:9 rats received corn oil; **acute toxicity group**: 10 rats were injected 50 % CCl_4 in corn oil (4 ml/kg/IP/single dose); **6weeks group**:12rats were injected with 50% CCl_4 in corn oil (4 ml/kg/IP/twice weekly/6weeks); **11weeks group**: 10 rats were injected with 50 % CCl_4 in corn oil (4 ml/kg/IP/twice weekly/6 weeks) followed by 5 weeks of CCl_4 treatment with the half previous dose

On the day after the last dose, rats were anesthetized with diethyl ether and blood samples were collected for measurement of blood chemistry. The animals then were euthanized, and tissue samples from the livers were harvested and divided into 2 parts; one part was processed for standard histology and immunofluorescence techniques and the other was homogenized for oxidative status assessment.

Results: TGFβRI and FGFR3 were shown to be upregulated in chronic liver injury including stages of fibrosis and cirrhosis. While TGFβRI was shown to be located mainly in the cell membrane; the cytoplasm was shown to be the main site for FGFR3 expression.

Conclusion: TGFβRI and FGFR3 were suggested to be of critical importance in pathogenesis of chronic liver injury so they may be used as a target for chronic liver injury therapy and/or candidate marker for diagnosis and/or prognosis of chronic liver injury.

Keywords: TGFβRI, FGFR3, fibrosis, cirrhosis

1. INTRODUCTION

Liver plays a limitless role in the preservation and body homeostasis regulation. It is included in most biochemical pathways to growth, protection against disease, nutrient fund, energy facility and reproduction (1).Hepatotoxicity can be generated by certain common causes including therapeutic agents, natural chemicals, laboratory and manufacturing agents and herbal therapies (2).

Carbon tetra chloride (CCl_4) is one of the most communal models for inducing hepatotoxicity. It is transformed into a toxic CCl_3^- radical by hepatic cytochrome P4502E1 (CYP2E1).Thus; it brings an acute Centro-lobular necrosis which starts a wound healing response (fibrosis) (3). However, Contact to these chemicals in humans is rare and generally occurs in the manufacturing during fabrication and in places where these chemicals is usually used (4).

Transforming growth factor β receptors (TGF-βRs) are of 2 types TGF-βRI and TGF-βRII. They mediate hepatic stellate cell (HSC) activation (5) after binding to their ligand cytokine TGFβ, the profibrogenic cytokine that traditionally have been considered the key fibrogenic stimulus to HSC (6).

Fibroblast growth factor receptor 3 (FGFR3) is involved in cell growth control, cell differentiation, and migration (7).There are many reports that indicated the involvement of FGF/ FGF receptor (FGFR) signalling in the progression liver diseases including fibrosis (8;9)and hepatocellular carcinoma (10-13).

.The aim of this study was to investigate the expression pattern of TGFβRI and FGFR3 at different stages of liver injury. This aspect of study was verified by investigation of the localization of these proteins in different liver injury stages.

2. METHODOLOGY

2.1. Animal model.

Adult male Sprague-Dawley rats weighing 250–300 g and aging 70 days were used in the current study. The animals were obtained from the breeding colony maintained at the animal house of the Nile Company for pharmaceuticals, Cairo, Egypt. They were housed in the animal facility of Faculty of Pharmacy, Al-Azhar University in 20 X 18 X 25 cm plastic cages with stainless steel wire lids and mesh floor with 5 animals per cage. They were kept at 23±1 °C, at 55 % relative humidity, with 12:12-h light: dark cycle, and maintained on a standard rodent chow (El-Nasr Company, Abou-Zaabal, Cairo, Egypt), and allowed to food and water *ad libitum*. Animals were randomly divided into four groups: **control group**: 9 rats: receiving corn oil (2ml/kg/twice weekly/IP) ; **acute toxicity group**: 10 rats were injected 50 % CCl_4 in corn oil (4 ml/kg/IP/single dose)(14) ; **6weeks group**:12rats were injected with 50% CCl_4 in corn oil (4 ml/kg/IP/twice weekly/6weeks) and finally **11weeks group**: 10 rats were injected with 50 % CCl_4 in corn oil (4 ml/kg/IP/twice weekly/6 weeks) followed by 5 weeks of CCl_4 treatment with the half previous dose. At the end of experimental period; rats were anesthetized with diethyl ether and blood samples were withdrawn from ocular vein for measurement of blood chemistry. The animals then were euthanized, and tissue samples from the livers were harvested and divided into 2 parts; one part was processed by standard histology and immunofluorescence techniques and the other was homogenized in 0.15 M KCl for MDA and SOD assay. All animal procedures were performed in accordance with the international guide for the care and use of laboratory animals (15)

2.2. Antibodies and chemicals.

Rabbit polyclonal TGFβRI and FGFR3 antibodies were purchased from Santa Cruz Biotechnology (CA, USA). Cy3-conjugated goat anti-rabbit antibody was purchased from Jackson Immunoresearch (PA, USA). 4,6- Diamidino-2- phenyl indole (DAPI). CCl_4 was purchased from Sigma-Aldrich (MO, USA).

2.3. Biochemical analysis.

Serum enzymatic activities of transaminases (ALT and AST) were estimated by kinetic method according to the method of international federation of clinical chemistry (IFCC) (16;17). Alkaline phosphatase (ALP) activity was assay according to the method of IFCC(18-20) and serum albumin concentration according to the method described by Gendler (21). The liver homogenate was used for the determination of the oxidative stress parameters. The level of thiobarbituric acid-reactive substances (measured as malondialdehyde (MDA) was determined as described by Mihara and Uchiyama (22). The activity of SOD was determined using the method described by Marklund (23).

2.4. Immunofluorescence analysis.

Slides containing liver tissues sections were handled according to method described by Abdel-Bakky and his associates (24). The primary TGFβRI and FGFR3 antibodies were diluted in

blocking solution in the suitable dilution (1:400) and left overnight in 4 °C. Secondary antibody (cyanine red conjugated) diluted in the blocking solution was incubated for 30 min and the nuclei were counterstained using DAPI. Finally, all slides were mounted with the fluoromount solution, covered by covering slips, and allowed to stand for detection by immunofluorescence microscope (Leica DM 5500B).

2.5. Statistical analysis.

Data were presented as the mean ±SE. Statistical analysis was performed using one-way analysis of variance (ANOVA) followed by Tukey-Kramer as a post hoc test, according to the number of groups. The 0.05 level of probability was used as the criterion of significance using GraphPad Prism software version 5 (GraphPad Software Inc, CA, USA).

3. RESULTS

3.1. LIVER FUNCTIONS AND OXIDATIVE STATUS ASSESSMENT.

To assess liver functions; we have performed liver function tests including serum transaminases, ALP, and albumin. The oxidative status of liver tissues was determined through MDA and SOD assay as indicated in **CCl4 treated** groups showed significant decrease in SOD activities.

Table 1.

As indicated in **CCl4 treated** groups showed significant decrease in SOD activities.

Table 1; Serum ALT and AST activity of control group rats were 46.6±2.85 and 54.1±2.65 respectively. Administration of I.P. CCl_4 significantly elevated serum transaminases activities whatever the duration of administration.

As shown in **CCl4 treated** groups showed significant decrease in SOD activities.

Table 1; ALP activity of control group rats was 312±21.9 (IU/L). It showed significant elevation only in chronic administration of CCl_4 with minimal change in single dose CCl_4 treatment.

Serum albumin of control group was 3.81±0.08 g/dl. The significant decrease observed only with 11 weeks CCl_4 treatment as shown in **Table 1**

As shown in **CCl4 treated** groups showed significant decrease in SOD activities.

Table 1; the tissue MDA content of control group was 4.73±0.318 nmol/g tissue. This content was significantly increased on CCl_4 treated groups whatever the duration of administration.

CCl4 treated groups showed significant decrease in SOD activities.

Table 1 shows the M ± SEM for SOD of studied groups. The control group showed tissue SOD activity of 526±25.2 U/mg tissue. CCl_4 treated groups showed significant decrease in SOD activities.

Table 1: Liver functions and oxidative status assessment tests.

	ALT(IU/L)	*AST(IU/L)*	*ALP(IU/L)*	*Albumin(g/dl)*	*MDA(nmol/g tissue)*	*SOD(U/mg tissue)*
Control	46.6±2.85	54.1±2.65	312±21.9	3.81±0.08	4.73±0.318	526±25.2
CCl_4 single I.P. dose	294±11.9[(a)(b)]	419±11.0[(a)]	395±11.1 [(b)]	3.8±0.06[(b)]	23.7±2.35[(a)(b)]	308±8.05[(a)(b)]

CCl_4 weeks I.P.	**6**	349±13.4[(a)]	436±15.4[(a)]	570±24.5[(a)]	3.39±0.13	31.9±1.44[(a)]	223±14[(a)]
CCl_4 weeks I.P.	**11**	298±8.48[(a)]	368±13.4[(a)(b)]	790±24.9[(a)(b)]	2.69±0.07[(a)]	38.1±1.74[(a)]	171±6.57[(a)]

Data are expressed as mean ± SEM
(a) Significantly different from control group
(b) Significantly different from 6 weeks CCl_4 group using one-way ANOVA followed by Tukey-Kramer test for multiple comparison test at $P \leq 0.05$

3.2. EXPRESSION AND LOCALIZATION OF TGFBRI.

Figure 1 shows that TGFβR1protein showed minimal expression in normal liver tissues and also in acute toxicity model. The expression was increased on conversion of toxicity from acute to chronic with maximal expression in 6 and 11 weeks groups. As indicated in **Graph 1** ; it was noted that the expression increased by about 146% in 6 weeks CCl_4 treatment group and by 55 % in 11 weeks CCl_4 treatment group. It was also observed that the expression is located in the cell membrane of epithelial hepatic tissue in areas that shows lesions. On the other hand; it appears as intense area filling the cytoplasm extending along the fibrous septa and surrounding the cirrhotic nodule in areas that show high density of fibroblastic cells. On the other hand there was also minimal expression inside the cirrhotic nodule.

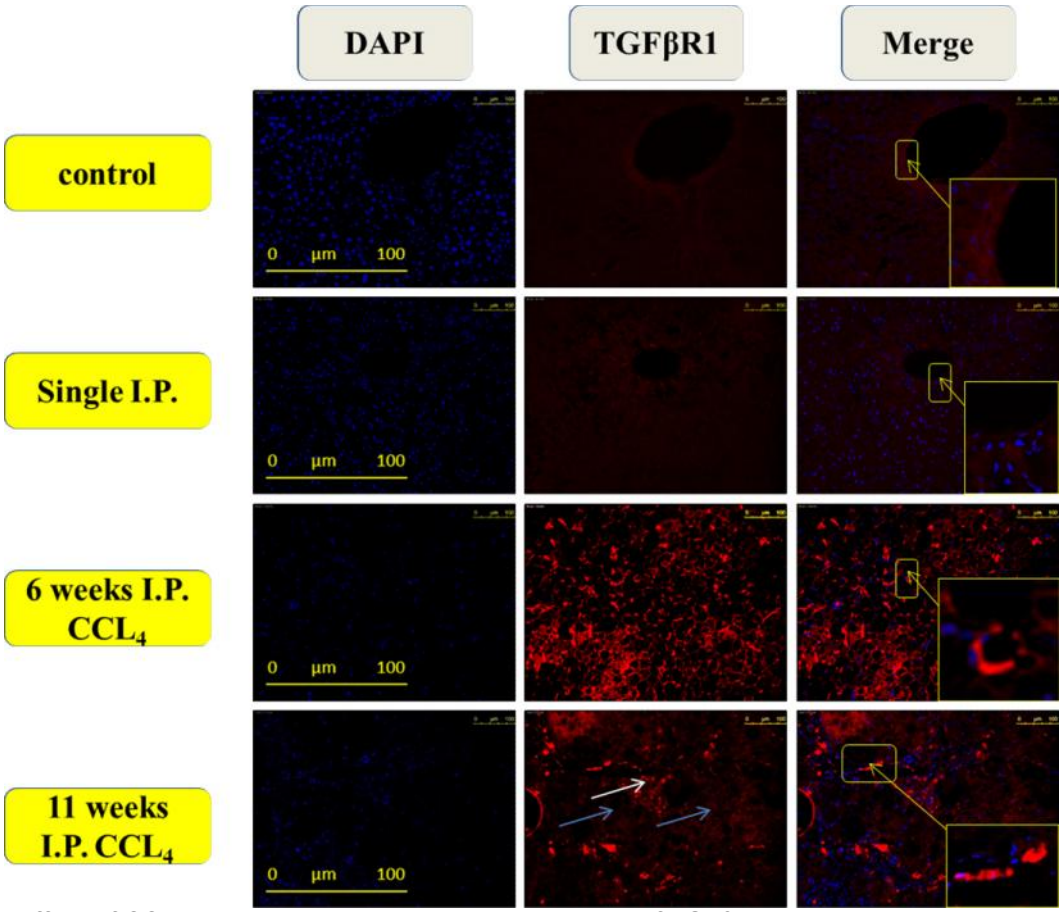

Figure 1: Effect of CCl4 administration on hepatic expression of TGFβRI protein

Immunofluorescence staining of liver sections of CCl_4 treated rats showing minimal TGFβR1 expression in control group and also in single I.P. treated group. Six weeks CCl_4 treated group showed maximal expression located mainly in cell membrane (yellow rectangle).Eleven weeks treatment showed constitutive expression (yellow rectangle) occurred mainly at area of fibrous septa or nodule border (white arrows) with minimal expression in cirrhotic nodule (blue arrows).

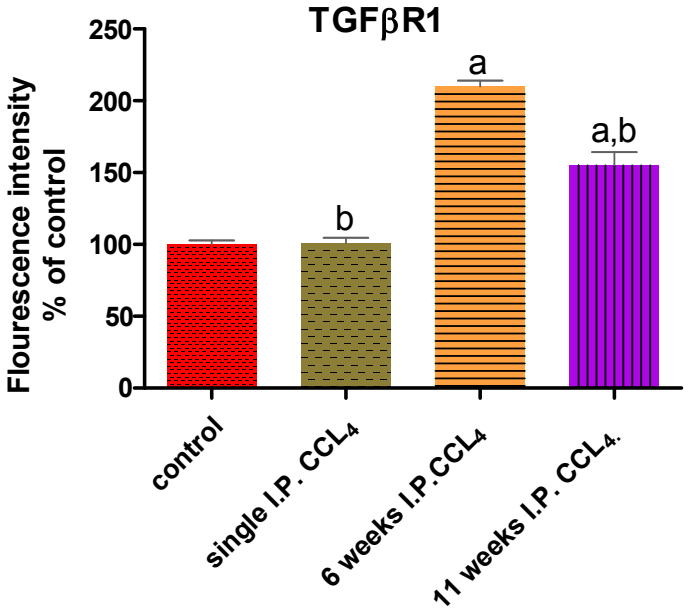

Graph 1: Effect of CCl4 administration on hepatic expression of TGFβRI protein
Fluorescence intensity was obtained from 5 fields of each section (minimally 2 rats of each group) using ImageJ software.
Data are expressed as mean ± SEM
(a) Significantly different from control group
(b) Significantly different from 6 weeks CCl_4 group one-way ANOVA followed by Tukey-Kramer test for multiple comparison test at $P \leq 0.05$

3.3. EXPRESSION AND LOCALIZATION OF FGFR3.

Figure 2 and **Graph 2** show that FGFR3 protein shows minimal expression in normal liver tissues and also in acute toxicity model. The expression was increased on conversion of toxicity from acute to chronic with maximal expression in 6 and 11 weeks groups. It was observed that FGFR3 expression occurs in the cytoplasm of the cells that found in the lesion areas including areas of steatosis, underlying fibrosis and fibrous septa. It was noted that the expression increased by about 146% in 6 weeks CCl_4 treatment group and. Intraperitoneal administration of CCl_4 for 11 weeks resulted in maximal expression that increased by about 222% compared to control.

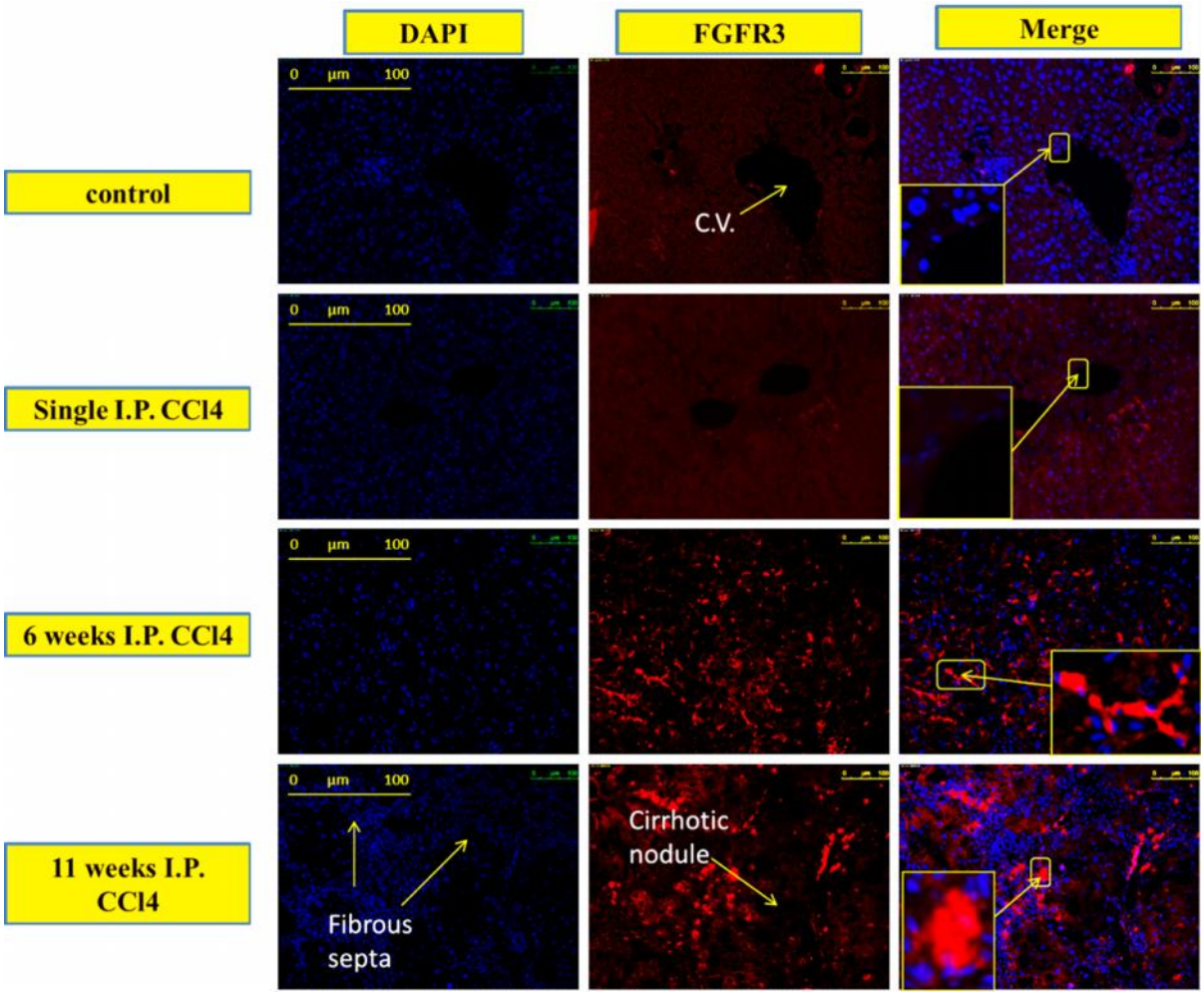

Figure 2: Effect of CCl4 administration on hepatic expression and localization of FGFR3 in CCl4 treated rats.

Fluorescence intensity was obtained from 5 fields of each section (minimally 2 rats of each group) using ImageJ software.

Data are expressed as mean ± SEM

(a) Significantly different from control group

(b) Significantly different from 6 weeks CCl_4 group one-way ANOVA followed by Tukey-Kramer test for multiple comparison test at $P \leq 0.05$

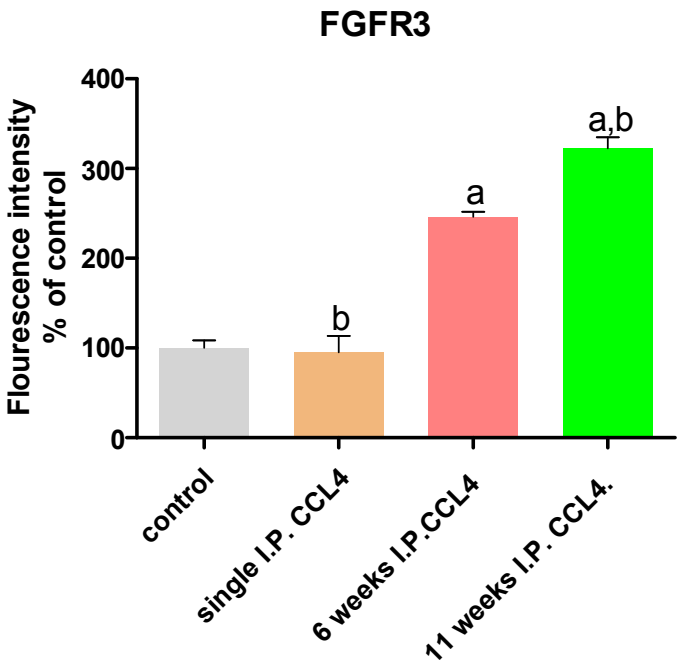

Graph 2: Effect of CCl4 administration on hepatic expression and localization of FGFR3 protein
Data are analysed using one-way ANOVA followed by Turkey-Kramer test for multiple comparison at $P \leq 0.05$.

(a) Significantly different from control.

(b) Significantly different from 6 weeks CCl_4 group.

Fluorescence intensity was obtained from 5 fields of each section (minimally 2 rats of each group) using ImageJ software.

3.4. HISTOPATHOLOGICAL FINDINGS

Effects of CCl_4 treatment on histopathological findings of liver tissue are represented in

Table 2 and **Figure 3**. The control group showed normal hepatic architecture. On contrast, CCl_4 treated groups showed pathological findings changes differed with the duration of treatment.

Single I.P. dose treated group showed average portal tract (PT) (yellow arrow) without interface activity or underlying fibrosis. On the other hand; it showed spotty necrosis (black arrow), and mild micro-vesicular steatosis and dilated central vein. Six weeks treatment caused expanded PT with fibrous septa extending from PT to PT (yellow arrows), marked micro- and macro-vesicular steatosis. The hepatocytes exhibited some aspects of single cell necrosis with dilated central veins and mild interface activity.

Eleven weeks treatment showed markedly expanded PT (yellow arrows) with definite inflammatory infiltrate, complete nodular formation (definite cirrhosis) and marked micro- and macro-vesicular steatosis. The hepatocytes exhibited single cell necrosis with mild spotty necrosis. Finally; the central veins were markedly dilated with marked interface activity.

Table 2: Histopathological findings of the studied groups

	control	Single I.P. CCl_4	CCl4 6 weeks	CCl4 11 weeks
CV	0	+	+	++
Steatosis	0	+	+++	+++
Hepatocyte	0	++	+	+
Spotty necrosis	0	++	0	+
Interface activity	0	0	+	++
PT	0	0	+	++
Fibrosis	0	0	++	++++

Central vein (CV):
0: within normal +: dilated ++: markedly dilated
Steatosis, Spotty necrosis, Interface activity:
0: no +: mild ++: moderate to marked
Hepatocytes:
0: within normal +: single cell necrosis ++: confluent or diffuse necrosis
Portal tract (PT):
0: within normal +: expanded ++: expanded with inflammatory infiltrate
Fibrosis:
0: no fibrosis
+: fibrosis confined to enlarged portal zones
++: fibrosis of peri-portal or portal-portal septa with intact architecture
+++: architectural distortion (septal or bridging fibrosis) without obvious cirrhosis
++++: probable or definite cirrhosis

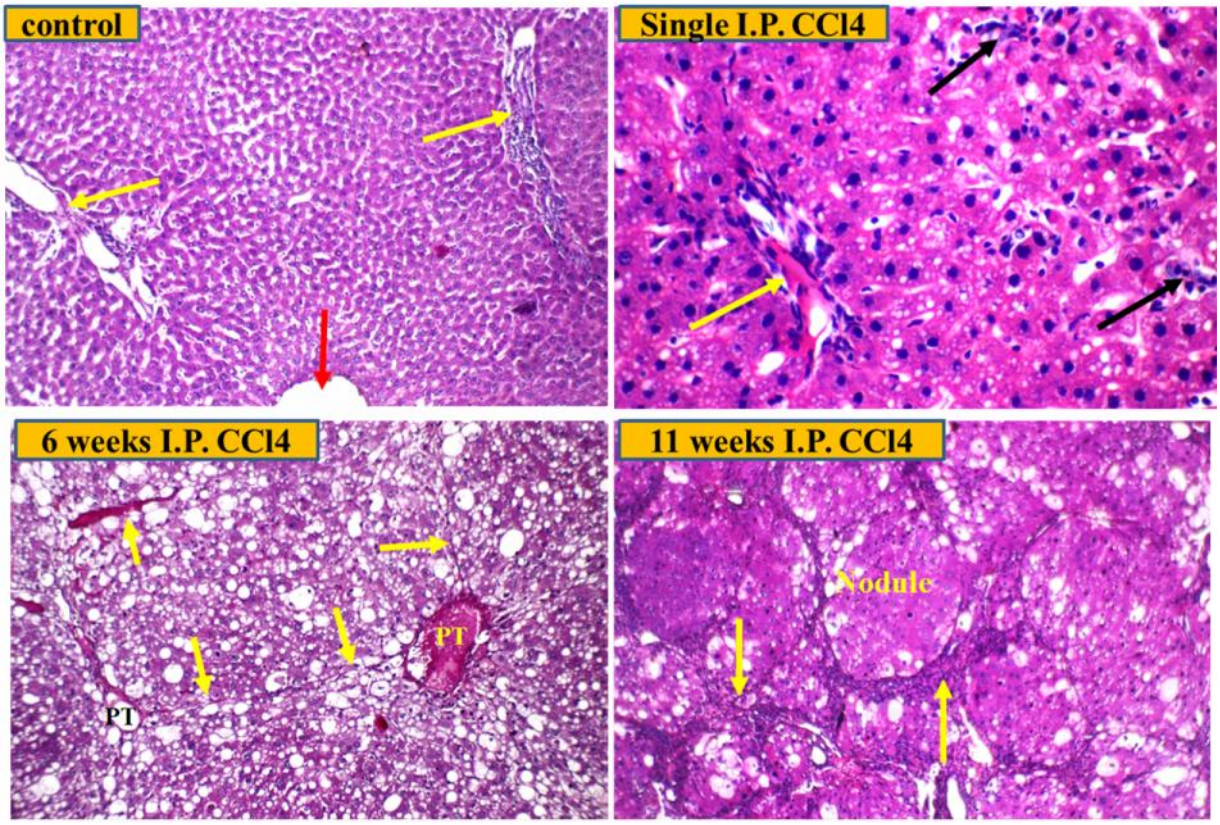

Figure 3: Histopathological micrograph of liver samples of CCl_4 treated groups ×235 using H and E stain. **Control**: liver tissue showing average PT (yellow arrows), average central vein (red arrow), and average hepatocytes arranged in cords. **Single I.P. CCl_4 dose**: liver tissue showing average PT (yellow arrow), spotty necrosis (black arrow), and mild micro-vesicular steatosis.**6 weeks I.P. CCl_4**: liver tissue showing expanded PT with underlying fibrosis and fibrous septa extending from PT to PT (yellow arrows), marked micro- and macro-vesicular steatosis.**11 weeks I.P. CCl_4**: liver tissue showing markedly expanded PT (yellow arrows), complete nodular formation, marked micro- and macro-vesicular steatosis.

4. DISCUSSION

Administration of CCl_4 either a single I.P. dose or chronic I.P. doses for 6 or 11 weeks significantly elevated serum transaminases enzymes activities suggesting hepatocellular damage. These results agreed with previous reports that indicated that CCl_4 significantly increases serum transaminases (25-27). This CCl_4 induced hepatic damage was reported to be due to oxidative stress (28;29).

ALP activity after single I.P. CCl4 treatment shows non-significant increase from control group suggesting minimal biliary injury detected upon that model. This result opposes what was reported by Kālu's team(26). This difference might be due difference in animal strain or route of administration that has not been mentioned. On the other hand; ALP elevation in chronic models including 6 weeks, 11 weeks groups showed significant increase compared to control which is less than 3 times as control; a result that might suggest hepatotoxicity and mild biliary toxicity. This matches with that previously reported by Posen and Doherty(30).Continuous CCl_4 for 11 weeks showed significant elevation in ALP activity compared to 6 weeks CCl_4 treatment suggesting that chronic hepatocellular intoxication might lead to biliary injury.

Serum albumin concentration showed only significant decrease from control at 11 weeks CCl_4 treatment, a group that showed cirrhotic nodule formation. This result agreed with previous reports that indicated the decrease in serum albumin concentration upon decreased liver functioning tissue mass(31).

Meanwhile; it was clarified that free radicals production and oxidative stress are main players in liver injury especially CCl_4 induced liver injury (28;29). In our study; administration of CCl_4 significantly elevated tissue content of MDA and reduced serum SOD activity. These results agreed with the previous reports that demonstrated the great role of oxidative stress in CCl_4 induced liver injury (32-34).

Supporting the measured biochemical data:Our findings demonstrated that single I.P. dose of CCl_4 resulted in marked spotty necrosis and confluent hepatocytes necrosis. On the other hand prolonged administration of CCl_4 to 6 weeks produced fibrosis of peri-portal or portal-portal septa with intact architecture while prolonged CCl_4 to 11 weeks produced definite cirrhosis with clear cirrhotic nodule. This is similar to what has been reported that histopathological changes occur according to CCl_4 administration period. A single dose of CCl_4 leads to centrizonal necrosis and steatosis (35), while continued administration leads to hepatic fibrosis, cirrhosis, and HCC (36)

The TGF-β is the principal regulator in chronic liver injury sharing in all stages of disease progression (37). Its action begins by binding to its receptor TGFβRI and TGFβRII(38). It was observed that TGFβR1expression occurs intracellularly in the cell membrane. This agrees with Massague and Chen reports(39). It was also shown that TGFβR1 expression was only upregulated in chronic liver toxicity; specifically phases that showed some extent of tissue remodeling prescribed by Devaux and his team (40) suggesting involvement of TGFβR1in cellular processes involved in chronic not acute liver injury. This was similar to the previous reports in myocardial infarction (MI) by Devaux and his team (40). Besides; they also showed that the maximal expression occurs in lesion areas suggesting the direct relationship between TGFβR1expression and lesions grade; a result that also is quite similar to Devaux and his team reports (40).

The FGF/FGFR signaling axis has been reported to be a contributor to fibrosis in the liver. (8;9). On the other hand FGFR3 was reported to be activated by FGF2(41); a cytokine that has been believed to be involved in fibrotic disorders(42) (43)

Our results showed that FGFR3 expression increased in chronically intoxicated groups suggesting involvement of FGFR3 in chronic liver injury processes. A result that is quite similar to reports of Lee's team(44). Lee and his team have also reported that expression of all FGFR seem to be cytoplasmic. This is quite similar to our results. Our results showed that the expression of FGFR3 appeared as large spread spot that may indicate that the expression was cytoplasmic.

5. CONCLUSION

In conclusion, our findings indicate, for the first time, that TGFβR1 and FGFR3 are upregulated in chronic not acute liver injury. TGFβR1 is upregulated in injury combined with underlying fibrosis or cirrhosis while FGFR3 is upregulated in injury combined with steatosis, fibrosis and cirrhosis; results that may suggest usage of TGFβR1 and FGFR3 as a candidate markers for diagnosis and prognosis of chronic liver diseases and a target for liver disease therapy.

REFERENCES

REFERENCE LIST

(1) SHARMA A, CHAKRABORTI KK, HANDA SS. ANTIHEPATOTOXIC ACTIVITY OF SOME INDIAN HERBAL FORMULATIONS AS COMPARED TO SILYMARIN. FITOTERAPIA 1991;62:229-35.

(2) OSTAPOWICZ G, FONTANA RJ, SCHIODT FV, LARSON A, DAVERN TJ, HAN SH, ET AL. RESULTS OF A PROSPECTIVE STUDY OF ACUTE LIVER FAILURE AT 17 TERTIARY CARE CENTERS IN THE UNITED STATES. ANN INTERN MED 2002 DEC 17;137(12):947-54.

(3) DOMENICALI M, CARACENI P, GIANNONE F, BALDASSARRE M, LUCCHETTI G, QUARTA C, ET AL. A NOVEL MODEL OF CCL4-INDUCED CIRRHOSIS WITH ASCITES IN THE MOUSE. J HEPATOL 2009 DEC;51(6):991-9.

(4) MORMONE E, GEORGE J, NIETO N. MOLECULAR PATHOGENESIS OF HEPATIC FIBROSIS AND CURRENT THERAPEUTIC APPROACHES. CHEM BIOL INTERACT 2011 SEP 30;193(3):225-31.

(5) ROBERTS AB. TGF-BETA SIGNALING FROM RECEPTORS TO THE NUCLEUS. MICROBES INFECT 1999 DEC;1(15):1265-73.

(6) TSUKAMOTO H. CYTOKINE REGULATION OF HEPATIC STELLATE CELLS IN LIVER FIBROSIS. ALCOHOL CLIN EXP RES 1999 MAY;23(5):911-6.

(7) KANAI M, GOKE M, TSUNEKAWA S, PODOLSKY DK. SIGNAL TRANSDUCTION PATHWAY OF HUMAN FIBROBLAST GROWTH FACTOR RECEPTOR 3. IDENTIFICATION OF A NOVEL 66-KDA PHOSPHOPROTEIN. J BIOL CHEM 1997 MAR 7;272(10):6621-8.

(8) BATALLER R, BRENNER DA. LIVER FIBROSIS. J CLIN INVEST 2005 FEB;115(2):209-18.

(9) GRESSNER AM, WEISKIRCHEN R. MODERN PATHOGENETIC CONCEPTS OF LIVER FIBROSIS SUGGEST STELLATE CELLS AND TGF-BETA AS MAJOR PLAYERS AND THERAPEUTIC TARGETS. J CELL MOL MED 2006 JAN;10(1):76-99.

(10) AMANN T, BATAILLE F, SPRUSS T, DETTMER K, WILD P, LIEDTKE C, ET AL. REDUCED EXPRESSION OF FIBROBLAST GROWTH FACTOR RECEPTOR 2IIIB IN HEPATOCELLULAR CARCINOMA INDUCES A MORE AGGRESSIVE GROWTH. AM J PATHOL 2010 MAR;176(3):1433-42.

(11) HARIMOTO N, TAGUCHI K, SHIRABE K, ADACHI E, SAKAGUCHI Y, TOH Y, ET AL. THE SIGNIFICANCE OF FIBROBLAST GROWTH FACTOR RECEPTOR 2 EXPRESSION IN DIFFERENTIATION OF HEPATOCELLULAR CARCINOMA. ONCOLOGY 2010;78(5-6):361-8.

(12) HO HK, POK S, STREIT S, RUHE JE, HART S, LIM KS, ET AL. FIBROBLAST GROWTH FACTOR RECEPTOR 4 REGULATES PROLIFERATION, ANTI-APOPTOSIS AND ALPHA-FETOPROTEIN SECRETION DURING

HEPATOCELLULAR CARCINOMA PROGRESSION AND REPRESENTS A POTENTIAL TARGET FOR THERAPEUTIC INTERVENTION. J HEPATOL 2009 JAN;50(1):118-27.

(13) HUANG X, YANG C, JIN C, LUO Y, WANG F, MCKEEHAN WL. RESIDENT HEPATOCYTE FIBROBLAST GROWTH FACTOR RECEPTOR 4 LIMITS HEPATOCARCINOGENESIS. MOL CARCINOG 2009 JUN;48(6):553-62.

(14) FLEURENTIN J, HOEFLER C, LEXA A, MORTIER F, PELT JM. HEPATOPROTECTIVE PROPERTIES OF CREPIS RUEPPELLII AND ANISOTES TRISULCUS: TWO TRADITIONAL MEDICINAL PLANTS OF YEMEN. J ETHNOPHARMACOL 1986 APR;16(1):105-11.

(15) INSTITUTE OF LABORATORY ANIMAL RESOURCES (US), USE OF LABORATORY ANIMALS, NATIONAL INSTITUTES OF HEALTH (US). GUIDE FOR THE CARE AND USE OF LABORATORY ANIMALS. NATIONAL ACADEMIES; 1985.

(16) BERGMEYER HU, HORDER M, REJ R. INTERNATIONAL FEDERATION OF CLINICAL CHEMISTRY (IFCC) SCIENTIFIC COMMITTEE, ANALYTICAL SECTION: APPROVED RECOMMENDATION (1985) ON IFCC METHODS FOR THE MEASUREMENT OF CATALYTIC CONCENTRATION OF ENZYMES. PART 2. IFCC METHOD FOR ASPARTATE AMINOTRANSFERASE (L-ASPARTATE: 2-OXOGLUTARATE AMINOTRANSFERASE, EC 2.6.1.1). J CLIN CHEM CLIN BIOCHEM 1986 JUL;24(7):497-510.

(17) BERGMEYER HU, HORDER M, REJ R. INTERNATIONAL FEDERATION OF CLINICAL CHEMISTRY (IFCC) SCIENTIFIC COMMITTEE, ANALYTICAL SECTION: APPROVED RECOMMENDATION (1985) ON IFCC METHODS FOR THE MEASUREMENT OF CATALYTIC CONCENTRATION OF ENZYMES. PART 3. IFCC METHOD FOR ALANINE AMINOTRANSFERASE (L-ALANINE: 2-OXOGLUTARATE AMINOTRANSFERASE, EC 2.6.1.2). J CLIN CHEM CLIN BIOCHEM 1986 JUL;24(7):481-95.

(18) TIETZ NW, RINKER AD, SHAW LM. INTERNATIONAL FEDERATION OF CLINICAL CHEMISTRY. IFCC METHODS FOR THE MEASUREMENT OF CATALYTIC CONCENTRATION OF ENZYMES. PART 5. IFCC METHOD FOR ALKALINE PHOSPHATASE (ORTHOPHOSPHORIC-MONOESTER PHOSPHOHYDROLASE, ALKALINE OPTIMUM, EC 3.1.3.1). IFCC DOCUMENT STAGE 2, DRAFT 1, 1983-03 WITH A VIEW TO AN IFCC RECOMMENDATION. CLIN CHIM ACTA 1983 DEC 30;135(3):339F-67F.

(19) TIETZ NW, RINKER AD, SHAW LM. IFCC METHODS FOR THE MEASUREMENT OF CATALYTIC CONCENTRATION OF ENZYMES PART 5. IFCC METHOD FOR ALKALINE PHOSPHATASE (ORTHOPHOSPHORIC-MONOESTER PHOSPHOHYDROLASE, ALKALINE OPTIMUM, EC 3.1.3.1). J CLIN CHEM CLIN BIOCHEM 1983 NOV;21(11):731-48.

(20) TIETZ NW, BURTIS CA, DUNCAN P, ERVIN K, PETITCLERC CJ, RINKER AD, ET AL. A REFERENCE METHOD FOR MEASUREMENT OF ALKALINE PHOSPHATASE ACTIVITY IN HUMAN SERUM. CLIN CHEM 1983 MAY;29(5):751-61.

(21) GENDLER S. URIC ACID. KAPLAN A ET AL. CLIN CHEM THE CV MOSBY CO ST LOUIS TORONTO PRINCETON 1984;1268-73.

(22) MIHARA M, UCHIYAMA M. DETERMINATION OF MALONALDEHYDE PRECURSOR IN TISSUES BY THIOBARBITURIC ACID TEST. ANAL BIOCHEM 1978 MAY;86(1):271-8.

(23) MARKLUND SL. SUPEROXIDE DISMUTASE ISOENZYMES IN TISSUES AND PLASMA FROM NEW ZEALAND BLACK MICE, NUDE MICE AND NORMAL BALB/C MICE. MUTAT RES 1985 JAN;148(1-2):129-34.

(24) ABDEL-BAKKY MS, HAMMAD MA, WALKER LA, ASHFAQ MK. TISSUE FACTOR DEPENDENT LIVER INJURY CAUSES RELEASE OF RETINOID RECEPTORS (RXR-ALPHA AND RAR-ALPHA) AS LIPID DROPLETS. BIOCHEM BIOPHYS RES COMMUN 2011 JUN 24;410(1):146-51.

(25) AHSAN R, ISLAM KM, MUSADDIK A, HAQUE E. HEPATOPROTECTIVE ACTIVITY OF METHANOL EXTRACT OF SOME MEDICINAL PLANTS AGAINST CARBON TETRACHLORIDE INDUCED HEPATOTOXICITY IN ALBINO RATS. GLOBAL J PHARMACOL 2009;3(3):116-22.

(26) KALU FN, OGUGUA VN, UJOWUNDU CO, NWAOGUIKPE RN. AQUEOUS EXTRACT OF COMBRETUM DOLICHOPENTALUM LEAF-A POTENT INHIBITOR OF CARBON TETRACHLORIDE INDUCED HEPATOTOXICITY IN RATS. JOURNAL OF APPLIED PHARMACEUTICAL SCIENCE 2011;1(10):114.

(27) DALTON SR, LEE SM, KING RN, NANJI AA, KHARBANDA KK, CASEY CA, ET AL. CARBON TETRACHLORIDE-INDUCED LIVER DAMAGE IN ASIALOGLYCOPROTEIN RECEPTOR-DEFICIENT MICE. BIOCHEMICAL PHARMACOLOGY 2009;77(7):1283-90.

(28) MANIBUSAN MK, ODIN M, EASTMOND DA. POSTULATED CARBON TETRACHLORIDE MODE OF ACTION: A REVIEW. J ENVIRON SCI HEALTH C ENVIRON CARCINOG ECOTOXICOL REV 2007 JUL;25(3):185-209.

(29) WEBER LW, BOLL M, STAMPFL A. HEPATOTOXICITY AND MECHANISM OF ACTION OF HALOALKANES: CARBON TETRACHLORIDE AS A TOXICOLOGICAL MODEL. CRIT REV TOXICOL 2003;33(2):105-36.

(30) POSEN S, DOHERTY E. THE MEASUREMENT OF SERUM ALKALINE PHOSPHATASE IN CLINICAL MEDICINE. ADV CLIN CHEM 1981;22:163-245.

(31) GIANNINI EG, TESTA R, SAVARINO V. LIVER ENZYME ALTERATION: A GUIDE FOR CLINICIANS. CANADIAN MEDICAL ASSOCIATION JOURNAL 2005;172(3):367-79.

(32) KALU FN, OGUGUA VN, UJOWUNDU CO, NWAOGUIKPE RN. AQUEOUS EXTRACT OF COMBRETUM DOLICHOPENTALUM LEAF-A POTENT INHIBITOR OF CARBON TETRACHLORIDE INDUCED HEPATOTOXICITY IN RATS. 2011.

(33) DALTON SR, LEE SM, KING RN, NANJI AA, KHARBANDA KK, CASEY CA, ET AL. CARBON TETRACHLORIDE-INDUCED LIVER DAMAGE IN ASIALOGLYCOPROTEIN RECEPTOR-DEFICIENT MICE. BIOCHEM PHARMACOL 2009 APR 1;77(7):1283-90.

(34) NOORI S, REHMAN N, QURESHI M, MAHBOOB T. REDUCTION OF CARBON TETRACHLORIDE-INDUCED RAT LIVER INJURY BY COFFEE AND GREEN TEA. PAKISTAN JOURNAL OF NUTRITION 2009;8(4):452-8.

(35) PIERCE RA, GLAUG MR, GRECO RS, MACKENZIE JW, BOYD CD, DEAK SB. INCREASED PROCOLLAGEN MRNA LEVELS IN CARBON TETRACHLORIDE-INDUCED LIVER FIBROSIS IN RATS. J BIOL CHEM 1987 FEB 5;262(4):1652-8.

(36) TAMAYO RP. IS CIRRHOSIS OF THE LIVER EXPERIMENTALLY PRODUCED BY CC14 AN ADEQUATE MODEL OF HUMAN CIRRHOSIS? HEPATOLOGY 1983;3(1):112-20.

(37) DOOLEY S, TEN DP. TGF-BETA IN PROGRESSION OF LIVER DISEASE. CELL TISSUE RES 2012 JAN;347(1):245-56.

(38) DEVAUX Y, BOUSQUENAUD M, RODIUS S, MARIE PY, MASKALI F, ZHANG L, ET AL. TRANSFORMING GROWTH FACTOR BETA RECEPTOR 1 IS A NEW CANDIDATE PROGNOSTIC BIOMARKER AFTER ACUTE MYOCARDIAL INFARCTION. BMC MED GENOMICS 2011;4:83.

(39) MASSAGUE J, CHEN YG. CONTROLLING TGF-BETA SIGNALING. GENES DEV 2000 MAR 15;14(6):627-44.

(40) DEVAUX Y, BOUSQUENAUD M, RODIUS S, MARIE PY, MASKALI F, ZHANG L, ET AL. TRANSFORMING GROWTH FACTOR BETA RECEPTOR 1 IS A NEW CANDIDATE PROGNOSTIC BIOMARKER AFTER ACUTE MYOCARDIAL INFARCTION. BMC MED GENOMICS 2011;4:83.

(41) ORNITZ DM, LEDER P. LIGAND SPECIFICITY AND HEPARIN DEPENDENCE OF FIBROBLAST GROWTH FACTOR RECEPTORS 1 AND 3. J BIOL CHEM 1992 AUG 15;267(23):16305-11.

(42) PRASSE A, PECHKOVSKY DV, TOEWS GB, JUNGRAITHMAYR W, KOLLERT F, GOLDMANN T, ET AL. A VICIOUS CIRCLE OF ALVEOLAR MACROPHAGES AND FIBROBLASTS PERPETUATES PULMONARY FIBROSIS VIA CCL18. AM J RESPIR CRIT CARE MED 2006 APR 1;173(7):781-92.

(43) MASAMUNE A, SATOH M, KIKUTA K, SUZUKI N, SHIMOSEGAWA T. ENDOTHELIN-1 STIMULATES CONTRACTION AND MIGRATION OF RAT PANCREATIC STELLATE CELLS. WORLD J GASTROENTEROL 2005 OCT 21;11(39):6144-51.

(44) LEE HJ, KANG HJ, KIM KM, YU ES, KIM KH, KIM SM, ET AL. FIBROBLAST GROWTH FACTOR RECEPTOR ISOTYPE EXPRESSION AND ITS ASSOCIATION WITH OVERALL SURVIVAL IN PATIENTS WITH HEPATOCELLULAR CARCINOMA. CLIN MOL HEPATOL 2015 MAR;21(1):60-70.