Original Research Article

Sulphasalazine Prevents Fibrosis; Relevance of TGFβRI

.

ABSTRACT

Aims: The aim of this study is to investigate the protective effect of sulphasalazine on liver fibrosis. Besides; investigation of the expression pattern of transforming growth factor β receptor I (TGFβRI) in liver fibrosis and the possible modulatory effect of sulphasalazine on it.
Study design: Controlled experiment
Place and Duration of Study: Department of Biochemistry and Department of Pharmacology and Toxicology, Faculty of pharmacy (boys) Al-Azhar University, between February 2015 and June 2015.
Methodology: Five Sprague-Dawley rats groups were used for the experiment. **Control group**: receiving corn oil; **DMSO group**: injected with DMSO; **6weeks group**: injected with 50% CCl_4 in corn oil; **sulphasalazine group**: injected with sulphasalazine and CCl_4 and finally **mesalazine group**: were given mesalazine and CCl_4. On the day after the last dose, rats were anesthetized with diethyl ether and blood samples were collected for measurement of blood chemistry. The animals then were euthanized, and livers were harvested and divided into 2 parts; one part was processed for standard histology and immunofluorescence techniques and the other was homogenized for oxidative status assessment.
Results: TGFβRI has been shown to be upregulated in chronic liver injury; fibrosis stage; with expression occurring mainly in cell membrane of lesion area. This expression was decreased significantly with sulphasalazine treatment. Sulphasalazine has shown to have ability to diminish fibrosis in chronic liver injury. This decrease in fibrosis observed with sulphasalazine was in parallel with decrease in TGFβRI expression. Besides; this action of sulphasalazine has been suggested to be due to the whole molecule not to its moiety; mesalazine.
Conclusion: TGFβRI may be used as a candidate marker for diagnosis and prognosis of chronic liver diseases. Besides; it may be used as a target therapy for chronic liver diseases. Moreover; sulphasalazine might be a promising adjuvant therapy for chronic liver diseases.

Keywords: TGFβRI, fibrosis, sulphasalazine, mesalazine

1. INTRODUCTION

Liver plays an unlimited role in the preservation and body homeostasis regulation. It is included in most biochemical pathways to growth, protection against disease, nutrient fund, energy facility and reproduction (1).Hepatotoxicity can be generated by certain common causes including therapeutic agents, natural chemicals, laboratory and manufacturing agents and herbal therapies (2).

Transforming growth factor β receptors (TGFβRs) are of 2 types TGF-βRI and TGF-βRII. They mediate Hepatic stellate cells (HSCs) activation (3) after binding to their ligand cytokine TGFβ, the profibrogenic cytokine that is traditionally considered the key fibrogenic stimulus to HSC (4).

Carbon tetra chloride (CCl_4) is one of the most communal models for inducing hepatotoxicity. It is transformed into a toxic CCl_3^- radical by hepatic cytochrome P 450 2E1 (CYP2E1).Thus; it brings an acute Centro-lobular necrosis which starts a wound healing response (fibrosis) (5). However, Contact to these chemicals in humans is rare and generally occurs in the manufacturing during fabrication and in places where these chemicals is usually used (6).

Hepatic stellate cells are the most important player in hepatic injury. Quiescent HSCs are characterized by significant desmin expression and vitamin A storage. Following liver injury, HSCs lose their vitamin A content, rise the expression of α-smooth muscle actin (α-SMA) and gain a myofibroblast- like phenotype (7).These events are primarily triggered by mediators released by activated Kupffer cell and injured hepatocytes (8).

Sulfasalazine is a synthetic drug obtained from the grouping of sulfapyridine and 5-aminosalicylic acid (mesalazine), an antibiotic and an anti-inflammatory agent, respectively. This drug is usually used in the inflammatory diseases of the large intestine and rheumatoid arthritis (9)

Despite great knowledge about liver fibrosis, there are little drugs approved for management of it. So the aim of this work is to investigate the possible protective effect of sulphasalazine on liver fibrosis; an aspect that has gone side by side with investigation of expression pattern of TGFβRI in liver fibrosis and investigation of the possible modulatory effect of sulphasalazine on it.

2. METHODOLOGY

2.1. Animal model.

Adult male Sprague-Dawley (SD) rats weighing 250–300 g and aging 70 days were used in the current study. The animals were obtained from the breeding colony maintained at the animal house of the Nile Company for pharmaceuticals, Cairo, Egypt. They were housed in the animal facility of Faculty of Pharmacy, Al-Azhar University in 20 X 18 X 25 cm plastic cages with stainless steel wire lids and mesh floor with 5 animals per cage. They were kept at 23±1 °C, 55 % relative humidity with 12:12-h light: dark cycle. They were maintained on a standard rodent chow (El-Nasr Company, Abou-Zaabal, Cairo, Egypt) and allowed to food and water *ad libitum*. Animals were randomly divided into five groups; **(1)control group**: 9 rats received corn oil (2mg/kg/twice weekly/intraperitoneal(IP)/repeated for 6 weeks) ; **(2)DMSO group**: 12 rats were injected with DMSO, the vehicle of sulphasalazine (1ml/kg/day/IP/repeated for 6 weeks) and 50 % CCl_4 in corn oil (4 ml/kg/IP/twice weekly/repeated for 6 weeks);**(3)6weeks group**:12rats were injected with 50% CCl_4 in corn oil (4 ml/kg/IP/twice weekly/repeated for 6weeks); **(4)sulphasalazine group**: 12 rats were injected with sulphasalazine (75 mg/kg/day/IP/repeated for 6weeks)(10) and CCl_4 as previously indicated in 6 weeks group and **(5)mesalazine group**: 12 rats were given mesalazine(100 mg/kg/day/orally by oral gavage/repeated for 6weeks)(11) and CCl_4 as previously indicated in 6 weeks group . At the end of experimental period, rats were anesthetized with diethyl ether and blood samples have been drawn from retro orbital plexus for measurement of blood chemistry. The animals then were euthanized, and tissue samples from the livers were harvested and divided into 2 parts; one part was processed by standard histology and immunofluorescence techniques and the other was homogenized in 0.15 M KCl for oxidative stress assay. All animal procedures were performed in accordance with the international guide for the care and use of laboratory animals (12)

2.2. Antibodies and chemicals.

Rabbit polyclonal TGFβR1 antibody was purchased from Santa Cruz Biotechnology (CA, USA). Cy3-conjugated goat anti-rabbit antibody was purchased from Jackson Immunoresearch (PA, USA). 4, 6- Diamidino-2- phenyl indole (DAPI). CCl_4 and DMSO were purchased from Sigma-Aldrich (MO, USA). Sulphasalazine was kindly supplied as yellowish powder by El-Kahera Pharmaceuticals Company, Cairo, Egypt and mesalazine was kindly supplied as white powder by Pharopharm pharmaceuticals company, Alexandria, Egypt

2.3. Biochemical analysis.

Serum enzymatic activities of transaminases (ALT and AST) were estimated by kinetic method according to the method of international federation of clinical chemistry (IFCC) (13;14). Alkaline phosphatase (ALP) activity was assayed according to the method of IFCC(15-17) and serum albumin concentration according to the method described by Gendler (18). The liver homogenate was used for the determination of the oxidative stress parameters. The level of thiobarbituric acid-reactive substances was assayed as malondialdehyde (MDA) as described by Mihara and Uchiyama (19). The activity of SOD was determined using the method described by Marklund (20).

2.4. Immunofluorescence analysis.

Liver tissues sections were handled according to method described by Abdel-Bakky et al. (21). The primary TGFβR1 antibody was diluted in blocking solution in the suitable dilution (1:400) and left overnight in 4 °C. Secondary antibody (cyanine red conjugated) diluted in the blocking solution was incubated for 30 min and the nuclei were counterstained using DAPI. Finally, all slides

were mounted with the fluoromount solution, covered by covering slips, and allowed to stand for detection by immunofluorescence microscope (Leica DM 5500B).

2.5. Histopathological examination

Liver samples were taken from rats belonging to the different groups and fixed in 10% neutral buffered formalin for 24 hours. Washing was done in tap water, and then serial dilutions of alcohol (methyl, ethyl and absolute ethyl) were used for dehydration. Specimens were cleared in xylene and embedded in paraffin at 56°C in hot air oven for 24 h. Paraffin wax tissue blocks were prepared for sectioning at 4 microns thickness by sledge microtome.

The obtained tissue sections were collected on glass slides, deparaffinized, stained by hematoxylin & eosin stain and then examination was done through a light electric microscope (22). Histopathological grading was achieved by subjective scoring approved by pathology department, faculty of pharmacy, Al-Azhar university, Cairo, Egypt with assistance of attached clues.

2.6. Statistical analysis.

Data were presented as the mean ±SE. Statistical analysis was performed using one-way analysis of variance (ANOVA) followed by Tukey-Kramer as a post test, according to the number of groups. The 0.05 level of probability was used as the criterion of significance using GraphPad Prism software version 5 (GraphPad Software Inc, CA, USA).

3. RESULTS

3.1. LIVER FUNCTIONS AND OXIDATIVE STATUS ASSESSMENT.

To assess liver functions; we have performed liver function tests including serum transaminases, ALP, and albumin. The oxidative status of liver tissues has been determined through MDA and SOD assay as indicated in Table 1 and Table 2.

As indicated in Table 1 and Table 2; Serum ALT and AST activity of control group rats were 46.6±2.85 and 54.1±2.65 respectively. Administration of CCl_4 I.P. alone or combined with DMSO for 6 weeks significantly increased ALT and AST activity compared to control group. Interestingly concomitant administration of CCl_4 with sulphasalazine reduced serum activity of AST compared to DMSO group.

As shown in Table 1 and Table 2; ALP activity of control group rats was 312±21.9. Administration of CCl_4 I.P. for 6 weeks increased ALP significantly by 83 % if given only and by 86 % in combination with DMSO compared to control group. Concomitant administration of sulphasalazine with CCl_4 decreased ALP activity by 10 % compared to DMSO group.

Serum albumin of control group was 3.81±0.08 g/dl. A significant decrease was observed only in mesalazine group as shown in Table 1 and Table 2

As shown in Table 1 and Table 2; the hepatic MDA content of control group was 4.73±0.318 nmol/g tissue. This content was significantly increased on CCl_4 treated groups to be 31.9±1.44 (nmol/g tissue) for 6 weeks group, 31.7±1.82(nmol/g tissue) for DMSO group and 25.7±1.5 (nmol/g tissue) for sulphasalazine group. On the other hand; combination of CCl_4 with mesalazine showed MDA content of 9.86 ±0.339 respectively; results that showed significant decrease compared to 6 weeks CCl_4 treatment although they appeared non-significantly changed from control group. Finally sulphasalazine showed a significant decrease in MDA content compared to DMSO group.

Table 1and Table 2 show the M ± SEM for SOD of studied groups. The control group showed tissue SOD activity of 526±25.2 U/mg tissue. This activity was significantly decreased in other groups to become 242±15.4, 223±14, 281±16 and 225±9.65 for DMSO, 6 weeks, sulphasalazine, and mesalazine groups.

Table 1: Liver functions and oxidative status assessment tests (samples were taken from all animals belonging to each group).

	ALT(IU/L)	*AST(IU/L)*	*ALP(IU/L)*	*Albumin(g/dl)*	*MDA(nmol/g tissue)*	*SOD(U/mg tissue)*
Control	46.6±2.85	54.1±2.65	312±21.9	3.81±0.08	4.73±0.32	526±25.2
CCl_4 6 weeks I.P.	349±13.4[(a)]	436±15.4[(a)]	570±24.5[(a)]	3.39±0.13	31.9±1.44[(a)]	223±14[(a)]
CCl_4 6 weeks I.P. +DMSO I.P.	332±12.8[(a)]	402±8.91[(a)]	580±21.1[(a)]	3.35±0.12	31.7±1.82[(a)]	242±15.4[(a)]
CCl_4 6 weeks I.P. + sulphasalazine I.P.	328±19[(a)]	338±14.5[(a)(b)(c)]	523±19.8[(a)]	3.34±0.12	25.7±1.5[(a)]	281±16[(a)]
CCl_4 6 weeks I.P. + oral mesalazine	315±19[(a)]	486±24.2[(a)]	701±44[(a)(b)]	3.18±0.16[(a)]	9.86 ±0.34[(b)]	225±9.65[(a)]

Data are expressed as mean ± SEM
(a) Significantly different from control group
(b) Significantly different from 6 weeks CCl_4 group
(c) Significantly different from 6 weeks CCl_4 + DMSO (for sulphasalazine) using one-way ANOVA followed by Tukey-Kramer test for multiple comparison test at $P \leq 0.05$

Table 2: Liver functions and oxidative status assessment tests (percentage change from control) (samples were taken from all animals belonging to each group).

	ALT(%change)	*AST(%change)*	*ALP(%change)*	*Albumin(%change)*	*MDA(%change)*	*SOD(%change)*
Control	100±6.12	100±4.9	100±7.02	100±2.1	100±6.77	100±4.79
CCl_4 6 weeks I.P.	749±28.8[(a)]	806±28.47[(a)]	183±7.85[(a)]	89±3.41	674±30.4[(a)]	42.4±2.66[(a)]
CCl_4 6 weeks I.P. +DMSO I.P.	712±27.5[(a)]	743±16.5[(a)]	186±6.76[(a)]	87.9±3.15	670±38.5[(a)]	46±2.93[(a)]
CCl_4 6 weeks I.P. + sulphasalazine I.P.	704±40.8[(a)]	625±26.8[(a)(b)(c)]	168±6.35[(a)]	87.7±3.15	543±31.7[(a)]	53.4±3.04[(a)]
CCl_4 6 weeks I.P. + oral mesalazine	676±40.8[(a)]	898±44.7[(a)]	225±4.1[(a)(b)]	83.5±4.2[(a)]	208 ±7.19[(b)]	42.8±1.83[(a)]

3.2. EXPRESSION AND LOCALIZATION OF TGFBR1.

Figure 1 and Graph 1 show that TGFβR1 protein showed minimal expression in normal liver tissues. The tissue expression was showed to be maximal in 6 weeks CCl_4 groups. It is noted that the expression increased by about 146% in 6 weeks CCl_4 treatment group. It is also observed that the expression was located in the cell membrane of epithelial hepatic tissue in areas that shows great lesions.

It is also noted that concomitant administration of DMSO and CCl_4 for 6 weeks produced non-significant change from CCl_4 only. On the other hand; Concomitant administration of sulphasalazine and CCl_4 decreased the expression by about 46% compared to DMSO group while concomitant administration of mesalazine with CCl_4 reduced the expression by about 36% compared to 6 weeks CCl_4 group.

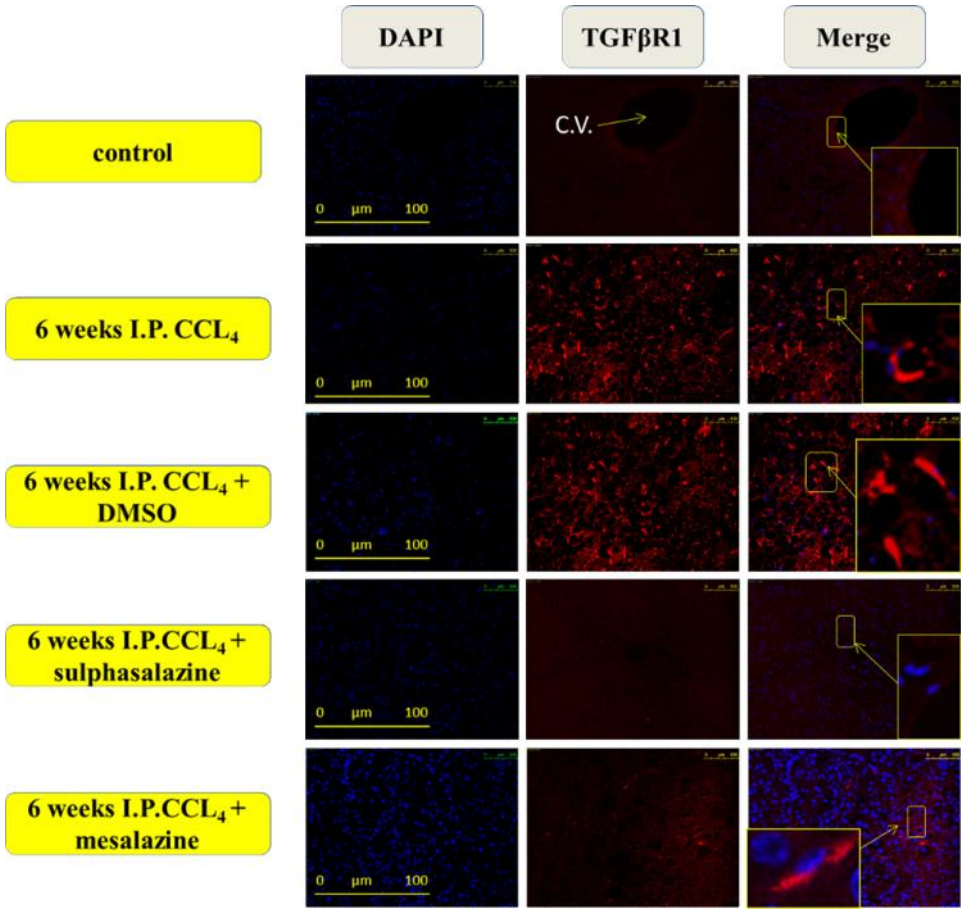

Figure 1: Immunofluorescence staining of liver sections of studied groups showing minimal TGFβR1 expression in control group. Six weeks CCl_4 treated group shows maximal expression located mainly in cell membrane (yellow rectangle). It is noted also that there is non-significant expression change between 6 weeks CCl_4 treatment alone or combined with DMSO. Combination of CCl_4 with sulphasalazine or mesalazine show decrease in the expression compared to 6 weeks CCl_4 treatment with maximal decrease occurring with sulphasalazine.

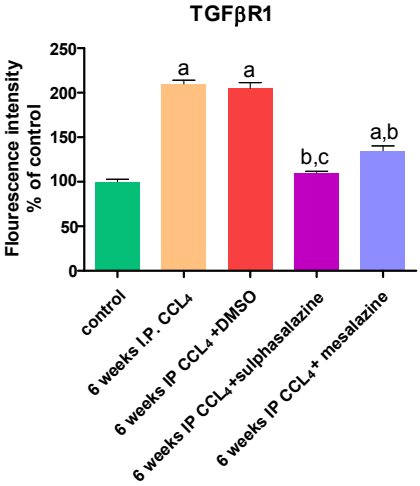

Graph 1: Fluorescence intensity was obtained from 5 fields of each liver section (minimally 2 rats of each group) using ImageJ software.

Data are expressed as mean ± SEM

(a) Significantly different from control group
(b) Significantly different from 6 weeks CCl_4 group
(c) Significantly different from 6 weeks CCl_4 + DMSO using one-way ANOVA followed by Tukey-Kramer test for multiple comparison test at $P \leq 0.05$

3.3. HISTOPATHOLOGICAL FINDINGS

Effects of CCl_4 treatment on histopathological findings of liver tissue are represented in Table 3 and Figure 2; the control group shows normal hepatic architecture. On contrast, six weeks CCl_4 treatment shows expanded portal tract with fibrous septa extending from a portal tract to another (yellow arrows), marked micro- and macro-vesicular steatosis. The hepatocytes exhibit some aspects of single cell necrosis with dilated central veins and mild interface activity.

It is noted that sulphasalazine had minimal effect on steatosis. Interestingly; despite sulphasalazine group animals show marked steatosis, they also show completely diminished underlying fibrosis in their liver tissues.

Finally; combination of mesalazine with CCl_4 results in some alleviation in injury signs. However; it seems not to have positive effects regarding steatosis or fibrosis.

Table 3: Histopathological findings of the studied groups (minimally 2 rats of each group with 5 fields of each rat at least)

	control	**CCl_4 6 weeks**	**CCl_4 6 weeks + DMSO**	**CCl_4 6 weeks + sulphasalazine**	**CCl_4 6 weeks + mesalazine**
CV	0	+	0	0	0
Steatosis	0	+++	++	+++	++
Hepatocyte	0	+	0	0	0
Spotty necrosis	0	0	+	0	0
Interface activity	0	+	0	0	0
PT	0	+	++	0	0
Fibrosis	0	++	++	0	++

Central vein (CV):
0: within normal +: dilated ++: markedly dilated
Steatosis, Spotty necrosis, Interface activity:
0: no +: mild ++: moderate to marked
Hepatocytes:
0: within normal +: single cell necrosis ++: confluent or diffuse necrosis
Portal tract:
0: within normal +: expanded ++: expanded with inflammatory infiltrate
Fibrosis:
0: no fibrosis
+: fibrosis confined to enlarged portal zones
++: fibrosis of peri-portal or portal-portal septa with intact architecture
+++: architectural distortion (septal or bridging fibrosis) without obvious cirrhosis
++++: probable or definite cirrhosis

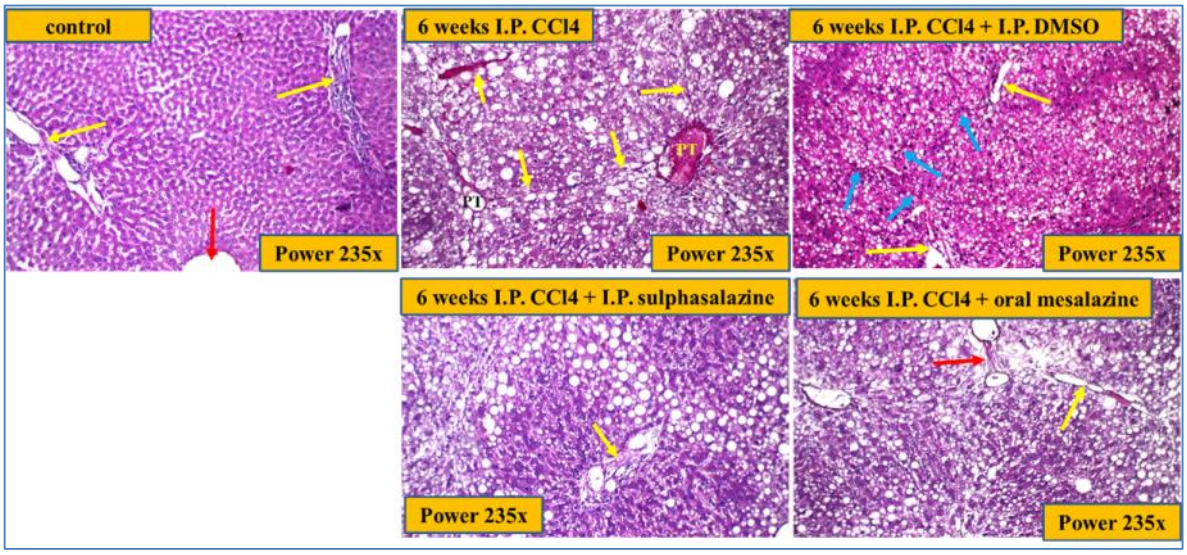

Figure 2: Effect of CCl_4 administration on hepatic histopathological findings with investigation of the possible modulatory effect of sulphasalazine and mesalazine (minimally 2 rats of each group with 5 fields of each rat at least)

Histopathological micrograph of liver samples of CCl_4 treated groups combined with DMSO, sulphasalazine and mesalazine ×235 using H and E stain. **Control:** liver tissue showing average PT (yellow arrows), average central vein (red arrow), and average hepatocytes arranged in cords. **6 weeks I.P. CCl_4:** liver tissue showing expanded PT with underlying fibrosis and fibrous septa extending from PT to PT (yellow arrows), marked micro- and macro-vesicular steatosis. **6 weeks I.P. CCl_4 + I.P. DMSO:** liver tissue showing average portal tract (yellow arrows), fibrous septa extending from PT (blue arrows), average hepatocytes and moderate steatosis. **6 weeks I.P. CCl_4 + I.P. sulphasalazine:** liver tissue showing average PT (yellow arrow), and marked steatosis. **6 weeks I.P. CCl_4 + oral mesalazine:** liver tissue showing average PT (yellow arrow), short fibrous septa (red arrow), average hepatocytes and moderate steatosis.

4. DISCUSSION

Administration of I.P. CCl_4 for 6 weeks has significantly elevated serum transaminases enzymes activities suggesting hepatocellular damage. These results agreed with previous reports that CCl_4 significantly increases serum transaminases (23-25). This CCl_4 induced hepatic damage has been reported to be due to oxidative stress (26;27).Concomitant administration of sulphasalazine with CCl_4 has reduced AST not ALT activity compared to DMSO group suggesting the positive effect toward liver injury. These effects might be due to the anti-inflammatory action of sulphasalazine. This disagrees with what has been reported by Jennings and his coworkers a result that was interpreted by the relationship of hepatic injury, steatosis, fibrosis and cirrhosis to ulcerative colitis not sulphasalazine medication (28).

ALP activity caused by IP CCl_4 administration for 6 weeks and DMSO group has showed significant increase compared to control which was less than 3 times as control; a result that might suggest hepatotoxicity and mild biliary toxicity. This matches with that previously reported by Posen and Doherty (29). Concomitant administration of mesalazine and CCl_4 for 6 weeks has significantly elevated ALP activity compared to 6 weeks CCl_4 treatment. This result might suggest the toxic effect of mesalazine with the mentioned regimen on hepatic tissue or synergistic effect of mesalazine on CCl_4 toxicity; a suggestion that might be clear upon ALP and albumin result.

Meanwhile; it was clarified that free radicals production and oxidative stress are main players in liver injury especially CCl_4 induced liver injury (26;27). In our study; administration of CCl_4 has significantly elevated tissue content of MDA and reduced serum SOD activity. These results agreed with the previous reports that demonstrated the great role of oxidative stress in CCl_4 induced liver injury. (30-32).

Supporting the measured biochemical data: Our histopathological findings have demonstrated that administration of CCl_4 for 6 weeks produced fibrosis of peri-portal or portal-portal fibrosis with intact architecture. This is similar to what has been reported that continued administration of CCl_4 leads to hepatic fibrosis, cirrhosis, and hepatocellular carcinoma (33)

It has been found that concomitant administration of sulphasalazine and CCl_4 had markedly cleared fibrosis; major findings seen in CCl_4. However, there is no positive effect on steatosis. This may be an expected result according to in-vitro study reports of Oakley et al. concerning the inhibitory effect of sulphasalazine on the machinery and machinery of fibrous tissue synthesis (34).

As an interesting matter; the decrease in histopathological scores observed in mesalazine group didn't agree with sulphasalazine group although it was documented that sulphasalazine is a prodrug for mesalazine in some pharmacological actions(35). This might suggest that the action of sulphasalazine previously reported by Oakley et al. may be related to the sulphasalazine molecule at all not related to its moiety, mesalazine.

The TGF-β is the principal regulator in chronic liver injury sharing in all stages of disease progression (36). Its action begins by binding to its receptor TGFβRI and TGFβRII (37). It has been observed that TGFβR1expression occurred in the cell membrane. This agrees with Massague and Chen reports(38). It has been also shown that TGFβR1 expression was upregulated only in chronic liver toxicity; specifically phases that showed some extent of tissue remodeling prescribed by Devaux et al. (39) suggesting involvement of TGFβR1in cellular processes involved in chronic not acute liver injury. This was similar to the previous reports in myocardial infarction (MI) by Devaux et al. (39). Besides; they also showed that the maximal expression occurs in lesion areas suggesting the direct relationship between TGFβR1expression and lesions grade; a result that also is quite similar to Devaux et al. (39). It was also observed that TGFβR1expression was nearly diminished in sulphasalazine group suggesting the tight linkage between TGFβR1 expression and fibrosis but not steatosis. This result can be explained by pro apoptotic effect of sulphasalazine toward activated HSC, the major cellular promoter of fibrogenesis (40).

5. CONCLUSION

In conclusion, our findings indicate, for the first time, that TGFβR1 content is increased in chronic liver injury. TGFβR1 is upregulated in injury combined with underlying fibrosis; a result that

may suggest usage of TGFβR1 as a candidate marker for diagnosis and prognosis of chronic liver diseases and a target for liver disease therapy. Moreover, sulphasalazine exhibits a fibroprotective effect in experimental liver fibrosis. This suggests a possible use of sulphasalazine as adjuvant in therapy of chronic liver diseases.

6. References

REFERENCE LIST

(1) SHARMA A, CHAKRABORTI KK, HANDA SS. ANTIHEPATOTOXIC ACTIVITY OF SOME INDIAN HERBAL FORMULATIONS AS COMPARED TO SILYMARIN. FITOTERAPIA 1991;62:229-35.

(2) OSTAPOWICZ G, FONTANA RJ, SCHIODT FV, LARSON A, DAVERN TJ, HAN SH, ET AL. RESULTS OF A PROSPECTIVE STUDY OF ACUTE LIVER FAILURE AT 17 TERTIARY CARE CENTERS IN THE UNITED STATES. ANN INTERN MED 2002 DEC 17;137(12):947-54.

(3) ROBERTS AB. TGF-BETA SIGNALING FROM RECEPTORS TO THE NUCLEUS. MICROBES INFECT 1999 DEC;1(15):1265-73.

(4) TSUKAMOTO H. CYTOKINE REGULATION OF HEPATIC STELLATE CELLS IN LIVER FIBROSIS. ALCOHOL CLIN EXP RES 1999 MAY;23(5):911-6.

(5) DOMENICALI M, CARACENI P, GIANNONE F, BALDASSARRE M, LUCCHETTI G, QUARTA C, ET AL. A NOVEL MODEL OF CCL4-INDUCED CIRRHOSIS WITH ASCITES IN THE MOUSE. J HEPATOL 2009 DEC;51(6):991-9.

(6) MORMONE E, GEORGE J, NIETO N. MOLECULAR PATHOGENESIS OF HEPATIC FIBROSIS AND CURRENT THERAPEUTIC APPROACHES. CHEM BIOL INTERACT 2011 SEP 30;193(3):225-31.

(7) GRESSNER AM. TRANSDIFFERENTIATION OF HEPATIC STELLATE CELLS (ITO CELLS) TO MYOFIBROBLASTS: A KEY EVENT IN HEPATIC FIBROGENESIS. KIDNEY INT SUPPL 1996 MAY;54:S39-S45.

(8) NIETO N. OXIDATIVE-STRESS AND IL-6 MEDIATE THE FIBROGENIC EFFECTS OF [CORRECTED] KUPFFER CELLS ON STELLATE CELLS. HEPATOLOGY 2006 DEC;44(6):1487-501.

(9) ARDIZZONE S, BIANCHI PG. A PRACTICAL GUIDE TO THE MANAGEMENT OF DISTAL ULCERATIVE COLITIS. DRUGS 1998 APR;55(4):519-42.

(10) TUGCU V, OZBEK E, TASCI AI, KEMAHLI E, SOMAY A, BAS M, ET AL. SELECTIVE NUCLEAR FACTOR KAPPA-B INHIBITORS, PYROLIDIUM DITHIOCARBAMATE AND SULFASALAZINE, PREVENT THE NEPHROTOXICITY INDUCED BY GENTAMICIN. BJU INT 2006 SEP;98(3):680-6.

(11) HAYASHI Y, AOYAGI K, MORITA I, YAMAMOTO C, SAKISAKA S. ORAL ADMINISTRATION OF MESALAZINE PROTECTS AGAINST MUCOSAL INJURY AND PERMEATION IN DEXTRAN SULFATE SODIUM-INDUCED COLITIS IN RATS. SCAND J GASTROENTEROL 2009;44(11):1323-31.

(12) INSTITUTE OF LABORATORY ANIMAL RESOURCES (US), USE OF LABORATORY ANIMALS, NATIONAL INSTITUTES OF HEALTH (US). GUIDE FOR THE CARE AND USE OF LABORATORY ANIMALS. NATIONAL ACADEMIES; 1985.

(13) BERGMEYER HU, HORDER M, REJ R. INTERNATIONAL FEDERATION OF CLINICAL CHEMISTRY (IFCC) SCIENTIFIC COMMITTEE, ANALYTICAL SECTION: APPROVED RECOMMENDATION (1985) ON IFCC METHODS FOR THE MEASUREMENT OF CATALYTIC CONCENTRATION OF ENZYMES. PART 2. IFCC METHOD FOR ASPARTATE AMINOTRANSFERASE (L-ASPARTATE: 2-OXOGLUTARATE AMINOTRANSFERASE, EC 2.6.1.1). J CLIN CHEM CLIN BIOCHEM 1986 JUL;24(7):497-510.

(14) BERGMEYER HU, HORDER M, REJ R. INTERNATIONAL FEDERATION OF CLINICAL CHEMISTRY (IFCC) SCIENTIFIC COMMITTEE, ANALYTICAL SECTION: APPROVED RECOMMENDATION (1985) ON IFCC METHODS FOR THE MEASUREMENT OF CATALYTIC CONCENTRATION OF ENZYMES. PART 3. IFCC METHOD FOR ALANINE AMINOTRANSFERASE (L-ALANINE: 2-OXOGLUTARATE AMINOTRANSFERASE, EC 2.6.1.2). J CLIN CHEM CLIN BIOCHEM 1986 JUL;24(7):481-95.

(15) TIETZ NW, RINKER AD, SHAW LM. INTERNATIONAL FEDERATION OF CLINICAL CHEMISTRY. IFCC METHODS FOR THE MEASUREMENT OF CATALYTIC CONCENTRATION OF ENZYMES. PART 5. IFCC METHOD FOR ALKALINE PHOSPHATASE (ORTHOPHOSPHORIC-MONOESTER PHOSPHOHYDROLASE, ALKALINE OPTIMUM, EC 3.1.3.1). IFCC DOCUMENT STAGE 2, DRAFT 1, 1983-03 WITH A VIEW TO AN IFCC RECOMMENDATION. CLIN CHIM ACTA 1983 DEC 30;135(3):339F-67F.

(16) TIETZ NW, RINKER AD, SHAW LM. IFCC METHODS FOR THE MEASUREMENT OF CATALYTIC CONCENTRATION OF ENZYMES PART 5. IFCC METHOD FOR ALKALINE PHOSPHATASE (ORTHOPHOSPHORIC-MONOESTER PHOSPHOHYDROLASE, ALKALINE OPTIMUM, EC 3.1.3.1). J CLIN CHEM CLIN BIOCHEM 1983 NOV;21(11):731-48.

(17) TIETZ NW, BURTIS CA, DUNCAN P, ERVIN K, PETITCLERC CJ, RINKER AD, ET AL. A REFERENCE METHOD FOR MEASUREMENT OF ALKALINE PHOSPHATASE ACTIVITY IN HUMAN SERUM. CLIN CHEM 1983 MAY;29(5):751-61.

(18) GENDLER S. URIC ACID. KAPLAN A ET AL. CLIN CHEM THE CV MOSBY CO ST LOUIS TORONTO PRINCETON 1984;1268-73.

(19) MIHARA M, UCHIYAMA M. DETERMINATION OF MALONALDEHYDE PRECURSOR IN TISSUES BY THIOBARBITURIC ACID TEST. ANAL BIOCHEM 1978 MAY;86(1):271-8.

(20) MARKLUND SL. SUPEROXIDE DISMUTASE ISOENZYMES IN TISSUES AND PLASMA FROM NEW ZEALAND BLACK MICE, NUDE MICE AND NORMAL BALB/C MICE. MUTAT RES 1985 JAN;148(1-2):129-34.

(21) ABDEL-BAKKY MS, HAMMAD MA, WALKER LA, ASHFAQ MK. TISSUE FACTOR DEPENDENT LIVER INJURY CAUSES RELEASE OF RETINOID RECEPTORS (RXR-ALPHA AND RAR-ALPHA) AS LIPID DROPLETS. BIOCHEM BIOPHYS RES COMMUN 2011 JUN 24;410(1):146-51.

(22) BANCHROFT JD, STEVENS A, TURNER DR. THEORY AND PRACTICE OF HISTOLOICL TECHNIQUES. 1996. CHURCHIL LIVINGSTONE, NEW YORK, LONDON, SAN FRANCISCO, TOKYO.

REF TYPE: GENERIC

(23) AHSAN R, ISLAM KM, MUSADDIK A, HAQUE E. HEPATOPROTECTIVE ACTIVITY OF METHANOL EXTRACT OF SOME MEDICINAL PLANTS AGAINST CARBON TETRACHLORIDE INDUCED HEPATOTOXICITY IN ALBINO RATS. GLOBAL J PHARMACOL 2009;3(3):116-22.

(24) KALU FN, OGUGUA VN, UJOWUNDU CO, NWAOGUIKPE RN. AQUEOUS EXTRACT OF COMBRETUM DOLICHOPENTALUM LEAF-A POTENT INHIBITOR OF CARBON TETRACHLORIDE INDUCED HEPATOTOXICITY IN RATS. JOURNAL OF APPLIED PHARMACEUTICAL SCIENCE 2011;1(10):114.

(25) DALTON SR, LEE SM, KING RN, NANJI AA, KHARBANDA KK, CASEY CA, ET AL. CARBON TETRACHLORIDE-INDUCED LIVER DAMAGE IN ASIALOGLYCOPROTEIN RECEPTOR-DEFICIENT MICE. BIOCHEMICAL PHARMACOLOGY 2009;77(7):1283-90.

(26) MANIBUSAN MK, ODIN M, EASTMOND DA. POSTULATED CARBON TETRACHLORIDE MODE OF ACTION: A REVIEW. J ENVIRON SCI HEALTH C ENVIRON CARCINOG ECOTOXICOL REV 2007 JUL;25(3):185-209.

(27) WEBER LW, BOLL M, STAMPFL A. HEPATOTOXICITY AND MECHANISM OF ACTION OF HALOALKANES: CARBON TETRACHLORIDE AS A TOXICOLOGICAL MODEL. CRIT REV TOXICOL 2003;33(2):105-36.

(28) JENNINGS PE, BLANDFORD RL, ROSENTHAL FD. ACUTE SULPHASALAZINE HEPATOTOXICITY. POSTGRAD MED J 1986 APR;62(726):305-6.

(29) POSEN S, DOHERTY E. THE MEASUREMENT OF SERUM ALKALINE PHOSPHATASE IN CLINICAL MEDICINE. ADV CLIN CHEM 1981;22:163-245.

(30) KALU FN, OGUGUA VN, UJOWUNDU CO, NWAOGUIKPE RN. AQUEOUS EXTRACT OF COMBRETUM DOLICHOPENTALUM LEAF-A POTENT INHIBITOR OF CARBON TETRACHLORIDE INDUCED HEPATOTOXICITY IN RATS. 2011.

(31) DALTON SR, LEE SM, KING RN, NANJI AA, KHARBANDA KK, CASEY CA, ET AL. CARBON TETRACHLORIDE-INDUCED LIVER DAMAGE IN ASIALOGLYCOPROTEIN RECEPTOR-DEFICIENT MICE. BIOCHEM PHARMACOL 2009 APR 1;77(7):1283-90.

(32) NOORI S, REHMAN N, QURESHI M, MAHBOOB T. REDUCTION OF CARBON TETRACHLORIDE-INDUCED RAT LIVER INJURY BY COFFEE AND GREEN TEA. PAKISTAN JOURNAL OF NUTRITION 2009;8(4):452-8.

(33) TAMAYO RP. IS CIRRHOSIS OF THE LIVER EXPERIMENTALLY PRODUCED BY CC14 AN ADEQUATE MODEL OF HUMAN CIRRHOSIS? HEPATOLOGY 1983;3(1):112-20.

(34) OAKLEY F, MESO M, IREDALE JP, GREEN K, MAREK CJ, ZHOU X, ET AL. INHIBITION OF INHIBITOR OF KAPPAB KINASES STIMULATES HEPATIC STELLATE CELL APOPTOSIS AND ACCELERATED RECOVERY FROM RAT LIVER FIBROSIS. GASTROENTEROLOGY 2005 JAN;128(1):108-20.

(35) AZAD KHAN AK, PIRIS J, TRUELOVE SC. AN EXPERIMENT TO DETERMINE THE ACTIVE THERAPEUTIC MOIETY OF SULPHASALAZINE. LANCET 1977 OCT 29;2(8044):892-5.

415 (36) DOOLEY S, TEN DP. TGF-BETA IN PROGRESSION OF LIVER DISEASE. CELL
416 TISSUE RES 2012 JAN;347(1):245-56.

417 (37) DEVAUX Y, BOUSQUENAUD M, RODIUS S, MARIE PY, MASKALI F, ZHANG L,
418 ET AL. TRANSFORMING GROWTH FACTOR BETA RECEPTOR 1 IS A NEW
419 CANDIDATE PROGNOSTIC BIOMARKER AFTER ACUTE MYOCARDIAL
420 INFARCTION. BMC MED GENOMICS 2011;4:83.

421 (38) MASSAGUE J, CHEN YG. CONTROLLING TGF-BETA SIGNALING. GENES DEV
422 2000 MAR 15;14(6):627-44.

423 (39) DEVAUX Y, BOUSQUENAUD M, RODIUS S, MARIE PY, MASKALI F, ZHANG L,
424 ET AL. TRANSFORMING GROWTH FACTOR BETA RECEPTOR 1 IS A NEW
425 CANDIDATE PROGNOSTIC BIOMARKER AFTER ACUTE MYOCARDIAL
426 INFARCTION. BMC MED GENOMICS 2011;4:83.

427 (40) FRIEDMAN SL. EVOLVING CHALLENGES IN HEPATIC FIBROSIS. NAT REV
428 GASTROENTEROL HEPATOL 2010 AUG;7(8):425-36.
429
430