Short Communication

Comparative Hepatotoxic Effects of Aqueous and Phenolic Extracts of Avocado *(Persea americana)* Seed in Wistar Albino Rats

ABSTRACT

Aims: The present study was conducted to determine hepatotoxic effect of aqueous and phenolic extracts of *Persea americana* seed.

Place and Duration of Study: Department of Biochemistry, Bayero University Kano, Nigeria. November 2012 to January 2013.

Methodology: Wistar albino rats weighing 100 to 110g were divided into four groups. The aqueous and phenolic extracts were administered orally for 21 days, at a dose of 500mg/kg body weight. Blood samples were collected for the assessment of serum marker enzymes, while the liver tissue was used for histopathological Studies.

Results: The serum levels of AST, ALT, and ALP in aqueous and phenolic extracts groups were found to be significantly higher compared to control group. However, group treated with solution of phenol shows no significant pathology. The Liver biopsy of aqueous and phenolic extracts treated rats shows severe degeneration of the hepatocytes when compared with control group, while group treated with solution of phenol shows little or no significant liver damage.

Conclusion: The result suggested hepatotoxic effect of aqueous and phenolic extracts of Avocado seed, therefore administration of *P. americana* seed extracts may contribute significantly to liver damage, at higher dose.

Key Words*: Avocado seed, Hepatotoxicity, Aqueous extract, Phenolic extract, Liver enzymes*

1. INTRODUCTION

Medicinal plants constitute an effective source of both traditional and modern medicines. Herbal medicine has been shown to have genuine utility, and about 80% of rural population depends on it as primary health care [1]. Plants have been the most explored for their bioactive component, which may be therapeutic with less side effects for human use [2]. Medicinal plant according to Sofowora [3] is the one with one or more of its organs containing substances that can be used for therapeutic purposes. It was estimated that there are about 200,000-700,000 species of tropical flowering plants that have medicinal properties [4]. The most important of these chemical constituent of plants are alkaloids such as (piperidine e.g. nicotine, tropane e.g. cocaine, mescaline, anabisine, atispine etc) steroids, flavonoids, saponins, tannins etc [3].Their action include antibacterial, antiviral, antifugal, anticarcinogenic, antihelminthic etc. However, these medicinal values lie in some chemical substances contained by the plants [5].

The *Persea americana* Mill. (Lauranceae) is a plant from Central America (Mexico, Guatemala, Antilles), but it has shown easy adaptation to other tropical regions [6]. Virtually all parts of avocado

tree and its products possess one or more function. The avocado leaves have been reported to have anti-tussive and anti-diabetic properties [7]. They also provide relief from arthritic pains in addition to analgesic and anti-inflammatory properties [7]. Several beneficial medicinal properties of compounds present in the Avocado seed and peel have been reported, which are related to the elevated levels of phenolic compounds (64% in seed, 23% in peel and 13% in pulp). In addition, the seeds and peels of Avocado also contribute 57% and 38% of the antioxidant capacities of the entire fruit, respectively [8]. The seed derivatives reportedly have anti-tumour activity in rodents [9] and the oil extract from the seed is used in controlling human weight [10]. It has been reported that avocado bark and leaves are harmful to animals like cats, dogs, cattle, goats, rabbits, rats, birds, fish and horse [11]. Anderson [12] reported that avocado seeds were toxic to the method of Brine Shrimp Lethality Test/BST (LC50 below 1000ug/ml) [13]. Traditionally, the seed is used in management of diabetes mellitus and also as laxative in some part of Nigeria. However, there is no available data about its toxicity. The aim of this study is to determine the hepatotoxic effect of aqueous and phenolic extracts of *P. americana* seed on Wistar albino rats.

2. MATERIALS AND METHODS

2.1. SAMPLE COLLECTION AND PREPARATION

The ripened fruits of *Persea americana* were collected at Yan-kaba market in Kano metropolis, Nigeria. It was authenticated by a Botanist at Biological science Department, Bayero University, Kano. The seeds were removed and chopped into small pieces with a grater, air dried and then grinded into powder. The powder was percolated in distilled water as well as phenol solution, then filtered with a sieve and kept in a clean bottle and stored in a refrigerator at 4^0C. 5ml of filtered aqueous and phenolic extracts were dried separately; 730mg and 400mg of extracts were obtained respectively

2.2. EXPERIMENTAL DESIGN

The experimental rats were housed in cages and kept in a room where a 12 hour light/dark cycle was maintained in the department of Biological Sciences, Bayero University, Kano. They were allowed free access to feed and water throughout the period of the experiment. The rats were treated according to the rules and regulations of animal ethics in Nigeria.

A total of 15 albino rats of both sexes weighing 100 to 110g were divided into 4 groups of 4 rats each, with group1 having a total of 3 rats as control.

Group 1: Normal or control rats: No extract were given to them

Group 2: They were given 500mg/kg aqueous extract of avocado seed

Group 3: They were given 500mg/kg phenolic extract of avocado seed

Group 4: Treated with a solution of phenol (0.9%) only (negative control)

The various groups above were given the extract orally, for a period of three (3) weeks on daily basis in the morning and evening.

2.3. LIVER FUNCTION TEST

Aspartate Aminotransferase (AST) and Alanine Aminotransferase (ALT) activities were determined using method of Reitman and Frankel [14] while Alkaline Phosphatase (ALP) activity was determined according to Rec [15].

2.4. HISTOPATHOLOGY STUDIES

The liver biopsies were fixed with 10% formal saline and then transferred to a cassette. The cassette were immersed in a multiple bath of progressively more concentrated ethanol, cleared with toluene and infiltrated with molten paraffin wax. The processed tissue was then taken out of the cassette and set in a mold. Additional paraffin was added to create a paraffin block which is attached to outside of the cassette. The processes of embedding then allow the sectioning of tissue into very thin (2-7 micron) section using a microtome. The microtome slices are the tissue ready for microscopic examination [16], [17].

2.5. STATISTICAL ANALYSIS

All results were expressed as Mean ± standard deviation for each group. Data were calculated and analysed manually using student t-test, *p* values of less than 0.05 were considered significant.

3. RESULTS AND DISCUSSION

Sub-chronic toxicity studies of phenol solution, aqueous and phenolic extracts of avocado seed on Wistar albino rats were conducted. The transaminases and ALP are marker enzymes present in high concentrations in the liver. When liver cells are inflamed or damaged, these enzymes leak into the bloodstream leading to their rise in plasma level [18]. Their estimation in the serum is a useful quantitative marker of the extent and type of hepatocellular damage [19]. Several studies reported therapeutic efficacy of avocado seed at different concentrations regarding a dose of 500mg/kg body weight. Imafidon and Okunrobo [20] demonstrated antihypertensive and cholesterol reducing tendency of aqueous extracts of avocado seeds at 500mg/kg body weight. Also studies of Imafidon and Amaechina [21] reported the reduction of lipid profile at the dose of 500mg/kg body weight in plasma, kidney, liver and heart of hypertensive rats. Furthermore, Afahakan *et al.,* [22] shows that, administration of high fat diet along with daily oral 125mg/kg, 250mg/kg and 500mg/kg of the methanolic extracts significantly prevented the diet-induced increases in the lipid parameters in a dose-dependent manner: while it lead to significant increase in the HDL-C in a similar manner. However, there is limited data regarding the toxicity potentials of the seed. On the other hand, the acute toxicity study conducted by Eduardo *et al.,* [23] shows that avocado seed extract administered at doses of 500mg/kg, 1000mg/kg, and 2000mg/kg showed a mortality rate of 20%, 60% and 80%, respectively. However, in their main study, no genotoxicity was reported at 250mg/kg body weight.

Results of the comparative hepatotoxic studies on the activities of liver marker enzymes in Wistar albino rats are summarised in table 1. The level of serum marker enzymes of rats in group II were

found to be significantly higher ($p<0.05$) when compared with control group. This might be as a result of administration of aqueous extract of avocado seed which might have certain constituent, that affect cellular permeability of the hepatocyte. In an acute and sub-acute toxicity studies conducted by Ozolua *et al* [24], it was reported that no significant changes in ALT and AST levels after 28 days of treatment with 2.5g/kg of aqueous seed extracts and their LD_{50} could not be determined after a maximum dose of 10g/kg as the animals did not exhibit any obvious external symptoms of toxicity. However, this variation in findings with our results is difficult to explain biologically. Moreover, the acute toxicity studies conducted earlier by Ozolua *et al.,[*24] has been contradicted by the recent findings of Eduardo et al., [23] who reported toxicity at even lesser concentration. Thus, our findings support the work of Eduardo *et al*. [23]. Moreover, it was reported by William *et al.* [25] and Adel-Monein *et al.* [26] that increase in liver enzymes could be due to hepatocellular damage caused by cytotoxic agent present in some plants. ALT is selectively a liver parenchymal enzyme and a sensitive indicator of acute liver damage [18]. The level of serum AST, ALT and ALP of rats in group III were significantly higher ($p<0.05$) when compared with the control rats in control group. This might be as a result of administration of phenolic extract of avocado seed, which might have certain constituent that can induce hepatotoxicity. In phenolic extract treated rats, the rise in ALT is generally accompanied by significant elevation in the levels of AST. This finding is in line with that of Ohr *et al.* [27] who reported that feeding an avocado seed in a ratio of 1:1 with normal ration increase the level of marker enzymes greatly and finally killed the entire experimental animal tested. Phenol as an organic solvent is known to be potential toxic, however, the serum levels of AST, ALT and ALP in group treated with 0.9% of phenol solution shows no significant difference ($p<0.05$) when compared with control group. Paracelsus [28], father of toxicology, stated that all substances are toxic or poison and nothing is without poison, it is only the dose and time of exposure that permits something not be poisonous. Therefore, the insignificant toxicity observed in group IV might be as a result of low concentration of the phenol or short period of exposure.

Table 1. Effects of oral administration of phenol solution, aqueous and phenolic extract of avocado seed, on serum AST, ALT and ALP for 21 days.

	AST (IU/L)	**ALT (IU/L)**	**ALP (IU/L)**
GROUP I	9.5 ± 2.30	10.60±2.30	119.6 ± 31.87
GROUP II	22.25 ± 9.85*	36.25 ± 13.88**	270.48 ± 41.49**
GROUP III	31.25 ± 12.27**	45.75 ± 20.95**	291.88 ± 64.08**
GROUP IV	9.75 ± 2.98	12.0 ± 0.00	151.8 ± 52.85

Results are presented as Mean ± standard deviation; *: significant, **: highly significant. Different Superscript indicates significant difference at $p< 0.05$.

Liver section of control and treated rats were analyzed as shown in figure 1 a-d. It was carried out to ascertain the extent of hepatotoxic effect caused by phenol solution, aqueous and phenolic extracts of *Persea americana* seed. Figure 1(a) shows the liver section of group I rats had normal liver cells architecture, where the central veins, portal tracts, hepatocytes and sinusoids appear normal. The lobular units were also well identified. Liver section of rats in group IV (Figure 1d) shows no significant pathological changes when compared with the rats in group I. The liver section of Group II rats (Figure 1b) shows damage to the liver cells. There were extensive areas of patchy and confluent hepatocyte necrosis and lobular inflammation; sinusoidal spaces were flooded with inflammatory cell and red blood cells when compared with the liver architecture of the control rats. The photomicrography liver section of phenolic extracts treated rats in group III (Figure 1c) shows severe degeneration of the hepatocyte and collapse of the normal liver architecture, when compared with the control liver section whose hepatocytes were arranged in cord, radiating from central vein. The photomicrography liver section of group III treated rats shows more severe hepatocytes degeneration when compared with group II, which indicates higher toxicity. The central veins in the hepatocytes of group III rats were embedded with fat; this might be as a result of lipophilic characteristics of phenol, which in turn increases its cellular uptake. The high serum level of marker enzymes as well as severity of liver damage observed in group III when compared to rats in group II might be as a result of variation in the solvent used for extraction. Since phenol is organic solvent it will extract more Phytochemicals from the seed than water, moreover, phenol is acidic as such it can damage the hepatocytes which increases the release of enzymes AST, ALT and ALP.

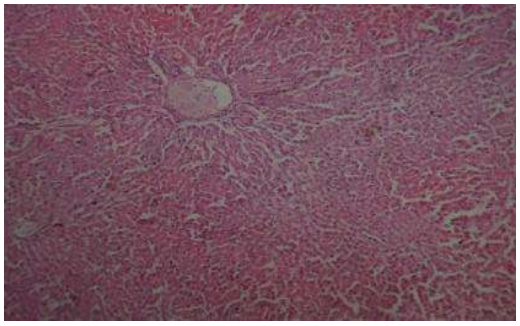

Figure 1(a): normal rat hepatocytes ×100

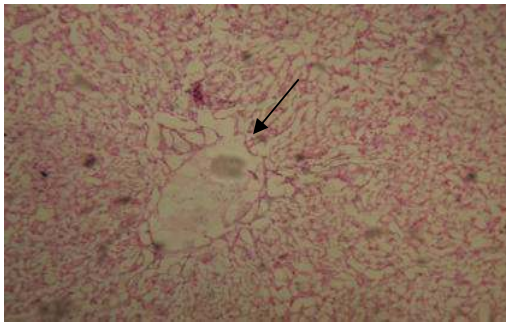

Figure 1(b): aqueous extract treated rat hepatocytes ×100

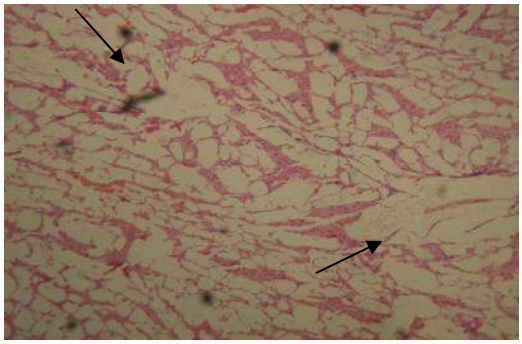

Figure 1(c): Phenolic extract treated rat hepatocytes ×200

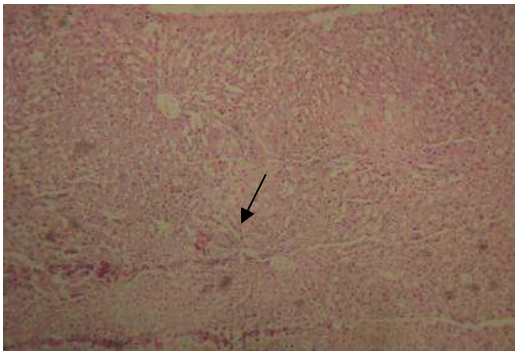

Figure 1(d): phenol solution treated rat hepatocytes ×100

4. CONCLUSION

The result of this study indicates that the daily oral administration of the aqueous and phenolic extract of *Persea americana* seed for a period of 3 weeks at a dose of 500mg/Kg has shown a Hepatotoxic effect. The histopathological analysis of the treated rat's liver shows degeneration of the hepatocyte and collapse of the liver architecture, thus, indicating liver damage. Further studies should be carried out by varying the dosage used in this study and also duration of the studies should be increased (chronic toxicity). Histopathological studies should also be carried out on other vital organs like kidney, brain etc. Isolation and characterization of active principles present in the seed should be carried out, to identify the possible toxic component of the seed.

REFERENCES

1. Babandi, A., Ibrahim, A., Murtala, Y. and Yakasai, M.H. Comparative Assessment of Phytochemicals and Trace Elements Composition of *Azadirachta indica* and *Calotropis procera* Roots. *Biological and Environmental Sciences Journal for the Tropics.* (2012). 9(2): 123-126

2. Burkil, H.M. The Useful Plants of West Tropical Africa. 2nd ed. Royal Botanic Garden, Kew Richmonal, United Kingdom (2008), Pp. 686.

3. Sofowora, A. Medicinal Plants and Traditional Medicine in Africa; Spectrum Books ltd, Ibadan (1993). Pp 220-224.

4. Atata, R.F., Sani, A.B. and Ajewali, S.M. Effect of stem bark *enantia chloranta* on some clinical isolates, *Biokemistri* (2003). 15:84-92.

5. Olodumaye, P., Delmer, D.P. and Carlson, R.W. Identification of a novel interpenoid saponin from *Pasium sativion* as a specific inhibitor of dignarmylate of Acetobacter xylenum (1998). 39:144-152.

6. Joao Jaime Giffoni Leite, Erica Helena Salles Brito, Rossana Aguiar Cordeiro, Raimunda Samia Nogueira Brilhante, Jose Julio Costa Sidrim, Luciana Medeiros Bertini, Selene Maia de Morais and Marcos Fabio Gadelha Rocha. Chemical Composition, Toxicity, Larvicidal and Antifungal activities of *Persea americana* (Avocado) seed Extracts (2009). 42(2): 110-113

7. Adeyemi, O.O., Okpo, S.O. and Ogunta, O.O. Analgesic and Anti inflammatory effect of the aqueous extract of leave of *Persea americana* mill (*Lauraceae*). *fitoterapia* (2002). 7**3**:375-380.

8. Maria Elena Pahua-Ramos, Alicia Ortiz-Moreno, German Chamarro-Cevallos, Maria Dolores Hernandez-Navarro, Leticia Garduno-Siciliano, Hugo Necoechea-Mondragon, Marcela Hernandez-Ortega. Hypolipedemic Effect of Avocado (Persea americana mill) seed in a Hypercholestrolemic mouse model. *Plant Foods Hum. Nutr.* (2012). 67: 10-16

9. Boulton, A., Malik, R., Arezzoc, M. and Sosenko, J. Diabetic Somatic neurapathies. *Diabetic Care* (2004). 27:1458-1486.

10. Roger, C.R. The Nutritional Evidence of flavanoid: Some physiologic and metabolic considerations. *Eperantia* (1988). 44(9): 725-784.

11. Clipsham, R. Avocado toxicity http://kgkat.tripod.com/avocado.html (2007).

12. Anderson, J.E., Goestz C.M. and Mc Laughlin J.L. A Blind Comparison of Simple Bench-top Bioassay and Human Tumour cell Cytotoxicities as Antitumour Prescreens in Natural Product Chemistry. *Elsevier*. Amsterdam, (1991).

13. Ruth Elenora Kristanty, Junie Suriawati, Joko Sulistiyo. Cytotoxic Activity of Avocado Seeds Extracts (Persea americana mill)On T47D cell Lines. International Research Journal of Pharmacy (2014). 5(7): 557-559

14. Reitman, S. and Frankel, S. A colorimetric method for the determination of serum glutamic-oxaloacetate and glutamic-pyruvic transaminase. *Am. J.chin. Pathol* (1957). 28:56.

15. Rec, G.S. Colorimetric method for serum alkaline phosphatase determination. *J. Clin. Biochem* (1972). 10(2):182.

16. Avwioro, O.G. Histochemistry and Tissue pathology: Principles and Technique 2nd edition. (2010). University Press,Delta State University, Abraka Nigeria.

17. Mitchell, R., Kumar, V., Abbas, A. and Fausto, N. Basic Pathology. Philadelphia: Saunders. 8th edition, 2011. Pp. 340-352

18. Khan, I.A., Reddy, B.V., Mahboob, M., Rahman, M.T and Jamil, K. Effect of Phosphorothionate on productive system of male rats. *J. Eviron. Sci. Health* (2011). 36:445:456.

19. Mitra, S.K., Venkataranganna, M.V. and Sundaran, R. Protective Effect of HD-03, a herbal formulation against hepatotoxic agent in rat. *J. Ethnopharmacol* (1998). 63:18-16.

20 Imafidon E. Kate and Okunrobo O. Lucky. Biochemical evaluation of the tradomedicinal use of seed of *Persea americana* Mill.(family: *laurenceae). World Journal Of Medical Sciences.* (2009) 4(2):143-146.

21 Imafidon E. Kate and Amaechina, F. C. Effects of aqueous seed extract of *Persea americana* Mill (avocado) on blood pressure and lipid profile in hypertensive rats. *Advances in Biological Research* (2010) 4(2):116-121.

22 Afahakan Mfonobong, Umar Ismail, Inuwa Hajiya Mairo, Zubairu Maimuna, Dawud Fatima. Hypolipidemic and antioxidant effects of petroleum ether and methanolic fractions of *Persea americana* Mill seeds in Wistar rats fed a High-fat High-cholesterol diet. *Int. J. Med. Pharm Sci* (2013) **3**(12):1-10.

23 Eduardo Padilla-Camberos, Moises Martinez-Velazquez, Jose Miguel Flores-Fernandez, and Socorro Villanueva-Rodriguez. Acute toxicity and genotoxic activity of avocado seed extract (*Persea americana* Mill., c.v Hass). *The scientific world journal* (2013).

24 Raymond I. Ozolua, Ogochukwu N. Anaka, Stephen O. Okpo, and Sylvester E. Idogun. Acute and sub-acute toxicological assessment of the aqueous seed extract of *Persea americana* Mill. (Laurenceae) in rats. *Afr. J. Traditional, complementary and alternative medicines*, (2009). **6**(4):573-578.

25 William, F., Balistreri, M.D. and Robert, R. Liver Function In: Burtis, USA C.A and Ashwood, E.R. eds. Tietz Fundamentals of Clinical Chemistry, W.B. Saunders Company (1997). Pp. 539-549.

26 Adel- monein, A., El-Feki, M. and Salah, E. Effect of *Nigella Sativa,* fish oil and glicalzde on alloxan diabetic rats, Biochemical and Histopathological Studies. *J. Egy. Ger. Soci. Zool* (2011) 2**3**:237-265.

27 Ohr, D., Coffer, D. and Mc Millan, T. Common Name of Plant Diseases. *American Phytopat.* (2003). 25:345-410.

28 Paracelsus, M. “Dose response handbook of pesticide toxicity” William C. Krieger, Academic Press (2008). Pp. 12-14.