Effects of chronic consumption of monosodium glutamate in Sprague Dawley rats' liver

Running Headline: Severity of MSG in rats liver

ABSTRACT

The safety of monosodium glutamate (MSG) usage has generated much controversy, because of the toxic nature of monosodium glutamate which is often added to food to improve taste and the unease that this may have deleterious effect on many organs of the body is on the increase. The evaluation of the effect of monosodium glutamate (analytical and commercial grade) on the liver of Sprague-Dawley rats was carried out. Monosodium glutamate administration caused significant increase in the body weight of experimental rats also the serum revealed that the transaminase enzyme levels were significantly up-regulated. Evidence from histological data confirmed structural changes like hydropic degeneration of hepatocytes, periportal cellular infiltration by mononuclear cells, severe portal and central venous congestion which is an indication that the liver functions may have been affected.

Keywords: Monosodium glutamate; histopathology; liver; rats; hepatocytes

INTRODUCTION

Monosodium glutamate (MSG) is a non-essential amino acid that occurs naturally and it is also called sodium salt of glutamic acid (Ninomiya, 1998). It is found naturally occurring in some fruits and vegetables (Specter, 2014). The commercial-grade is sold in most open market stalls and stores in Nigeria as "Ajinomoto". In most food industry MSG is used to enhance flavour with a pleasant taste just as the glutamate that occurs naturally (Ikeda, 2002).

Monosodium glutamate is often used for taking away stains from cloth in some communities in Nigeria. Although, there are various reports on the toxic nature of MSG to human and animals but it still improves appetite and taste (Belluardo *et al*., 1990). Numerous conditions have been known to be caused by MSG; these conditions include abdominal discomfort, asthma, ventricular arrhythmia, urticaria, neuropathy and atopic dermatitis (Geha *et al*., 2001). Onakewhor *et al*. (1998) reported that MSG caused abnormal increase in sperm morphology and oligozoospermia in male wistar rats' dose dependently. It has also been reported by Oforofuo *et al*. (1997) to cause degeneration of sperm cell population and

morphology as well as testicular hemorrhage. MSG has a toxic effect on many body organs by altering ionic permeability of neural membrane and induces persistent depolarization (Robinson, 2006). Conditions like stroke, epilepsy, brain trauma, neuropathic pain, schizophrenia, anxiety, depression, Parkinson's disease, Al-zheimer's disease, Huntington's disease, and amyotrophic lateral sclerosis have been reported to be neurotoxic effects of MSG (Samuels, 1999).

The liver is the largest glandular organ of the body, weighing between 1.4-1.6kg (Johnson, 1995) and the function in the body includes plasma protein synthesis, glycogen storage, production an alkaline compound (bile) that helps in digestion, and detoxification of most substances (Gartner *et al*., 2000). Since the liver is involved in the performance of these varied functions, it may be susceptible to injury resulting from toxic substances. This study is therefore designed to evaluate the effects of monosodium glutamate in the liver of experimental animals

MATERIALS AND METHOD

Chemicals

Analytical grade MSG ($C_5H_8NNaO_4.H_2O$) and the commercially available food grade package sold in most open market in Nigeria were the chemicals used in this study. Stock solution was prepared by dissolving known gram (g) of both analar grade and food-grade monosodium glutamate crystals differently in separate bottles in known millilitres (mL) of

distilled water. The dose scheduled was adjusted so that the amount of MSG administration per animal was as per their respective group body weights.

Experimental Animals

Fifty (50) female Sprague-Dawley rats bred in- house with an average weight of about 100 – 150g were used for the experiment. The experimental rats had free access to food and water; they were also maintained under standardized conditions away from any stressful conditions. All experimental procedures and animal maintenance were conducted in strict accordance with the ethical guidelines of the animal care unit of the Department of Physiology, Ladoke Akintola University of Technology, Ogbomoso, Oyo State, Nigeria.

Clinical examination of the experimental animals

Prior to MSG administration, the weights of all the animals were recorded and all rats were confirmed to be healthy. The experimental animals were randomly divided into 5 groups of 10 rats each. Group I received 0.10g/kg body weight, Group II 0.15g/kg body weight, Group III 0.20g/kg body weight of analar grade MSG in 1.5ml of water daily while Group IV received 0.20g/kg body weight of commercial food grade MSG also in 1.5ml of water daily for fourteen days. Group V served as the control and all grades of MSG were administered orally.

Biochemical Analysis of the serum

Blood samples of the rats were taken through the ocular route at the end of treatment period and serum was separated by centrifugation at 3000rpm for 10 min. The serum was collected and used for analysis, which included blood glucose, total protein, albumin, globulin and enzymes activities (AST and ALT).

Cholesterol and glucose assay

The method of Siedel *et al*. (1981) was used to determine cholesterol by enzymatic colorimetric reaction and glucose was determined by spectrophotometric method as described by Teuscher and Richterich (1971).

Transaminases assay:

The method of Schmidt (1963) and Oladipo *et al*. (2014) was used to determine ALT and AST by spectrophotometric method.

Total serum protein assay

Total serum protein was determined using the biuret method as described by Reinold (1953).

Albumin assay

Albumin was determined using the BGG (Bromocresol green) method as described by Peters *et al*. (1982).

Histological analysis of the liver

The animals were sacrificed by cervical dislocation at the end of the experimental period and they were dissected, the livers were removed and fixed in 10% formalin solution for routine histological techniques. The tissue pieces were embedded in paraffin and sections were then cut with a microtome, stained with hematoxylin and eosin and assessed under an Olympus microscope (Olympus Optical Co., GMBH, Hamburg, Germany). Images were captured using Camedia software (E20P 5.0 Megapixel;Hamburg, Germany) at 20X magnification

Statistical Analysis

Statistical analyses of the data gathered were processed using SPSS 17.0 software. Comparison between groups was made using One-way Analysis of variance (ANOVA).

RESULTS

It was noted that monosodium glutamate increased appetite and thirst in the experimental animals. Also, there was increase in the body weight of the experimental animals with more significant increase in the Group III animals after the experimental period as shown in Table 1.

Evaluation of the sera of experimental animals showed that monosodium glutamate administration elevated the expressions of transaminase enzymes; also the levels of globulin and total protein fractions were up-regulated. But glucose and cholesterol levels were down-regulated with the exception of the cholesterol level of group III animals as can be seen in Table 2.

It was confirmed from the histological data that there was a mild diffuse hydropic degeneration of hepatocytes in the group I animals. Moderate periportal cellular infiltration by mononuclear cells was seen in the group II rats. Also, the group III animals showed severe portal and central venous congestion while group IV showed a mild periportal cellular infiltration when compared with the control group as shown in Figure 1.

Table 1**:** Body weight of experimental animals before and after MSG administration

Groups	Weight before treatment	Weight after treatment
Group I	$120 \pm 1.73^{a,b}$	134 ± 2.00^{b}
Group II	$130 \pm 8.54^{a,b}$	144 ± 1.53^{c}
Group III	140 ± 4.04^{b}	162 ± 2.00^{d}
Group IV	110 ± 4.04^{a}	129 ± 0.57^{b}
Group V	110 ± 9.01^{a}	120 ± 0.58^{a}

Value = mean ± standard deviation; values followed by the same alphabets in the same column are not significantly different ($p \leq 0.05$).

Table 2**:** Biochemical analysis of the blood sera of experimental rats

Parameters	Group I	Group II	Group III	Group IV	Group V
AST (µKat/L)	1.63 ± 0.41[c]	1.66 ± 0.19[c]	1.74 ± 0.18[b]	1.78 ± 0.16[b]	1.51 ± 0.10[a]
ALT (µKat/L)	0.47 ± 0.06[c]	0.47 ± 0.02[c]	0.49 ± 0.07[a]	0.51 ± 0.07[a]	0.38 ± 0.07[b]
ALB (µmol/L)	6.23 ± 0.22[b]	6.67 ± 0.39[bc]	6.73 ± 0.31[c]	6.59±0.18[b]	6.12 ± 0.49[a]
TP (g/L)	84.75±4.88[c]	84.96±9.45[c]	86.94 ± 2.11[c]	76.42±5.31[b]	69.60±8.75[a]
GLOB (g/L)	45.82±7.93[c]	47.44±3.95[c]	48.65±5.28[c]	37.82±5.41[b]	34.25±10.98[a]
CHOL (mg/dL)	77.18±16.36[d]	79.93±7.88[d]	94.74±11.31[c]	64.66±2.24[a]	87.10±11.97[b]
GLU (mmol/L)	4.47±0.94[b]	4.77±0.96[b]	5.21±0.28[c]	5.26±1.72[c]	5.41±0.79[a]
BIL (µmol/L)	7.29±2.82[b]	8.65±1.46[c]	9.86±7.84[d]	6.71±1.95[b]	6.90±0.91[a]

Value = mean ± standard deviation; values followed by the same alphabets in the same row are not significantly different ($p \leq 0.05$). GI = Group I; GII = Group II; GIII = Group III; GIV = Group IV; GV = Group V.

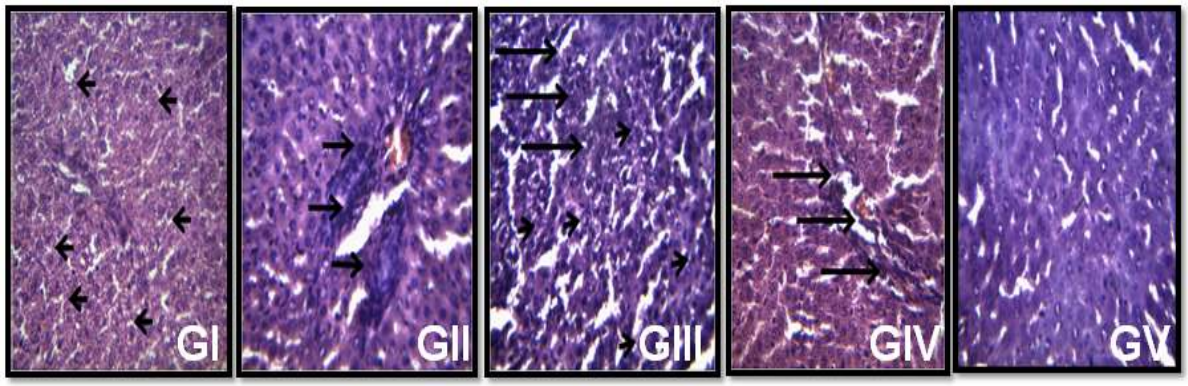

Figure 1: Histology of the livers of experimental rats after MSG treatment. GI = Group I (Arrow shows mild diffuse hydropic degeneration of hepatocytes); GII = Group II (Arrows indicating moderate periportal cellular infiltration by mononuclear cells); GIII = Group III (Arrow shows severe portal and central venous congestion); GIV = Group IV (Arrows indicating a mild periportal cellular infiltration); GV = Group V.

DISCUSSION AND CONCLUSION

One of the widely used additives and flavouring agents in food is monosodium glutamate and it is mostly used to enhance preference and taste in food (Walker and Lupien, 2000; Chaudari and Roper, 1998). But diseases like ventricular arrhythmia, endothelial dysfunction brain lesion, diabetes, coronary heart disease and cancer have been associated with the consumption of monosodium glutamate (Dinz *et al.*, 2005; Mallick, 2007).

The significant body weight increase observed in this study has been previously reported by Oladipo *et al*. (2015). The significant elevation of the expressions of transaminase enzymes in the sera of experimental animals is an indication of liver damage as tansaminase enzymes are discharged in to the blood upon liver damage and thus are used as liver damage marker (Al-Mamary, 2002). The significant down-regulation of glucose levels in the experimental animals is an indication of reduction in the tolerance of glucose (Diniz *et al*., 2004).

In this study, liver sections of rats treated with low dose of analar MSG showed considerable structural changes, amongst which was mild diffuse hydropic degeneration of hepatocytes. This is in alignment with the previous work of Singh (1997) who reported the distortion and dilatation of the hepatocytes and their central vein. He further reported that the haematopoietic function of the liver may have been highly affected as a result of probable toxic effect of MSG. As reported by Singh (1997), MSG may have acted as toxins to the hepatocytes, thereby affecting their cellular integrity and causing defect in membrane permeability and cell volume homeostasis. The hydropic and degenerative changes observed in this experiment may have been caused by the cytotoxic effect of MSG on the liver; which is in agreement with Waters *et al*. (1994).

The liver section of the rats treated with food grade MSG showed a mild periportal cellular infiltration by mononuclear cellS. This is supported by Butler (1996) who reported hepatocellular necrosis in the periportal areas and fibroplasia with mononuclear leucocytic infiltration. The observed necrosis might lead to hepatitis as reported by Nwaopara *et al*. (2007) and the infiltration of mononuclear leucocytes into the portal area was probably an adaptive cellular response to possible hepatitis resulting from the toxic effects of MSG.

Furthermore, the animals administered with high dose of analar MSG showed severe portal and central venous congestion. Seeto *et al*. (2000) stated that liver failure had severe

underlying cardiac disease that had often led to passive congestion of the liver. Also, Eweka *et al*. (2007) revealed that with increasing dose of monosodium glutamate consumption; there was varying degrees of dilatations of the central vein of the liver which contain lysed red blood cells. This suggests that the distortion of the cyto-architecture of the liver could be associated with functional changes that may be detrimental to the health of the rats.

In conclusion, the results of the present investigation have shown that mono-sodium glutamate (MSG) is capable of producing alterations in the body weight and liver functions. These alterations appear in the liver probably because it is mainly responsible for detoxification of foreign compounds in the body.

REFERENCES

Ajibade A. J., Fakunle P. B., Olayemi O. T. and Adetogun A. A. (2011). Some morphological observations on the heart of adult wistar rats following exposure to aqueous extract of *Ocimum gratissimum. International Journal of Current Research* 3(12): 100-104.

Al-Mamary M, Al-Habori M, Al-aghbari AM & Basker MM (2002). Investigation into the toxicological effects of *Catha edulis* leaves. A short term study in animals. *Phytotheraphy Research* 16(2): 127-132

Belluardo, M., Mudo, G. and Bindoni, M. 1990. Effect of early destruction of the mouse arcuate nucleus by MSG on age dependent natural killer activity: *Brain Res*., 534: 225-333.

Chaudari N. and Roper S.D (1998). Molecular and physiological evidence for glutamate (Umami) taste transduction via a G protein-coupled receptor. Ann N.Y Acad.sci, 855: 398-405.

Diniz, Y.S., Fernando, A.A., Campos, K.E., Mani, F., B. Ribas, D., and Novelli, E.L. (2004). "Toxicity of Hyper Caloric Diet and Monosodium Glutamate: Oxidative Stress and Metabolic Shifting in Hepatic Tissue," *Food and Chemical Toxicology* 42: 319-325.

Diniz, Y.S., Faine, L.A., Galhardi, C.M., Rodrigues, H.G., Ebaid, G.X., Burneiko, R.C., Cicogna, A.C. and Novelli, E.L.B. (2005). Monosodium glutamate in standard and high fiber diets: metabolic syndrome and oxidative stress in rats. *Nutrition* 21: 749-755.

Gartner L.P. and Hiatt J.L. (2000). Color Atlas of Histology. 3rd Ed. New York: Lippincott Williams and Wilkins Publishers; pp. 294–301.

Geha, R.S., Beiser, A., Ren, C., Patterson, R., Grammar, L.C., Ditto, A.M., and Harris, K.E. (2001). “Review of Allergic Reaction to Monosodium Glutamate and Outcome of a Multicenter Double Blind Placebo-Controlled Study,” *Journal of Nutrition* 130:1032S-1038S.

Ikeda K. (2002). "New seasonings". Chem Senses 27 (9): 847–849

Johnson P. (1995). “The Assessment of Hepatic Function and Investigation of Jaundice,” In: W. Marshall and S. Bangert, (Eds.), Clinical Biochemistry: Metabolic and Clinical Aspects, Churchill Livingstone, New York, pp. 217- 236.

Mallick H. N. (2007). Understanding safety of glutamate in food and brain. *Ind. J. Physiol. Pharmacol*. 51: 216-234.

Nayira, A., Abdel B., Azza M. M. and Faddah, L.M. (2009). Protective effect of N-acetyl Cysteine and /or Pro vitamin A against Monosodium Glutamate Induced Cardioparthy in Rats. *Journal of pharmacology and Toxicology* 4(5): 178-193.

Ninomiya K. (1998). Technical Committee, Umami Manufacturers Association of Japan. "Natural occurrence". *Food Reviews International* 14 (2 & 3): 177- 211.

Oforofuo, I. A. O., Onakewhor, J. U. E. and Idaewor, P. E. (1997). “The Effect of Chronic Administration of MSG on the Histology of the Adult Wistar Rat Testes,” *Bioscience Research Communications*.9: 2

Oladipo I. C., Sanni, A. I., Chakraborty W., Chakravorty S., Jana S., Rudra D. S., Gacchui R. and Swarnakar S. (2014) Bioprotective Potential of Bacteriocinogenic *Enterococcus gallinarum* Strains Isolated from Some Nigerian Fermented Foods, and of Their Bacteriocins. *Polish Journal of Microbiology.* 63 (4): 415–422

Oladipo I. C., Adebayo E. A. and Kuye O. M. (2015). Effects of monosodium glutamate in ovaries of female sprague-dawley rats. *Int.J.Curr.Microbiol.App.Sci* 4(5): 737-745

Oluba, O. M., Onyeneke, E. C., Idonije, B. O. and Eidangbe, G. O. (2011): Effect of Soy Protein on Monosodium Glutamate (MSG)-induced Obesity in Rats. *Asian J. Pharm. Biol. Res.* 1 (1): 8-14.

Onakewhor, J.U.E., Oforofuo, I.A.O and Singh, S.P (1998)“Chronic Administration of Monosodium Glutamate In- duces Oligozoospermia and Glycogen Accumulation in Wistar Rat Testes,” *Africa Journal of Reproductive Health* 2 (2): 190-197.

Peters, T., Biamonte, G.T. and Doumas, B.T. (1982). Protein [total protein] in serum, urine and cerebrospinal fluid; albumin in serum. *Selected method* of *clinical chemistry*. Vol. 9.

Reinold J. G. (1953). Standard methods of clinical chemistry. ED. Reiner Acad Press, New York. 88.

Rhodes, J., Titherley, A. C., Norman, J. A., Wood, R. and Lord, D. W. (1991). "A Survey of the Monosodium Glutamate Content of Foods and an Estimation of the Dietary Intake of Monosodium Glutamate," *Food Additives and Contaminants*, 8(5): 663-672.

Robinson, M. B. (2006). Acute regulation of sodium-dependent glutamate transporters: a focus on constitutive and regulated trafficking. *Handb.Exp.Pharmacol*., 175: 251–275.

Samuels A. (1999) "The toxicity/safety of MSG: a study in Suppression of information," *Accountability in Research.* 6 (4): 259-310.

Schmidt, E., and Schmidt, F.W. (1963). Enzym-Bestimmungen im Serum bei Leber-Erkrankungen. Funktions-Muster ala Hilfsmittel der Diagnose. *Enzym. Biol. Clin.* 3:1.

Siedel, J., Schlumberger, H., Klose, S., Ziegenhorn, J., Wahlefeld, A.W. (1981). Improved reagent for the enzyme determination of serum cholesterol. *J. Clin. Chem. Clin. Biochem.* 19: 838-839

Specter, M. (2014). "What's So Bad About Gluten?". New Yorker magazine

Teuscher, J. and P. Richterich, (1971). Enzymatic Method of Glucose. *Schaveiz Med. Wschr,* 101: 345-390.

Walker, R. and Lupien, J. R. (2000). "The Safety Evaluation of Monosodium Glutamate," *Journal of Nutrition*, 130(4S Suppl): 1049S- 1052S.