UNDER PEER REVIEW

Original Research Article

Comparative Hepatotoxic Effects of Aqueous and Phenolic Extracts of Avocado *(Persea americana)* Seed in Wistar Albino Rats

ABSTRACT

Aims: The present study was conducted to determine hepatotoxic effect of aqueous and phenolic extracts of *Persea americana* seed.

Place and Duration of Study: Department of Biochemistry, Bayero University Kano, Nigeria. between November 2012 to January 2013.

Methodology: Wistar albino rats weighing 100 to 110g were divided into four groups. The aqueous and phenolic extracts were administered orally for 21 days, at a dose of 500mg/kg body weight. Blood samples were collected for the assessment of serum marker enzymes, while the liver tissue was used for histopathological Studies.

Results: When compared with normal control group, there was significant difference in the level of serum AST, ALT, and ALP in aqueous and phenolic extracts group. However group IV treated rats show no significant pathology. The Liver biopsy of group II and III treated rats show severe degeneration of the hepatocytes when compared with group I while group IV show little or no significant liver damage.

Conclusion: The result suggested hepatotoxic effect of aqueous and phenolic extracts of Avocado seed, therefore administration of *P. americana* seed extracts may contribute significantly to liver damage, at higher dose.

***Key Words**: Avocado seed, Hepatotoxicity, Aqueous extract, Phenolic extract, Liver enzymes*

1. INTRODUCTION

Medicinal plants constitute an effective source of both traditional and modern medicines. Herbal medicine has been shown to have genuine utility, and about 80% of rural population depends on it as primary health care [1]. Plants have been the most explored for their bioactive component which may be therapeutic with less side effects for human use [2]. Medicinal plant according to [3] is the one with one or more of its organs containing substances that can be used for therapeutic purposes. It was estimated that there are about 200,000-700,000 species of tropical flowering plants that have medicinal properties [4]. The most important of these chemical constituent of plants are alkaloids such as (piperidine e.g. nicotine, tropane e.g. cocaine, mescaline, anabisine, atispine etc) steroid, flavanoid, saponin, tannin etc [3].Their action include antibacterial, antiviral, antifugal, anticarcinogenic, antihelminthic etc. However, these medicinal value lie in some chemical substances contained by the plants [5].

The *Persea americana* Mill. (Lauranceae) is a plant from Central America (Mexico, Guatemala, Antilles), but it has shown easy adaptation to other tropical regions [6]. Virtually all parts of avocado

UNDER PEER REVIEW

tree and its products possess one or more function. The avocado leaves have been reported to have anti-tussive and anti-diabetic properties [7]. They also provide relief from arthritic pains in addition to analgesic and anti-inflammatory properties [7]. Several beneficial medicinal properties of compounds present in the Avocado seed and peel have been reported, which are related to the elevated levels of phenolic compounds (64% in seed, 23% in peel and 13% in pulp). In addition, the seeds and peels of Avocado also contribute 57% and 38% of the antioxidant capacities of the entire fruit, respectively [8]. The seed derivatives reportedly have anti-tumour activity in rodents [9] and the oil extract from the seed is used in controlling human weight [10]. It has been reported that avocado bark and leaves are harmful to animals like cats, dogs, cattle, goats, rabbits, rats, birds, fish and horse [11]. Anderson [12] reported that avocado seeds were toxic to the method of Brine Shrimp Lethality Test/BST (LC50 below 1000ug/ml) [13]. The aim of this work is to determine the hepatotoxic effect of aqueous and phenolic extracts of *P. americana* seed on wistar albino rats.

2. MATERIALS AND METHODS

2.1. SAMPLE COLLECTION AND PREPARATION

The fruits of *Persea americana* were ~~collected at Yan-kaba market in Kano metropolis, Nigeria. It was~~ authenticated by a Botanist at Biological science Department, Bayero University, Kano. The seeds were removed and chopped into small pieces ~~in a grater~~, air dried and then grinded into powder. The powder was percolated in distilled water as well as phenol solution. The crude extract from both solutions are then filtered with a sieve, and concentrated to dryness on a water bath. The filtrates were kept in a clean bottle and stored in a refrigerator for further use.

2.2. EXPERIMENTAL DESIGN

The experimental rats were housed in cages and kept in a room where a 12 hour light/dark cycle was maintained ~~in the department of Biological Sciences, Bayero University, Kano~~. They were allowed free access to feed and water throughout the period of the experiment.

A total of 15 albino rats were divided into 4 groups of 4 rats each, with group1 having a total of 3 rats as control.

Group 1: Normal or control rats: No extract were given to them

Group 2: They were given 500mg/kg aqueous extract of avocado seed

Group 3: They were given 500mg/kg phenolic extract of avocado seed

Group 4: They were given 0.9% phenol solution.

The various groups above were given the extract orally, for a period of three (3) weeks on daily basis in the morning and evening.

UNDER PEER REVIEW

2.3. LIVER FUNCTION TEST

Aspartate Aminotransferase (AST) and Alanine Aminotransferase (ALT) were determined using method of Reitman and Frankel [14] while Alkaline Phosphatase (ALP) was determined according to Rec [15].

2.4. HISTOPATHOLOGY STUDIES

The liver biopsies were fixed with 10% formal saline and then transferred to a cassette. The cassette were immersed in a multiple bath of progressively more concentrated ethanol, cleared with toluene and infiltrated with molten paraffin wax. The processed tissue was then taken out of the cassette and set in a mold. Additional paraffin was added to create a paraffin block which is attached to outside of the cassette. ~~The processes of embedding then allow the sectioning of tissue into very thin (2-7 micron) section using a microtome. The microtome slices are the tissue ready for microscopic examination~~ [16], ~~[17]~~.

2.5. STATISTICAL ANALYSIS

All result was expressed as mean ± standard deviation for each group. Data were analysed using student t-test, P values of less than 0.05 were considered significant.

3. RESULTS AND DISCUSSION

Sub-chronic studies of phenol solution, aqueous and phenolic extracts of avocado seed on wistar albino rats were conducted. The transaminases and ALP are marker enzymes present ~~in~~ high concentrations in the liver, when liver cells are inflamed or damaged, these enzymes leak into the bloodstream leading to a rise in the plasma level of these enzymes [18]. Their estimation in the serum is a useful quantitative marker of the extent and type of hepatocellular damage [19]. Results of the comparative hepatotoxic studies on the activities of liver marker enzymes in Wistar albino Rats are summarised in table 1. The level of serum marker enzymes of rats in group II was found to be significantly higher ($P<0.05$) when compared with that of group I. This might be as a result of administration of aqueous extract of avocado seed that might have certain constituent, which affect cellular permeability of the hepatocyte. Result of studies conducted by Wittekind [20] and Karthikeyan et al. [21] reported non toxic effect of aqueous extract of avocado seed at a dose of 10mg/kg body weight. The plausible rationale for these differences can be as a result of dose used in this research (500mg/kg). Moreover, it was reported by William *et al.* [22] and Adel-Monein *et al.* [23] that increase in liver enzymes could be due to hepatocellular damage caused by cytotoxic agent present in some plants. ALT is selectively a liver parenchymal enzyme and a sensitive indicator of acute liver damage [18]. The level of serum AST, ALT and ALP of rats in group III were significantly higher ($P<0.05$) when compared with the control rats in group I. This might be as a result of administration of phenolic extract of avocado seed, which might have certain constituent that can induce hepatotoxicity. The rise in ALT is generally accompanied by significant ~~elevation~~ in the levels of AST. This finding is in line with that of Ohr *et al.* [24] who reported that feeding an avocado seed in a ratio of 1:1 with normal

UNDER PEER REVIEW

ration increased the level of marker enzymes greatly and finally killed all the experimental animal tested (mice). The serum levels of AST, ALT and ALP in group IV showed no significant difference (P<0.05) when compared with group I. ~~This might be as a result of low concentration of the phenol or short period of exposure, this is in line with findings of Paracelsus [25] who stated that all substances are toxic or poison and nothing is without poison, its only the dose and time of exposure that permits something not be poisonous.~~

Table 1. Effects of oral administration of phenol solution, aqueous and phenolic extract of avocado seed, on serum AST, ALT and ALP for 21 days.

	AST	ALT	ALP
GROUP I	9.5 ± 2.30	10.60±2.30	119.6 ± 31.87
GROUP II	22.25 ± 9.85*	36.25 ± 13.88**	270.48 ± 41.49**
GROUP III	31.25 ± 12.27**	45.75 ± 20.95**	291.88 ± 64.08**
GROUP IV	9.75 ± 2.98	12.0 ± 0.00	151.8 ± 52.85

Results are presented as mean ± standard deviation; * : significant, ** : highly significant. Different Superscript indicate significant difference at P < 0.05.

Liver section of control and treated rats were analyzed as shown in figure 1-4. It was carried out to ascertain the extent of hepatotoxic effect caused by phenol solution, aqueous and phenolic extracts of *Persea americana* seed. Figure1 shows the liver section of group I rats, which has normal liver cells architecture, where the central veins, portal tracts, hepatocytes and sinusoids appear normal. The lobular unit is also well identified. Liver section of Rats in group IV (Figure 4) shows no significant pathological changes when compared with the rats in group I. The liver section of Group II rats (Figure 2) show damage to the liver cells. There were extensive areas of patchy and confluent hepatocyte necrosis and lobular inflammation; sinusoidal spaces are flooded with inflammatory cell and red blood cells when compared with the liver architecture of the rats in group I. The photomicrography liver section of phenolic extracts treated rats in group III (Figure 3) shows severe degeneration of the hepatocyte and collapse of the normal liver architecture, when compared with the control liver section whose hepatocyte are arranged in cord, radiating from central vein. The photomicrography liver section of group III treated rats shows more severe hepatocytes degeneration when compared with group II, which indicate higher toxicity. The central veins in the hepatocytes of group III rats are embedded with fat which might be as a result of lipophilic characteristics of phenol which in turn increase its cellular uptake. The high serum level of marker enzymes as well as severity of liver damage observed in group III when compared to rats in group II might be as a result of variation in the solvent used for extraction. Since phenol is organic solvent it will extract more phytochemicals from the seed than water, moreover, phenol is acidic as such it can damage the hepatocytes which increase the release of enzymes AST, ALT and ALP.

UNDER PEER REVIEW

139 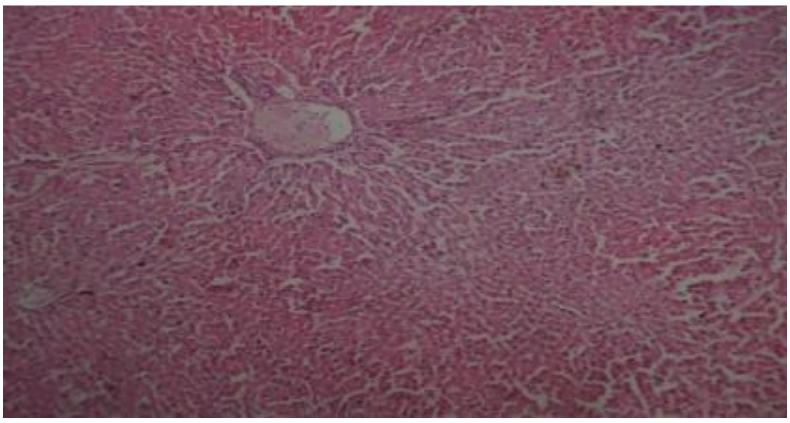

140 **Figure1: normal rat liver**

141 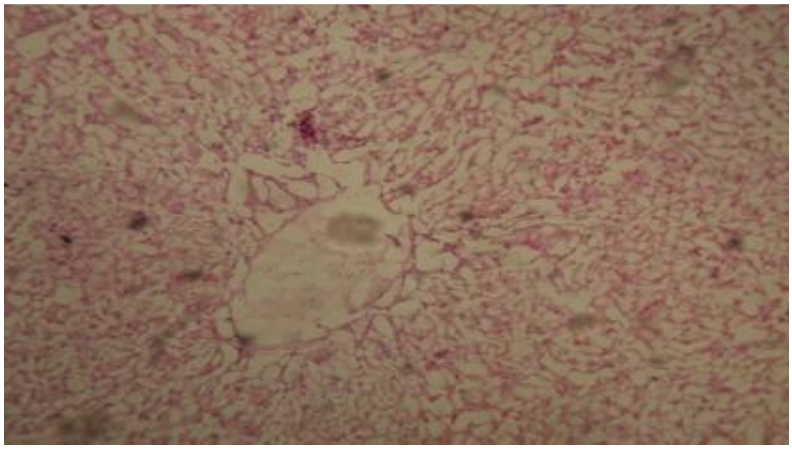

142 **Figure 2: aqueous extract treated rat liver**

143

144 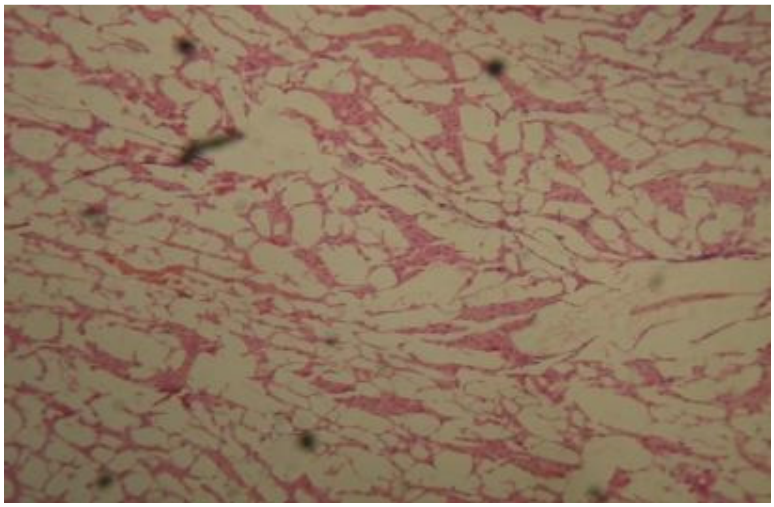

145 **Figure 3: Phenolic extract rat treated liver**

UNDER PEER REVIEW

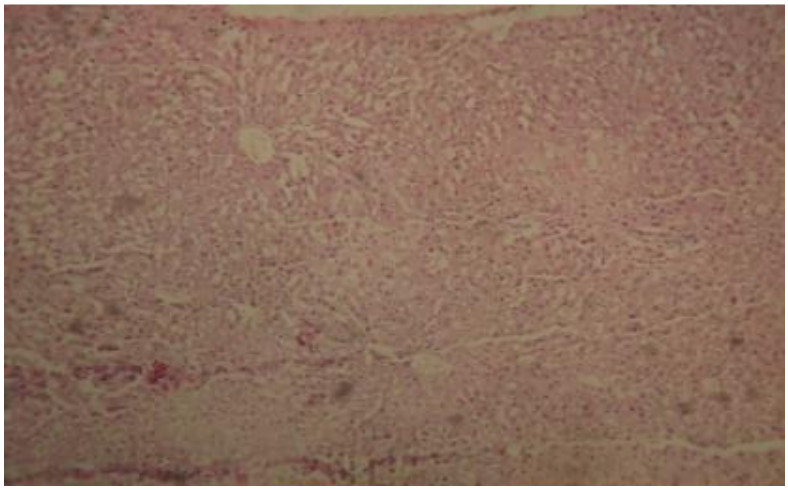

Figure 4: phenol solution treated rats liver section

4. CONCLUSION

The result of this study indicates that the daily oral administration of the aqueous and phenolic extract of *Persea americana* seed for a period of 3 weeks at a dose of 500mg/Kg has shown a Hepatotoxic effect. The histopathological analysis of the treated rat's liver shows degeneration of the hepatocyte and collapse of the liver architecture, thus, indicating liver damage. Further studies should be carried out by decreasing the dosage used in this study and also duration of the studies should be increased (chronic toxicity). Histopathological studies should also be carried out on other vital organs like kidney, brain etc. Isolation and characterization of the seed should be carried out, to identify the possible toxic component of the seed.

REFERENCES

1. Babandi, A., Ibrahim, A., Murtala, Y. And Yakasai, M.H. Comparative Assessment of Phytochemicals and Trace Elements Composition of Azadirachta indica and Calotopis procera Roots. *Biological and Environmental Sciences Journal for the Tropics.* (2012). 9(2): 123-126

2. Burkil, H.M. The Useful Plants of West Tropical Africa. 2nd ed. Royal Botanic Garden, Kew Richmonal United Kingdom (2008). P. 686.

3. Sofowora, A. Medicinal Plants and Traditional Medicine in Africa; Spectrum Books ltd, Ibadan (1993). Pp 220-224.

4. Atata, R.F., Sani, A.B. and Ajewali, S.M.. Effect of stan bark *enantia chloranta* on some clinical isolates *Biokemistri* (2003). **15**:84-92.

5. Olodumaye, P., Delmer, D.P. and Carlson, R.W. Identification of a novel interpenon saponin from *Pasium sativion* as a specific inhibitor of dignarmylate of Acetorbacter xylenum (1998). **39**:144-152.

6. Joao Jaime Giffoni Leite, Erica Helena Salles Brito, Rossana Aguiar Cordeiro, Raimunda Samia Nogueira Brilhante, Jose Julio Costa Sidrim, Luciana Medeiros Bertini, Selene Maia de Morais and Marcos Fabio Gadelha Rocha. Chemical Composition, Toxicity and Larvicidal

UNDER PEER REVIEW

and Antifungal activities of Pearsea americana (Avocado) seed Extracts (2009). 42(2): 110-113

7. Adeyemi, O.O., Okpo, S.O. and Ogunta, O.O. Analgesic and Anti inflammatory effect of the aqueous extract of leave of *Persea americana* mill (*Lauraceae*). *fitoterapia* (2002). 7**3**:375-380.

8. Maria Elena Pahua-Ramos, Alicia Ortiz-Moreno, German Chamarro-Cevallos, Maria Dolores Hernandez-Navarro, Leticia Garduno-Siciliano, Hugo Necoechea-Mondragon, Marcela Hernandez-Ortega. Hypolipedemic Effect of Avocado (Persea americana mill) seed in a Hyperchlostrolemic mouse model. Plant Foods Hum Nutr (2012). 67: 10-16

9. Boulton, A., Malik, R., Arezzoc, M. and Sosenko, J. Diabetic Somatic neurapathies *Diabetic Care* (2004). **27**:1458-1486.

10. Roger, C.R. The Nutritional Evidence of flavanoid: Some physiologic and metabolic considerations, *epedemia* (1988). **44**(9): 725-784.

11. Clipsham, R. Avocado toxicity http://kgkat.tripod.com/avocado.html (2007).

12. Anderson, J.E., Goestz C.M. and Mc Laughlin J.L. A Blind Comparison of Simple Bench-top Bioassay and Human Tumour cell Cytotoxicities as Antitumour Prescreens in Natural Product Chemistry. Editor Elesivier. Amsterdam, (1991).

13. Ruth Elenora Kristanty, Junie Suriawati, Joko Sulistiyo. Cytotoxic Activity of Avocado Seeds Extracts (Persea americana mill)On T47D cell Lines. International Research Journal of Pharmacy (2014). 5(7): 557-559

14. Reitman, S. and Frankel, S. A colorimetric method for the determination of serum glutamic oxaloacetate and glutamic pyruvic transaminase. *Am. J. chin. Pathol* (1957). **28**:56.

15. Rec, G.S. Colorimetric method for serum alkaline phosphatase determination. *J. Clin. Bioche* (1972). **10**(2):182.

16. Avwioro, O.G. Histochemistry and Tissue pathology: Principles and Technique 2nd edition. (2010). University Press, Delta State University, Abraka Nigeria.

17. ~~Mitchell, R., Kumar, V., Abbas, A. and Fausto, N. (Basic Pathology. Philadelphia: Saunders. 8th Edition 2011). Pp. 340-352~~

18. Khan, I.A., Reddy, B.V., Mahboob, M., Rahman, M.T and Jamil, K. Effect of Phosphorothionate on productive system of male rats. *J. Eviron. Sci. Health* (2011). **36**:445:456.

19. Mitra, S.K., Venkataranganna, M.V. and Sundaran, R. Protective Effect of HD-03, a herbal formulation against hepatotoxic agent in rat. *J. Ethanopharmacol* (1998). **63**:18-16.

20. WitteKind, C. Prognostic Factors in liver tumour; *verh. Dtsch Gs. Pathol* (1995). **79**:109-115.

21. Karthikeyan, S., Gobianand, K., Mohan, C.U. and Balasubramanian, M.P. (2006). Biochemical Changes in Serum, Lung, Heart and Spleen Tissue of Mice Exposed to Sub-acute Toxic Inhalation of Mosquito Repellent Mat Vapour. *J. Environ. Biol* (2007). 27: 355-358

22. William, F., Balistreri, M.D. and Robert, R. Liver Function In: Burtis, USA C.A and Ashwood, E.R. eds. Tietz Fundamentals of Clinical Chemistry, W.B. Saunders Company (1997). Pp. 539-549.

23. Adel- monein, A., El-Feki, M. and Salah, E.. Effect of *Nigella Sativa,* fish oil and glicalzde on alloxan diabetic rats, Biochemical and Histopathological Studies *J. Egy. Ger. Soci. Zool* (2011) 2**3**:237-265.

UNDER PEER REVIEW

24. Ohr, D., Coffer, D. and Mc Millan, T. Common Name of Plant Diseases *American Phytopat.* (2003). **25**:345-410.

25. ~~Paracelsus, M.. "Dose response handbook of pesticide toxicity" William C. Krieger, Academic Press (2008). Pp. 12-14~~