UNDER PEER REVIEW

Original Research Article

LIGHT and FGF-BP are Upregulated in Chronic Liver Injury

ABSTRACT

Aims: The aim of this study is to explore the expression pattern of LIGHT and FGF-BP at the different stages of liver injury including acute injury, fibrosis and cirrhosis

Study design: Controlled experiment

Place and Duration of Study: Department of Biochemistry and Department of Pharmacology and Toxicology, Faculty of pharmacy (boys) Al-Azhar University, between February 2015 and June 2015.

Methodology: four Sprague-Dawley rat groups were used for the experiment. Control group:9 rats received corn oil; acute toxicity group: 10 rats were injected 50 % CCL_4 in corn oil (4 ml/kg/IP/single dose); 6weeks group:12rats were injected with 50% CCL_4 in corn oil (4 ml/kg/IP/twice weekly/6weeks); 11weeks group: 10 rats were injected with 50 % CCL_4 in corn oil (4 ml/kg/IP/twice weekly/6 weeks) followed by 5 weeks of CCL_4 treatment with the half previous dose

On the day after the last dose, rats were anesthetized with diethyl ether and blood samples were collected for measurement of blood chemistry. The animals then were euthanized, and tissue samples from the livers were harvested and divided into 2 parts; one part was processed for standard histology and immunofluorescence techniques and the other was homogenized for oxidative status assessment.

Results: LIGHT and FGF-BP were shown to be upregulated in chronic liver injury; while LIGHT was shown to be upregulated in cirrhosis stage only, FGF-BP was shown to be upregulated at fibrosis and cirrhosis stages. LIGHT was shown to be expressed at the cytoplasm of the cells at cirrhotic nodule border. FGF-BP localization was shown to occur mainly at the extracellular matrix.

Conclusion: LIGHT and FGF-BP was suggested to be of critical importance in pathogenesis of chronic liver injury so they may be used as a target for chronic liver injury therapy and/or candidate marker for diagnosis and/or prognosis of chronic liver injury.

Keywords: LIGHT, FGF-BP, fibrosis, cirrhosis

UNDER PEER REVIEW

1. INTRODUCTION

The liver plays an unlimited role in the preservation and body homeostasis regulation. It is included in most biochemical pathways to growth, protection against disease, nutrient fund, energy facility and reproduction (1).Hepatotoxicity can be generated by certain common causes including therapeutic agents, natural chemicals, laboratory and manufacturing agents and herbal therapies (2).

Carbon tetra chloride (CCL_4) is one of the most communal models for inducing hepatotoxicity. It is transformed into a toxic CCL_3^- radical by hepatic cytochrome P4502E1 (CYP2E1).Thus; it brings an acute Centro-lobular necrosis which starts a wound healing response (fibrosis) (3). However, Contact to these chemicals in humans is rare and generally occurs in the manufacturing during fabrication and in places where these chemicals is usually used (4).

LIGHT (lymphotoxin-like, exhibits inducible expression, and competes with HSV glycoprotein D (gD) for HVEM, a receptor expressed by T lymphocytes) It is a cytokine in the TNF superfamily that is involved in innate and adaptive immune responses as well as in regulation of cell survival and proliferation(5). LIGHT was demonstrated to have a crucial role in fibrous tissue precipitation and fibrosis cascades in different tissues (5-8).

Fibroblast growth factor binding proteins (FGF-BPs) compromise a family of three secreted proteins that are of vital importance for fibroblast growth factors (FGFs) action. (9). They are reported to be upregulated in tissue healing and repair specifically that includes some sorts of fibrosis cascades (10) (11)

.The aim of this study was to explore the expression pattern of LIGHT and FGF-BP at different stages of liver injury. This aspect of study was verified by investigation of the localization of these proteins in different liver injury stages.

2. METHODOLOGY

2.1. Animal model.

Adult male Sprague-Dawley rats weighing 250–300 g were used in the current study. The animals were obtained from the breeding colony maintained at the animal house of the Nile Company for pharmaceuticals, Cairo, Egypt. They were housed in the animal facility of Faculty of Pharmacy, Al-Azhar University in 20 X 18 X 25 cm plastic cages with stainless steel wire lids and mesh floor with 5 animals per cage. They were kept at 23±1 ℃, at 55 % relative humidity, with 12:12-h light: dark cycle, and maintained on a standard rodent chow (El-Nasr Company, Abou-Zaabal, Cairo, Egypt), diets and water ad libitum. Animals were randomly divided into four groups: control group: 9 rats: receiving corn oil (2ml/kg/twice weekly/IP) ; acute toxicity group: 10 rats were injected 50 % CCL_4 in corn oil (4 ml/kg/IP/single dose)(12) ; 6weeks group:12rats were injected with 50% CCL_4 in corn oil (4 ml/kg/IP/twice weekly/6weeks) and finally 11weeks group: 10 rats were injected with 50 % CCL_4 in corn oil (4 ml/kg/IP/twice weekly/6 weeks) followed by 5 weeks of CCL_4 treatment with the half previous dose. On the day after the last dose, rats were anesthetized with diethyl ether and blood samples were collected for measurement of blood chemistry. The animals then were euthanized, and tissue samples from the livers were harvested and divided into 2 parts; one part was processed by standard histology and immunofluorescence techniques and the other was homogenized in 0.15 M KCl for MDA and SOD assay. All animal procedures were performed in accordance with the international guide for the care and use of laboratory animals (13)

2.2. Antibodies and chemicals.

Rabbit polyclonal LIGHT and FGF-BP antibodies were purchased from Santa Cruz Biotechnology (CA, USA). Cy3-conjugated goat anti-rabbit antibody was purchased from Jackson Immunoresearch (PA, USA). 4, 6- Diamidino-2- phenyl indole (DAPI). CCL_4 was purchased from Sigma-Aldrich (MO, USA).

2.3. Biochemical analysis.

Serum enzymatic activities of transaminases (ALT and AST) were estimated by kinetic method according to the method of international federation of clinical chemistry (IFCC) (14;15). Alkaline phosphatase (ALP) activity was assay according to the method of IFCC(16-18) and serum albumin concentration according to the method described by Gendler (19). The liver homogenate was used for the determination of the oxidative stress parameters. The level of thiobarbituric acid-reactive substances (measured as malondialdehyde (MDA) was determined as described by Mihara and Uchiyama (20). The activity of SOD was determined using the method described by Marklund (21).

UNDER PEER REVIEW

2.4. Immunofluorescence analysis.

Slides containing liver tissues sections were handled according to method described by Abdel-Bakky and his associates (22). The primary LIGHT and FGF-BP antibodies were diluted in blocking solution in the suitable dilution (1:400) and left overnight in 4 ℃. Secondary antibody (cyanine red conjugated) diluted in the blocking solution was incubated for 30 min and the nuclei were counterstained using DAPI. Finally, all slides were mounted with the fluoromount solution, covered by covering slips, and allowed to stand for detection by immunofluorescence microscope (Leica DM 5500B).

2.5. Statistical analysis.

Data were presented as the mean ±SE. Statistical analysis was performed using one-way analysis of variance (ANOVA) followed by Tukey-Kramer as a post hoc test, according to the number of groups. The 0.05 level of probability was used as the criterion of significance using GraphPad Prism software version 5 (GraphPad Software Inc, CA, USA).

3. RESULTS

3.1. LIVER FUNCTIONS AND OXIDATIVE STATUS ASSESSMENT.

To assess liver functions; we have performed liver function tests including serum transaminases, ALP, and albumin. The oxidative status of liver tissues was determined through MDA and SOD assay as indicated in **CCL4 treated** groups showed significant decrease in SOD activities.

Table 1.

As indicated in **CCL4 treated** groups showed significant decrease in SOD activities.

Table 1; Serum ALT and AST activity of control group rats were 46.6±2.85 and 54.1±2.65 respectively. Administration of I.P. CCL_4 significantly elevated serum transaminases activities whatever the duration of administration.

As shown in **CCL4 treated** groups showed significant decrease in SOD activities.

Table 1; ALP activity of control group rats was 312±21.9 (IU/L). It showed significant elevation only in chronic administration of CCL_4 with minimal change in single dose CCL_4 treatment.

Serum albumin of control group was 3.81±0.08 g/dl. The significant decrease observed only with 11 weeks CCL_4 treatment as shown in **Table 1**

As shown in **CCL4 treated** groups showed significant decrease in SOD activities.

Table 1; the tissue MDA content of control group was 4.73±0.318 nmol/g tissue. This content was significantly increased on CCL_4 treated groups whatever the duration of administration.

CCL4 treated groups showed significant decrease in SOD activities.

Table 1 shows the M ± SEM for SOD of studied groups. The control group showed tissue SOD activity of 526±25.2 U/mg tissue. CCL_4 treated groups showed significant decrease in SOD activities.

Table 1: Liver functions and oxidative status assessment tests.

	ALT(IU/L)	*AST(IU/L)*	*ALP(IU/L)*	*Albumin(g/dl)*	*MDA(nmol/g tissue)*	*SOD(U/mg tissue)*
Control	46.6±2.85	54.1±2.65	312±21.9	3.81±0.08	4.73±0.318	526±25.2
CCL_4 single	294±11.9[(a)(b)]	419±11.0[(a)]	395±11.1 [(b)]	3.8±0.06[(b)]	23.7±2.35[(a)(b)]	308±8.05[(a)(b)]

UNDER PEER REVIEW

I.P. dose							
CCL_4	**6**	349±13.4[(a)]	436±15.4[(a)]	570±24.5[(a)]	3.39±0.13	31.9±1.44[(a)]	223±14[(a)]
weeks I.P.							
CCL_4	**11**	298±8.48[(a)]	368±13.4[(a)(b)]	790±24.9[(a)(b)]	2.69±0.07[(a)]	38.1±1.74[(a)]	171±6.57[(a)]
weeks I.P.							

Data are expressed as mean ± SEM
(a) Significantly different from control group
(b) Significantly different from 6 weeks CCL_4 group using one-way ANOVA followed by Tukey-Kramer test for multiple comparison test at $P \leq 0.05$

3.2. EXPRESSION AND LOCALIZATION OF LIGHT.

Figure 1 shows that LIGHT protein showed well defined expression only liver tissue that showed well defined cirrhosis; while there no any definite protein expression in normal liver tissues, acute toxicity model and chronic models that didn't show cirrhosis. It was also noted that the expression was located mainly in the cirrhotic nodule borders; area that showed high density of fibroblasts while areas that showed parenchymal cells as interior of the cirrhotic nodule didn't show any expression. It was noted that the expression increased by about 38% 11weeks CCL_4 treated group compared to control group while there weren't significant expression change in other groups as indicated in **Graph** 1.

UNDER PEER REVIEW

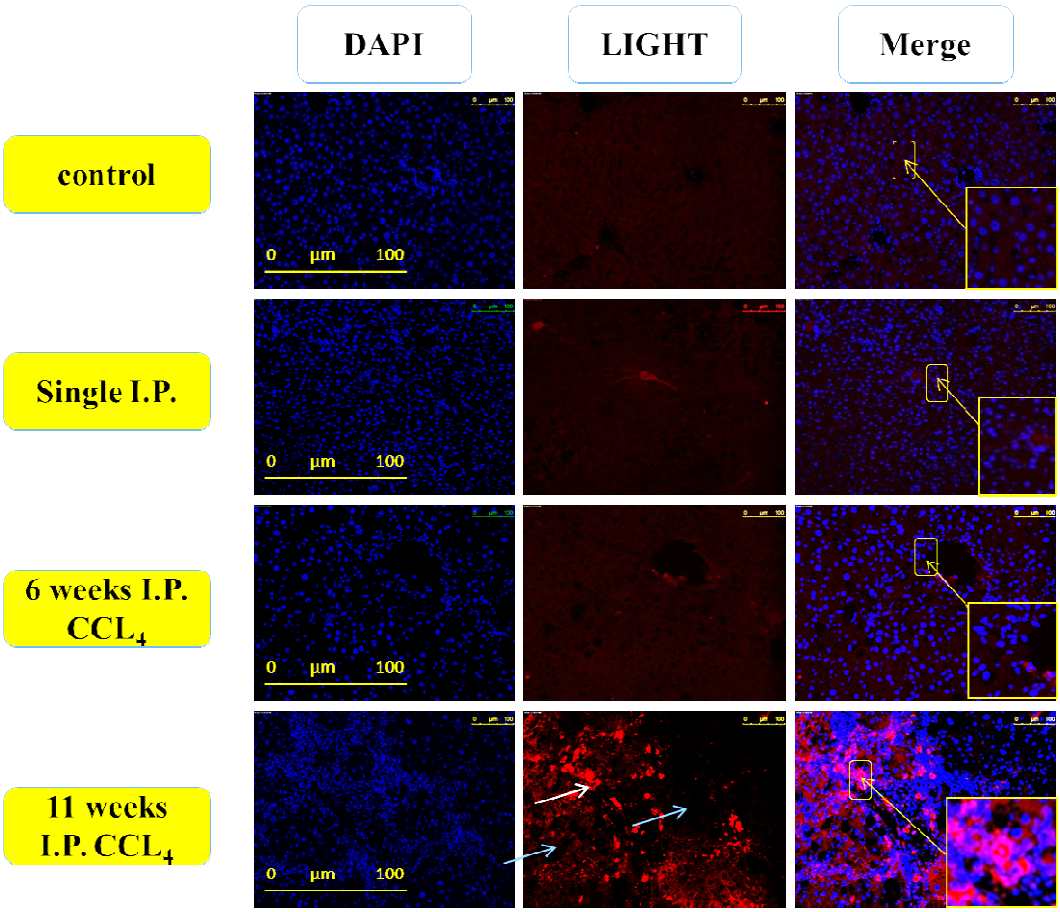

Figure 1: Effect of CCL4 administration on hepatic expression of LIGHT protein

Immunofluorescence staining of liver sections of CCL_4 treated rats showing minimal LIGHT expression in control group, single I.P. treated group and six weeks CCL_4 treated group. The expression was increased significantly in 11 weeks group.it was noted that the expression located mainly in the cytoplasm of cells located in fibrous septa (white arrow) with minimal expression in the interior of cirrhotic nodule (blue arrows).

UNDER PEER REVIEW

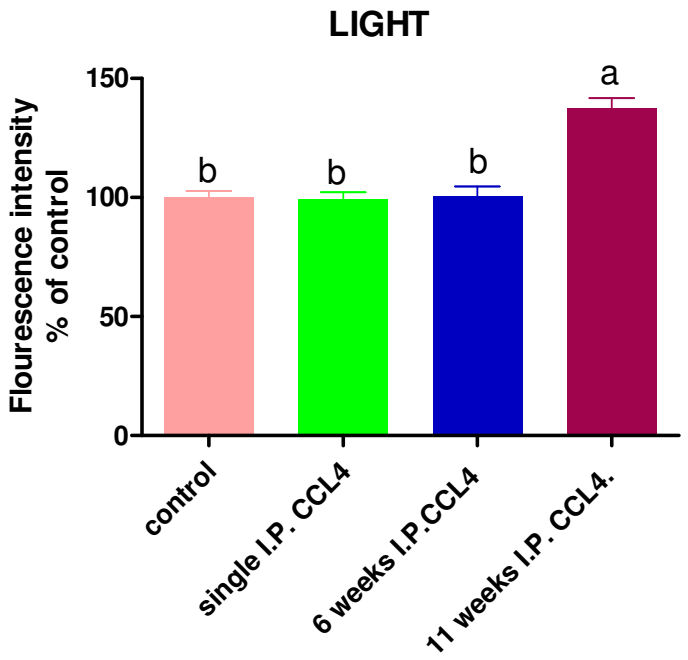

Graph 1: Effect of CCL_4 administration on hepatic expression of LIGHT protein
Fluorescence intensity was obtained from 5 fields of each section (minimally 2 rats of each group) using ImageJ software.
Data are expressed as mean ± SEM
(a) Significantly different from control group
(b) Significantly different from 6 weeks CCL_4 group one-way ANOVA followed by Tukey-Kramer test for multiple comparison test at P≤0.05

3.3. EXPRESSION AND LOCALIZATION OF FGF-BP.

Figure 2Error! Reference source not found. shows that FGF-BP showed minimal expression in normal liver tissues and also in acute toxicity model. The expression was increased on conversion of toxicity from acute to chronic with maximal expression in 6 and 11 weeks groups. It also can be noted that FGFBP was located mainly in the extracellular matrix of necrotic area in injured tissue.

As indicated in **Graph 2**; quantitative analysis of immunofluorescence staining expressed as fluorescence intensity revealed that there no significant change in the expression between control and singly treated group. On the other hand; the expression increased by about 58% and 32% in 6 and 11weeks CCL4 treated groups respectively compared to control group

UNDER PEER REVIEW

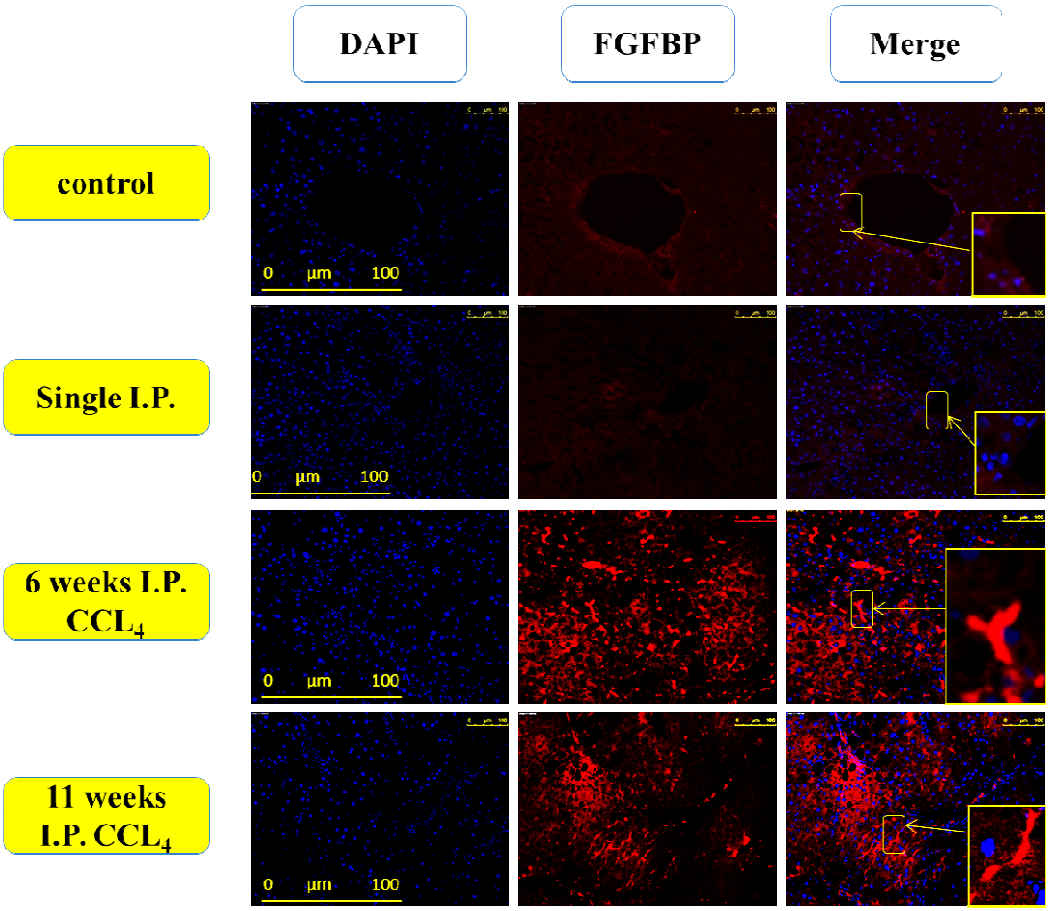

Figure 2: Effect of CCL4 administration on hepatic expression and localizaion of FGF-BP

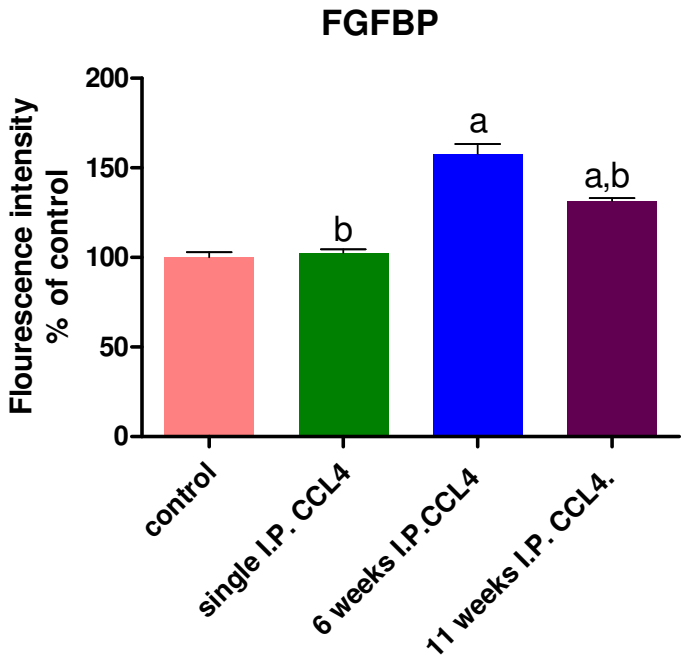

Graph 2: Effect of CCL_4 administration on FGF-BP

UNDER PEER REVIEW

Fluorescence intensity was obtained from 5 fields of each section (minimally 2 rats of each group) using ImageJ software.
Data are expressed as mean ± SEM
(a) Significantly different from control group
(b) Significantly different from 6 weeks CCL_4 group one-way ANOVA followed by Tukey-Kramer test for multiple comparison test at $P \leq 0.05$

3.4. HISTOPATHOLOGICAL FINDINGS

Effects of CCL4 treatment on histopathological findings of liver tissue are represented in **Table 2** and **Figure 3**. The control group showed normal hepatic architecture. On contrast, CCL_4 treated groups showed pathological findings changes according to the duration of treatment.

Single I.P. dose treated group showed average portal tract (PT) (yellow arrow) without interface activity or underlying fibrosis. On the other hand; it showed spotty necrosis (black arrow), and mild micro-vesicular steatosis and dilated central vein. Six weeks treatment caused expanded PT with fibrous septa extending from PT to PT (yellow arrows), marked micro- and macro-vesicular steatosis. The hepatocytes exhibited some aspects of single cell necrosis with dilated central veins and mild interface activity.

Eleven weeks treatment showed markedly expanded PT (yellow arrows) with definite inflammatory infiltrate, complete nodular formation (definite cirrhosis) and marked micro- and macro-vesicular steatosis. The hepatocytes exhibited single cell necrosis with mild spotty necrosis. Finally; the central veins were markedly dilated with marked interface activity.

Table 2: Histopathological findings of the studied groups

	control	Single I.P. CCL_4	CCL4 6 weeks	CCL4 11 weeks
CV	0	+	+	++
Steatosis	0	+	+++	+++
Hepatocyte	0	++	+	+
Spotty necrosis	0	++	0	+
Interface activity	0	0	+	++
PT	0	0	+	++
Fibrosis	0	0	++	++++

Central vein (CV):
0: within normal +: dilated ++: markedly dilated
Steatosis, Spotty necrosis, Interface activity:
0: no +: mild ++: moderate to marked
Hepatocytes:
0: within normal +: single cell necrosis ++: confluent or diffuse necrosis
Portal tract (PT):
0: within normal +: expanded ++: expanded with inflammatory infiltrate
Fibrosis:
0: no fibrosis
+: fibrosis confined to enlarged portal zones

UNDER PEER REVIEW

++: fibrosis of peri-portal or portal-portal septa with intact architecture
+++: architectural distortion (septal or bridging fibrosis) without obvious cirrhosis
++++: probable or definite cirrhosis

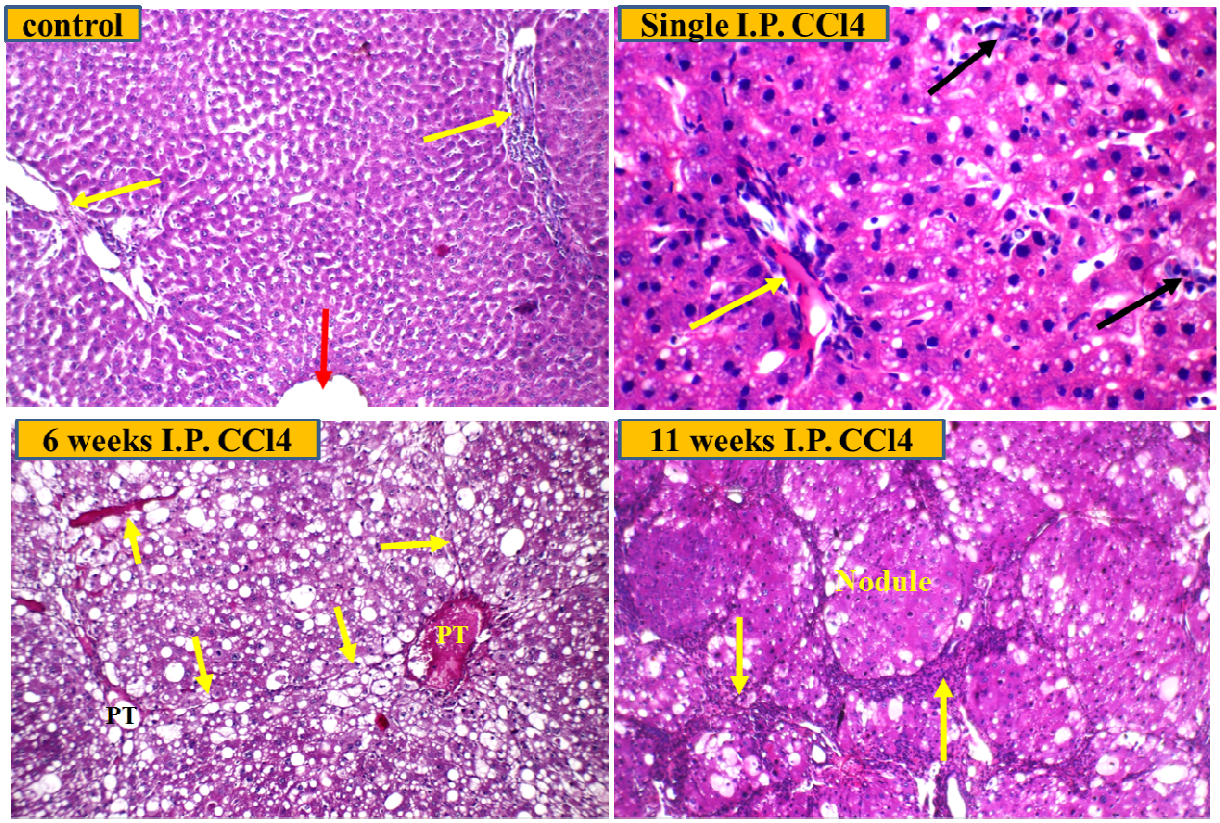

Figure 3: Histopathological micrograph of liver samples of CCL_4 treated groups ×235 using H and E stain. **Control**: liver tissue showing average PT (yellow arrows), average central vein (red arrow), and average hepatocytes arranged in cords. **Single I.P. CCL_4 dose**: liver tissue showing average PT (yellow arrow), spotty necrosis (black arrow), and mild micro-vesicular steatosis.**6 weeks I.P. CCL_4**: liver tissue showing expanded PT with underlying fibrosis and fibrous septa extending from PT to PT (yellow arrows), marked micro- and macro-vesicular steatosis.**11 weeks I.P. CCL_4**: liver tissue showing markedly expanded PT (yellow arrows), complete nodular formation, marked micro- and macro-vesicular steatosis.

4. DISCUSSION

Administration of CCL_4 either a single I.P. dose or chronic I.P. doses for 6 or 11 weeks significantly elevated serum transaminases enzymes activities suggesting hepatocellular damage. These results agreed with previous reports that CCL_4 significantly increases serum transaminases (23-25). This CCL_4 induced hepatic damage was reported to be due to oxidative stress (26;27).

ALP activity after single I.P. CCL4 treatment shows non-significant increase from control group suggesting minimal biliary injury detected upon that model. This result opposes what was reported by Kālu's team(24). This difference might be due difference in animal strain or route of administration that has not been mentioned. On the other hand; ALP elevation in chronic models including 6 weeks, 11 weeks groups showed significant increase compared to control which is less than 3 times as control; a result that might suggest hepatotoxicity and mild biliary toxicity. This matches with that previously reported by Posen and Doherty(28).Concomitant CCL_4 for 11 weeks has showed significant elevation in ALP activity compared to 6 weeks CCL_4 treatment suggesting that chronic hepatocellular intoxication might lead to biliary injury.

Serum albumin concentration showed only significant decrease from control at 11 weeks CCL_4 treatment, a group that showed cirrhotic nodule formation. This result agreed with previous reports that indicated the decrease in serum albumin concentration upon decreased liver functioning tissue mass(29).

UNDER PEER REVIEW

Meanwhile; it was clarified that free radicals production and oxidative stress are main players in liver injury especially CCL_4 induced liver injury (26;27). In our study; administration of CCL_4 significantly elevated tissue content of MDA and reduced serum SOD activity. These results agreed with the previous reports that demonstrated the great role of oxidative stress in CCL_4 induced liver injury (30-32).

Supporting the measured biochemical data:Our findings demonstrated that single I.P. dose of CCL_4 resulted in marked spotty necrosis and confluent hepatocytes necrosis. On the other hand prolonged administration of CCL_4 to 6 weeks produced fibrosis of peri-portal or portal-portal septa with intact architecture while prolonged CCL_4 to 11 weeks produced definite cirrhosis with clear cirrhotic nodule. This is similar to what has been reported that histopathological changes occur according to CCL_4 administration period. A single dose of CCL_4 leads to centrizonal necrosis and steatosis (33), while continued administration leads to hepatic fibrosis, cirrhosis, and HCC (34)

Concerning inflammatory cytokines; it was shown that LIGHT protein expression showed significant upregulation in 11 weeks group only. This might suggest that LIGHT was greatly involved in critical cellular processes that control cirrhosis progression. This was quite similar to previous reports that have indicated the importance of LIGHT in fibrous tissue precipitation and fibrosis cascades in different tissues(5-8;35) and might be an attractive marker and a target for fibrosis therapies relevant to humans(36).

Concerning FGF-BP; our results demonstrated that FGF-BP is upregulated significantly in chronic liver injury groups compared to control group; groups with fibrosis and cirrhosis pattern that have been shown to involve cellular processes of classic wound healing and repair of other tissues(37). These finding agreed with what has been reported that FGF-BP is of critical importance in tissues that involve some sorts of tissue healing or repair (10;11).

5. CONCLUSION

In conclusion, our findings indicate, for the first time, that LIGHT and FGF-BP are upregulated in chronic not acute liver injury specifically in stages of fibroblast activity. LIGHT is upregulated only in cirrhosis stages while stages before didn't. FGF-BP is upregulated in chronic liver injury stages involving fibrosis and cirrhosis. This may be a guide for usage of LIGHT and/or FGF-BP as a candidate marker for diagnosis and/or prognosis of chronic liver diseases and their usage as a target for drug therapy in treatment of liver diseases

UNDER PEER REVIEW

6. References

REFERENCE LIST

(1) SHARMA A, CHAKRABORTI KK, HANDA SS. ANTIHEPATOTOXIC ACTIVITY OF SOME INDIAN HERBAL FORMULATIONS AS COMPARED TO SILYMARIN. FITOTERAPIA 1991;62:229-35.

(2) OSTAPOWICZ G, FONTANA RJ, SCHIODT FV, LARSON A, DAVERN TJ, HAN SH, ET AL. RESULTS OF A PROSPECTIVE STUDY OF ACUTE LIVER FAILURE AT 17 TERTIARY CARE CENTERS IN THE UNITED STATES. ANN INTERN MED 2002 DEC 17;137(12):947-54.

(3) DOMENICALI M, CARACENI P, GIANNONE F, BALDASSARRE M, LUCCHETTI G, QUARTA C, ET AL. A NOVEL MODEL OF CCL4-INDUCED CIRRHOSIS WITH ASCITES IN THE MOUSE. J HEPATOL 2009 DEC;51(6):991-9.

(4) MORMONE E, GEORGE J, NIETO N. MOLECULAR PATHOGENESIS OF HEPATIC FIBROSIS AND CURRENT THERAPEUTIC APPROACHES. CHEM BIOL INTERACT 2011 SEP 30;193(3):225-31.

(5) GRANGER SW, RICKERT S. LIGHT-HVEM SIGNALING AND THE REGULATION OF T CELL-MEDIATED IMMUNITY. CYTOKINE GROWTH FACTOR REV 2003 JUN;14(3-4):289-96.

(6) DOHERTY TA, SOROOSH P, KHORRAM N, FUKUYAMA S, ROSENTHAL P, CHO JY, ET AL. THE TUMOR NECROSIS FACTOR FAMILY MEMBER LIGHT IS A TARGET FOR ASTHMATIC AIRWAY REMODELING. NATURE MEDICINE 2011;17(5):596-603.

(7) YAMAMOTO T. THE BLEOMYCIN-INDUCED SCLERODERMA MODEL: WHAT HAVE WE LEARNED FOR SCLERODERMA PATHOGENESIS? ARCH DERMATOL RES 2006 FEB;297(8):333-44.

(8) HERRO R, ANTUNES RS, AGUILERA AR, TAMADA K, CROFT M. THE TUMOR NECROSIS FACTOR SUPERFAMILY MOLECULE LIGHT PROMOTES KERATINOCYTE ACTIVITY AND SKIN FIBROSIS. J INVEST DERMATOL 2015 AUG;135(8):2109-18.

(9) ABUHARBEID S, CZUBAYKO F, AIGNER A. THE FIBROBLAST GROWTH FACTOR-BINDING PROTEIN FGF-BP. INT J BIOCHEM CELL BIOL 2006;38(9):1463-8.

(10) LIU XH, AIGNER A, WELLSTEIN A, RAY PE. UP-REGULATION OF A FIBROBLAST GROWTH FACTOR BINDING PROTEIN IN CHILDREN WITH RENAL DISEASES. KIDNEY INT 2001 MAY;59(5):1717-28.

(11) KURTZ A, AIGNER A, CABAL-MANZANO RH, BUTLER RE, HOOD DR, SESSIONS RB, ET AL. DIFFERENTIAL REGULATION OF A FIBROBLAST GROWTH FACTOR-BINDING PROTEIN DURING SKIN CARCINOGENESIS AND WOUND HEALING. NEOPLASIA 2004 SEP;6(5):595-602.

UNDER PEER REVIEW

(12) FLEURENTIN J, HOEFLER C, LEXA A, MORTIER F, PELT JM. HEPATOPROTECTIVE PROPERTIES OF CREPIS RUEPPELLII AND ANISOTES TRISULCUS: TWO TRADITIONAL MEDICINAL PLANTS OF YEMEN. J ETHNOPHARMACOL 1986 APR;16(1):105-11.

(13) INSTITUTE OF LABORATORY ANIMAL RESOURCES (US), USE OF LABORATORY ANIMALS, NATIONAL INSTITUTES OF HEALTH (US). GUIDE FOR THE CARE AND USE OF LABORATORY ANIMALS. NATIONAL ACADEMIES; 1985.

(14) BERGMEYER HU, HORDER M, REJ R. INTERNATIONAL FEDERATION OF CLINICAL CHEMISTRY (IFCC) SCIENTIFIC COMMITTEE, ANALYTICAL SECTION: APPROVED RECOMMENDATION (1985) ON IFCC METHODS FOR THE MEASUREMENT OF CATALYTIC CONCENTRATION OF ENZYMES. PART 2. IFCC METHOD FOR ASPARTATE AMINOTRANSFERASE (L-ASPARTATE: 2-OXOGLUTARATE AMINOTRANSFERASE, EC 2.6.1.1). J CLIN CHEM CLIN BIOCHEM 1986 JUL;24(7):497-510.

(15) BERGMEYER HU, HORDER M, REJ R. INTERNATIONAL FEDERATION OF CLINICAL CHEMISTRY (IFCC) SCIENTIFIC COMMITTEE, ANALYTICAL SECTION: APPROVED RECOMMENDATION (1985) ON IFCC METHODS FOR THE MEASUREMENT OF CATALYTIC CONCENTRATION OF ENZYMES. PART 3. IFCC METHOD FOR ALANINE AMINOTRANSFERASE (L-ALANINE: 2-OXOGLUTARATE AMINOTRANSFERASE, EC 2.6.1.2). J CLIN CHEM CLIN BIOCHEM 1986 JUL;24(7):481-95.

(16) TIETZ NW, RINKER AD, SHAW LM. INTERNATIONAL FEDERATION OF CLINICAL CHEMISTRY. IFCC METHODS FOR THE MEASUREMENT OF CATALYTIC CONCENTRATION OF ENZYMES. PART 5. IFCC METHOD FOR ALKALINE PHOSPHATASE (ORTHOPHOSPHORIC-MONOESTER PHOSPHOHYDROLASE, ALKALINE OPTIMUM, EC 3.1.3.1). IFCC DOCUMENT STAGE 2, DRAFT 1, 1983-03 WITH A VIEW TO AN IFCC RECOMMENDATION. CLIN CHIM ACTA 1983 DEC 30;135(3):339F-67F.

(17) TIETZ NW, RINKER AD, SHAW LM. IFCC METHODS FOR THE MEASUREMENT OF CATALYTIC CONCENTRATION OF ENZYMES PART 5. IFCC METHOD FOR ALKALINE PHOSPHATASE (ORTHOPHOSPHORIC-MONOESTER PHOSPHOHYDROLASE, ALKALINE OPTIMUM, EC 3.1.3.1). J CLIN CHEM CLIN BIOCHEM 1983 NOV;21(11):731-48.

(18) TIETZ NW, BURTIS CA, DUNCAN P, ERVIN K, PETITCLERC CJ, RINKER AD, ET AL. A REFERENCE METHOD FOR MEASUREMENT OF ALKALINE PHOSPHATASE ACTIVITY IN HUMAN SERUM. CLIN CHEM 1983 MAY;29(5):751-61.

(19) GENDLER S. URIC ACID. KAPLAN A ET AL. CLIN CHEM THE CV MOSBY CO ST LOUIS TORONTO PRINCETON 1984;1268-73.

(20) MIHARA M, UCHIYAMA M. DETERMINATION OF MALONALDEHYDE PRECURSOR IN TISSUES BY THIOBARBITURIC ACID TEST. ANAL BIOCHEM 1978 MAY;86(1):271-8.

(21) MARKLUND SL. SUPEROXIDE DISMUTASE ISOENZYMES IN TISSUES AND PLASMA FROM NEW ZEALAND BLACK MICE, NUDE MICE AND NORMAL BALB/C MICE. MUTAT RES 1985 JAN;148(1-2):129-34.

UNDER PEER REVIEW

(22) ABDEL-BAKKY MS, HAMMAD MA, WALKER LA, ASHFAQ MK. TISSUE FACTOR DEPENDENT LIVER INJURY CAUSES RELEASE OF RETINOID RECEPTORS (RXR-ALPHA AND RAR-ALPHA) AS LIPID DROPLETS. BIOCHEM BIOPHYS RES COMMUN 2011 JUN 24;410(1):146-51.

(23) AHSAN R, ISLAM KM, MUSADDIK A, HAQUE E. HEPATOPROTECTIVE ACTIVITY OF METHANOL EXTRACT OF SOME MEDICINAL PLANTS AGAINST CARBON TETRACHLORIDE INDUCED HEPATOTOXICITY IN ALBINO RATS. GLOBAL J PHARMACOL 2009;3(3):116-22.

(24) KALU FN, OGUGUA VN, UJOWUNDU CO, NWAOGUIKPE RN. AQUEOUS EXTRACT OF COMBRETUM DOLICHOPENTALUM LEAF-A POTENT INHIBITOR OF CARBON TETRACHLORIDE INDUCED HEPATOTOXICITY IN RATS. JOURNAL OF APPLIED PHARMACEUTICAL SCIENCE 2011;1(10):114.

(25) DALTON SR, LEE SM, KING RN, NANJI AA, KHARBANDA KK, CASEY CA, ET AL. CARBON TETRACHLORIDE-INDUCED LIVER DAMAGE IN ASIALOGLYCOPROTEIN RECEPTOR-DEFICIENT MICE. BIOCHEMICAL PHARMACOLOGY 2009;77(7):1283-90.

(26) MANIBUSAN MK, ODIN M, EASTMOND DA. POSTULATED CARBON TETRACHLORIDE MODE OF ACTION: A REVIEW. J ENVIRON SCI HEALTH C ENVIRON CARCINOG ECOTOXICOL REV 2007 JUL;25(3):185-209.

(27) WEBER LW, BOLL M, STAMPFL A. HEPATOTOXICITY AND MECHANISM OF ACTION OF HALOALKANES: CARBON TETRACHLORIDE AS A TOXICOLOGICAL MODEL. CRIT REV TOXICOL 2003;33(2):105-36.

(28) POSEN S, DOHERTY E. THE MEASUREMENT OF SERUM ALKALINE PHOSPHATASE IN CLINICAL MEDICINE. ADV CLIN CHEM 1981;22:163-245.

(29) GIANNINI EG, TESTA R, SAVARINO V. LIVER ENZYME ALTERATION: A GUIDE FOR CLINICIANS. CANADIAN MEDICAL ASSOCIATION JOURNAL 2005;172(3):367-79.

(30) KALU FN, OGUGUA VN, UJOWUNDU CO, NWAOGUIKPE RN. AQUEOUS EXTRACT OF COMBRETUM DOLICHOPENTALUM LEAF-A POTENT INHIBITOR OF CARBON TETRACHLORIDE INDUCED HEPATOTOXICITY IN RATS. 2011.

(31) DALTON SR, LEE SM, KING RN, NANJI AA, KHARBANDA KK, CASEY CA, ET AL. CARBON TETRACHLORIDE-INDUCED LIVER DAMAGE IN ASIALOGLYCOPROTEIN RECEPTOR-DEFICIENT MICE. BIOCHEM PHARMACOL 2009 APR 1;77(7):1283-90.

(32) NOORI S, REHMAN N, QURESHI M, MAHBOOB T. REDUCTION OF CARBON TETRACHLORIDE-INDUCED RAT LIVER INJURY BY COFFEE AND GREEN TEA. PAKISTAN JOURNAL OF NUTRITION 2009;8(4):452-8.

(33) PIERCE RA, GLAUG MR, GRECO RS, MACKENZIE JW, BOYD CD, DEAK SB. INCREASED PROCOLLAGEN MRNA LEVELS IN CARBON TETRACHLORIDE-INDUCED LIVER FIBROSIS IN RATS. J BIOL CHEM 1987 FEB 5;262(4):1652-8.

(34) TAMAYO RP. IS CIRRHOSIS OF THE LIVER EXPERIMENTALLY PRODUCED BY CC14 AN ADEQUATE MODEL OF HUMAN CIRRHOSIS? HEPATOLOGY 1983;3(1):112-20.

UNDER PEER REVIEW

(35) HERRO R, DA SILVA AR, AGUILERA AR, TAMADA K, CROFT M. TUMOR NECROSIS FACTOR SUPERFAMILY 14 (LIGHT) CONTROLS THYMIC STROMAL LYMPHOPOIETIN TO DRIVE PULMONARY FIBROSIS. J ALLERGY CLIN IMMUNOL 2015 SEP;136(3):757-68.

(36) HERRO R, CROFT M. THE CONTROL OF TISSUE FIBROSIS BY THE INFLAMMATORY MOLECULE LIGHT (TNF SUPERFAMILY MEMBER 14). PHARMACOL RES 2015 DEC 31;104:151-5.

(37) SCHUPPAN D. STRUCTURE OF THE EXTRACELLULAR MATRIX IN NORMAL AND FIBROTIC LIVER: COLLAGENS AND GLYCOPROTEINS. SEMIN LIVER DIS 1990 FEB;10(1):1-10.