

Case study

Multiple myeloma relapse presenting as unilateral blindness.

Abstract

Multiple Myeloma is a chronic disease. While therapy is largely focused for control, relapse is inevitable. Central nervous system relapse of myeloma is less common. Unilateral painless blindness is a rare entity and its occurrence in setting of multiple myeloma has not been commonly reported. We encountered a case of multiple myeloma on treatment, who developed unilateral blindness and later on confirmed to have relapse of disease.

Introduction

Multiple Myeloma is a systemic malignant condition of plasma cell lineage. About 3% of myeloma cases have extra medullary depositions of malignant plasma cells known as plasmacytomas.[1] While plasma cell deposits in upper half of skeletal system is common, involvement of central nervous system and orbits has been noted as well.[2,3,4] Unilateral optic nerve infiltration by plasma cells during treatment course of myeloma is an unusual and interesting finding.

Case Presentation:

A 57 years old female presented with loss of vision from right eye for 2 months. She was a diagnosed case of multiple myeloma [IgG, Kappa] for last 2 years. Her initial treatment was with a 2 drug therapy including Bortezomib, Dexamethasone along with Zolendronic acid. She achieved remission after 4 months and was continued on same chemotherapy for total 8 months. She was placed on thalidomide- dexamethasone regimen thereafter. She was on regular follow up and last assessment done 6 months back showed good control of disease. Her clinical examination now showed absence of light perception in right eye with no proptosis or ophthalmoplegia. Left ocular examination was normal. Detailed CNS examination showed no other significant finding. She underwent MRI brain which showed infiltrating mass compressing right optic nerve, distal to chiasma.[Fig1] Direct and indirect ophthalmoscopy was normal with

normal fundus examination. Systemic workup showed increase in plasma cells in bone marrow and increased beta 2 microglobulin, serum LDH and IgG kappa chain. A systemic relapse of disease was considered along with plasma cell deposits over right optic nerve. She was started on Dexamethasone- Cyclophosphamide regimen in view of CNS penetration of these drugs. Radiotherapy to plasma cell deposit was started. Inj Bortezomib was added later in the course. She showed partial gain of vision post therapy. [perception of light and finger counting at 1 meter present].

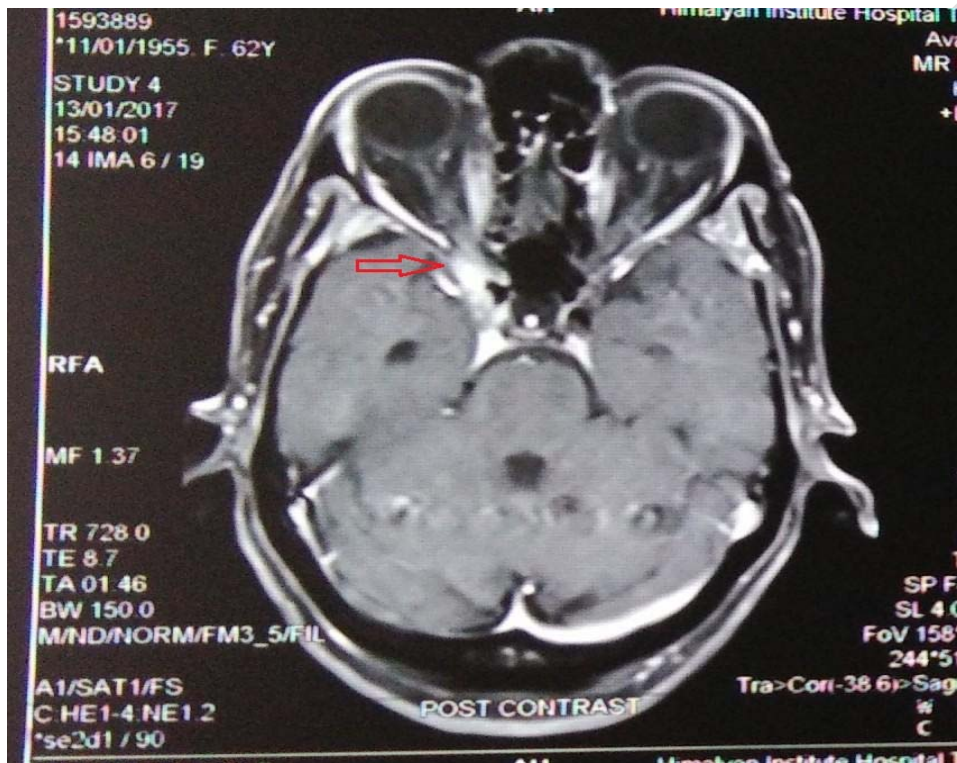


Fig I- MRI brain showing soft tissue density at right optic foramen.

Discussion

Multiple myeloma is a systemic disease of plasma cells. It is at one end of a spectrum of plasma cell dyscrasia, while milder localized forms can be detected as well. Being a systemic disease, its manifestation and presentation are variable. Usual presentation includes derangement of renal and haematological parameters as well as lytic bony lesions. However infiltration of organs has been noted as well.[5,6] It is practically an incurable disease and target of therapy is only to control it. Usual course with treatment is also with relapses at variable time periods. Ocular

manifestation of multiple myeloma at presentation of relapse are variable. It includes corneal deposits, macular exudative detachments, or choroidal deposits. Usual presentation is with proptosis and hyperemia. [7,8] Plasma cell infiltration of cranial nerves has been noted less frequently. Frequent involvement is noted for oculomotor, abducens and hypoglossal cranial nerves. [9,10] Optic nerve compression causing blindness has been noted as initial feature in literature.[11] However a systemic relapse presenting with unilateral blindness is an unusual finding.

Treatment of CNS involvement is not standardized and mostly derived from systemic therapy of myeloma. Drugs with good CNS penetration should work well. As plasma cell deposits are sensitive to radiotherapy, an immediate relief is expected from palliative radiotherapy. Index case presented to us with unilateral blindness for 2 months duration. Post radiotherapy, **only marginal improvement was noted**. A possibility of long standing compression causing permanent damage to optic nerve fibres is considered.

Conclusion:

Unilateral blindness due to malignant plasma cell deposits is an uncommon clinical entity. As **multiple myeloma has vivid clinical presentation**, a prompt suspicion **should be kept for disease progression even in the scenario of unusual complaints**.

Consent Disclaimer:

As per international standard or university standard written participant consent has been collected and preserved by the authors.

References

1. Adkins JW, Shields JA, Shields CL, Eagle RC Jr, Flanagan JC, Campanella PC. Plasmacytoma of the eye and orbit. *Int Ophthalmol*. 1996;20:339-43.
2. Knapp AJ, Gartner S, Henkind P. Multiple myeloma and its ocular manifestations. *Surv Ophthalmol*. 1987; 5: 343-51.
3. Chim CS, Ng I, Trendell-Smith NJ, Liang R. Primary extramedullary plasmacytoma of the lacrimal gland. *Leukemia Lymphoma*. 2003; 42: 831-4.

4. Damaj G, Mohty M, Vey N et al. Features of extramedullary and extraosseous multiple myeloma: a report of 19 patients from a single center. *European Journal of Haematology*. 2004; 73: 402–6.
5. Ravinet A, Perbet S, Guièze R, et al. Lung postmortem autopsy revealing extramedullary involvement in multiple myeloma causing acute respiratory distress syndrome. *Case Reports in Hematology*. 2014, Article ID 635237, 3 pages, doi:10.1155/2014/635237
6. Togano T, Sohtaro MI, Miwa A, Hagiwara S. Clinicopathological Analysis of CNS Involvement in Multiple Myeloma. *Blood*. 2015; 126: 5326.
7. Malik A, Narang S, Handa U, Sood S. Multiple myeloma presenting as bilateral orbital proptosis. *Indian J Ophthalmol*. 2009; 57: 393-5.
8. Lazaridou MN, Micallef-Eynaud P, Hanna IT. Soft tissue plasmacytoma of the orbit as part of the spectrum of multiple myeloma. *Orbit*. 2007;26:315-8.
9. Movsas TZ, Balcer LJ, Eggenberger ER, Hess JL, Galetta SL. Sixth nerve palsy as a presenting sign of intracranial plasmacytoma and multiple myeloma. *J Neuro-Ophthalmol*. 2000; 20: 242-5.
10. Kashyap R, Kumar R, Kumar S. Cranial nerve palsy in multiple myeloma and solitary plasmacytoma. *Asia Pac J Clin Oncol*. 2010; 6: 251-5.
11. Yilmaz, SG, Ture G, Zengin MÖ, Talay E, Men S. Optic nerve and dura mater involvement as the first sign of multiple myeloma. *European journal of ophthalmology*. 2014; 25: 77-9.