

A rare case of acquired axillary cystic hygroma in an adult patient.

ABSTRACT:

A case of cystic hygroma was found in an adult male patient of 43 -year- age in the left axilla, which was non tender cystic mass (57 x 40 x 49 mm) filled with haemorrhagic blood. It was successfully removed surgically without any complications. Being very rare presentation in axilla of an adult, this case is reported.

Keywords: Cystic hygroma, Adult, Axilla, Haemorrhage.

1. INTRODUCTION

Cystic hygroma, a benign and congenital malformation of lymphatic system, also known as lymphangioma, usually occurs in children especially in neck. [1-3]. Cystic hygroma in adult is very rare and less than 150 cases of cervicofacial cystic hygroma are reported in English literature up to 2011 [2]. Hygroma means a water containing tumour. This lesion does not have connection with the lymphatic or venous system. It may have unilocular or multilocular cystic lesions and may be of variable size. In microcystic varieties the cyst may be less than 2 cm diameter but in macrocystic size is more than 2 cm (also known as cystic hygroma) and in mixed variety the size of cysts is variable [4,5]. Most often it is found in cervical region of children and less frequently found in axilla or other site. Other uncommon sites are soft tissue, orbital cavity, mediastinum, pancreas, liver, ovary, and fallopian tubes [6]. There are only four cases of cystic hygroma in axilla of adult patient [7-10].

Literature search (PUBMED, google and science direct) did not show any published report from Malaysia. In view of rare occurrence in adult especially in axilla, this case is reported. To the best of our knowledge this is the first reported case of cystic hygroma in axillary region in an adult patient from Malaysia.

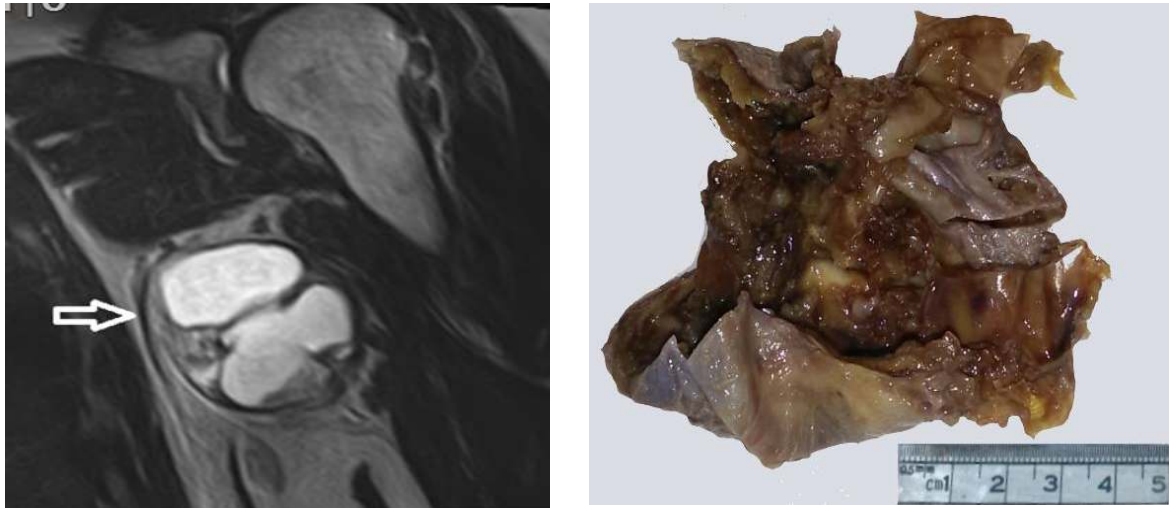2. CASE HISTORY

A 43 -year- old man, was referred to surgical clinic of this hospital on 7th July 2015 with complaint of a mass in left axilla since 10 years which was very small, but recently in last few months, it was increasing in size and patient had problem in moving the left upper arm. The surgeon examined the case and found a cystic mass in left axilla about 60 mm x 50 mm in size. It was cystic and fixed. There was no history of trauma, and there was no loss of weight or appetite by the patient. Patient gave history of chronic use of deodorant spray.

Patient was referred to radiology department for MRI of left axillary mass which revealed a well-defined oval cystic mass in left axilla measuring 57 x 40 x 49 mm. it was not attached to surrounding structure like blood vessels and muscles etc. The mass was cystic and no solid component was found in it [Figure 1]. The wall was smooth and thin and there was a fluid level

37 seen in the cyst. Axillary lymph nodes were not enlarged. The MRI diagnosis was a cystic hygroma
38 with hemorrhagic blood within it.

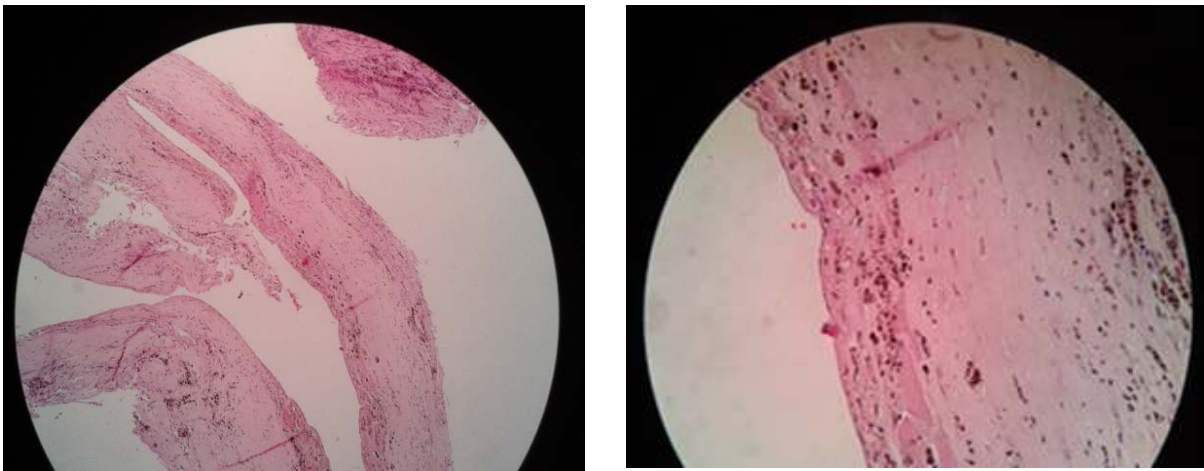
39



40

41 **Fig 1.** MRI of left axilla showing wall of cyst (large black arrow). The cyst is filled with haemorrhagic blood
42 (white in colour within the cyst wall -- large arrow mark).

43 **Fig 2 :** Gross appearance of the inner surface of the wall showing some blood clots (dark brown).



44 **Fig3:** Microscopic appearance of the cyst wall (H&E stain, X 100). The thin and smooth cyst wall composed
45 fibrous connective tissue lined by flattened epithelium.

46 **Fig 4:** High power microscopic (H&E stain, X 400) shows flattened epithelium and scattered hemosiderin
47 laden macrophage in the wall.

48 The patient was operated under general anaesthesia on 8th July 2015 and the cystic lesion was
49 completely removed. The removed specimen was sent in formalin for histopathology.

The pathologist noted that the outer wall was intact, smooth, and brownish black in colour and size of cut opened specimen was 93x83x10 mm as seen in picture. The lumen of cyst was unilocular and bit irregular without any papillary structures. The wall was thin and smooth. There were some blood clots within the cyst [Figure 2].

Few random areas were selected from the gross specimen and processed for microscopic examination. Microscopic features were characterised by a thin and smooth wall, which was composed of fibrous connective tissue lined by very thin and flatten epithelium. Few hemosiderin laden macrophages were seen in the wall. There were no any papillary structures or any malignant changes in cyst wall [figure 3]. Histopathological diagnosis was cystic hygroma with some haemorrhage in the cyst.

Post-operative stay in the hospital was uneventful. The patient was discharged from hospital on third postoperative day and was followed up at two monthly intervals. There was no problem found during follow up visits. The operated site showed healed scar without any recurrence in the left axilla (disease free for four months)

3. DISCUSSION

Cystic hygroma (also known as cystic lymphangioma) is a congenital lesion usually seen in children under the age of 2 years. It is a malformation of lymphatics. It may occur at various places in the body but usually in the neck and uncommonly in other part of body of children. Cystic hygroma is an uncommon lesion in adult and very few cases are reported in literature. [2,4]. The cystic hygroma are benign and painless proliferation of lymphatics and occurs with no connection between lymphatics and venous system.

The predisposing factors that are responsible for the development of cystic hygroma in adult are infection, trauma, being as a growth or iatrogenic stimuli etc. [1]. Surgical excision is the main treatment and other treatment includes injection of bleomycin, a sclerosing agent and laser surgery.[1,3,5]

A case of large, fluctuant and non-tender cystic hygroma (10x12x17 cm) was reported by Gelal et al in a 24 year old, seven months pregnant woman in left axilla, situated between anterior and posterior axillary line [7].

Güner et al reported a case of axillary cystic hygroma in 83 -year- old male with history of discomfort during inspiration phase of breathing for the past four months. It was a painless and mobile right axillary mass. They did not find any recurrence during five months follow up period [8].

Michail et al reported a cystic hygroma in a female patient which developed rapidly in the axillary region in the absence of any predisposing factor [9].

McCaffrey et al reported another case of cystic hygroma in a 58 year old male in right upper flank extending up to axilla which was non tender and large (20x12x7 cm). It was multi septate lesion and there was no any recurrence found on follow up after one year of surgery [10].

In our case there was no history of any predisposing factors. Presence of blood in the removed cyst suggests the possibility of minor trauma before coming to the hospital for check-up. The size of cystic hygroma of this case was medium size when compared to other two cases.

Detailed imaging procedures like ultrasound, MRI and CT scan will help the diagnosis preoperatively and histopathological examination of surgically removed specimen will confirm the diagnosis of cystic hygroma.

4. CONCLUSION

Cases of cystic hygroma in adult male especially in the axillary region is a rare occurrence.

ETHICAL APPROVAL:

It is not applicable.

REFERENCES:

1. Naidu SI, McCalla MR. Lymphatic malformations of the head and neck in adults: a case report and review of the literature. *Ann Otol Rhinol Laryngol*. 2004 Mar;113(3 Pt 1):218-222.
2. Gow L, Gulati R, Khan A, Mihaimed F. Adult-onset cystic hygroma: a case report and review of management. *Grand Rounds*. 2011;11(1):5-11.
3. Bloom DC, Perkins JA, Manning SC. Management of lymphatic malformations. *Curr Opin Otolaryngol Head Neck Surg*. 2004;12(6): 500-504.
4. Manikoth P, Mangalore GP, Megha V. Axillary Cystic Hygroma. *Journal of post graduate medicine*. 2004; 50 (3) 215-216.
5. Fonkalsrud EW. Lymphatic disorders. In : Grosfeld JL, O'Neil JA Jr, Caron JA. *Pediatric surgery*. 6 th ed. Mosby Elsevier, Chicago 2006: pp 2137-2145.
6. Stacey e. Mills, Sternburg's Diagnostic surgical pathology 4th ed. Volumes 1-3. Lippincott Williams & Wilkins. 2004 pp 72, 1098,1259-60,1632,1754,2617, 2662.
7. Gelal F, Yucel K, Tugsel E , Guney S. Axillary Cystic Lymphangioma Presenting in Pregnancy. *Tr J of Medical science* 1998; 28 : 571-572.
8. Güner A, Aydın A, Çelik F. Cystic Hygromas in Adults: Reports of Two Cases .*Olgu Sunumlar / Case Reports*. 2006;2:101-103
9. Michail O, Michail P, Kyriaki D, Kolindou A, Klonaris C, Griniatsos J. Rapid development of an axillary mass in an adult: a case of cystic hygroma. *South Med J*. 2007;100(8):845-9.
10. McCaffreya F , Taddeob J . Surgical management of adult-onset cystic hygroma in the axilla *Int J Surg Case Rep*. 2015; 7: 29-31