

LYMPHANGIOMA OF NASOPHARYNX IN AN ADULT : A RARE CASE.

ABSTRACT: Lymphangiomas are rare benign congenital malformations of the lymphatics, most often encountered during childhood. Generally they are found in the head and neck, isolated involvement of the nasopharynx is very rare. Our patient had a nasopharyngeal lymphangioma which aggravated his chronic otitis media. The surgical excision of mass was performed by a combined transoral and transnasal endoscopic approach. Histopathological evaluation revealed the diagnosis as lymphangioma. After a follow-up of 1 year the patient is free of recurrence.

KEYWORDS: Lymphangioma; Nasopharynx; IHC-immunohistochemistry.

INTRODUCTION: Lymphangiomas are congenital malformations of the lymphatic system. Lymphangiomas are classified as microcystic, macrocystic and cystic hygromas according to the size of the lymphatic cavities incorporated [1].


They commonly present in the head and neck region, with over 90% of lesions manifesting before 2 years of age. The onset of the lesion after 2 years of age is rare [2].


Isolated involvement of the nasopharynx with lymphangioma is very rare. Literature search for nasopharyngeal lymphangioma displayed two unique cases that had been reported in Russia in 1966 and 1969 (no abstract available), after which two more cases have been reported, one in Turkey and the other in India, in 2013 [2],[3].

Nasopharyngeal lymphangioma can cause eustachian tube obstruction and precipitate chronic otitis media.

CASE REPORT:


A 34 year old male presented with left chronic suppurative otitis media for 10 to 12 years; patient had noticed a small mass in the oral cavity on the left side for last 4 to 5 years.

On otoscopy, the left tympanic membrane showed a large central perforation with mucoid discharge in the middle ear. ~~Patient gave history~~  intermittent mucopurulent ear discharge which used to subside on topical antibiotic medications temporarily.


Oral examination revealed a 3x3 cm pinkish cystic mass in the left supratonsillar fossa. On probing it was found to be attached to the posterior tonsillar pillar and ~~to have an extension~~  into the nasopharynx. (figure 1 & 2)

Diagnostic nasal endoscopy showed a polypoidal mass, which was obliterating the eustachian tube (ET) opening on the left side. It was attached to the supero-lateral wall of the nasopharynx, the posterior lip of the ET opening (figure 3) and in continuity with the small cystic mass seen in the oropharynx, through the posterior pillar of the tonsil.

A computed tomography(CT) contrast neck reported a minimally enhancing(27 Hounsfield units on plain and 31 Hounsfield units on postcontrast) soft tissue mass measuring 22 x 21 mm. There was minimal obliteration of the left fossa of Rosenmuller and the mass extended into the oropharynx involving the left posterior tonsillar pillar and supratonsillar fossa. (figure4 A&B)

A magnetic resonance imaging (MRI) showed no neuro-vascular extension and a submucosal soft tissue mass.(figure4 C) 

After routine blood investigations, pre-anaesthetic checkup and informed written consent, patient was posted for surgery. A combined approach of transnasal and transoral routes was used. A simple rubber catheter was inserted through the right nostril and used to retract the soft palate for better visualization. A 4mm rigid zero degree endoscope along with a insulated sickle knife, on which unipolar cautery was applied, was used to gradually separate the nasopharyngeal part. Care was taken to avoid cauterization of the eustachian tube opening. Once the nasopharyngeal part was separated from the lateral wall, the oropharyngeal part was excised in a manner similar to tonsillectomy, by placing the patient in the Rose's position. The oropharyngeal extension was removed along with the left posterior pillar of the tonsil (figure5) using a bipolar cautery. Hemostasis was achieved, rest of the post-operative period was uneventful. Histopathology showed, multiple cystically dilated channels lined by a flattened endothelium. Immunohistochemistry(IHC) was positive for lymphatic lineage markers D 2–40 (figure6). The histopathological diagnosis was lymphangioma.

DISCUSSION: Lymphangiomas are uncommon, congenital benign malformations of the lymphatic system.  They are slowly progressive vascular hamartomas.

Recently Catalfamo et al.[4] reported nine tongue lymphangiomas in adults. Naidu and Mc Calla [5] reported a comprehensive review of studies from 1828 to 2000 years on lymphatic malformation in adults. They found 91 adult cases of lymphangiomas, located on the neck. But our adult male patient had a lymphangioma in the nasopharynx, which is an unusual site.

Lymphangiomas are diagnosed on the basis of history, examination findings and radiological investigations. Lymphangiomas at oral cavity, tongue, and larynx can present with symptoms of dysphagia, dyspnea, foreign body sensation, sore throat and tonsillar mass. When located at the nasopharynx, they may cause nasal obstruction or may aggravate the COM without symptoms of nasal obstructions per se. Though our patient had a visible mass in the oropharynx, smaller sized nasopharyngeal pathology can go undetected if nasal endoscopy is not performed. Hence from our experience, it is essential that every patient with COM be screened with nasal endoscopy to rule out any nasal/nasopharyngeal pathology.

MRI can demarcate the mass from the surrounding tissues and can give the extent of the lesion. Contrast enhanced CT scan can also be helpful in investigating these lesions.

Antrochoanal polyps, nasopharyngeal carcinoma, angiofibroma, cystic lesions, and other benign masses should be included in the differential diagnosis. Lymphangiomas can get infected or can cause hemorrhage and the mass effect associated with rapid growth of the lesion. Also in some patients, lymphocytopenia, a precipitating cause of infection, can be documented[6]. Lymphangiomas can be managed by namely surgical excision; laser debulking, sclerotherapy and corticosteroids[7]. It is suggested that the desire for complete excision must be weighed against the need to keep vital structures intact. If the larynx is involved tracheostomy is almost always required [8].

Though in our case we used cautery, surgical laser is considered particularly suitable because it allows precise ablation and recontouring of the tissue so that the functions can be preserved [9]. Coblation too would be similar to laser or perhaps even better, but there is no literature available currently regarding its use for such a case. Sclerosing agents can be used but they act by causing inflammatory reaction hence, their use can result in damage to adjacent structures. Radiotherapy is not effective in treatment of lymphangiomas[10].

In our case we were able to excise the lesion without causing any damage to surrounding vital anatomical structures using a transoral and transnasal endoscopic approach. We reported this case because of the unusual site of involvement and unusual age of presentation. Also, it is very rare to see a nasopharyngeal lymphangioma aggravating chronic otitis media due to ET obstruction.

CONCLUSION: Although lymphangioma of the nasopharynx is very rare, it can cause ET obstruction and aggravate COM. Complete surgical excision followed by a tympanoplasty (if required) would be the ideal way to go about. Since there is a risk of recurrence, regular follow up would be essential.

Informed consent and ethical approval was obtained before the procedure. No funds/grants were obtained for this surgery.

REFERENCES:

- [1]. Bloom D C ,Perkins JA,Manning SC.Management of lymphatic malformations. Curr Opin Otolaryngol Head Neck Surg 2004;12:500–504.
- [2] Haksever M, Akduman D, Aslan S, Yazla S, Haksever H. Nasopharyngeal lymphangioma in an adult: a rarity. Laryngoscope. 2013 Dec;123(12):2972-5. doi:10.1002/lary.24214. Epub 2013 Jun 11. PubMed PMID: 23712707.
- [3]. Verma R, Verma RR, Verma RR, Sardana NK. Isolated Lymphangiomatous Polyp Nasopharynx in an Adult First Case Report in English Literature. Indian J Otolaryngol Head Neck Surg. 2014 Dec;66(4):460-3. doi: 10.1007/s12070-013-0681-3. Epub 2013 Oct 18. PubMed PMID: 26396962; PubMed Central PMCID: PMC4571466.
- [4]. Catalfamo L,Nava C,Lombardo G ,Iudicello V,Siniscalchi E N ,Saveriade PF. Tongue lymphangioma in adult. J Craniofac Surg 2012;23:1920–1922.

- [5]. Naidu SI, McCalla M R. Lymphatic malformations of the head and neck in adults: a case report and review of the literature. *Ann Otol Rhinol Laryngol* 2004;113:218–222.
- [6]. Stanescu L, Georgescu EF, Simionescu C, Georgescu I. Lymphangioma of the oral cavity. *Rom J Morphol Embryol* 2006;47:373–377.
- [7]. Orvidas LJ, Kasperbauer JL (2000) Pediatric lymphangiomas of the head and neck. *Ann Otol Rhinol Laryngol* 109(4):411–421.
- [8]. Cohen SR, Thompson JW (1986) Lymphangiomas of the larynx in infants and children: a survey of pediatric lymphangioma. *Ann Otol Rhinol Laryngol* 95(suppl 127):1–20.
- [9]. Papsin BC, Evans JNG (1996) Isolated laryngeal lymphangioma: a rare cause of airway obstruction in infants. *J Laryngol Otol* 110: 969–972.
- [10]. Sobol SE, Manoukian JJ (2001) Acute airway obstruction from a laryngeal lymphangioma in a child. *Int J Pediatr Otorhinolaryngol* 58:255–257.

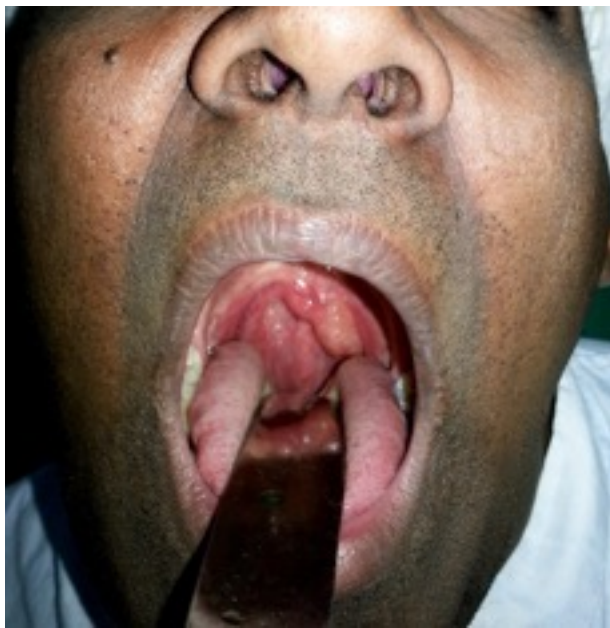

Figure 1: Cystic mass in the oropharynx

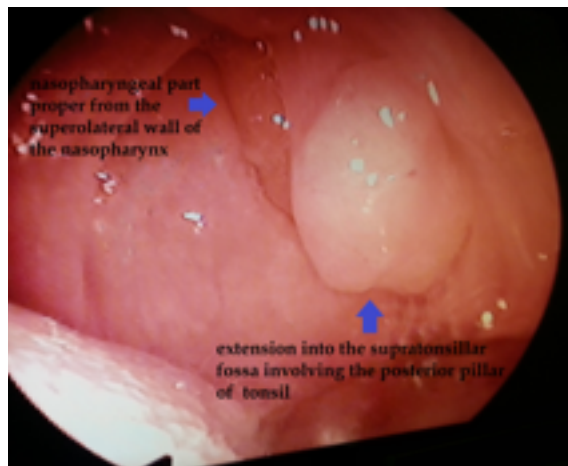

Figure 2:Zero degree view of the mass in the oropharynx

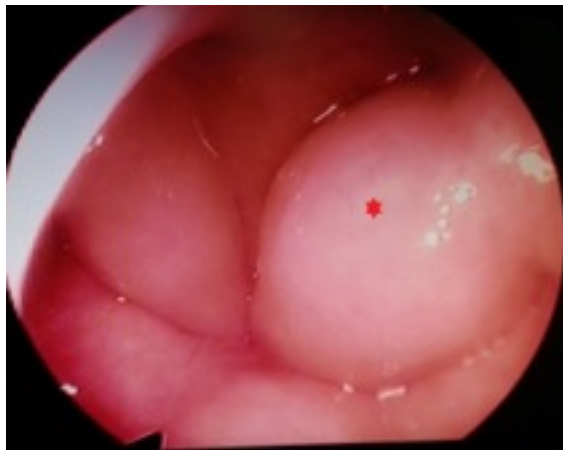

Figure 3:Zero degree view through the left nostril showing the nasopharyngeal mass (*)

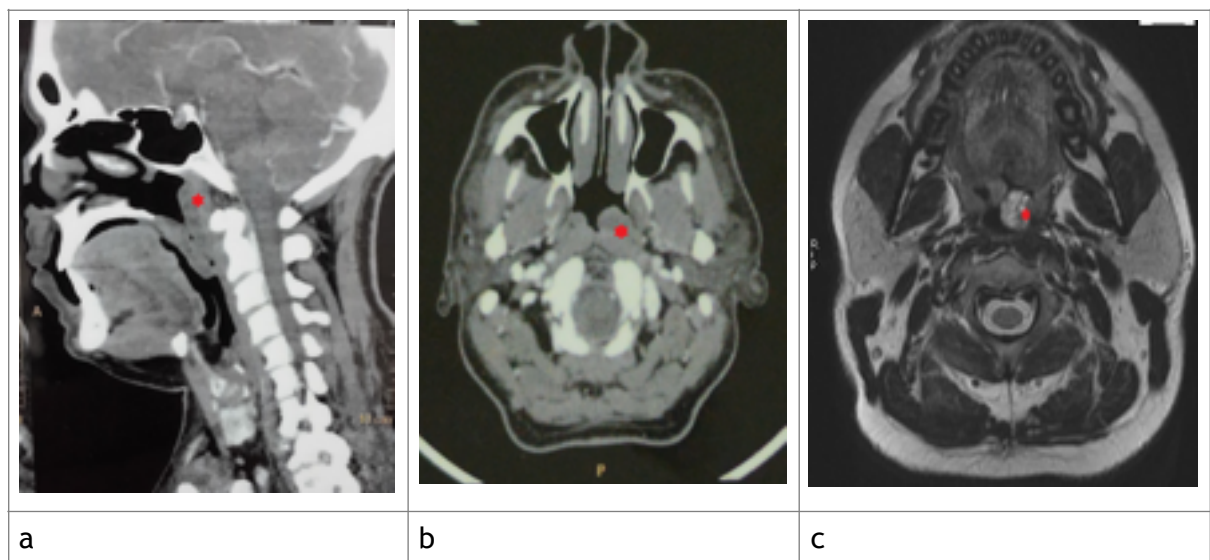


Figure 4:Radiological imaging

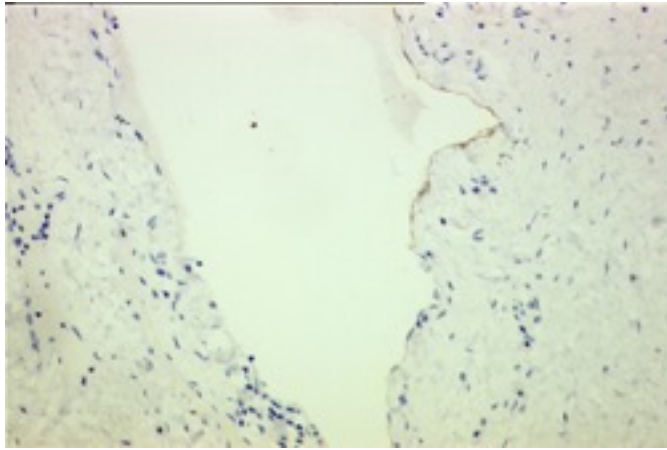


Figure 5:Excisional biopsy specimen

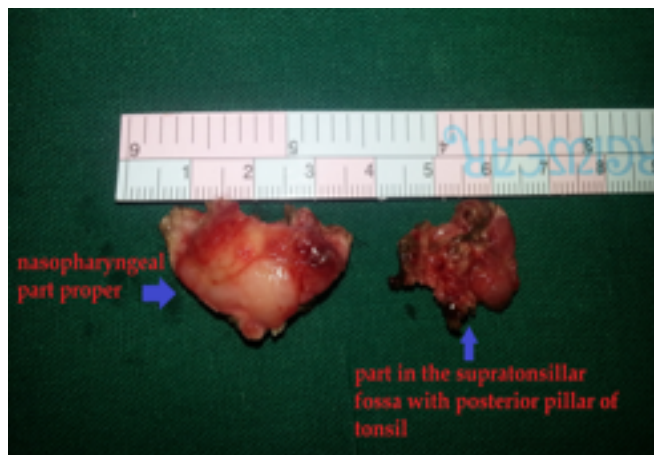

Figure 6:IHC with D2-40 marker for lymphangioma