

Original Research Article

P53 Expression in Response to Equigan Induced Testicular Injury and Oxidative Stress in Male Rat and The Possible Prophylactic Effect of Star Anise Extracts

ABSTRACT

Objectives: Equigan is an anabolic androgenic steroid that developed for veterinary use to improve the food producing animal growth rate through promoting protein synthesis and muscle growth. The current study aimed to investigate the possible prophylactic effect of star anise extracts (SAE) response of to Equigan induced testicular injury, oxidative stress, P53 expression in male rats.

Materials and Methods: Forty adult male rats were equally divided into four groups. 1st Control group, while 2nd group were rats receive orally SAE for 12 weeks. 3rd group include rats that injected intramuscularly with Equigan for 12 weeks while 4th group were co-treated group where rats injected with Equigan and SAE for 12 weeks. **Results:** Testis sections in Equigan treated rat induced abnormal arrangement of spermatogenesis cycles; disturbance and decrease in the spermatogenic cells, many of a syncytial cells were detected with marked decrease in sperms numbers and moderate depleted and degenerated Leydig cells. Testicular immunohistochemical observation after Equigan intramuscular injections showed a significant increase of the apoptotic protein p53. **Co-administration of SAE with Equigan improved the testicular injury and P53 alternations.**

Conclusions: SAE could scavenge free radicals and produce beneficial effects against Equigan damage in testis and P53 alternations.

Keywords: Equigan Anabolic steroid, Rat testis, Star anise, Histopathology, P53 apoptotic markers.

1. INTRODUCTION

Recently; anabolic-androgenic steroids are forbidden for meat production and human uses in most countries worldwide due to their undesirable effects included blood, cardiovascular disorders, liver dysfunction, kidney disease and testicular problems [1-8].

Equigan is an anabolic androgenic steroid (synthetic androgen hormone derived from testosterone) that developed for veterinary use to improve the food producing animal growth rate through promoting protein synthesis and muscle growth [9]. Equigan have been reclassified as Schedule III drugs and in addition it classified as class 2A (growth promoters-steroids according to the International Agency for Research on Cancer; ISRC), as a probable human carcinogen with a high carcinogenic index. Equigan can show up on

a steroid test for up to 1.5 years due to its very long half-life and it has dual effects on humans, directly by injection to better physical performance or to build muscles and indirectly through consuming meat of animals that were treated with Equigan [10].

Star anise (*Illicium verum* Hook. f.) is aromatic evergreen trees that grows in China and Vietnam and are well-known herbal medicine used in treatment of stomach aches, insomnia, vomiting, inflammation and rheumatic pain [11]. Star anise crude extracts has been reported to have various biological activities, such as antimicrobial [12] and antioxidant by reducing free radical production and lipid peroxidation [13]. Therefore, the current study aimed to investigate the possible prophylactic effect of star anise extracts (SAE) response of to Equigan **induced testicular oxidative stress, tissue injury, and P53 expression** in male rats.

2. MATERIAL AND METHODS

2.1. Chemical and reagent

Equigan® vial was obtained from Laboratorios Tornel Co., (S.A. Mexico). Each vial containing oily solution (50mg /ml vehicle).

2.2. Experimental animals

Healthy male albino rats (weighting 180-200 g and 12-14 weeks age), supplied from the accredited breeding and experimental laboratory (Tanta Alpha Center, Egypt) were used for this study. The animals had free access to water. Rats were monitored closely during the treatment period (12 weeks). All the experiments were designed and conducted according to the ethical norms approved by the Ethical Committee of National Research Center. This work was supported by the Deanship of Scientific Research (DSR), Princess Nourah bint Abdulrahman University, Riyadh, Saudi Arabia, under grant No.37-K-189. The experimental procedures were approved by the Committee of Ethics in the Use of Experimental Animals –ENRC (Protocol no. 039/2008).

After 2 weeks of acclimatization, rats were assigned to 4 groups (10 animals each).

Control group; in which rats will not receive any treatment.

Star anise group; in which rats will receive orally star anise extract (SAE) by stomach tube (100 mg/kg BW/ twice a week) for 12 weeks according to Wang et al. [12].

Equigan group; in which rats will injected intramuscular with Equigan (5 mg/Kg BW\ week) for 12 weeks according to Zahran et al. [10].

Treated Equigan with SAE group; in which rats will receive intramuscular injections of Equigan at (5 mg/Kg body weight/week) with oral SAE (100 mg/Kg body weight/ twice a week) together for 12 weeks.

2.2.1. Tissue preparation

At the end of the experimental period, rats from each group were euthanized with anesthetic ether and subjected to a complete necropsy after 10–12 hr of fasting. Testes tissues were weighed, cut and

homogenized (10% w/v) separately in ice-cold 1.15% KCl- 0.01mol/l sodium potassium phosphate buffer (pH 7.4) in a Potter-Elvehjem type homogenizer. The homogenate was centrifuged at 10,000 g for 20 min at 4°C and the resultant supernatant was used for different enzyme assays.

2.2.2. Activities of antioxidant enzymes

Thiobarbituric acid-reactive substances (TBARS) were measured in the homogenate using the method of Esterbauer and Cheeseman [14]. Hydrogen peroxide (H₂O₂) concentrations were measured according to Velikova et al. [15]. The activity of Catalase (CAT; EC 1.11.1.6) was determined using the Luck method involving the decomposition of hydrogen peroxide [16]. Reduced glutathione (GSH) content was measured after reaction with 5,5'- dithiobis-(2-nitrobenzoic acid) using the method of Ellman [17]. Superoxide dismutase activity (SOD; EC 1.15.1.1) was determined according to Misra and Fridovich [18].

2.2.3. Histopathological studies

Testes of the rats were immediately removed and fixed by immersion in 10% buffered formalin solution for 24-48 hours. Fixed testes were dehydrated, cleaned and embedded in paraffin. Serial sections of 5 µm thickness were cut by rotary microtome (Litz, Wetzlar; Germany) and stained with eosin and haematoxylin [19].

2.2.4. Detection of proliferation and apoptotic markers:

Expression of P53 as apoptotic markers (P53-ir) in the testis sections were detected using avidin Biotin Complex (ABC) method according to Tousson et al. [6].

2.3. Statistical Analysis

Data were expressed as mean values ± SE and statistical analysis was performed using one way ANOVA to assess significant differences among treatment groups. The criterion for statistical significance was set at $p < 0.01$ for the biochemical data. All statistical analyses were performed using SPSS statistical version 21 software package (SPSS® Inc., USA).

3. RESULTS

3.1. Thiobarbituric acid, hydrogen peroxide and reduced glutathione content:

As shown in Table 1, significant ($P < 0.05$) increase in TBARS and H₂O₂ concentrations, in rat testes after the intramuscular injection with Equigan. On the other hand, the levels of TBARS and H₂O₂ were decreased in treated Equigan with SAE group. On the other hand, GSH content was significantly decreased in rat treated with Equigan while rats treated with Equigan and SAE showed a significant increase in GSH content as compared to Equigan group (Table 1).

3.2. Antioxidant enzyme activities:

Data concerning testes CAT and SOD in rats treated with Equigan and their combination are presented in Table 1. Antioxidant enzyme activities were significantly decreased in Equigan treated group as compared to control. On the other hand, a significant modulation in antioxidant enzyme activities was observed in the group treated with Equigan plus SAE as compared with the Equigan treated one ($P<0.05$).

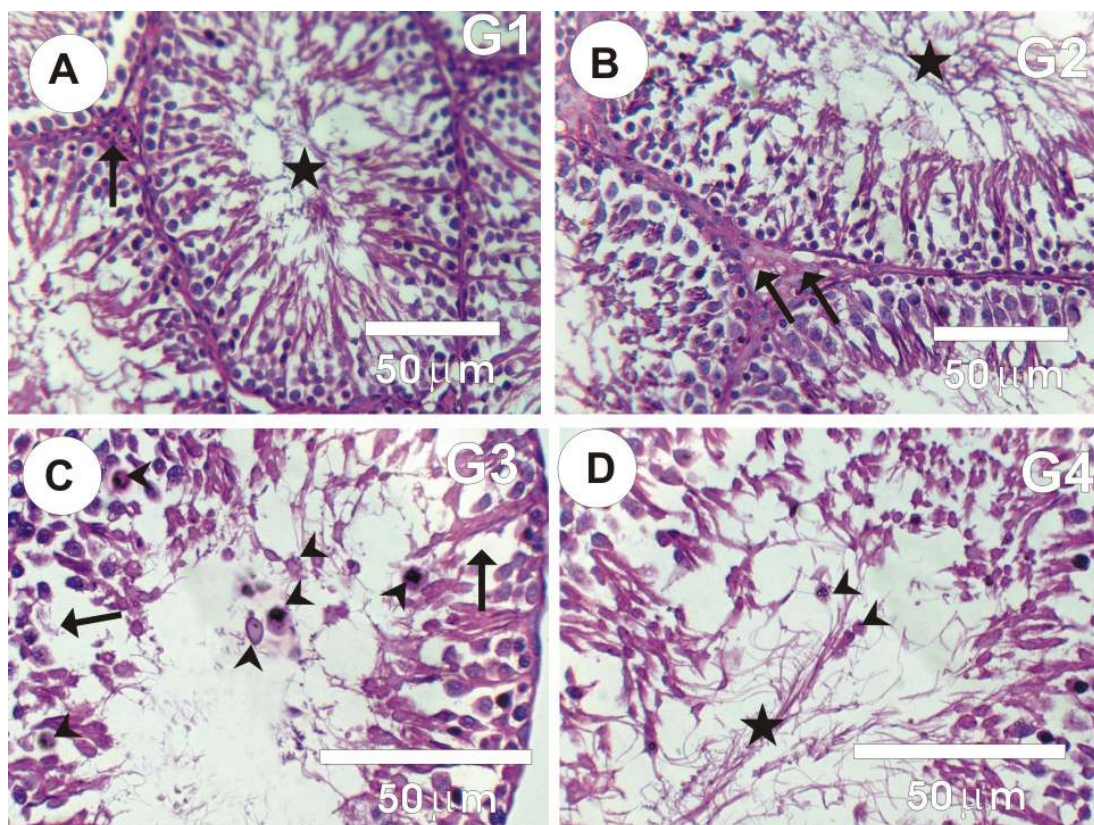
Table 1: Activities of thiobarbituric acid-reactive substances (TBARS; nmol/g protein), hydrogen peroxide (H_2O_2 ; $\mu\text{mol/ protein}$), Reduced glutathione (GSH; mmol/mg protein), catalase (CAT; U/mg protein), and superoxide dismutase (SOD; U/mg protein) in testes of male rats treated with star anise extract (SAE), Equigan and star anise extract plus Equigan (SAE+ Equigan).

Parameters	Experimental groups in testes			
	Control	SAE	Equigan	Equigan+SAE
TBARS*	18.05 \pm 0.524 [#]	16.48 \pm 0.755 [#]	29.22 \pm 1.15 ^a	23.14 \pm 1.605 ^{#a}
H₂O₂**	6.91 \pm 0.198 [#]	6.27 \pm 0.227 [#]	9.20 \pm 0.413 ^a	7.05 \pm 0.305 [#]
GSH***	2.31 \pm 0.044 [#]	2.86 \pm 0.107 [#]	1.78 \pm 0.043 ^a	2.01 \pm 0.059 ^{#a}
CAT*	7.02 \pm 0.369 [#]	7.84 \pm 0.442 [#]	4.76 \pm 0.545 ^a	5.19 \pm 0.760 ^a
SOD**	63.52 \pm 3.76 [#]	70.09 \pm 4.13 [#]	38.66 \pm 2.01 ^a	55.30 \pm 2.18 ^{#a}

Values are expressed as mean \pm SE; n=10 for each treatment group. Significant difference from the control group at ^a $p<0.05$. Significant difference from Equigan group at [#] $p<0.05$.

3.3. Effect of Equigan and SAE on testis histopathology

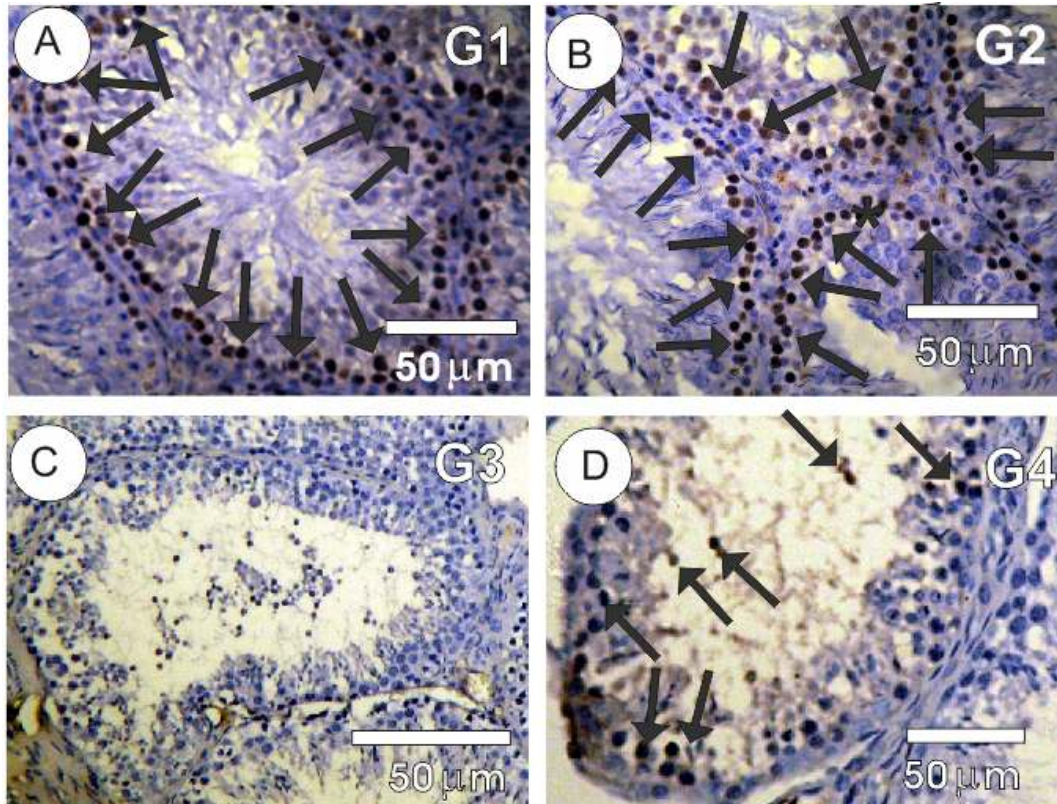
Sections of the testis in male rats in control and SAE groups showed normal structure of seminiferous tubules with regular cycle of spermatogenesis (Figures 1A&1B). However, testis sections in Equigan group showed abnormal arrangement of spermatogenesis cycles; disturbance and decrease in the spermatogenic cells, sloughing of germ cells into the tubular lumen, many of a syncytial cells were detected with marked decrease in sperms numbers and moderate depleted and degenerated Leydig cells (Figure 1C). Testis sections in the treated Equigan with SAE showed a mild degree of improvement where incomplete spermatogenesis cycles with a few numbers of a syncytial cells, in addition to mild depleted and degenerated Leydig cells were observed (Figure 1D).



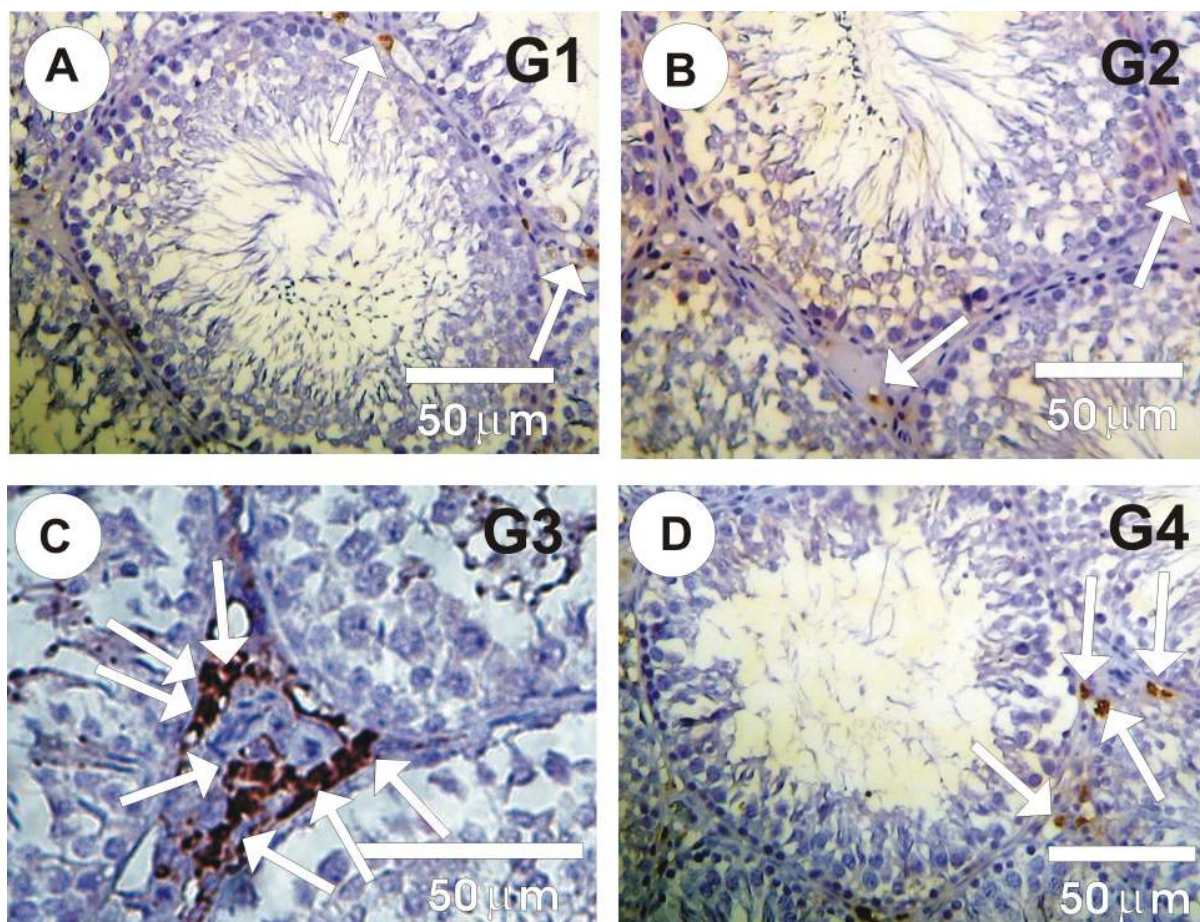
Figures 1: Photomicrographs of rat testes sections stained by HE. **A&B:** Rat testes in control (G1) and SAE (G2) groups shown normal structure of seminiferous tubules that were fully packed with sperms (stars). **C:** Rat testes in Equigan group (G3) shown abnormal arrangement of spermatogenesis cycles with disturbance and decrease in the spermatogenic cells (arrows), many of a syncytial cells (arrow heads) were detected with marked decrease in sperms numbers. **D:** Rat testes sections in the treated Equigan with SAE group (G4) showed incomplete spermatogenesis cycles with a few numbers of a syncytial cells (arrow heads).

3.4. Effect of Equigan and SAE on testicular P53 expression:

The distribution and detection in P53 expression (P53-ir) in testis sections in the different groups were showed in Figure 2 (A-D). Testis sections in control and SAE groups revealed faint positive reaction for P53-ir (Figures 2A&2B). Testis sections of Equigan group showed moderate positive reaction for P53-ir in Leydig cells and in some Sertoli cells when compared with control (Figure 2C). In contrast; testes sections in treated Equigan with SAE revealed mild positive reaction for P53-ir when compared with Equigan (Figure 2D).



Figures 2(A-D): Photomicrographs of testes sections stained with Ki67-ir in the different groups. **A&B:** Testes sections in control and SAE group showed strong positive affinity for Ki67 (arrows). **C:** Testis sections of Equigan group showed mild to faint positive affinity for Ki67 (arrows). **D:** Testes sections in treated Equigan with SAE revealed mild positive affinity for Ki67 (arrows).



Figures 3(A-D): Photomicrographs of testes sections stained with P53-ir in the different groups. **A&B:** Testes sections in control and SAE group showed faint positive affinity for P53 (arrows). **C:** Testis sections of Equigan group showed strong positive affinity for P53 (arrows). **D:** Testes sections in treated Equigan with SAE revealed mild positive affinity for P53 (arrows).

4. DISCUSSION

Equigan is one of the anabolic androgenic steroids which exhibit moderately androgenic and strong anabolic properties (8). The current study aimed to investigate the possible prophylactic effect of star anise extracts (SAE) on the liver oxidative stress, histopathological and immunohistochemical (P53 expression as apoptotic markers) by Equigan. Lipid peroxidation has been suggested to be closely related to Equigan-induced testicular damage and TBARS is a good indicator of the degree of lipid peroxidation [20]. The observed significant increases in TBARS content of testicular tissues in rats treated with Equigan results in loss of motility and impairment of spermatogenesis with the formation of cytotoxic secondary products such as TBARS [21]. This effect was confirmed by the significant negative correlation between testicular TBARS, and sperm count and motility [4,10]. Oda and. El-Ashmawy [22] and Thabet et al. [23] who reported that; a significant reduction in the sperm motility and count after boldenone

injections while no abnormalities were detected in the sperm morphology after boldenone injections. Cell damage occurs when there is an excess of reactive species derived from oxygen and nitrogen, or a defect of antioxidant molecules [24]. The observed increase in both reactive oxygen and nitrogen species after Equigan treatment was parallel to the increase in TBARS and the decrease in GSH [25]. Treatment with SAE caused significant decrease in TBARS, while GSH, CAT and SOD content was significantly increased. In addition, rats treated with SAE with Equigan showed significant alleviation ($P<0.05$) and maintained their levels near normal. Administration of star anise increased antioxidant enzyme activities in Equigan treated rats which might be due to its ability to reduce the accumulation of free radical generation. The chelating property of star anise to react with free radicals or with highly reactive byproducts of lipid peroxidation as well as enhancement of tissue TBARS might be responsible for the reduction of oxidative modification for enzymes and are versa of the activities of antioxidants and glutathione metabolizing enzymes. In addition, star anise maintained renal blood flow as a result of preserved nitric oxide through scavenging of the superoxide anions. Many herbs like SAE are well known to contain flavonoids and have a strong antioxidant effect that is beneficial for serum antioxidant levels, leading to improved sperm health parameters via the reduction of oxidative stress (26). Equigan is able to generate destructive ROS including hydroxyl radical and frequently used to produce oxidative and necrotic damages and this could be indicative of free radical scavenging properties of SAE. So it seems likely that long-term use of herbs can increase testosterone levels, improve sperm parameters and increase the chance of fertility.

In the current study, revealed that the our results indicated that; the intramuscular injection of rats with Equigan showing significant histological changes such as severe degeneration, marked decrease in the Leydig cells number, a trophy in most of seminiferous tubules; and increasing in the seminiferous tubules lumen with the lack of sperms. Moreover, the testicular degeneration was evident by vacuolation and desquamation of the spermatocytes. Also, the Leydig cells were slightly depleted and degenerated. Our results agreed with Tousson et al., [4] who reported that intramuscular injection with boldenone in rabbit has negative effect spermatogenesis and many of histopathological alternations in testes. The testicular lesions were similar to those described by Thabet et al. [23] and Oda and El-Ashmawy [22]. Cannizzo et al. [27] suggested that most of the histopathological changes seen in testis can be explained by estradiol, this was confirmed by the increase in estradiol level recorded in the present study. leukocytic infiltrations (neutrophils) on the degenerated cells and the interstitial tissue by chemotaxic agents that produced by damaged inflammatory tissues. Tousson et al. [4] showed the same results after boldenone injection in rabbit, which increased in dose dependent way. These changes suggested that boldenone adversely affects spermatogenesis which may lead to a continuous damage of the testicular function and structure and subsequent future infertility following boldenone cessation, explaining the common genital progressive disturbances of athletes and body builder. It also supports the findings of Takahashi et al. [28] who found a reduction in Leydig cell numbers after nandrolone administration. Co-treatment of Equigan with SAE showed a mild degree of improvement where incomplete spermatogenesis cycles with

depleted and degenerated Leydig cells and mild increasing in the sperm numbers when compared with Equigan rats group. These restorations may be due to the protective effect and antioxidant role of Star anise and this is in consistence with the study of Senthilkumar et al. [29]. As regards the reversibility of the effect of the drug on testicular tissue, in the present work, the recovery groups showed -in some fields- minimal spermatogenesis activity and scanty sperms production. However, this regeneration was not satisfactory and need to be evaluated by fertility indices. On the other hand, these results contradict the previous results of Holma [30] which showed complete recovery after discontinuing methandienone treatment for 3 month, and the conclusion of Hickson et al. [31] who stated that testicular atrophy, decreased spermatogenesis and altered sperm morphology have all been reversible. This may explain the contradiction between the continuous spermatogenesis after high amounts of testosterone in rat [33], the affected sperm parameter in men using methandienone [30], spermatogenic arrest and depletion in Leydig cells in rats injected by oxandrolone [34] and the reduction in Sertoli and Leydig cell numbers after using testosterone [34] and nandrolone [28]. The highest frequency of p53 positive cells was observed in the testicular sections in Equigan group, while the lowest in control group, when there is an excess of anti-apoptotic proteins, the cells are more resistant to apoptosis. Therefore, the increasing of p53 apoptotic cells in the present study reveals the possibility of the apoptosis occurrence after Equigan administration.

5. CONCLUSION

Many of abnormalities in testis structure were observed after injection of rats with Equigan these changes as arrangement of spermatogenesis cycles; disturbance and decrease in the spermatogenic cells, many of a syncytial cells were detected with marked decrease in sperms numbers and moderate depleted and degenerated Leydig cells. Testicular immunohistochemical observation after Equigan intramuscular injections showed a significant increase of the apoptotic protein p53. Co-administration of SAE with Equigan improved the testicular injury and P53 alternations. SAE could scavenge free radicals and produce beneficial effects against Equigan damage in testis and P53 alternations.

Acknowledgments

This work was supported by the Deanship of Scientific Research (DSR), Princess Nourah bint Abdulrahman University, Riyadh, Saudi Arabia, under grant No.37-K-189. The authors therefore, gratefully acknowledge the DSR technical and financial support.

CONSENT

It is not applicable.

ETHICAL APPROVAL

It is not applicable.

REFERENCES

- 1 El-Moghazy M, Tousson E Sakeran MI. Changes in the hepatic and renal structure and function after a growth promoter boldenone injection in rabbits. *Animal Biology* 2012; 62: 171-180.
- 2 Saleh N, Waded E. Immune response following the administration of the anabolic steroid Boldenone Undecylenate in rabbits. *Stem Cell* 2014; 5: 80-87.
- 3 Barakat LA, Tousson E, Ibrahim W, et al. Role of propolis in improving hepatic and renal damage in boldenone undecylenate in male rats. *American J Biol Chem.* 2015; 3: 8-15
- 4 Tousson E, El-Moghazy M, Massoud A, Akel A. Histopathological and immunohistochemical changes in the testis of rabbits after injection with the growth promoter boldenone. *Reprod. Sci.* 2012; 19(3), 253-9.
- 5 Tousson E, Ibrahim W, Barakat LA, et al: Role of Propolis administration in boldenone-induced oxidative stress, Ki-67 protein alterations and toxicity in rat liver and kidney. *Intern J Scientific & Engineering Res* 2015; 6: 660-664
- 6 Tousson E, El-Moghazy M, Massoud A, et al: Physiological and biochemical changes after boldenone injection in adult rabbits. *Toxicology and Industrial Health* 2016; 32: 177–182
- 7 Mohammed HH, Badawi ME, El-Tarabany MS, et al: Effects of boldenone undecylenate on growth performance, maintenance behaviour, reproductive hormones and carcass traits of growing rabbits. *Polish Journal Vet Sci* 2016; 19: 245–251.
- 8 Tousson E. Histopathological alterations after a growth promoter boldenone injection in rabbits. *Toxicology and Industrial Health* 2016; 32: 299–305.
- 9 Soma LR, Uboh CE, Guan F, MC-Donnell S, Pack J. Pharmacokinetics of boldenone and stanozolol and the results of quantification of anabolic and androgenic steroids in race horses and nonrace horses. *J. Vet Pharmacol Therap*, 2007; 30: 101-108.
- 10 Zahran F, Tousson E, Shalapy M. Ameliorating Effect of Ginkgo biloba and Moringa oleifera Against Equigan Induced Testicular Toxicity and Oxidative Stress in Male Rat. *American Journal of Biological Chemistry*, 2015; 3: 39-44.
- 11 Fritz E, Olzant SM, Länger R. *Illicium verum* Hook. f. and *Illicium anisatum* L.: anatomical characters and their value for differentiation. *Sci Pharm.* 2008; 76: 65–76.
- 12 Wang GW, Hu WT, Huang BK, Qin LP. *Illicium verum*: A review on its botany, traditional use, chemistry and pharmacology. *J Ethnopharmacol* 2011; 136: 10–20.
- 13 Guo DJ, Cheng HL, Chan SW, Yu PH. Antioxidative activities and the total phenolic contents of tonic Chinese medicinal herbs. *Inflammopharmacology* 2008; 16, 201–207.
- 14 Esterbauer H, Cheeseman KH. Determination of aldehydic lipid peroxidation products: malonaldehyde and 4-hydroxynonenal. *Methods Enzymology* 1990; 186: 407–421.
- 15 Velikova V, Yordanov I, Edreva A. Oxidative Stress and Some Antioxidant Systems in Acid Rain-Treated Bean Plants: Protective Role of Exogenous Poly-amines. *Plant Science* 2000; 151: 59-66

263 16 Luck H. "Catalase," In: Methods of Enzymatic Analysis, H. U. Bergmeyer, Ed., pp. 885–893, Academic
 264 Press, New York, NY, USA. 1971.

265 17 Ellman GL. Tissue sulfhydryl groups. Archives of Biochemistry and Biophysics 1959; 82: 70-77.

266 18 Misra HP, Fridovich I. The role of superoxide anion in the auto-oxidation of epinephrine and a simple assay for
 267 superoxidedismutase. *Journal of Biological Chemistry* 1972; 247: 3170 - 3175.

268 19 Bancroft JD, Steven A. Theory and Practice of Histological Technique (3rded.) NY: Churdchill
 269 livingstone, 1990; 42: 107-110.

270 20 Atessahin A, Karahan I, Turk G, Gur S, Yilmaz S, Ceribas AO. Protective role of lycopene on cisplatin
 271 induced changes in sperm characteristics, testicular damage and oxidative stress in rats. *Reprod*
 272 *Toxicol.* 2006; 21:42–47.

273 21 De Lamirande E, Gagnon C. The dark and bright sides of reactive oxygen species on sperm function.
 274 In: Gagnon, C. (Ed.), *The Male Gamete: From Basic Science to Clinical Application*. Cache River
 275 Press, Vienna, Austria, pp. 455–467. 1999.

276 22 Oda SS, El-Ashmawy IM. Adverse effects of the anabolic steroid, boldenone undecylenate, on
 277 reproductive functions of male rabbits. *International journal of experimental pathology*, 2012; 93:
 278 172-178.

279 23 Thabet NS, Abelrazek EM, Ghazy EM, et al: Effect of the anabolic steroids, boldenone undecylenate
 280 on reproductive performance on male rabbits. *J Reprod. Infertil* 2010; 1: 8–17.

281 24 Medina J, Moreno-Otero R. Pathophysiological basis for antioxidant therapy in chronic liver disease.
 282 *Drugs.* 2005; 65: 2445–2461

283 25 El Sayed H, Ahmad TA. The use of propolis as vaccine's adjuvant. *Vaccine*, 2012; 31: 31-39.

284 26 Khaki, A., Fathiazad, F ., Nouri, M., Khaki, A ., Maleki, N.A., Khamnei, H.J., and Ahmadi, P. Beneficial
 285 effects of quercetin on sperm parameters in streptozotocin-induced diabetic male rats. *Phytother*
 286 *Res.* 2010; 24(9):1285-91

287 27 Cannizzo FT, Zancanaro G, Spada F, Mulasso C. and Biolatti, B. Pathology of the testicle and sex
 288 accessory glands following the administration of boldenone and boldione as growth promoters in
 289 veal calves. *Journal of Veterinary Medical Science* 2007; 69: 1109-1116.

290 28 Takahashi M, Tatsugi Y, Kohno T: Endocrinological and pathological effects of anabolic-androgenic
 291 steroid in male rats. *Endocr J* 2004; 51: 425-34

292 29 Senthilkumar S, Yogerta SK, Subashini R, Deraki T. Attenuation of cyclophosphamide induced toxicity
 293 by squalene in experimental rats. *Chemico-Biological Interactions* 2006; 160: 252-260.

294 30 Holma PK. Effects of an anabolic steroid (metandienone) on spermatogenesis. *Contraception* 1977;
 295 15(2):151-162.

296 31 Hickson RC, Ball KL and Falduto MT. Adverse effects of anabolic steroids. *Med. Toxicol. Adverse*
 297 *Drug Exp.* 1989; 4(4):254-271

298 32 Ludwig DJ. The effect of androgen on spermatogenesis. *Endocrinology* 1950; 46:453-481.

- 299 33 Grockett BH, Ahmad N and Warren DW. The effects of an anabolic steroid (oxandrolone) on
300 reproductive development in the male rat. *Acta Endocrinol.* 1992; 12 6(2):173
- 301 34 Feinberg MJ, Lumia AR, McGinnis MY. The effect of anabolic– androgenic steroids on sexual behavior
302 and reproductive tissues in male rats. *Physiol Behav* 1997; 62 (1), 23–30.
- 303
- 304