UNDER PEER REVIEW

Case study

URETERIC CALCULI COMPLICATING PREGNANCY

ABSTRACT:

Urolithiasis is the most common cause of non-obstetrical abdominal pain that requires hospitalization among pregnant patients (1). We are presenting a case of symptomatic right ureteric calculi. This was diagnosed during second trimester. The patient did not respond to conservative management and had to be treated surgically with good symptomatic improvement.

KEY WORDS: Urolithiasis, Ureteric calculi, Pregnancy

INTRODUCTION:

Kidney stones affect 10% of the population during their lifetime and over the past 2 decades this statistic has risen. This affects 1 in 200 to 1 in 1500 pregnancies.

Urinary tract changes occur during pregnancy. Both kidneys increase in size by 1-1.5 cm during pregnancy (2). Kidney volume increases by 30% due to renal vasculature and interstitial volume. There is an increase in glomerular filtration rate by 50% (3). Dilatation of renal pelvises and caliceal system occurs due to progesterone effect. Mechanical compression of the ureters at the pelvic brim by the gravid uterus (more prominent on the right) (4). Certain bladder changes like increased vascularity of bladder, decreased muscle tone and odematous bladder mucosa are seen in pregnancy. There is an increased frequency to micturate. Creatinine, urea and uric acid clearance increases during pregnancy.

CASE REPORT:

Mrs. P, 24 years female, primi gravida, with 22 weeks gestation was admitted with c/o right loin to groin pain for past 1 week. Associated with vomiting and dysuria. The following investigations were done, hemoglobin was 10.2%, total count was 10,300, random blood sugar was 74 mg/dl, RFT was with normal range, urine routine showed positive for protein (2+), nitrate (1+), leukocyte (2+), plenty of RBC, 15-20 WBC, 2-3 epithelial cells. Urine culture and sensitivity testing showed few pus cells and occasional gram negative bacilli, E.coli 10000 CFU, sensitivity to amikacin, cefotaxime, cefuroxime, co-trimoxazole, gentamicin, nitrofurantoin, norfloxacin. Ultrasonogram findings showed 1x0.4 cm calculus in the right vesicoureteric junction, bilateral ureteric jet was normal, SLIUG with gestational age of 22+ weeks

Conservative management:

Initially conservative management was tried for 2 weeks. Patient was started on hydration therapy with intravenous fluids and plenty of oral fluids. Pain was treated with analgesics and antispasmodics (like drotaverine). The urinary infection was treated with antibiotics- nitrofurantoin 100mg twice daily for one week. There was no symptomatic

UNDER PEER REVIEW

improvement with conservative management. Hence, patient was taken up for surgery (right URS with DJ stenting)

Preoperative preparation: Patient was started on progesterone supplements one day prior to surgery

Procedure

Under spinal anesthesia, right URS (ureteroscopy) was done using 6F ureteroscope and right VUJ (vesicoureteric junction) calculus visualized (Figure1). ICL (intra corporeal lithotripsy) done using pneumatic waves. Another stone of size approx. 1.5 cm found in the right lower ureter and the same cleared. Bilateral 6 F DJ stenting done. The steps of the procedure are summarized in table 1.

Long lasting carbothane stents were used. Advantage of carbothane stent is that they can be left in situ for 6 months. Whereas, conventional stents should be removed by 3 months.

POST-OPERATIVE PERIOD

Progesterone supplements were continued for 10 days. Cefotaxime was given for 7 days. Tocolytics like isoxsuprine was given for 3 days. Biochemical analysis of the stone: calcium oxalate. Patient had a good symptomatic relief.

FOLLOW UP

Patient was advised to increase intake of fluids and low calcium diet. She went till 37 weeks and delivered vaginally a boy baby, birth weight 2.17 kg. One month after delivery, the stents were removed.

DISCUSSION

Treatment goals in a case of renal calculi complicating pregnancy:

To reduce maternal discomfort, to prevent renal damage and sepsis due to obstructing calculi and to minimize risk to fetus.

Surgical care: Surgical intervention is required in 20-30% of pregnancies complicated by urolithiasis. Indications for surgical interventions are 1) ureteral obstruction associated with increasing azotemia, 2) obstruction in a solitary kidney, 3) intractable pain despite maximal conservative measures, 4) urosepsis and 5) renal colic induced preterm labor.

Ureteroscopy is the first line approach to urinary calculi that requires intervention. Anatomical distortion late in pregnancy and complications due to exposure to anesthesia are few minor limitations.

Timings of surgical intervention is usually in the first and second trimester. PCN is preferred in women with </= 22 weeks of gestation.

LASER or pneumatic source are the preferred energy sources.

UNDER PEER REVIEW

CONCLUSION:

Urolithiasis during pregnancy is more complex than when it occurs in the general population and diagnosis can sometimes be quite challenging.

CONSENT:

We have obtained the patient's consent for the case report.

REFERENCES

1. Riley JM, Dudley AG, Semins MJ. Nephrolithiasis and pregnancy: has the incidence been rising?. J Endourol. 2014 Mar. 28(3):383-6.

2. Burgess KL, Gettman MT, Rangel LJ, Krambeck AE. Diagnosis of urolithiasis and rate of spontaneous passage during pregnancy. J Urol. 2011 Dec. 186(6):2280-4.

3. Liu G, Wang J, Li J, Zheng J, Huang Z, Ye Z. Urolithiasis in pregnancy: survey in clinical epidemiology. J Huazhong Univ Sci Technolog Med Sci. 2011 Apr. 31(2):226-30.

4. Katz DS, Klein MA, Ganson G, Hines JJ. Imaging of abdominal pain in pregnancy. Radiol Clin North Am. 2012 Jan. 50(1):149-71.

5. Srirangam SJ, Hickerton B, Van Cleynenbreugel B. Management of urinary calculi in pregnancy: a review. J Endourol. 2008 May. 22(5):867-75.

6. White WM, Zite NB, Gash J, Waters WB, Thompson W, Klein FA. Low-dose computed tomography for the evaluation of flank pain in the pregnant population. J Endourol. 2007 Nov. 21(11):1255-60.

7. Parsons JK, Hergan LA, Sakamoto K, Lakin C. Efficacy of alpha-blockers for the treatment of ureteral stones. J Urol. 2007 Mar. 177(3):983-7; discussion 987.

8. Rivera ME, McAlvany KL, Brinton TS, Gettman MT, Krambeck AE. Anesthetic exposure in the treatment of symptomatic urinary calculi in pregnant women. Urology. 2014 Dec. 84(6):1275-8.

9. Akpinar H, Tüfek I, Alici B, Kural AR. Ureteroscopy and holmium laser lithotripsy in pregnancy: stents must be used postoperatively. J Endourol. 2006 Feb. 20(2):107-10.

10. Boubred F, Vendemmia M, Garcia-Meric P, Buffat C, Millet V, Simeoni U. Effects of maternally administered drugs on the fetal and neonatal kidney. Drug Saf. 2006. 29(5):397-419.

11. Koren G, Florescu A, Costei AM, Boskovic R, Moretti ME. Nonsteroidal antiinflammatory drugs during third trimester and the risk of premature closure of the ductus arteriosus: a meta-analysis. Ann Pharmacother. 2006 May. 40(5):824-9.

UNDER PEER REVIEW

Steps	Procedure
1	Under spinal anesthesia
2	Right URS (ureteroscopy) was done using 6F ureteroscope
3	Right VUJ (vesicoureteric junction) calculus visualized
4	ICL (intra corporeal lithotripsy) done using pneumatic waves
5	Another stone of size approx. 1.5 cm found in the right lower ureter and the same cleared
6	Bilateral 6 F DJ (double J) stenting done

Table 1: Steps of Right Ureteroscopy With Pneumatic Wave Lithotripsy Followed By Bilateral DJ (Double J) Stenting

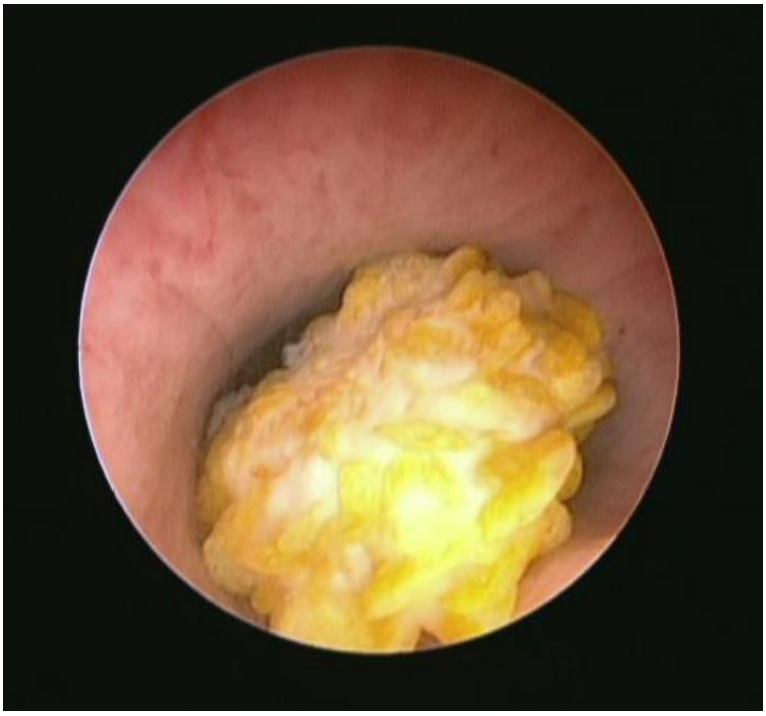

Figure 1: Right Vesicoureteric Junction Calculus Visualised By 6 F Ureteroscope