

## OVERVIEW OF MANAGEMENT OF NASAL SEPTAL ABSCESS IN A PRIVATE FACILITY IN LAGOS, NIGERIA

### Abstract

**Background:** Nasal septal abscess is an uncommon nasal disorder. Commonly present lately, so its management must be meticulously and urgent.

This study aimed at determined the clinical presentation, diagnosis and management septal abscess in our community.

**Method:** This prospective hospital based study of consecutive patients diagnosed with nasal septal abscess over a period five year at a private facility, Golden cross infirmary, Lagos, Nigeria. Consented patients were enrolled into the study. Data obtained collated and analysed using SPSS version 18.

**Results:** Forty seven patients were enrolled into the study. Male accounted for 32 (68.1%) and female accounted for 15 (31.9%) with male female ratio of 2:1.

The peak age group incidence were  $\leq 10$  and 41-50 years age group.

Duration of illness at presentation was 4 (8.5%) patients within a week, 14 (29.8%) patients at two weeks, and 29 (61.7%) patients at three weeks. Sources of referral were mainly from general practitioner 19 (40.4%) , and family physician 24 (51.1%).

Majority of our patients 45 (95.7%) were seen at clinic and 1 (2.1%) casualty (accident and emergency).

Clinical features at presentation were nasal blockage 47 (100%), difficulty breathing 43 (91.5%), nasal pain 38 (80.9%), rhinorrhea 45 (95.7%), mouth breathing 26 (55.3%), Snoring 19 (40.4%), headache 28 (59.6%), poor appetite 12 (25.5%) and fever 8 (17.0%).

Hematoma/abscess was bilateral in 43 (91.5%) cases. Needle aspiration of the nasal septum confirmed hematoma in 4 (8.5%) cases and abscess in 43 (91.5%) cases. Aspirates microscopy, culture, and sensitivity tests were negative in 7 (14.9%) with growth of 23 (48.9%) *Staphylococcus aureus*, 15 (31.9%) *Streptococcus* spp and 2 (4.3%) *Hemophilus influenzae*.

Implicated aetiological factors were rhinosinusitis 31 (66.0%), trauma was 9 (19.1%) and furunculitis/vestibulitis 5 (10.6%) and idiopathic 2 (4.3%) cases.

All our patients had combination of surgery (incision and drainage with drains), antibiotics, analgesic and daily dressing. Complications recorded were 3 (6.4%) recurrence, 37 (78.7%) septal oedema and 6 (12.8%) facial cellulitis.

**Conclusion:** Nasal septal hematoma/abscess are quite uncommon. There is predominance of male patients in all age groups. Sinonasal infection and trauma and other causes have been described as the main aetiological factors. Prolonged nasal obstruction not responding to nasal decongestant is a pointer to early diagnosis. Immediate surgical intervention are essential for prevention of complications

**Keywords:** Nasal septal abscess, septal hematoma, incision and drainage, rhinosinusitis, culture and sensitivity.

### Introduction

The nose is a special organ occupying the middle third of the face and the most prominent facial structure making it to be prone to most injuries on the face<sup>1</sup>. The nasal septum is the bone and cartilage in the nose that separates the nasal cavity into the two nostrils.



Nasal septum hematoma and abscess are defined as blood or pus collections between the bone and cartilaginous septum and the mucoperiosteum or mucoperichondrium <sup>2</sup>. Nasal septal hematoma/abscess are not common disorder and the real prevalence is not well established <sup>2,3</sup>.

Increase in level of awareness of nasal septal hematoma/abscess has changed through the years and in different centers.

It is very important to examine the nasal septum of all individuals who have suffered a trauma and to also conduct a nasal radiological examination <sup>4,5</sup>.

There is gender predisposition to nasal septal hematoma/abscess. There was great predominance of male patients with septal hematoma/abscess in all ages. There are different aetiological causes of nasal septal hematoma/abscess. The most studied and most common causes are injuries that range from surgery, domestic, assault, industrial, sport activities or accidents.

Other causes are infection of facial structures such as dental abscess, ethmoid and sphenoid sinusitis, and nasal furunculosis <sup>6-8</sup>. However, in clinical diagnosis absence of antecedent facial or nasal trauma, should prompt the possible source of nasal septal infection.

Pathophysiology of nasal septal hematoma with subsequent to nasal injury is poorly understood <sup>9-11</sup>. There were some mechanical forces which applied against the cartilage that result in rupture of vessels of the mucoperichondrium. When there is associated cartilage fracture, the blood can dissect through the fracture line and cause bilateral hematoma. Accumulated hematoma expand and mechanically obstruct the vascular supply of the nasal cartilage, leading to avascular necrosis induced by pressure within threetofourdays. The accumulated hematoma and necrotic tissue are good culture media for bacterial such as Staphylococcus that colonizes the nasal mucosa with resultant formation of abscess.

The common clinical manifestations at diagnosis are nasal obstruction, mouth breathing, nasal pain, local fluctuation, deformed nose, tender on palpation and reddish edema of septal mucosa <sup>12</sup>. Test aspirate may produce blood in hematoma or pus in abscess.

Aspirate from nasal septum must be investigated. Microscopic culture and sensitivity usually revealed offending organisms. Common isolated organisms are Staphylococcus aureus, Staphylococcus viridans, Enterococcus faecalis, Streptococcus pyogens, Streptococcus pneumoniae and Hemophilus influenza <sup>13</sup>. Anaerobes and coliform microorganisms are less commonly isolated. Fungal agent has been implicated in immune compromised individuals. Further investigation includes computerized tomography scans in intracranial complicated cases.

Nasal septal hematoma/abscess is associated with cosmetic complication such as septal oedema, facial cellulitis, osteocartilaginous necrosis and saddle nose <sup>14,15</sup>. Intracranial complications are due to cranial of the diseases. This includes subarachnoid empyema, meningitis and cerebral abscess. Routes of intracranial extension are vascular (venous or lymphatic), fracture lines, suture lines, surgical wound and direct bone erosion by the diseases.

Nasal septal hematoma/abscess are treated by both surgical and medical approaches. There is paucity of literature on the nasal septal hematoma/abscess management in Nigeria. This study is aimed at determining the septal hematoma/abscess aetiology, clinical features, complications, and management in a private facility in Lagos.

## **Materials and methods**

This is a prospective hospital based study of all patients with diagnosis of nasal septal abscess. All consecutive patients who presented with diagnosis of nasal septal abscess at the



Golden cross infirmary, Lagos were enrolled into the study. The study was carried out over a period of 5 years (January 2011 to December 2016).

Ethical clearance was obtained from the ethical committee of the hospital.

Informed consent was obtained from patients/guardian/parents before patients were enrolled into the study. Consented patients were prospectively studied.

Interviewer assisted questionnaire were given to consented patient to obtain detailed history on biodata, and occupation. Detailed otorhinolaryngological history was taken from the patient/guardian/parents. Detailed history on possible aetiological and predisposing factor was taken. Past medical, surgical, family and social history were taken. General physical and systemic examination was performed. Thorough nose, ear, throat, head and neck examination were done and documented. Thorough rhinological examination includes anterior rhinoscopy, nasal cavity and nasal septal examination. Aseptic needle aspiration was performed on nasal septum and the aspirates was examined and sent for microscopy, culture, and sensitivity.

All the patients were educated based on the findings and the line of management of the nasal septal hematoma/abscess. Patient were then booked for incision and drainage. The procedure was performed under local or general anesthesia depending on the patient clinical status. Under local or general anesthesia a vertical incision was made over the point of maximum fluctuance. The abscess loculi are broken and the septal cavity was irrigated with 0.9% saline solution and packed with Vaseline gauze impregnated with gentamicin cream. Appropriate analgesic and broad spectrum antibiotics were prescribed and adjusted with result of aspirate culture and sensitivity. Depending on patient postoperative state the patient were either treated as day case or admitted. Participant was followed up in the ear, nose and throat clinic for possible outcome and complications.

All data obtained were documented, collated and analysed. The data analysis was done by using SPSS version 18.

## Results

There were 47 consented participants. Male sex accounted for 32 (68.1%) and female were 15 (31.9%) and male to female ratio was 2:1.

Table 1 showed age distribution of the study population. The peak age group incidence were  $\leq 10$  years age group and 41-50 years age group.

Duration of illness prior to presentation revealed as follows: 4 (8.5%) patients at 1 week, 14 (29.8%) patients at 2 weeks, and 29 (61.7%) patients at 3 weeks. This is illustrated in figure 1.

Sources of referral of the patients with nasal septal abscess presenting in our ear, nose and throat department were 43 (91.5%) general practitioner, 1 (2.1%) casualty officer and 3 (6.4%) others.

Majority of the patients presented at otorhinolaryngological clinic while minority presented as emergencies. These were: clinic, 45 (95.7%), casualty (accident and emergency) 1 (2.1%) and wards 1 (2.1%) as shown in figure 2.

Table 2 shown clinical features of the patients at presentation were 47 (100%) nasal blockage, 43 (91.5%) difficulty with breathing, 38 (80.9%) nasal pain, 45 (95.7%) rhinorrhea, 26 (55.3%) mouth breathing, 19 (40.4%) Snoring, 28 (59.6%) headache, 12 (25.5%) poor appetite and 8 (17.0%) fever.

The hematoma/abscess was bilateral in 43 (91.5%) cases, 3 (6.4%) in the right and 1 (2.1%) in the left side of the nasal septum as illustrated in figure 2.

Needle aspiration of the nasal septum confirmed hematoma in 4 (8.5%) cases and abscess in 43 (91.5%) cases.

All the aspirates from the nasal septum were sent for microscopy, culture, and sensitivity tests. Negative culture were noticed in 7 (14.9%). Positive culture were noticed in 40 (85.1%)



aspirates. The analysis revealed 23 (48.9%) *Staphylococcus aureus*, 15 (31.9%) *Streptococcus* spp and 2 (4.3%) *Hemophilus influenzae*. This is shown in table 3.

Detailed history on aetiological factors revealed rhinosinusitis was responsible for 31 (66.0%) cases while trauma was responsible for 9 (19.1%) and furunculitis with vestibulitis was responsible for 5 (10.6%) cases and idiopathic in 2 (4.3%) cases. This is illustrated in figure 3.

Prior to presentation at our department most participants 44 (93.6%) had used some form of self-medication such as 34 (72.3%) antibiotics, 11 (23.4%) decongestants, 38 (80.9%) analgesic and 42 (89.4%) vitamins.

All our patients had combination of surgery (incision and drainage with drains), antibiotics, analgesic and daily dressing until abscess cavity was cleared. Incision and drainage was done under local anaesthesia in 23 (48.9%) and general anaesthesia in 24 (51.1%). Antibiotics were changed in 15 (31.9%) based on microscopic, culture and sensitivity result and patients response to earlier prescribed treatment. All the study population were successfully treated and discharged home. Participants were followed up as outpatient over 6 weeks. No defaulters among all our participants. Recurrence were noticed in 3 (6.4%) of our patients and further complications were 37 (78.7%) septal oedema and 6 (12.8%) facial cellulitis.

Table 1: Age distribution of patients with nasal septal abscess

Age group	Number of participants	Percentage (%)
≤10	11	
11-20	8	
21-30	5	
31-40	6	
41-50	14	
≥60	3	

Figure 1: Duration of illness.

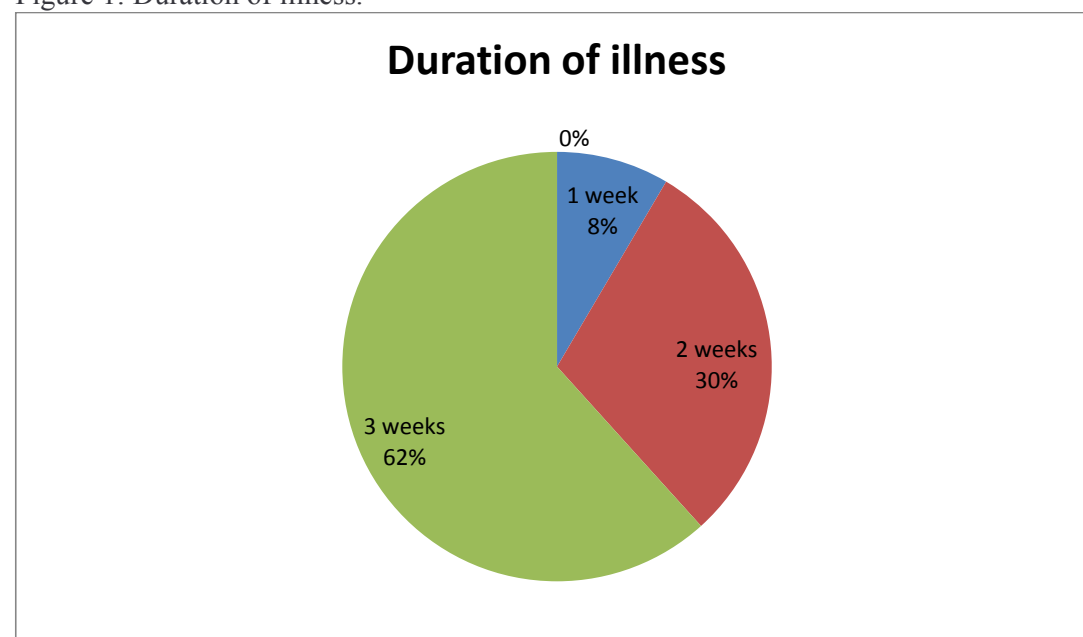




Figure 2: Presentation of nasal septal hematoma/abscess to the department

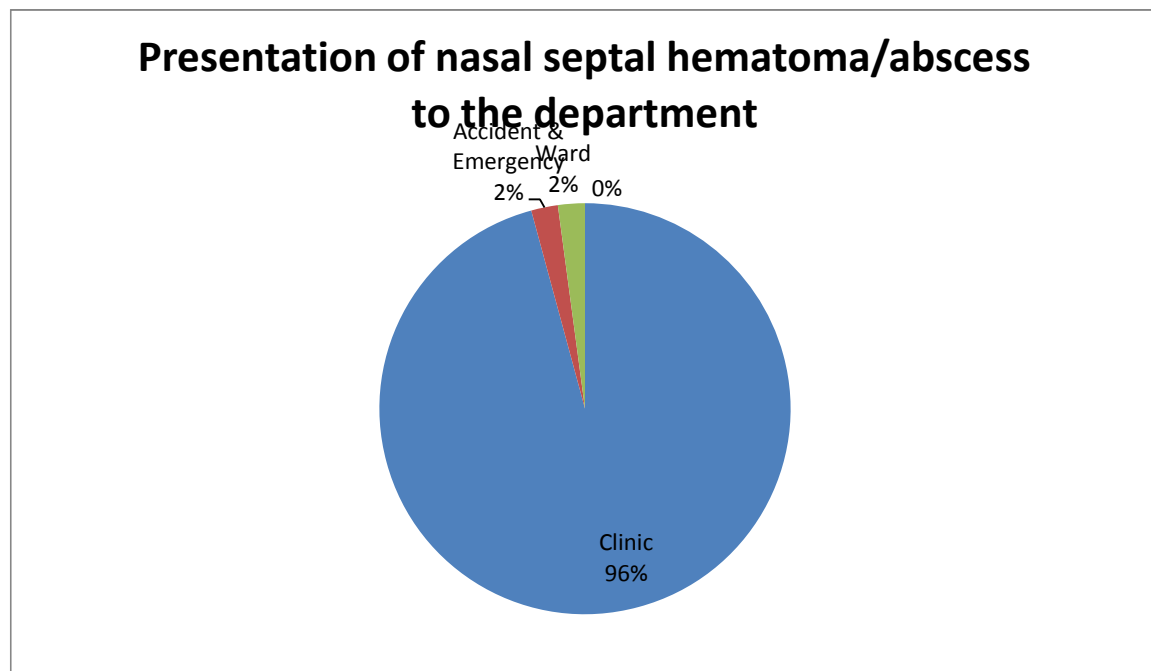


Table 2: Clinical presentation of patients with nasal septal hematoma/abscess

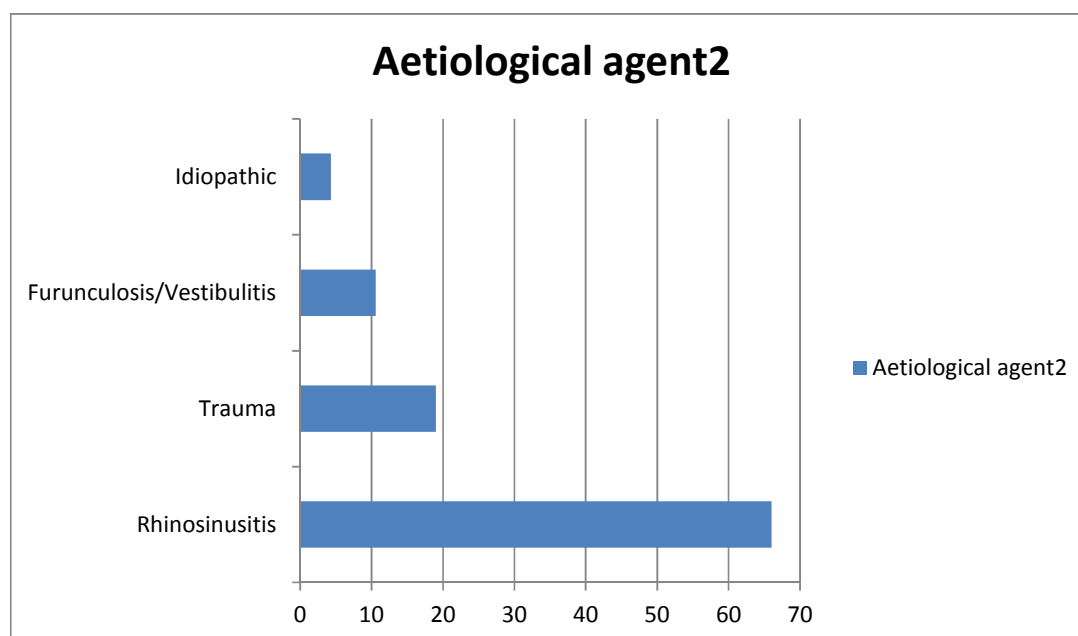
Symptoms	Number of patients(n)	Percentage (%)
Nasal blockage	47	100
Difficulty breathing	43	91.5
Nasal pain	38	80.9
Rhinorrhea	45	95.7
Mouth breathing	26	55.3
Snoring	19	40.4
Headache	28	59.6
Poor appetite	12	25.5
Fever	8	17.0

Table 3: Isolated microorganisms from nasal septal hematoma/abscess

Microorganisms	Number (n)	Percentage (%)
Staphylococcus aureus	23	48.9
Streptococcus	15	31.9
Hemophilus influenzae	2	4.3
Nil growth	7	14.9



Figure 3: Aetiology agent of nasal septal hematoma/abscess



## Discussion

Nasal septal haematoma/abscess are uncommon sinonasal disorders worldwide. This is evidenced by diagnosis of only 47 cases during this 5 years study in our community<sup>12-17</sup>. The rate of occurrence of nasal septal hematoma/abscess varies in different communities<sup>12</sup>. In our study 68.1% males participants were twice females participants (M:F =2:1) and previous studies revealed a strong male predominance in hematoma/abscess of the nasal septum<sup>16</sup>. Males are more commonly involved in accident and violence than females. Men are prone to accident such as road traffic accidents, industrial and domestic accidents due to their role in the family than females. Male are also at greater risk of exposing to infection than female, hence developed nasal septal hematoma/abscess than female.

Nasal septal haematoma/abscess affect all age group. This is noted to be common in children in some series<sup>16</sup>. Their findings was that the muco-perichondrium is not closely bound down to the cartilage in children compared with adults. Mild trauma can easily leads to collection of blood into the subperichondrial space with the torn of the submucosal blood vessels. Our study revealed bimodal age group peaks at ( $\leq 10$ ) and (41-50) age groups. This may be due to the findings of infection as a major cause of nasal septal hematoma/abscess. Trauma was major aetiological agent in previous study<sup>17-19</sup>. In this study the major aetiological agent was sinonasal infection like rhinosinusitis. Trauma is responsible for less cases in our series.

Patients with nasal septal hematoma/abscess usually present very late to Otorhinolaryngologist head and neck surgeons. The early stage which is characterized with hematoma in patients with traumatic aetiology or cellulitis in patients with infective aetiology were missed in most patients. Abscess would have been aborted with simple drainage of hematoma or antibiotics with nasal septal cellulitis. Majority 29 (61.7%) of the studied participants present at the third weeks of their disease. This could be the reason for high percentage of 43 (91.5%) abscess in this studied population than 4 (8.5%) hematoma of same studied population.

Majority 45 (95.7%) of the patients present at our ear, nose and throat clinic rather than 1 (2.1%) accident and emergency ward. This may be because most of our participant present as



cold cases. The patient are mostly stable as in this studied population. Further literature search revealed few complicated cases at presentation to the Otorhinolaryngologist head and neck surgeon<sup>20</sup>.

Patient are not familiar with symptoms of nasal septal diseases and its complications. Sinonasal disease such as acute rhinitis are considered to be households and are ordinarily managed with over-the-counter drugs.

In this study the most common clinical features of septal hematoma/abscess was nasal obstruction, found in all the patients . This is the resultant effect of combination of nasal septal inflammation, oedema and accumulation of blood or pus. This compromise the nasal air flow. Work from other studies reported similar findings<sup>21-23</sup>. Subsequently this will lead to mouth breathing with occasional snoring. On clinical examination a bulbous bluish or reddish hue over the nasal septal mucosa is a pointer to nasal septal hematoma/abscess. Complete intranasal examination with anterior rhinoscopy in all cases of nasal septal hematoma/abscess is essential for further findings such as extent of the abscess, intranasal laceration, dislocation and fractures. Needle aspiration was done on the nasal septum for all the participants. The nature of the aspirate will confirm the diagnosis (pus or blood), relieve pressure, and provide specimen for microscopy culture and sensitivity.

Majority of the nasal septal aspirate yields growth of respiratory tract microorganism. This proof that nasal septal abscess in this study were due mainly to sinonasal infections. Majority of isolated microorganisms were staphylococcus aureus, streptococcus and Hemophilus influenzae. This contradict other study which emphasis that nasal septal hematoma/abscess are secondary to nasal and facial trauma<sup>23-25</sup>.

In patients with nasal septal hematoma/abscess computerise tomography (CT) scanning is required. CT scan is necessary to rule out complications such as intracranial extension. CT Scan is indicated with the following findings: extensive facial cellulitis, periorbital cellulitis, meningitis, loss of consciousness and localizing neurological signs and treatment failure.

Complications were recorded in this work which includes recurrent cases, facial cellulitis nasal septal oedema and so on.

Some previous study did not record any complications<sup>26-27</sup>. This may be explained by less cases reported in their study. Further reason may be virulence of the offending organism, stage of presentation and management techniques.

## Conclusion

Nasal septal hematoma/abscess is not commonly encountered sinonasal condition with almost equal incidence in both children and adults. Infection and trauma are the most frequent etiology. Males are more affected than females. Nasal septal hematoma/abscess with early presentation, prompt diagnosis, and treatment provide a good prognosis. Treatment is by incision and drainage, intranasal packing, with insertion of drain, including antibiotics coverage is an effective treatment modality.

A high index suspicion, and vigilant nasal examination of patients presenting with long standing nasal obstruction with or without nasal trauma would lead to early diagnosis of septal hematoma/abscess and prevention of functional, aesthetic, and intracranial complications.

## References

1. Menger DJ, Tabink I, Nolst Trenité GJ. Treatment of septal hematomas and abscesses in children. *Facial Plast Surg.* 2007. 23(4):239-43.
2. Matthew DJ. Functional Rhinoplasty



- 270 Management of Pediatric Nasal Surgery (Rhinoplasty). *Facial Plastic Surgery Clinics of*  
271 *North America*. 2017, .25(2):211–221.
- 272 3.Afolabi, O.A.; Salisu, A.; Adeyemo, A.A. Ijaduola, G.T.A Nasal Septal Abscess in Ibadan  
273 Nigeria. *Tropical Journal of Health Sciences* 2009; 16(2): 25-27.
- 274 4. Verwoerd CDA, Verwoerd-Verhoef HL. Rhinosurgery in children: developmental and  
275 surgical aspects. In: Nolst-Trenité GL, editor. *Rhinoplasty: A Practical Guide to Functional*  
276 *and Aesthetic Surgery of the Nose*. 3 ed. Amsterdam, The Netherlands: Netherlands Kugler  
277 Publications BV publisher; 2005. - 201–208.
- 278 5. Schwartz JM. Nasal septal abscess. *Consultant*. 2007;5:47.
- 279 6. Walker R, Gardner L, Sindwani R. Fungal nasal septal abscess in the  
280 immunocompromised patient. *Otolaryngol Head Neck Surg*. 2007;136:506–507.
- 281 7. Sandel VHD, Davison SP. Three spontaneous occurrences of nasal septal abscess in  
282 patients with chronic asymptomatic HIV – the need for early intervention and reconstruction.  
283 *Ear Nose Throat J*. 2009;88:1058–1066.
- 284 8. Salam B, Camilleri A. Non-traumatic nasal septal abscess in an immunocompetent patient.  
285 *Rhinology*. 2009;47:476–477.
- 286 9. Adobamen PROC. Management of nasal septal abscess in Nigeria. *Niger J General Pract*.  
287 2011;9(2):28–30.
- 288 10. Toback S. Nasal septal haematoma in an 11-month – old infant: a case report and review  
289 of literature. *Pediatr Emerg Care*. 2003;19:265–267.
- 290 11. Menachem GrossRon Eliashar. Nasal septal haematoma with abscess: an unusual  
291 complication of nasal injury. *Injury Extra* January 2004, .35(1):1–2.
- 292 12. Alshaikh N, Lo S. Nasal septal abscess in children: from diagnosis to management and  
293 prevention. *Int J Pediatr Otorhinolaryngol*. 2011 . 75(6):737-44.
- 294 13. Dirk JM, Ivar CT, Gilbert JNT. Nasal Septal Abscess in Children  
295 Reconstruction With Autologous Cartilage Grafts on Polydioxanone Plate. *Arch Otolaryngol*  
296 *Head Neck Surg*. 2008;134(8):842-847.
- 297 14. Huang PH, Chiang YC, Yang TH, Chao PZ, Lee FP. Nasal septal abscess. *Otolaryngol*  
298 *Head Neck Surg*. 2006 -135(2):335-6.
- 299 15. Savage RR, Valvich C. Hematoma of the nasal septum. *Pediatr Rev*. 2006 . 27(12):478-9.
- 300 16. Sayin I, Yazici ZM, Bozkurt E, Kayhan FT. Nasal septal haematoma and abscess in  
301 children. *J Craniofac Surg*. 2011;22(6):e17–e19.
- 302 17. Sanyaolu LN, Farmer SEJ, Cuddihy PJ. Nasal septal haematoma *BMJ (Online)* 2014;  
303 349.
- 304 18.Tien D.A., Krakovitz P., Anne S. Nasal septal abscess in association with pediatric acute  
305 rhinosinusitis. *International Journal of Pediatric Otorhinolaryngology*. 2016, .91:27–29.
- 306 19. LinI IH, Huang S. Nasal septal abscess complicated with acute sinusitis and facial  
307 cellulitis in a child. *Auris Nasus Larynx*. June 2007, .34(2):241–243.
- 308 20. Hassani R, Aderdour L, Maliki O, Boumed A, Elfakiri MM, Bouchoua F, Raji A. Nasal  
309 septal abscess complicating acute sinusitis in a child. *Archives de Pédiatrie* 2011, -18(1):15–  
310 17,
- 311 21. Yi C, Anjali S, Joseph H. Jr. Clinical Communications: Pediatric Spontaneous Nasal  
312 Septal Abscess Presenting as a Soft Tissue Mass in a Child*The Journal of Emergency*  
313 *Medicine*. 2017, .52(4):e129–e132.
- 314 22. Cheng LH, Kang BH. Nasal septal abscess and facial cellulitis caused by community-  
315 acquired methicillin-resistant *Staphylococcus aureus*. *The journal Laryngology & Ontology*.  
316 2010 124(9):1014-1016.
- 317 23. Khedim A, Ben Slimene S, Faïdi A, Mansour S, Bel Hadj Yahia S, Chtioui I, Ayari S,  
318 Chafai F, Maamouri M. A case of Nasal septum abscess. *Médecine et Maladies Infectieuses* ,  
319 2007, .37:S260–S263



- 320 24. Huang WH, Hung PK. Methicillin-resistant *Staphylococcus aureus* infections in acute  
321 rhinosinusitis. *Laryngoscope* 2006;116:288–91.(aetio)
- 322 25. George A, Smith WK, Kumar S and Pfeleiderer AG. Posterior nasal septal abscess in a  
323 healthy adult patient. *The Journal of Laryngology & Otology*. 2008; 122 (12) :1386-1388.
- 324 26. Pei-Hsuan H, Yuh-Chyun C, Fei-Peng L. Nasal septal abscess. *Otolaryngology - Head*  
325 *and Neck Surgery* 2006, -135(2):335–336.
- 326 27. Tan NWH, Turvey SE, Byrne AT, Ludemann JP, Kollmann TR. *Staphylococcus aureus*  
327 nasal septal abscess complicated by extradural abscess in an infant. 2012*Journal of*  
328 *Otolaryngology - Head and Neck Surgery*.