

# Plagiarism report

*By A O*

---

WORD COUNT

2886

TIME SUBMITTED

24-OCT-2018 03:33PM

PAPER ID

41411669

## Case study

ESTHETIC CONSIDERATIONS WHEN RESTORING SINGLE MAXILLARY CENTRAL  
INCISOR.*SHORT TITLE : REHABILITATION OF MAXILLARY CENTRAL INCISOR*

15

## SUMMARY:

The aim of this article is to illustrate the esthetic rehabilitation of discolored maxillary central incisor according to dominance principle based on establishing ideal proportions. The factors that can affect the esthetic value of dental supported crown in aesthetic zone are also discussed. These parameters include abutment color, ceramic thickness, the opacity of luting agent and gingival contours.

It describes 2 clinical situations of restoring discolored maxillary central incisors using all ceramic crowns. The patients presented with hidden smiles and were asking for improvement of their appearance. For both, clinical examination showed discrepancy between central incisors. The treatment plan included Lithium Disilicate Ceramic crowns. The opacity of the material was selected according to the abutment discoloration. An IPS Natural Die Material shade guide was also used. The restorations were bonded using a resin material. Finally, Pink/white aesthetic score PES/WES was applied to evaluate the esthetic result

## KEY WORDS:

Maxillary central incisor, Aesthetics, Glass ceramics, Luting agent, Abutment teeth color.

## INTRODUCTION

Restoring maxillary central incisor is a challenge at several levels. Scientists are in general agreement that its morphological features, which should be closely correlated with facial proportions, are influential factors in esthetic perception. Williams et al. demonstrated that the tooth shape is determined by facial form (1); But many other studies have found no correlation between facial outline and preferred tooth shape (2). As the central incisor should be the most dominant teeth displayed during the smile, several tools have been suggested for assessing its dominance such as shape, size, shade. The incisal edge position and proportions; They constitute starting points for aesthetic management of maxillary central incisor. (3, 4, 5)

The width of maxillary central incisor is expected to be proportional to its length which determines the width/Length ratio. According to literature, it was evaluated to be between 75 % and 78% (6). Recent studies demonstrated similarities between professionals and non professionals regarding the dominance of central incisor in dental esthetic perception (7). They, both, don't accept any reduction in an average central incisor length. However, a reduction of the width of lateral incisor about 0.5 mm can be unperceived. (6).

Establishing correct proportions of central incisor depends also, according to Spear & Kokich, on achieving ideal gingival levels especially when gingival contours are altered. In the same context, assessing the papilla level relatively to the overall crown length of maxillary central incisor is also considered as important as criteria previously mentioned. It is in fact an important step in the process of establishing a correct position of maxillary anterior teeth (8).

Restoring discolored abutment teeth in aesthetic zone poses a problem regarding the ceramic material selection. In such situations, dark abutments may negatively affect the esthetic value of a translucent ceramic crown conducting to a discoloration of the restoration especially in the cervical region. (9)

Material selection depends essentially on the degree of abutment color. With Dissilicate Ceramic crown, final esthetic result is, according to recent studies, interplaying between multiple parameters including ceramic thickness, substrate shade and luting agent color. (10)

13

Correct restoration colour match is a key requirement for patient satisfaction. It is, so, important to realise that the clinician need to have basic knowledge of light science. He is considered to be the responsible for creating a less confusing communication with the laboratory via some tools such as graphics, shade mapping cards, esthetic checklists and shade guide .(11 , 12 )

Using reliable indices for objective esthetic evaluation is a fundamental step in order to monitor the results over time.

Various indices such pink/white esthetic score (PES/WES) were proposed. According to litterature , this score is recommended to both soft and hard tissues evaluation in implant supported restorations. (13)

It includes 5 parameters and a score of 2,1 or 0 was assigned to each parameter.It's validity for natural tooth was discussed recently by authors(14).

#### CLINICAL DISCUSSION

This clinical presentation is dealing with two situations of rehabilitation of discoloured central incisors ; concerning 23 years old male and female patients with a chief complaint of poor aesthetics. They were asking for improvement of their smiles and bothered about the discrepancy between maxillary central incisors [Fig 1 and Fig 14].

In the first situation, Intra oral examination revealed a resin composite restoration on the concerned teeth with discolored margins. [Fig2].

3

Periodontal probing revealed a thick gingival biotype ; with gingival thickness of 2 mm and a sulcus depth of 2 mm. Altered gingival contours, leading to inadequate Width –to-height ratio and discrepancy between the 2 central incisors, were also detected . Radiological examination shows an adequate canal root treatment[Fig 3].

Photographs were taken using NIKON D7100 Camera . A comprehensive Esthetic evaluation was performed according to the asthetic cheklist of MAURO FRADENI ; Facial and dentolabial analysis and data were gathered [Fig 4; part1- part3 ].

The patient presents a convex profile with parallel commissural and bipupular lines. No harmonious smile line with squared teeth form and size discrepancy were noticed.

The treatment procedure started by a periodontal treatment consisting on periodontal scaling ; followed then by aesthetic crown lengthening and Lithium Dissilicate Ceramic crown.

Shade selection was performed before any procedure to avoid deshydration of the tooth. A color mapping card was performed referring to the right central incisor; It was divided into 4 to five areas starting by the apical third to the incisal [Fig 5].

The tooth was prepared for all ceramic crown with internal rounded shoulder at subgingival level edges with no sharp angles(Fig 6). the abutment teeth shade was, then, determined using the IPS Natural Die Material shade guide (IVOCCLAR VIVADENT).

The management of the provisional restoration, with precisely fitting and highly polished margins, is a fundamental step. Its role was essential for the healing process. It was performed using an acrylic resin and placed prior to gingivoplasty, margins were then modified according to new gingival levels (Fig 7).

Aesthetic crown lengthening using a gingivoplasty (Fig 8) . It contributes, first, to the correction of gingival asymmetries; Second, it leads to correct width –To Length ratio which was estimated around 76% according to measurements. Snow recommended , central incisor width 25% of intern canine distance(6).

As mentioned by authors, soft tissues healing is mostly completed after 8 weeks. Definitive restoration can be, then, successfully placed within 8–12 weeks (Fig 9,10,11).The impression step should be delayed until a subsequent appointment once soft tissue health has been re-established. (15, 16,17,18)

According to Mizrahi ; acrylic resin increased versatility in modification of shape and colour(11).

The frequency with which the provisional restoration is modified is related to the expected soft-tissue rebound (19).

A second indirect provisional restoration was manufactured by CAD-CAM technique using PMMA ( methymethacrylate based resin ) with high mechanical properties compared to conventional provisional restoration . It gives the technician Sufficient time to fabricate the ceramic crown (Fig 12) .

The shape of teeth was also verified at this stage. Central incisor can have 3 main shapes (square, tapered, triangular).

According to a recent systematic review which was dealing with lay preferences for dentogingiva esthetic parameters, it has been shown that tapered incisors are the most attractive in both male and female (20). The incisal edge position of the central incisor is of great importance in esthetic perception; it should be parallel to the bipupular plan. As mentioned by authors, vertical asymmetries as small as 0.6 were perceived as unacceptable according to Brazilian population (21).

In the second situation, left upper central incisor was endodontically treated and severely discolored. A comprehensive Esthetic assessment showed a reverse smile line, angular teeth form and inadequate Width-to-height ratio (Fig13-14). The abutment color was evaluated as ND9 according to shade guide previously used (Fig15).

Ceramic material selection was essentially depending on the abutment shade (ND9). High translucent material was, then, rejected in favor of opacious one that can mask the colored underlying substrate (22). Zirconia, in spite of its low translucency compared to Glass Ceramics, it should be avoided for its Milky white colour (23). Lithium Disilicate Ceramic, which was manufactured with different opacities, can be indicated. Medium or high opacity are recommended.

Final restorations were, then, performed using Lithium Disilicate Ceramic material (E max Cad Cam ceramic- Ivoclar Vivadent); Low opacity block was used for the first patient. Meanwhile, A medium opacity material was recommended for the second one. (Fig16).; it was associated with ND9 abutment color. The CAD/CAM technology (CEREC IN IAB) was performed. blocks were used for cores and then veneered later (24).

Characterization of central incisor surface texture is as important as matching the shade. Indeed, it is important to consider anatomical shape characterising the buccal surface of the central.

Regarding the contact area a slightly more apical contact, compared to the mesial one. three ridges and two concavities are created with a cervical area which is basically triangular; the

disto-incisal angle is rounded. Three ridges and two concavities were overall created to mimic a natural micro-geography aspect.

An aesthetic try in of the crown was made before crowns staining and glazing. This allows verification of the crown morphology and colour. At this stage, the incisal edge position, the midline, the axial inclination, the gingival margins and the papilla level have been verified. The thickness of ceramic material was also checked (Fig17).

As recommended by authors, a ceramic thickness of 2mm, which is sufficient to mitigate the dark aspect of underlying substrate. Less than 2mm, the luting agent should be selected of a medium opacity (25); .

The crowns were bonded using a dual cured resin luting cement (Variolink N, Ivoclar Vivadent, ref #642981 AN) according to the protocol described by Magne and Cascione (2006). First, The internal surface of the crown was thoroughly rinsed with water and cleaned with alcohol. Second, the ceramic restoration was etched during 60 to 90 sec using HFl (9%) acid; then fresh silane was applied for 60 sec. Third, the tooth surface was etched with 36% ortho phosphoric acid. Finally, bonding agent was applied. All cement should be removed before polymerisation and any residual cement remaining after polymerisation should be removed with a sickle scaler or a #12 scalpel blade.

Resin cement may cause visually inacceptable color changes with thin ceramic restorations; the color change effect decreases when the ceramic thickness increases. It concerns especially laminate veneers of 0.5 to 1 mm of thickness (25).

the final restorations were assessed using *White/ Pink esthetic ( WES/PES )* (Fig18, Fig 19). According to literature *WES /PES* index was essentially recommended to evaluate supported implant restorations, but its rightness for objective evaluation of single tooth crown has been confirmed by recent studies.

Significant differences between initial and final scores of the *WES/PES* were evident. For the first patient, The white score (PES) increased\_ from (1/10) to (8/10); However, the Pink score (PES(PES)) was improved\_ from (5 /10) to (9/10) [Fig20 ]. In the second situation, only whit esthetic score was applied for evaluation and it reached 8 /10 (Fig21).

## CONCLUSION

Restoring single central incisor, according to the principle of dominance, remains a challenge for prosthodontics ; for that they should respect some guidelines regarding the shade, proportions, size.

Shade selection, ceramic material choice and appropriate communication with laboratory technician are combined factors for success.

10  
9  
The underlying tooth structure has primary effect on the appearance of the definitive ceramic restration. To eliminate this undesirable effect factors such as ceramic thickness, ceramic shade and cement color should be considered.

## REFERENCES

1. Williams, J.L. A new classification of human tooth forms with reference to a new system of artificial teeth. *Dent Cosmos*. 1914; 56:627–628.
2. Kurt M. Anderson, Rolf G, Behrents, Thomas McKinney, Peter H. Buschang. Tooth shape preferences in an esthetic smile. *Am J Orthod Dentofacial Orthop* 2005; 128:458-65?
3. Hasanreisoglu U, Berksun S, Aras K, Arslan I. An analysis of maxillary anterior teeth: facial and dental proportions. *J Prosthet Dent* 2005; 94:530-8.
4. Ishida Y, Fujimoto K, Higaki N, Goto T, Ichikawa T. End points and assessments in esthetic dental treatment.. *J Prosthodont Res*. 2015 Oct; 59(4):229-35.
5. Petropoulou A1, Pappa E, Pelekanos S. Esthetic considerations when replacing missing maxillary incisors with implants: a clinical report. *J Prosthet Dent* 2013; 109:140-144.
6. Snow S.R. Esthetic smile analysis of anterior tooth width: the golden percentage. *J Esthet Dent*. 1999; 11:177–84.
7. Shetty S, Pitti V, Satish Babu C L, Surendra Kumar G P, Jnanadev K R. To evaluate the validity of Recurring Esthetic Dental proportion in natural dentition. *J Conserv Dent* 2011; 14:314-7.

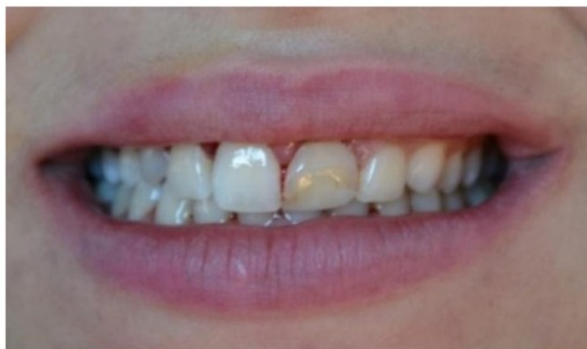

8. Frank M. Spear, Vincent G. Kokich. A Multidisciplinary Approach to Esthetic Dentistry. *Dent Clin N Am* 51 (2007) 487–505
9. Sedanur Turgut, Bora Bags, Elif Aydogan Ayaz. Achieving the desired colour in discoloured teeth, using leucite-based cad-cam laminate Systems. *Journal of dentistry* 42(2014) 68-74.
10. Yada Chaiyabutr, John C. Kois, Dene LeBeau, and Gary Nunokawa. Effect of abutment tooth color, cement color, and ceramic thickness on the resulting optical color of a CAD/CAM glass-ceramic lithium disilicate reinforced crown. *J Prosthet Dent* 2011; 105:83-90.
11. Basil Mizrahi. Restoration of a single central incisor with an all-ceramic crown: a case report. *International Dentistry SA* vol.10, no.3.
12. James F. Fondriest. Shade Matching a Single Maxillary Central Incisor. *Quintessence of Dental Technology* 2005.
13. Vidigal GM Jr, Groisman M, Clavijo VG, Barros Paulinelli Santos IG, Fischer RG. Evaluation of Pink and White Esthetic Scores for Immediately Placed and Provisionally Restored Implants in the Anterior Maxilla. *Int J Oral Maxillofac Implants*. 2017 May/Jun.
14. Alessandro Lanza, Fabrizio Di Francesco, Gennaro De Marco, Felice Femiano, and Angelo Ito. Clinical Application of the PES/WES Index on Natural Teeth: Case Report and Literature Review. *Case Rep Dent*. 2017
15. Claman, L.; Alfaro, M.A.; Mercados, A. An interdisciplinary approach for improved esthetic results in anterior maxilla. *J. Prosth. Dent*. 2003, 89, 1–5.
16. Fletcher, P. Biological rationale of aesthetic crown lengthening using innovative proportion gauge. *Int. J. Periodontics Restor. Dent*. 2011, 31, 523–532.
17. Malbaker, A.M. Gingival retraction—Techniques and materials: A review. *Pak. Oral Dent. J*. 2010, 30, 545–551.

18. Huynh, G. Surgical crown lengthening of the clinical crown: A periodontal concept for reconstructive dentistry. *Periodontology* 2007, 3, 193–201.
19. Calandriello M, Carnevale G, Ricci G. *Parodontologia*. Bologna: Martina Press, 1980.
20. Del Monte S, Afrashtehfar K, Emami E, Abi Nader S, Tamimi F. Lay preferences for dentogingival esthetic parameters: A systematic review. *J Prosthet Dent*. 2017 Dec; 118(6):717-724.
21. Andre Wilson; Machado; Won Moon; Luiz Gonzaga and Gandini Jr. Influence of maxillary incisor edge asymmetries on the perception of smile esthetics among orthodontists and laypersons. *American Journal of Orthodontics and Dentofacial Orthopedics* Volume 143, Issue 5, May 2013, Pages 658-664.
22. Luke S. Kahng. Material Selection and shade matching for a single Central incisor. *The journal of cosmetic dentistry* 2006; Vol 22; N 1:80-86.
23. Renato Abdalla Prata, Vinicus Pires d'Oliveira. Effect of try in paste removal method on bond strength to lithium disilicate ceramic. *Journal of dentistry* 2011, 39; 863-870.
24. Sedanur Turgut, Bora Bags, Elif Aydogan Ayaz. Achieving the desired colour in discoloured teeth, using leucite-based cad-cam laminate Systems. *Journal of dentistry* 42 (2014) 68-74.
25. Sedanur Turgut, Bora Bagis. Effect of resin cement and ceramic thickness on final color and laminate veneers: An in vitro study. *Journal of prosthetic dentistry* 2013; 109:179-186.

UNDER PEER REVIEW

FIGURES



**1**  
Fig 1: Preoperative view of the patient's natural smile

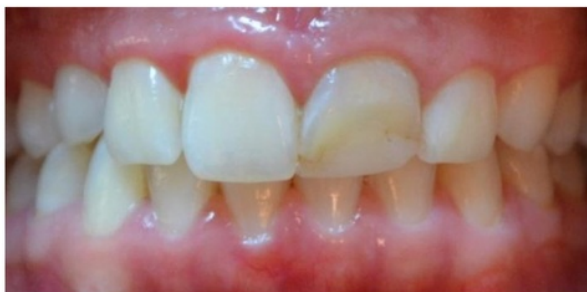

Fig 2: Retracted preoperative full-mouth view showing discoloured margins of resin

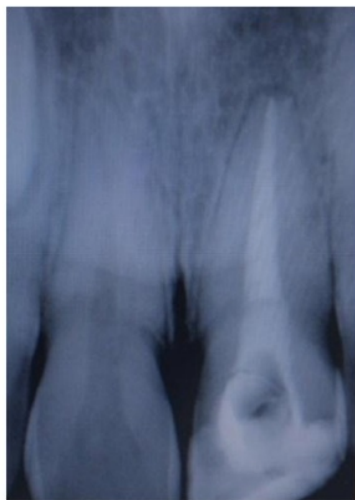

Fig 3 : Radiological examination

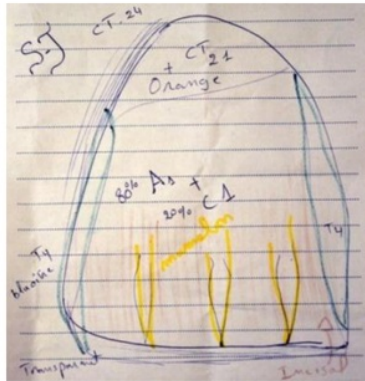

Fig 5: Color mapping schema

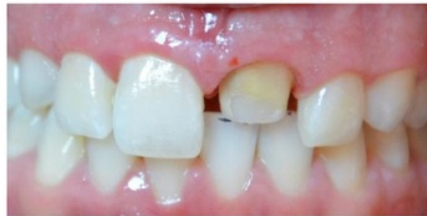

Fig 6 : Abutment tooth after healing period : tooth preparation

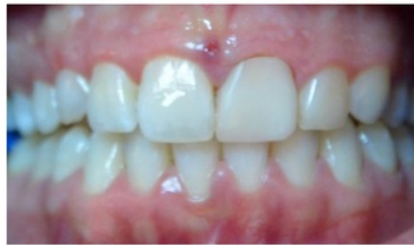
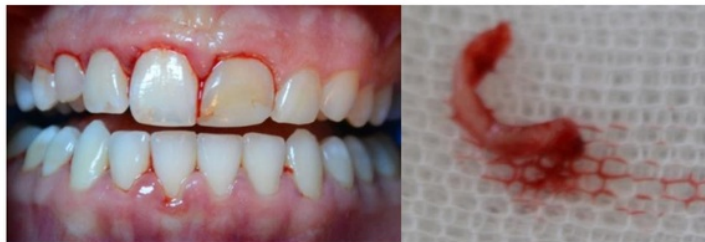
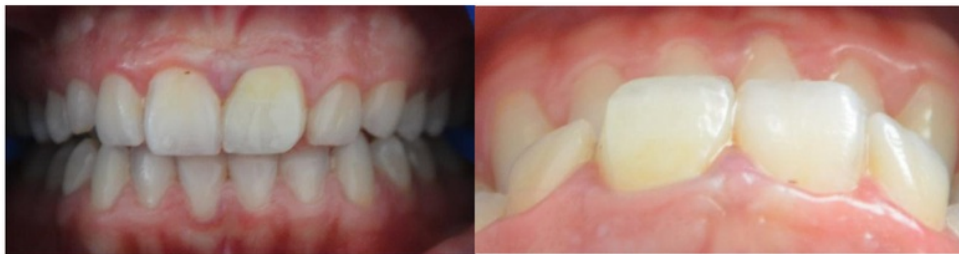Fig 7 : Provisional restoration placed immediately after crown lengthening using acrylic resin



A

B

Fig 8 (A,B): Crown lengthening [gingivoplasty]



A

B

Fig 9 (A,B) : <sup>1</sup> Retracted close-up postoperative view of the maxillary anterior restoration

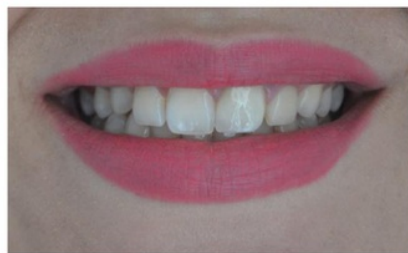

Fig 10: Facial <sup>1</sup> postoperative view of the patient's natural smile

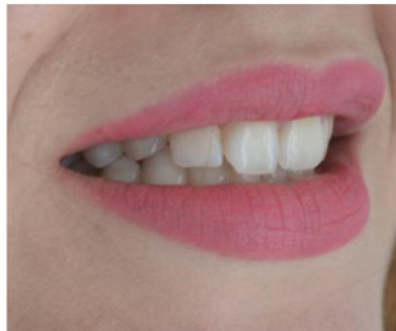

Fig 11: Right <sup>1</sup> lateral postoperative view of the patient in natural smile

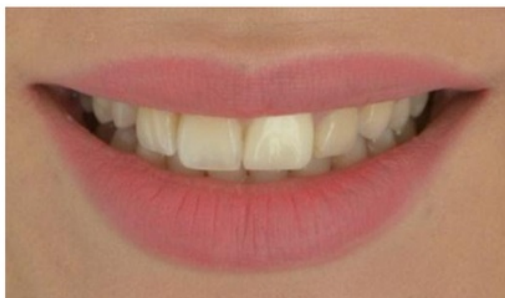
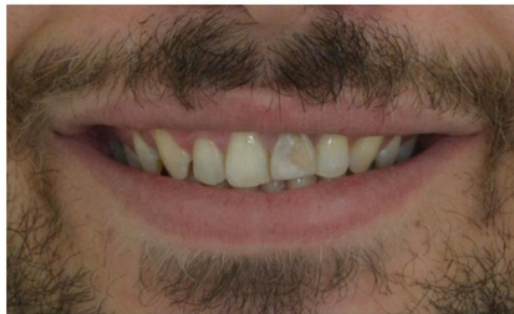
Fig12 : CAD/CAM provisional restoration



**1**  
Fig 13: Preoperative view of the patient's natural smile.

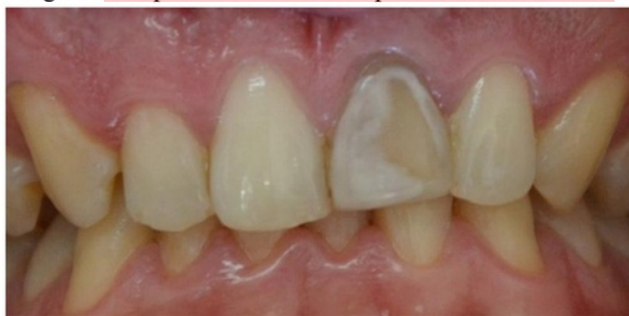

Fig 14: Retracted close-up preoperative view.

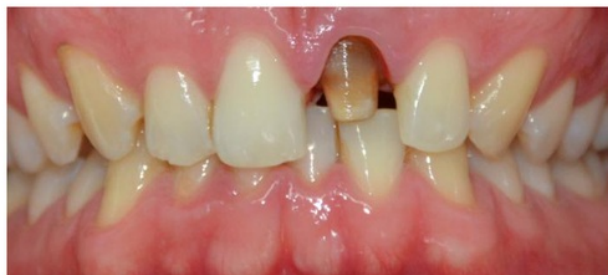

Fig15: Discolored abutment teeth; ND9



Fig16 : Medium opacity ceramic material

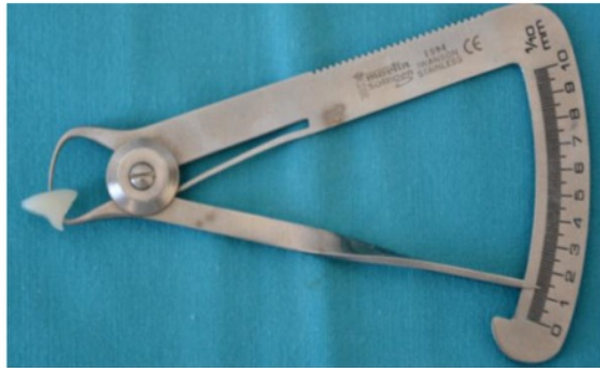

Fig17: ceramic thickness of the final restoration

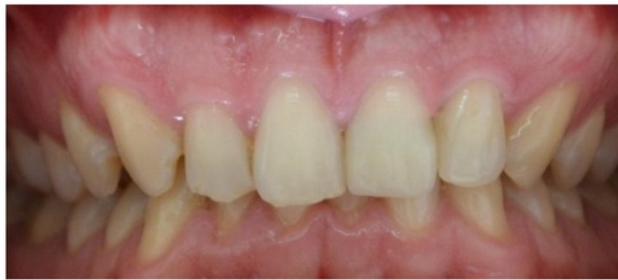

Fig18: <sup>1</sup> Retracted close-up postoperative view of the maxillary anterior restoration.

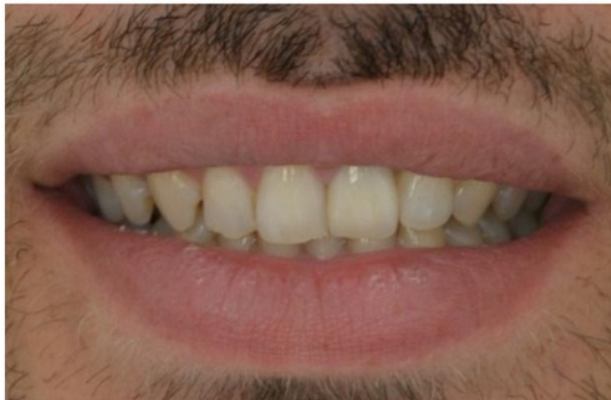

Fig 19: <sup>1</sup> Facial postoperative view of the patient's natural smile



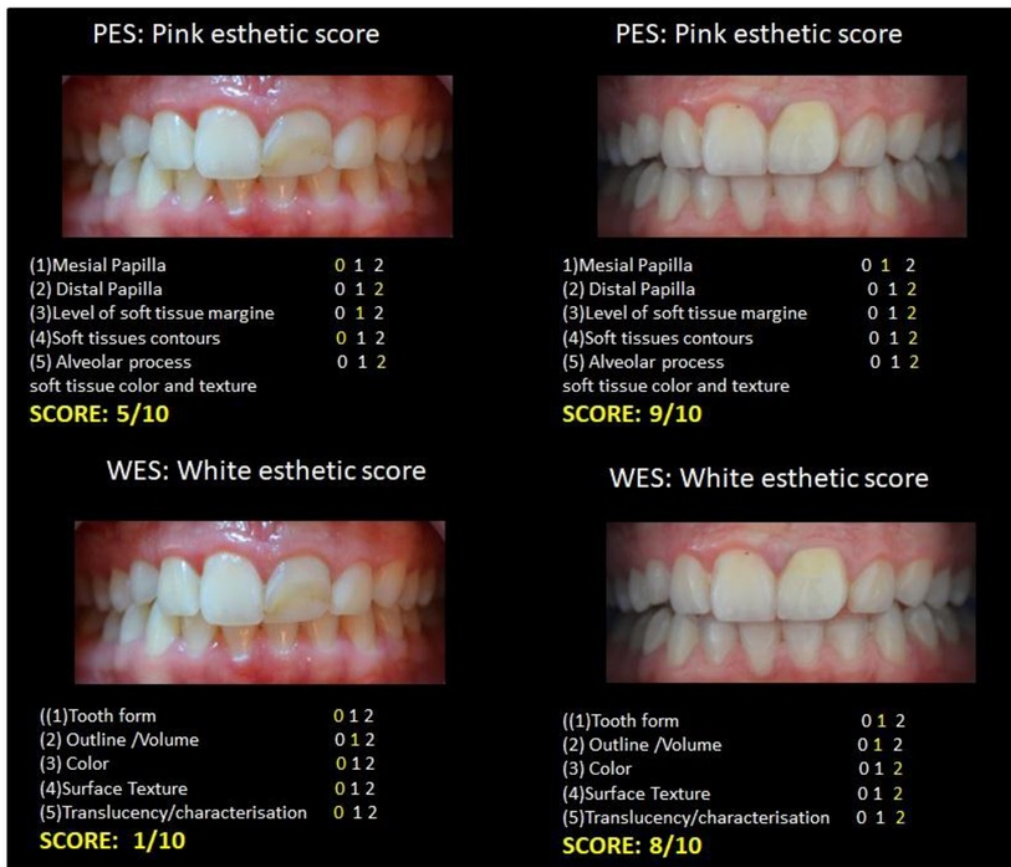


Fig 20 : Initial WES/PES Versus Final WES/PES

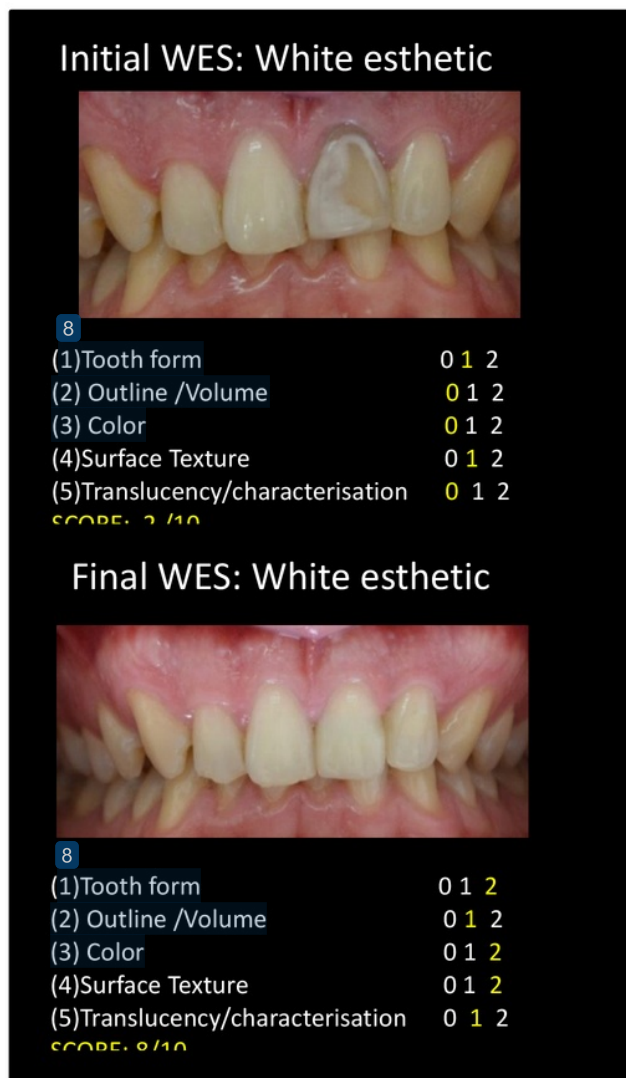

Fig 21 : Initial WES versus Final WES

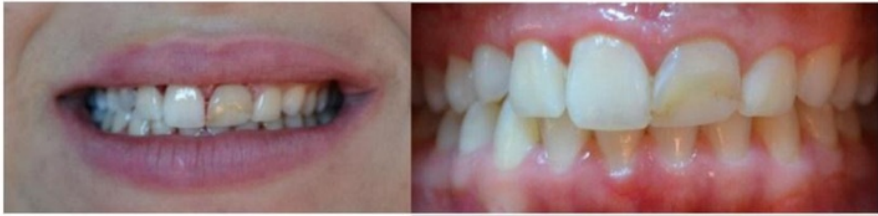# ESTHETIC CHECKLIST

1 / 4

 MAURO FRADEANI

Examiner  Date 14 / 04 / 2018

Patient  Age 23 years



PATIENT'S PHOTOGRAPH PATIENT'S PHOTOGRAPH

**Esthetic self-evaluation** \_\_\_\_\_

- Unsatisfied with , the shade and the shape of the upper left central incisor
- \_\_\_\_\_


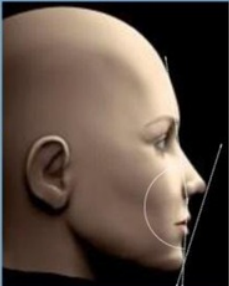
**Patient's requests and expectations** \_\_\_\_\_

- Esthetic improvement of the smile
- \_\_\_\_\_

Preferences  White and aligned teeth  Teeth with slight irregularities

Past records: Smile photo  Yes  No Study casts  Yes  No Radiographs  Yes  No

### FACIAL ANALYSIS

	<b>Interpupillary line vs horizon</b>			<b>Profile</b>		
	Parallel <input checked="" type="checkbox"/>	Slanted <input type="checkbox"/> Rt _____ <input type="checkbox"/> Lt _____		<input type="checkbox"/> Normal	<input checked="" type="checkbox"/> Convex	
	<b>Commissural line vs horizon</b>			<input type="checkbox"/> Concave	<b>E-line</b>	
Parallel <input checked="" type="checkbox"/>		Slanted <input type="checkbox"/> Rt _____ <input type="checkbox"/> Lt _____	<input type="checkbox"/> Max _____ mm <input type="checkbox"/> Mand _____ mm		<b>Lips</b>	
<b>Facial midline</b>		Centered <input type="checkbox"/>	Deviated <input checked="" type="checkbox"/> Rt 02 <input type="checkbox"/> Lt _____	<input checked="" type="checkbox"/> Thick		
				<input type="checkbox"/> Medium		
				<input type="checkbox"/> Thin		

Notes \_\_\_\_\_

\_\_\_\_\_

Copyright © by Quintessence Publishing Co, Inc




Fig 4: Aesthetic checklist (Part 1) Dr. MauroFradeani

/4

### DENTOLABIAL ANALYSIS

AT REST

**TOOTH EXPOSURE AT REST** 4






Indicate  **A**  **B**  **C** Max 05 \_\_\_\_\_ mm  
Mand 01 \_\_\_\_\_ mm


---

SMILE


**INCISAL CURVE vs LOWER LIP** 4




Convex




Flat




Reverse



Contacting  
 Rt  
 Lt




Not contacting  
Rt \_\_\_\_\_ mm  
Lt \_\_\_\_\_ mm




Covering  
Rt \_\_\_\_\_ mm  
Lt \_\_\_\_\_ mm


**SMILE LINE** 4



Average




Low




High  
Gingival exposure  
Rt \_\_\_\_\_ mm  
Lt \_\_\_\_\_ mm


**SMILE WIDTH (NO. OF TEETH VISIBLE)** 4



6-8




10




12-14


**LABIAL CORRIDOR** 4



Normal




Wide  
Rt \_\_\_\_\_ mm  
Lt \_\_\_\_\_ mm




Absent


**UPPER INTERINCISAL LINE vs MIDLINE** 4



Coincident




Deviated Rt  
\_\_\_\_\_ mm




Deviated Lt  
\_\_\_\_\_ mm


**OCCUSAL PLANE vs COMMISSURAL LINE/HORIZON** 4



Parallel



Slanted Rt  
\_\_\_\_\_ mm



Slanted Lt  
\_\_\_\_\_ mm

Indicate by tooth number current situation; mark deviation (in mm) from ideal: + (if too long), -- (if too short)

16	15	14	13	12	11	21	22	23	24	25	26
46	45	44	43	42	41	31	32	33	34	35	36

Fig 4: Aesthetic checklist (Part 2) M.Fradeani

Table of esthetic changes (natural and/or iatrogenic) that have occurred over the years, by tooth number

E								D								E	
18	17	16	15	14	13	12	11	21	2	23	24	25	26	2	28		
48	47	46	45	44	43	42	41	31	3	33	34	35	36	3	38		
M																M	

INDICATE:  $\Rightarrow$  Restoration, X = Missing, A = Abraded, D = Dyschromic, E = Extruded, F = Fractured, R = Rotated

**MAXILLARY vs MANDIBULAR INTERINCISAL LINE**

Coincident
  Deviated Rt \_\_\_\_\_ mm
  Deviated Lt \_\_\_\_\_ mm

**TOOTH TYPE**

Ovoid
  Tapering
  Square

**TEXTURE**

**Mac**  No  Slight  Pronounced  
**o**  No  Slight  Pronounced

**MAXILLARY CENTRAL INCISORS: SHAPE, CONTOUR, AND PROPORTION**

W/H ratio 11	21 75%	Profile 11	21
	85%	<input checked="" type="checkbox"/> Normal	<input type="checkbox"/> Buccal <input checked="" type="checkbox"/> Lingual

**OCCUSAL RELATIONSHIP**

**Dental Class**  I  II  III  
**Overbite** 02 mm  
**Overjet** \_\_\_\_\_ mm  
**Interarch relationship**  MIP  CO-CR  
**Incisal guidance**  Yes  No **Canine guidance** Rt  Yes  No Lt  Yes  No

<b>TOOTH ANALYSIS</b>	<p><b>CONTOUR</b></p> <input type="checkbox"/> Normal <input checked="" type="checkbox"/> Abnormal <p><b>PROPORTION</b></p> <input type="checkbox"/> Normal <input checked="" type="checkbox"/> Abnormal <p><b>INTERINCISAL ANGLES</b></p> <input type="checkbox"/> Normal <input checked="" type="checkbox"/> Abnormal <p><b>TOOTH AXES</b></p> <input checked="" type="checkbox"/> Normal <input type="checkbox"/> Abnormal <p><b>TOOTH ARRANGEMENT</b></p> <input checked="" type="checkbox"/> Regular <input type="checkbox"/> Crowded <input type="checkbox"/> Diastemata	<p>MARK ANY IRREGULARITIES ON DRAWING</p>	<p><b>GINGIVAL MARGINS</b></p> <input type="checkbox"/> Symmetric <input checked="" type="checkbox"/> Asymmetric <p><b>ZENITHS</b></p> <input type="checkbox"/> Regular <input checked="" type="checkbox"/> Irregular <p><b>PAPILLAE</b></p> <input checked="" type="checkbox"/> Present <input type="checkbox"/> Absent <p><b>BIOTYPE</b></p> <input type="checkbox"/> Thick <input checked="" type="checkbox"/> Thin <p><b>ALTERATIONS</b></p> <input checked="" type="checkbox"/> Gingival inflammation <input checked="" type="checkbox"/> Hypertrophy <input type="checkbox"/> Recession <p><b>EDENTULOUS RIDGES</b></p> <input type="checkbox"/> Normal <input type="checkbox"/> Deformed	<b>GINGIVAL ANALYSIS</b>
-----------------------	--	---	---	--------------------------

Fig 4: Aesthetic checklist (Part 3) ; M.Fradeani

# Plagiarism report

## ORIGINALITY REPORT

20%

SIMILARITY INDEX

### PRIMARY SOURCES

1	<a href="http://www.dentistrytoday.com">www.dentistrytoday.com</a> Internet	90 words — 4%
2	<a href="http://www.moderndentistrymedia.com">www.moderndentistrymedia.com</a> Internet	86 words — 4%
3	<a href="http://www.mdpi.com">www.mdpi.com</a> Internet	38 words — 2%
4	<a href="http://www.digitalsmiledesign.com">www.digitalsmiledesign.com</a> Internet	30 words — 1%
5	<a href="http://hal.archives-ouvertes.fr">hal.archives-ouvertes.fr</a> Internet	26 words — 1%
6	Stefano Del Monte, Kelvin I. Afrashtehfar, Elham Emami, Samer Abi Nader, Faleh Tamimi. "Lay preferences for dentogingival esthetic parameters: A systematic review", <i>The Journal of Prosthetic Dentistry</i> , 2017 Crossref	20 words — 1%
7	Matteo Marzadori, Martina Stefanini, Matteo Sangiorgi, Ilham Mounssif, Carlo Monaco, Giovanni Zucchelli. "Crown lengthening and restorative procedures in the esthetic zone", <i>Periodontology 2000</i> , 2018 Crossref	17 words — 1%
8	Stefan Paul. "Immediate supracrestal implant placement with immediate temporization in the anterior dentition: a retrospective study of 31 implants in 26 patients with up to 5.5-years follow-up", <i>Clinical Oral Implants Research</i> , 03/2012 Crossref	16 words — 1%

- 
- 9 [www.dt.mahidol.ac.th](http://www.dt.mahidol.ac.th) 16 words — 1%  
Internet
- 
- 10 Shogo Yagawa, Futoshi Komine, Ryosuke Fushiki, Kei Kubochi, Fumiaki Kimura, Hideo Matsumura. "Effect of priming agents on shear bond strengths of resin-based luting agents to a translucent zirconia material", *Journal of Prosthodontic Research*, 2018 14 words — 1%  
Crossref
- 
- 11 Anderson, K.M.. "Tooth shape preferences in an esthetic smile", *American Journal of Orthodontics & Dentofacial Orthopedics*, 2005 12 words — 1%  
Crossref
- 
- 12 [www.scilit.net](http://www.scilit.net) 10 words — < 1%  
Internet
- 
- 13 Jay D. Matani, Mohit G. Kheur, Tabrez A. Lakha, Vinay Jain. "Replicating a discolored tooth preparation: A technique for effective laboratory communication", *The Journal of Prosthetic Dentistry*, 2018 10 words — < 1%  
Crossref
- 
- 14 Doğu Ömür Dede, Gözlem Ceylan, Burak Yılmaz. "Effect of brand and shade of resin cements on the final color of lithium disilicate ceramic", *The Journal of Prosthetic Dentistry*, 2017 9 words — < 1%  
Crossref
- 
- 15 Flávia cracel-Nogueira, Teresa Pinho. "Assessment of the perception of smile esthetics by laypersons, dental students and dental practitioners", *International Orthodontics*, 2013 9 words — < 1%  
Crossref
- 
- 16 João Malta Barbosa, Nick Tovar, Pablo A. Tuesta, Ronaldo Hirata et al. "Scan-layered reconstructions: A pilot study of a nondestructive dental histoanatomical analysis method and digital workflow to create restorations driven by natural dentin and enamel morphology", *Journal of Esthetic and* 8 words — < 1%

---

17	<a href="http://preview-progressinorthodontics.springeropen.com">preview-progressinorthodontics.springeropen.com</a> Internet	8 words — < 1%
18	<a href="http://www.mysciencework.com">www.mysciencework.com</a> Internet	8 words — < 1%
19	<a href="http://www.nature.com">www.nature.com</a> Internet	8 words — < 1%
20	Frank M. Spear, Vincent G. Kokich. "A Multidisciplinary Approach to Esthetic Dentistry", <i>Dental Clinics of North America</i> , 2007 Crossref	7 words — < 1%
21	LexisNexis Publications	6 words — < 1%
22	Ji-Eun Ku, Hong-So Yang, Kwi-Dug Yun. "A morphometric analysis of maxillary central incisor on the basis of facial appearance in Korea", <i>The Journal of Advanced Prosthodontics</i> , 2012 Crossref	6 words — < 1%

---

EXCLUDE QUOTES OFF

EXCLUDE MATCHES OFF

EXCLUDE BIBLIOGRAPHY ON