Case study

Surgical treatment of ruptured pseudoaneurysm of the descending thoracic aorta associated with Takayasu's arteritis A case report of a 9-year-old boy

ABSTRACT

Takayasu's arteritis (TA) is a chronic inflammatory disease of the aorta and its major branches. Aortic aneurysm is a severe complication of TA, with an estimated mortality rate of 50% in patients that undergo surgery for a rupture[1]. We herein reviewed the clinical, paraclinical and operation characteristics of a 9-year-old male patient, who had a ruptured pseudoaneurysm of the thoracic aorta due to TA, and was successfully treated by open emergency surgery with cardiopulmonary bypass support.

Key word: Takayasu's arteritis, thoracic pseudoaneurysms.

INTRODUCTION

Takayasu's arteritis (TA) is an idiopathic chronic vasculitis of large vessels and their main branches that rarely affects children. The inflammation results in varying degrees of stenosis, occlusion or dilation of the involved vessels. The aetiology and precise pathogenesis of TA remain unclear but much has been learnt about the disease since 1908, after the first report by Mikito Takayasu, a Japanese ophthalmologist [2]. Arterial stenosis was one of the most common lesions with about 90% presented in the TA patients that were mentioned in global literature. Aneurysms and pseudoaneurysm conditions were less common with an incidence of 25% [3]. However, they had high risk of rupture with high mortality rates of up to 50% [1]. We herein report a case of a 9-year-old male patient who underwent open repaired surgery for a ruptured thoracic pseudoaneurysm associated with Takayasu arteritis with cardiopulmonary bypass support.

CASE PRESENTATION

Past medical history

UNDER PEER REVIEW

A 9-year-old male patient, who had an unremarkable medical history, presented symptoms including fatigue, cough, mid-grade fever and persistent left chest pain radiating to his back. The symptoms lasted for one week before he was transferred to a local hospital due to a condition of hemoptysis. The plain chest X ray revealed an abnormal shadow on the middle of his left chest, laboratory examination showed an increase of white blood cells with 15 K/µL. The initial diagnosis was caseous pneumonia differentiated from pulmonary tuberculosis infection.

Four hours later, the patient presented a sudden onset of left chest pain, dyspnea and early signs of hypovolemic shock. A computer tomography with contrast was indicated immediately, the figures revealing a ruptured pseudoaneurysms of the descending thoracic aorta. After being get blood transfusion, the patient was transferred to Cho Ray Hospital 30 minutes later

Physical Findings

- Vital signs: Pulse rate: 130 beats per minute, body temperature 37 degrees C, respiratory rate 30 breaths per minute, blood pressure on left arm: 125/85 mmHg, right arm 120/90 mmHg, both of legs could not measure blood pressure, femoral pulse was absent.

- The patient was fatigued, with pallor skin.

- Examination of the chest revealed tachycardia, dullness and diminished breath sounds on the left side.

Laboratory data

Red blood cells count: 3.69 T/L, Haematocrite 28.3%, Hemoglobin 89 g/L, White blood cell count 16 G/L, Neutrophyle 78.7%, Platelet count 233 G/L, C-reactive protein 30.8mg/L, Erythrocyte sedimentation rate (ESR) rose to 44mm per hour and 84mm per 2 hours.

Imaging diagnosis

- **Chest x ray** : Large pleural effusion, the mediastinal structures were shifted mediastinal to the right (Figure 1)

UNDER PEER REVIEW

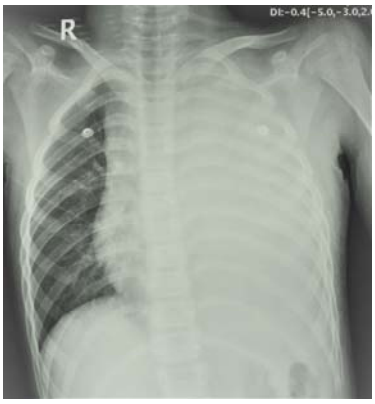

Figure 1: The plain chest x ray shows a large pleural effusion

- Chest CT scan with contrast (Figure 2): Descending thoracic aorta presented a pseudoaneurysm with 8 centimeters in diameter, thoracic aorta below the pseudoaneurysm presented a severe stenosis about 0.7 centimeters in diameter lasting for 3 centimeters, large haemothorax, superial mesenteric artery also revealed stenosis.

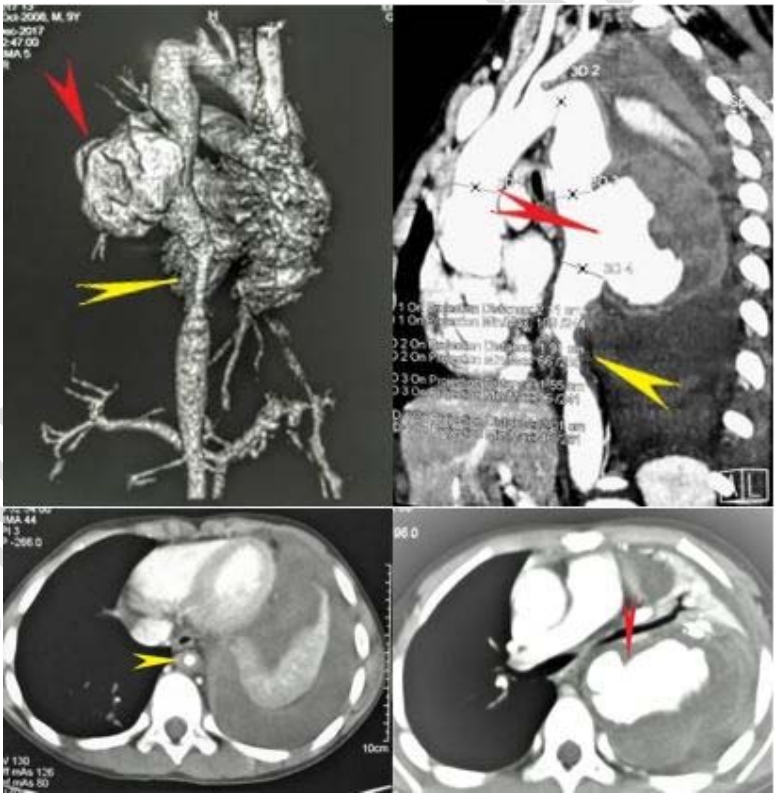

Figure 2: CT scan figures show a ruptured pseudoaneurysms with 8 centimeters in diameter (red arrow) and a 3cm stenosis (yellow arrow) of descending thoracic aorta

UNDER REVIEW

- Echography: Beside the pseudoaneuryms and stenosis of thoracic aorta shown by the CT scan, echography results found a moderate pericardial effusion, aneurysms of the left common carotid artery, atherosclerosis and mild stenosis of the iliac and femoral artery on both sides.

Treatment

Our surgical team decided that the patient was a candidate for emergency surgery. A sternotomy was performed, we exposed the entire aorta arch and descending aorta just above the pseudoaneurysm, set up circulation extracorporelle via the ascending aorta, right femoral artery, superior vena cava and inferior vena cava. The body temperature was reduced to 33 degrees C. After opening the pleural cavity, we saw a lot of blood and blood clots estimated at about 1.5 liters. The pseudoaneurysms at the descending thoracic aorta were about 12x10cm in size. The aorta just above the diaphragm had severe stenosis (Figure 3).

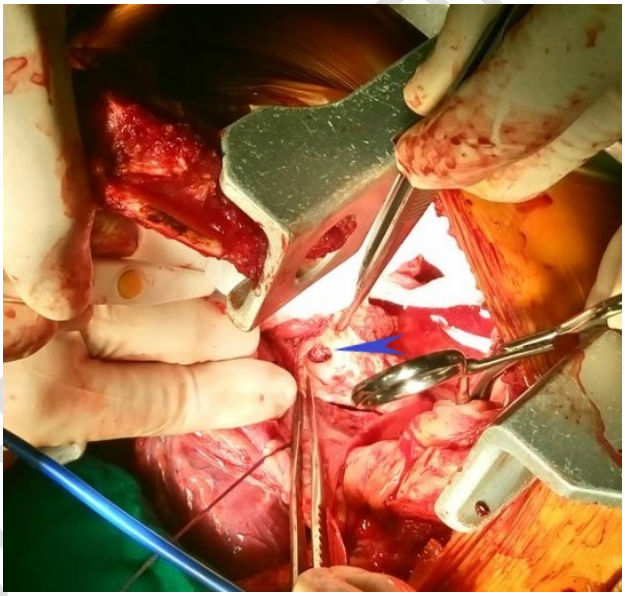

Figure 3: Severe stenosis in descending thoracic aorta just above the diaphragm (blue arrow)

We clamped the aorta above the neck of the pseudoaneurysms as well as below the stenosis position. A Dacron graft was used to repair the aorta (Figure 4). The aortic cross-clamping time was 45 minutes, cardiopulmonary bypass time was 120 minutes.

UNDER REVIEW

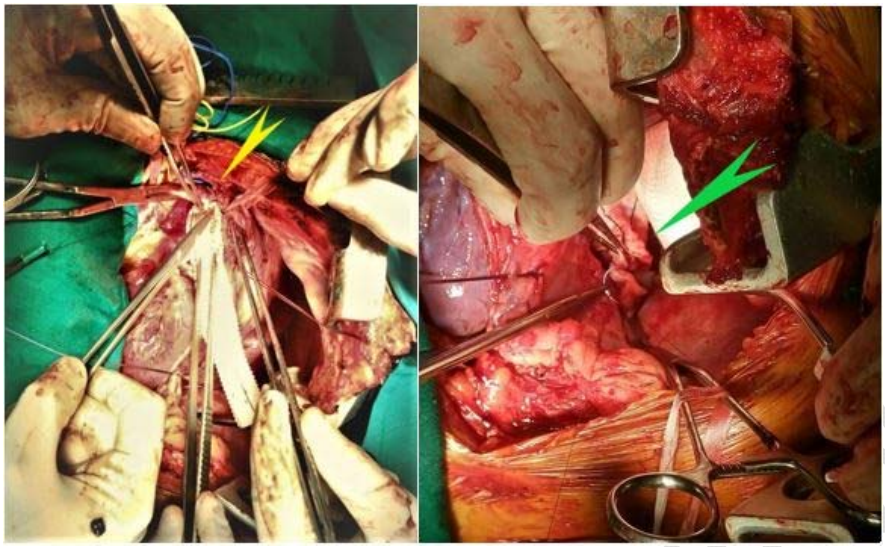

Figure 4: Making a connection between the upper (yellow arrow) and lower part (green arrow) of the descending thoracic aorta and Dacron graph

The postoperative course was uneventful, the patient was treated by antibiotic, pain relief and corticoid therapy. The histopathological figures showed necrosis of the aorta wall and the infiltration of lymphocytes, plasmacytes and neutrophils. We indicated a CT scan in the postoperative period. The figures of the CT scan confirmed that the entire descending thoracic aorta was repaired successfully (Figure 5). The postoperative plain chest x-ray showed a shadow in the left side, which was the remnants of pseudoaneurysm cover, the left lung had expanded completely (Figure 5) .

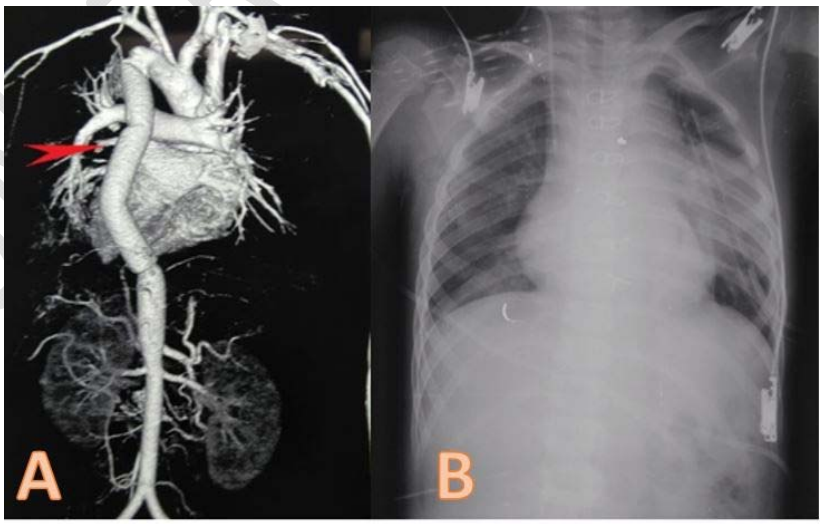

Figure 5: CT scan confirmed that the entire descending thoracic aorta was replaced by Dacron tube (A), Plain chest x ray showed a shadow which was the remnants of the pseudoaneurysm cover (B).

UNDER PEER REVIEW

The patient was discharged on the 16th day after operation. He was transferred to a pediatric hospital to follow up and take care of the Takayasu arteritis condition.

DISCUSSION

Takayasu's arteritis (TA) is a large vessel systemic granulomatous vasculitis primarily involving the aorta and its major branches. It is reported all around the world. However, it is more common in south-east Asia, Africa and South America [4]. This disease is the most common cause of renohypertension in Asian children [5]. According to a systemic review in Japan during the period from 1982 to 1984, there were 2600 patients with TA [6]. In United States of America, the incidence was estimated at 2.6 per million population/year [7].

Takayasu's arteritis is practically reported in young adults in the second and third decades of life. The onset of symptoms may be earlier, including in childhood, but rarely in infancy. The female:male ratio was about 9:1 in some reports from Japan [6]. In Vietnam, according to a report of Ho Chi Minh city Children's Hospital, the female:male ratio was about 1.63:1 [8]. The exact pathogenesis of TA has been unclear, cell-mediated immunity has an important role in the mechanisms of arteritis. Genetic factor, which relates to TA, has been extensively studied. The research from Japan showed that HLA B-52 and DR-2 are associated with TA, Korea also had a report of HLA B-52 and B-5 association [9]. Some recent studies show that there was a close association between Tuberculosis and Takayasu. Furthermore, the epidemiological regions of Tuberculosis and Takayasu were similar. In Vietnam, a study conducted by the Children's Hospital in 2003 found that 23.8% of Takayasu patients had Tuberculosis disease or their family had Tuberculosis [8].

To make a diagnosis of Takayasu's arteritis on this patient, we based it on clinical criteria. Several criteria of differing sensitivity and specificity have been offered. We based on the *European League Against Rheumatism (EULAR)/Pediatric Rheumatology International Trials Organization (PRINTO)/Pediatric Rheumatology European Society (PRES)* validated the TA criteria for childhood [10] (Table 1). Diagnosis requires the presence of mandatory criteria and at least one additional criteria. On this patient, the figures of the CT scan showed narrowing of the aorta, iliac and femoral artery, it also had a pseudoaneurysm. We also had 3 of 5 additional features, those were (1) lost peripheral artery pulse (femoral pulse was absent) ,(2) discrepancy of four limb systolic blood pressure >10 mmHg in any limb (blood pressure on left arm: 125/85 mmHg, right arm 120/90 mmHg, while both of legs could not

UNDER PEER REVIEW

measure blood pressure) and (5) Erythrocyte sedimentation rate >20 mm per hour or C-reactive protein above normal (ESR 44mm per hour and CRP 30.8mg/L).

Table 1:European League Against Rheumatism (EULAR)/Pediatric Rheumatology International Trials Organization (PRINTO)/ Pediatric Rheumatology European Society (PRES) classification criteria of Takayasu's arteritis and additional criteria

Mandatory criteria Angiographic abnormality	Angiography (conventional, CT, and MRI) of the the aorta, its main branches or pulmonary arteries	Aneurysm/ dilatation, narrowing, occlusion, or thickened arterial wall, not due to any other causes
Additinal criteria (need one of five)	1. Pulse deficit or claudication	- Lost/decreased/unequal peripheral artery pulse - Symptoms of claudication: focal muscle pain induced by physical activity
	2. Blood pressure discrepancy	Discrepancy of four limb systolic blood pressure >10 mmHg in any limb
	3. Bruits	Audible murmurs or palpable thrills over large arteries
	4. Hypertension	Systolic/diastolic blood pressure >95th centile for height
	5. Acute phase reactant	Erythrocyte sedimentation rate >20 mm per hour or C-reactive protein above normal.

The diagnosis is difficult to make during the acute early phase, because patients show symptoms of systemic inflammation such as fever, fatigue, headache, muscle pain, arthralgia, and weight loss. The laboratory findings such as erythrocyte sedimentation rate and C-reactive protein show an increase. All of them are nonspecific. Therefore, the disease often goes unrecognised in this phase. This patient presented symptoms including fatigue, cough, mid-grade fever and persistent left chest pain radiating to his back. In addition, the plain chest x-ray showed a shadow on the left side of the thorax. All of the clinical findings were similar to a pneumonia or pulmonary Tuberculosis. That was the reason why the local hospital made the mistake on initial diagnosis. Until the boy had the symptom of pseudoaneurysm rupture with violent chest pain, hypovolemic shock, the CT scan had been indicated to confirm.

UNDER PEER REVIEW

Aortic aneurysm, as well as pseudoaneurysm, are a potentially life-threatening risk factor, with the estimated mortality to be 80% and 50% in patients who arrive at the hospital and who undergo surgery for a rupture, respectively. The progress of ruptured pseudoaneurysm was extremely quick because of the presence of stenosis just below which made high pressure on the wall of pseudoaneurysm.

After performing open repair of the thoracic aorta, postoperative steroid therapy was a main point to control the degree of inflammation. The boy had many problems such as aneurysms of the left common carotid artery, atherosclerosis and mild stenosis of iliac and femoral artery on both sides. All of them need to be followed up continuously.

CONCLUSION

Takayasu's arteritis is a rare disease in children. To date, with the development of non-invasive diagnostic imaging tools, the final diagnosis had been made earlier. With the development of a new generation of immunosuppressive drugs combined with classical steroids as well as more advances in surgical technology and perioperative care, the prognosis of TA has improved. However, despite these developments, the management of TA in children still has many challenges because the diagnosis is still often late and currently there is no sensitive and specific gold standard for the monitoring of inflammatory disease. Treatment is essential to prevent the insidious course and vascular damage: stenosis, occlusive lesions, aneurysms with dangerous complications and high rate of mortality.

CONSENT AND ETHICAL APPROVAL

As per university standard guideline participant consent and ethical approval has been collected and preserved by the authors.

ABBREVIATIONS

TA: Takayasu's arteritis; CT scan: Computed Tomography scan, HLA: Human leukocyte antigens.

REFERENCE

1. Davis FM RD, Daugherty A: Mechanisms of aortic aneurysm formation: translating preclinical studies into clinical therapies. Heart 2014, 100:1498 - 1505.

UNDER PEER REVIEW

2. Takayasu.M: A case with unusual changes of the central vessel in the retina. Nippon Ganka Gakkai Zasshi 1908, 12:554-557.

3. Mason, Justin C: Takayasu arteritis—advances in diagnosis and management. Nat Rev Rheumatol 2010, 6:406-415.

4. Lande A BR, Rossi P, Passariello R, Castrucci A. : Takayasu's arteritis. A world-wide entity. NY State J Med 1976, 32:379–392.

5. Chugh KS SV: Takayasu's arteritis as a cause of renovascular hypertension in Asian countries. Am J nephrol 1992, 306:464-465.

6. Sekiguchi M SJ: An overview of Takayasu Arteritis. Heart Vessels 1992:6-10.

7. Hall S BW, Lie JT. : Takayasu arteritis. A study of 32 North American patients. Medicine (Baltimore) 1985, 64:89–99.

8. Thach Le Huy, Dong Vo Cong, Dung Do Van : Characteristics of Takayasu arteritis in Vietnamese children from 1998 to 2002. Journal of Medicine Ho Chi Minh City 2003, 7:112-118.

9. Weyand CM GJ: Medium- and large-vessel vasculitis. Engl J Med 2003, 2:160-169.

10. Ozen S PA, Iusan SM, et al. : Ankara 2008. Part II: final classification criteria.: EULAR/PRINTO/PRES criteria for Henoch-Schönlein purpura, childhood polyarteritis nodosa, childhood Wegener granulomatosis and childhood Takayasu arteritis. Ann Rheum Dis 2010, 69:798-806.

UNDER PEER REVIEW