

Skull Parosteal Lipoma - Hard Lump on the Head of Bony Origin?

ABSTRACT

Aims: A skull parosteal lipoma is extremely rare with only 4 cases reported in the recent literature. This is in contrast to other parosteal lipomas that occur more commonly in the long bones of the upper and lower limbs. In this report, we present the fifth case of skull parosteal lipoma according to our comprehensive literature review.

Case presentation: A 67-year old gentleman with well controlled hypertension presents with a painless right frontal swelling of three year's duration. He recalls prior blunt injury to the right frontal area 6 years ago. Magnetic resonance (MR) imaging scan of the head was performed and demonstrated a well-circumscribed subperiosteal lesion in an otherwise asymptomatic patient. With a diagnosis of a benign lesion that was asymptomatic, the patient was not offered surgery and the lesion has since remained stable.

Discussion: The aetiology of parosteal lipoma is unknown. Local trauma on long bones has been associated with subsequent parosteal lipoma several years later. In this patient, we suggest that there may be possible association with previous trauma. MR imaging can delineate the tissue layer of origin and demonstrate a lesion with the same attenuation value and intensity signal as adipose tissue.

Conclusion: A skull parosteal lipoma may be differentiated from other differentials with adequate physical examination and appropriate imaging technique. MR imaging has been shown to be useful to exclude other differentials such as an angular dermoid cyst. Surgical resection with wide excision margins may be performed to obtain a histopathological diagnosis.

Keywords: Benign osseous lesions, well-circumscribed bony prominence, reactive hyperostosis

1. INTRODUCTION

An osseous lipoma is a benign tumour composed mainly of mature adipose tissue with a bony component. It may be either intraosseous or juxtacortical depending on whether the lipoma arises within or on the surface of the bone [1]. In contrast, an osteolipoma is a very rare variant of lipoma that accounts for less than 1% of all the cases and is histologically a variant of lipoma that shows osseous metaplasia [2].

Parosteal lipoma is a benign soft tissue neoplasm composed of adipose tissue with an osseous component that occurs in close contiguity to the bone. They make up only 0.3% of lipomas [3]. It is the surface form of osseous lipoma, which is classified based on origin into intraosseous (arising within the bone) or juxtacortical (arising from the surface of the bone) lipoma [1].

The term "parosteal lipoma", is thought to be more accurate instead of "periosteal lipoma", as it indicates a lesion contiguous with the bone but not necessarily arising from the periosteum [4]. In contrast, a periosteal lipoma is strictly defined as a lipoma originating from the periosteum [5].

A skull parosteal lipoma arises from the cranium and is extremely rare with only 4 cases reported in the recent literature. This is in contrast to other parosteal lipomas that occur more commonly in the long bones of the upper and lower limbs. In this report, we present the fifth case of skull parosteal lipoma according to our comprehensive literature review.

2. CASE PRESENTATION

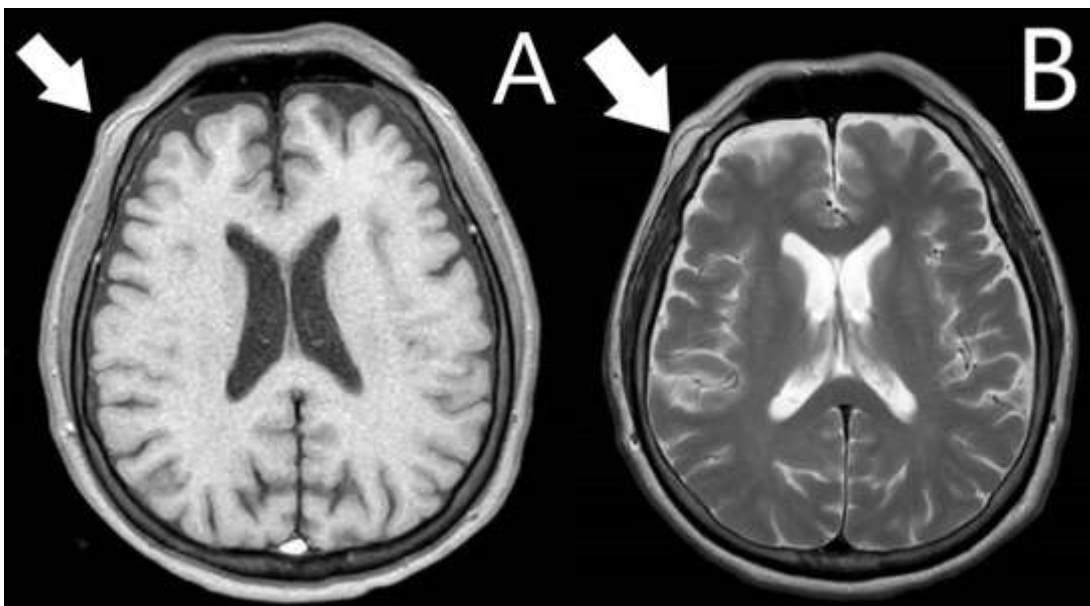
A 67-year old Chinese gentleman with well controlled hypertension presented with a right frontal swelling of 3 years' duration. The swelling has become more prominent but is painless and otherwise asymptomatic. He recalls prior head injury to his right frontal area 6 years ago. There were no constitutional symptoms or cervical lymphadenopathy.

Physical examination reveals a 2.5cm hemispherical swelling in the fronto-orbital area superolateral to the right orbit that is smooth and non-tender on palpation as shown in Fig. 1. It is hard, deep to the skin, and immobile. There is no overlying erythema, warmth or skin changes.

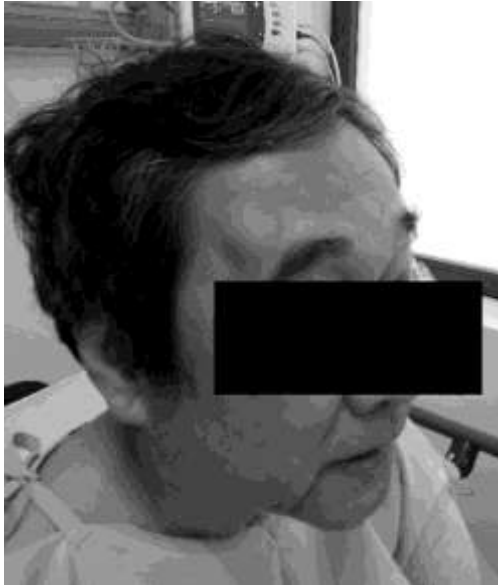

Fig. 1. Clinical image of the patient's forehead showing a visible swelling in the frontal area adjacent to the right eyebrow

In view of the above clinical findings, a magnetic resonance imaging scan was performed. Magnetic resonance (MR) imaging scan of the head, as shown in Fig. 2, demonstrates a well-circumscribed, non-infiltrative, 2cm subperiosteal lesion in the right frontotemporal region (white arrow) that is hyperintense on both T1- and T2-weighted sequences, with low intensity on a T1 fat suppression image. No diffusion restriction or enhancement is evident.



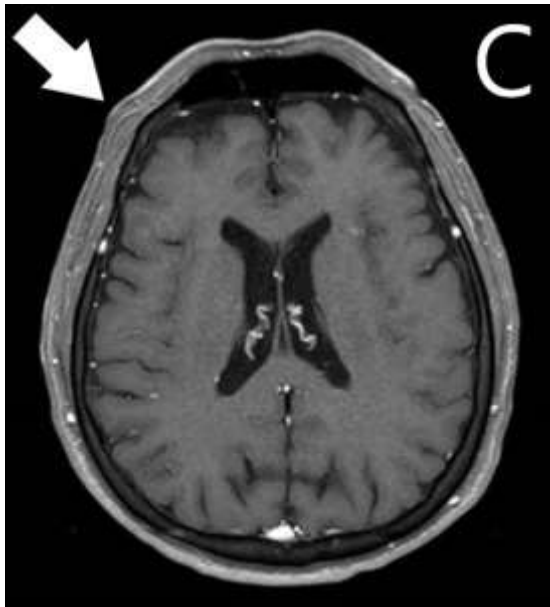


Fig. 2. MR image of the head demonstrating a subperiosteal mass (arrow) with high signal intensity on T1- (A) and T2-weighted images (B) and low intensity on T1 fat suppression image (C).

2.1 Clinical Course

With a radiological diagnosis of a benign lesion that was asymptomatic, the patient was not offered surgery and the lesion has remained stable for the past 18 months.

3. DISCUSSION

A skull parosteal lipoma is extremely rare with only 4 cases reported in the recent literature (Table 1). These were in the frontal [6, 7], temporal [8] and parieto-occipital regions [4]. This is in contrast to other parosteal lipomas that occur more commonly in the long bones of the upper and lower limbs [1].

Table 1. Summary of reported cases of skull parosteal lipomas

Case	Location	Authors (year) [ref]	Patient Age	Sex	Symptom	Therapy
1	Frontal	Current (2018)	67	Male	Nontender swelling	Conservative: lesion stable over past 18 months
2	Temporal	Dolzhansky et al. (2016) [8]	48	Male	Painful swelling	Surgery: subperiosteal dissection & segmental resection with removal of the parotid gland
3	Frontal	Morishita et al. (2015) [7]	5	Male	Nontender swelling	Surgery: dissection of lipoma and periosteum
4	Parieto-occipital	Murakami et al. (2014) [4]	50	Female	Nontender swelling	Surgery: wide resection with 2cm margin
5	Frontal	Cil et al. (2008) [6]	20	Male	Nontender swelling	Surgery: excision of mass with shaving of cortical bone

Patients with frontal parosteal lipomas are frequently asymptomatic and they present with a forehead swelling that causes a cosmetic problem as it becomes prominent as it grows in size. This is in contrast to other parosteal lipomas on the radius or femur which may present with localized swelling and pain [1].

The aetiology of parosteal lipoma is unknown but the pathogenesis may be common with soft tissue lipoma based on cytogenetic analysis [9]. However, we suggest that there may be possible association with previous trauma as seen in this patient and also that local trauma on long bones has been associated with subsequent parosteal lipoma several years later [10]. Parosteal lipomas seem to affect mainly adults aged over 40 years [10].

Initial investigation such as plain radiography may show the classic appearance of an exostosis-like bony prominence well-circumscribed by a radiolucent layer of fat [1, 8]. However, this may represent a broad differential diagnosis of other benign osseous lesions. Magnetic resonance imaging (MRI) and computed tomography (CT) can delineate the tissue layer of origin, and can also indicate that the lesion has attenuation values and signal intensity identical to that of adipose tissue [1, 3].

Parosteal lipoma can be classified into four variants of underlying ossification: type 1: no ossification, type 2: pedunculated exostosis, type 3: sessile exostosis, and type 4: patchy chondro-osseous modulation [11].

MRI can be used to differentiate skull parosteal lipoma from an angular dermoid cyst which also occurs at the frontal region adjacent to the eyebrow at the outer angle of the eye especially those tethered immobile ones where imaging can assess the depth and any intra-orbital extension [12].

Angular dermoid cyst occurs at the frontal region adjacent to the eyebrow at the outer angle of the eye, more frequently in the paediatric age group [12]. This is a congenital cyst deep to the skin that is benign, slow-growing and arises along the medial and lateral ends of the eyebrows due to developmental inclusion of epidermis along the bony sutures during embryonic development.

Angular dermoid cysts may fluctuate and are usually soft to cystic while skull parosteal lipomas appear bony hard on palpation because of the overlying reactive hyperostosis. They can also arise on the midline of the nose, and the midline of the neck and trunk [13]. As such, patients should be examined thoroughly for other lumps on the face and torso.

A long-standing skull parosteal lipoma may progress into the overlying skull cortex with reactive hyperostosis giving the impression of a well-differentiated liposarcoma on imaging [4]. In that instance, concordance between both radiological and histological data is essential.

If a parosteal lipoma can be diagnosed on preoperative imaging, resection of the lipoma along with shaving of the overlying reactive ossification is sufficient [6]. Some surgeons suggest that any periosteal involvement should be removed completely based on preoperative imaging with CT or MRI scans [9]. Surgical excision with wide resection margins should be done in those with suspicion of malignant transformation in order to obtain a histopathological diagnosis.

4. CONCLUSION

In conclusion, skull parosteal lipoma is rare and may be differentiated from other differentials with adequate physical examination and appropriate imaging technique. MR imaging is useful to exclude other differentials such as an angular dermoid cyst, and also to delineate any periosteal involvement. Complete resection with wide resection margins is recommended for symptomatic lesions where preoperative imaging suggests periosteal involvement.

CONSENT

All authors declare that written informed consent was obtained from the patient for publication of this case report and accompanying images.

ETHICAL APPROVAL

As per international standard or university standard written ethical permission has been collected and preserved by the authors.

REFERENCES

1. Kapukaya A, Subasi M, Dabak N, Ozkul E. *Osseous lipoma: eleven new cases and review of the literature*. Acta Orthop Belg, 2006. 72(5): p. 603-14.
2. Bajpai M, Kumar M, Agarwal D, Agrawal S, Gupta S, Kumar M. *Osteolipoma of the palate: An unusual presentation*. Natl J Maxillofac Surg 2014;5:250-1.
3. Murphey MD, Johnson DL, Bhatia PS, Neff JR, Rosenthal HG, Walker CW. *Parosteal lipoma: MR imaging characteristics*. AJR Am J Roentgenol, 1994. 162(1): p. 105-10.
4. Murakami M, Hirai M, Sakakibara T, Yamaki T, Kusuzaki K. *Skull parosteal lipoma with reactive hyperostosis: a case report*. Neurol Med Chir (Tokyo), 2014. 54(4): p. 314-6.
5. Aoki S, Kiyosawa T, Nakayama E, Inada C, Takabayashi Y, Sumi Y, et al. *Large Parosteal Lipoma without Periosteal Changes*. Plastic and Reconstructive Surgery Global Open, 2015. 3(1): p. e287.
6. Cil Y, Kocer NE, Yapici AK. *Frontal parosteal lipoma*. J Craniofac Surg, 2008. 19(4): p. 1122-5.
7. Morishita T, Toriyama K, Yagi S, Takanari K, Fujii M, Nishida Y, et al. *Frontal parosteal lipoma with thickening of diploic space*. JPRAS Open, 2015. 5: p. 19-23.
8. Dolzhansky OV, Paltseva EM, Bulanov DV, Fedorov DN. *[Parosteal osseous lipoma of the temporal bone concurrent with involvement of the parotid salivary gland]*. Arkh Patol, 2016. 78(5): p. 40-44.
9. Greco M, Mazzocchi M, Ribuffo D, Dessy LA, Scuderi N. *Parosteal lipoma. Report of 15 new cases and a review of the literature*. Ann Ital Chir, 2013. 84(2): p. 229-35.
10. Bispo Junior RZ, Guedes AV. *Parosteal lipoma of the femur with hyperostosis: case report and literature review*. Clinics (Sao Paulo), 2007. 62(5): p. 647-52.
11. Burt AM, Huang BK. *Imaging review of lipomatous musculoskeletal lesions*. SICOT-J, 2017. 3: p. 34.
12. Sathananthan N, Moseley IF, Rose GE, Wright JE. *The frequency and clinical significance of bone involvement in outer canthus dermoid cysts*. British Journal of Ophthalmology, 1993. 77(12): p. 789-794.
13. Turkyilmaz Z, Karabulut R, Bayazit YA, Sonmez K, Koybasioglu A, Yilmaz M, et al. *Congenital neck masses in children and their embryologic and clinical features*. B-ent, 2008. 4(1): p. 7-18.