

**Anatomical variation in the branching pattern of
musculocutaneous nerve & its clinical importance - A case
report:**

AUTHORS:

Suresh R Rao & Gangadhara Swamy

Department of Anatomy,
Subbaiah Institute of Medical Sciences and Research Centre,
Shimoga, Karnataka, India.

CORRESPONDING ADDRESS:

Dr. Suresh R Rao
Department of Anatomy
Subbaiah Institute of Medical Sciences and Research Centre,
Shimoga, Karnataka, India.

EMAIL: s4chavan@yahoo.co.in

Anatomical variation in the branching pattern of musculocutaneous nerve & its clinical importance - A case report:

Suresh R Rao & Gangadhara Swamy
Department of Anatomy
Subbaiah Institute of Medical Sciences and Research Centre,
Shimoga, Karnataka, India.

Abstract: The anatomical knowledge of the musculocutaneous nerve and its variations play an important role for the surgeons, due to the fact that one of the complications in many upper-limb surgical procedures involve injury to this nerve. During our routine dissection, we observed an anatomical variation of the musculocutaneous nerve taking origin from the lateral cord of the brachial plexus and after passing through the coracobrachialis muscle it then gave a communicating branch to the median nerve in the left upper limb of a male cadaver. The union between the musculocutaneous nerve and the median nerve occurred approximately at the midpoint of the arm. We consider this variation to be rare.

Key Words: Musculocutaneous nerve, Median nerve, Variations.

Introduction:

Disparities in the origin, course, branching pattern and termination of the brachial plexus in the upper extremity are quite frequent and have been documented in many literatures (1). The clinical and surgical importance of anatomical knowledge of the musculocutaneous nerve and its variation is very essential to the doctors. Lack of this knowledge may lead to one of the complications in many upper limb surgical procedures, which involves injury of this nerve. About 65.3% of the populations were reported of these types of variations (2). A classical description of the musculocutaneous nerve given in Gray's Anatomy indicates that the musculocutaneous nerve is the nerve of the anterior compartment of the arm and arises from the lateral cord of brachial plexus having root value C5, 6 and 7 opposite to the lower border of pectoralis minor muscle. It gives a branch to the shoulder joint and then it passes through the coracobrachialis and descends laterally between biceps and brachialis to the lateral side of the arm. Just below the elbow it pierces the deep fascia lateral to the tendon of biceps and continues as the lateral cutaneous nerve of the forearm. It supplies coracobrachialis, both the heads of biceps and most of brachialis (lateral most slip of brachialis is supplied by the radial nerve). The branch to coracobrachialis is given-off before the nerve enters the muscle: its fibres are from the seventh cervical ramus and may branch directly from the lateral cord. After piercing the coracobrachialis it then supplies to biceps and the brachialis, the branch to brachialis also supplies to the elbow joint. It gives a small branch to the humerus, which enters the shaft with the nutrient artery [20]. The musculocutaneous nerve has frequent variations. It may run behind coracobrachialis or adhere for some distance to the median nerve and pass behind biceps. Some fibres of the median nerve may run in the musculocutaneous nerve, leaving it to join their proper trunk; less frequently the reverse occurs, and the median nerve sends a branch to the musculocutaneous. Occasionally it supplies pronator and may replace radial branches to the dorsal surface of the thumb (3).

Case Report

Using conventional dissecting techniques, with a purpose of preparation of the teaching and museum anatomical specimens the left upper limb was dissected in a 55-year-old embalmed male cadaver, in the Anatomy Department of Subbaiah Medical College and Research Centre, India. There was no sign of trauma, surgery or wound scars in the upper extremity. The skin, superficial fascia and the deep fascia of the upper limb, were removed systematically. The muscles, nerves and vessels were cleaned and exposed. Special attention was given to the nerves and vessels of the axilla, arm and forearm region.

During the dissections of the axilla, arm and forearm region we observed a rare case of the musculocutaneous nerve. After piercing the coracobrachialis it gave a communicating branch in the middle of the arm to the median nerve and later continued as the lateral cutaneous nerve of the forearm (Figure1). In addition to the communicating branch given to the median nerve, we also observed muscular branches coming from the musculocutaneous nerve to supply coracobrachialis, short and long head of biceps and brachialis muscle. However, we did not observe any variations in further course and distribution musculocutaneous nerve.

Discussion:

Musculocutaneous nerve is the nerve of the anterior compartment of the arm. The lateral cord of the brachial plexus continues as musculocutaneous nerve. After piercing the coracobrachialis muscle the nerve descends laterally between the biceps and the brachialis muscle and supplies all the muscles in the anterior compartment of the arm. A variation in the origin, course and the branches of the musculocutaneous nerve has been documented (4-8). Reports of absence of musculocutaneous nerve, musculocutaneous nerve not piercing the coracobrachialis and assumption of its innervation by the median nerve have also been found in review of literature.(9-11) Variations often involve communication between the musculocutaneous and the median nerves through one or more of the communicating branches (12&13)

Taking into consideration of the large number of discrepancies found in the review of literature, attempts have been made to classify such variations of the musculocutaneous nerve. Le Minor (14) describes five types of variation patterns of musculocutaneous nerve and Venieratos and Anagnostopoulou (15) indicates three types of variations. Some authors classified the variations in the musculocutaneous nerve based on the number of communicating branches and their height (16 &17).In our finding, the communicating branch of the musculocutaneous nerve with the median nerve occurs after piercing the coracobrachialis muscle.

The embryological basis of the upper limb might assist in relating this anatomical disparity. At 4-7th week of intra uterine life the mesenchyme, from the dorso-lateral part of the somites immigrates and forms the muscles into the limb bud, which is penetrated by the ventral primary rami of the suitable spinal nerves which are located opposite to the developing limb bud at the same time. Communication between nerves and muscle cells are necessary for mesenchymal condensation to form muscles. Connecting loops of the nerve fiber to form plexuses join nerves supplying the limbs. The median nerve is formed by the combination of ventral segmental branches and musculocutaneous nerve arises from it. Any deviation from these processes, lead to anatomical variation in the innervations of the muscles by appropriate nerves (18 & 19).

Consent Disclaimer:

As per international standard or university standard, patient's written consent has been collected and preserved by the author(s).

Conclusion:

The present study highlights the rare anatomical variations of musculocutaneous nerve and the awareness of such variations is important for surgeons, anesthetists and orthopedists who are involved in the management of the upper limb peripheral nerve lesions in shoulder, axilla and arm regions that could be a cause of serious medical conditions.

References:

1. Kerr AT. The brachial plexus of nerves in man, the variations in its formation and branches. *The American Journal of Anatomy*. 1918;23(2):285-395.
2. Buch – Hansen K. Über Varietäten des Nervus Musculocutaneus und deren Beziehungen. *Anat Anz* 1955; 102:187-203.
3. Brachial plexus. Susan Standring. Gray's Anatomy. The Anatomical Basis of Clinical Practice. 41st ed. Spain: Elsevier. 2008.
4. Bergman RA, Thompson SA, A AK, Saadeh FA: Compendium of the human anatomic variation. *Urban and Schwarzenberg*, Baltimore. 1988; 138-143.
5. Williams PL, Bannister LH, Berry MM, Collins P, Dyson M, Dussek JE et al. Nervous system. In: Gray's Anatomy. 38th edition. Churchill Livingstone, Edinburgh, London 1995: 1267-72.
6. Sergio Ricardo Rios Nascimento,|| Cristiane Regina Ruiz, Eduardo Pereira, Lilian Andrades, and Cristiano Cirqueira de SouzaRev Rare anatomical variation of the musculocutaneous nerve – case report *Bras Ortop*. 2016; 51(3): 366–369.
7. Gujar S., Savita G., Shah G.V., Bondre K.V. Unilateral variation in musculocutaneous nerve – a case report. *IJABMS*. 2012; 14(18):1–6.
8. Rebouças F., Brasil Filho R., Filardis C., Pereira R.R., Cardoso A.A. Estudo anatômico do trajeto do nervo musculocutâneo em relação ao processo coracoide. *Rev Bras Ortop*. 2010; 45(4):400–403.

9. Prasada Rao PVV, Chaudhary SC. Absence of the musculocutaneous nerve: Two case reports. *Clin Anat* 2001; 14(1):31-35.
10. Nakatani T, Mizukami S, Tanaka S: Three cases of the musculocutaneous nerve not perforating the coracobrachialis muscle. *Acta Anat Nippon* 1997a; 72(3):191-194.
11. Ihunwo AO, Osinde SP, Mukhtar AU: Distribution of median nerve to the muscles of the anterior compartment of the arm. *Cent Afr J Med* 1997; 43:359-360.
12. Sachdeva K, Singla RK. Communication between median and musculocutaneous nerve. *J Morphol Sci.* 2011;28(4):246–249.
13. Radunovic M, Vukanovic-Bozovic A, Radojevic N, Vukadinovic T. A new anatomical variation of the musculocutaneous and the median nerve anastomosis. *Folia Morphol.* 2013;72(2):176–179.
14. Le Minor JM. A rare variation of the median and musculocutaneous nerves in man. *Arch Anat Histol Embryol.* 1990; 73: 33-42.
15. Venieratos D, Anagnostopoulou S. Classification of communications between the musculocutaneous and median nerves. *Clin Anat.* 1998;11(5):327–331.
16. Maeda S, Kawai K, Koizumi M, Ide J, Tokiyoshi A, Mizuta H, et al. Morphological study, by teasing examination, of the communication from the musculocutaneous to median nerves. *Anat Sci Int.* 2009;84(1–2):41–46.
17. Guerri-Guttenberg RA, Ingolotti M. Classifying musculocutaneous nerve variations. *Clin Anat.* 2009;22(6):671–683.
18. Rodriguez-Niedenfuhr, M, Vazquez T, Choi D, Parkin I, Sadudo JR. Supernumerary humeral heads of the biceps brachii muscle revisited. *Clin Anat* 2003; 16(3): 197-203.
19. Uzun A, Seelig LL Jr. A variation in the formation of the median nerve: communicating branch between the musculocutaneous and median nerves in man. *Folia Morphol (Warsz)* 2001; 60(2): 99-101.

20. D.Jagadeesh Babu, T.Jayachandra Pillai, K. Deva Priyanka, Y.Jalaja, U.Sunil Kumar; "A Study on Variations of Musculocutaneous Nerve in Adult Cadavers", 2279-0853, p-ISSN: 2279-0861. Volume 15, Issue 5 Ver. VIII (May. 2016), PP 14-17

21. Preksha Sharma, Shreya Sharma, Sangita Chauhan, Neha Sharma, "

A case study of musculocutaneous nerve variations,

International Journal of Research in Medical Sciences, Sharma P et al. *Int J Res Med Sci.* 2015 Dec;3(12):3779-3781.

22. Nascimento SR¹, Ruiz CR¹, Pereira E¹, Andrades L¹, de Souza CC¹., " Rare anatomical variation of the musculocutaneous nerve - case

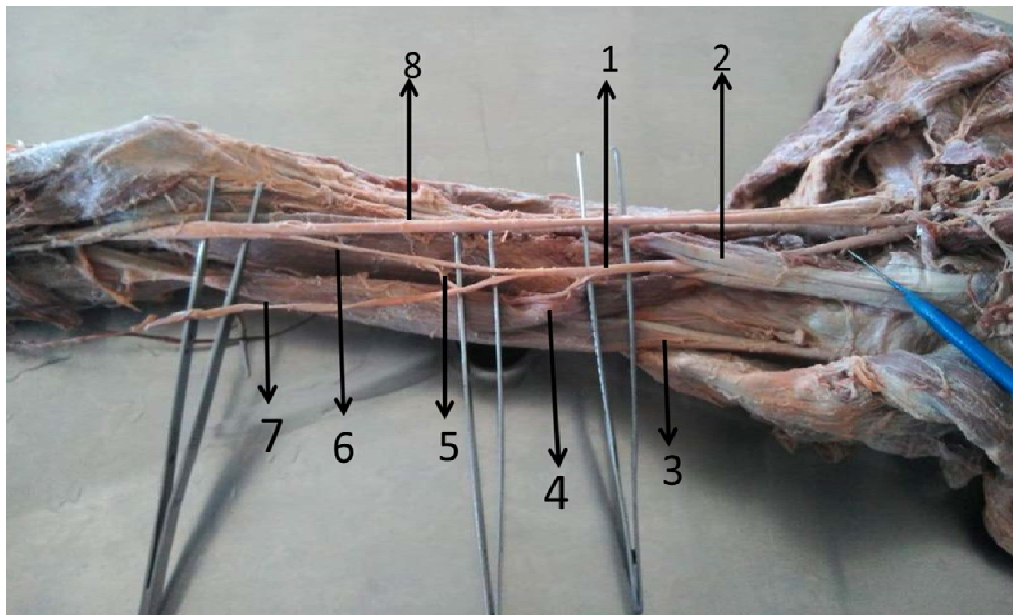


Fig.1: 1-Musculocutaneous nerve 2-Coracobrachialis 3-Long Head of Biceps brachii 4- Short Head of Biceps brachii 5-Branch to brachialis muscle 6-Communicatin branch from Musculocutaneous nerve to Median nerve 7- Lateral cutaneous nerve of forearm 8- Median nerve

