Case Study

Urinary bladder rupture after a long party-night

.

ABSTRACT

Introduction:

Urinary bladder rupture is a rare life-threatening event. Especially patients with alcohol intoxication are unable to provide a clear medical history. Physical examination often shows an acute abdominal pain. Under these circumstances the diagnosis of a urinary bladder rupture requires a high index of suspicion

Presentation of Case:

After a long party night with consumption of alcohol a 42-years old man wakes up with severe abdominal pain. Physical examination shows peritonitis- signs especially in the lower abdominal part. Ultrasound detects free intraperitoneal fluid. The CT scan of the Abdomen shows perihepatic fluid. With the diagnosis of acute abdomen without any radiological signs of perforation we performed a laparotomy. Intraoperatively a 3x2 cm rupture of the superior wall is seen and closed with sutures. After the operation the patient is received to the ICU.

Discusccion:

Urinary bladder rupture has a high mortality often due to late diagnosis. Spontaneous rupture of the urinary bladder is often associated with malignant disease, bladder outflow obstruction and neurogenic bladder. Alcohol-intoxicated patients are challenging cases in the emergency room. A clear history of the disease is not presented. In our case the patient had no history of trauma or any known urological diseases. So, it is possible as reported previously in a few earlier cases that urinary retention in these cases may be due to rapid filling of the bladder secondary to the diuretic effect of alcohol. Moreover, nausea and vomiting might lead to enhanced intra-abdominal pressure and higher probability of spontaneous bladder rupture

Conclusion:

Spontaneous rupture of the urinary bladder is a rare cause for acute abdominal pain with a high mortality because of delayed diagnosis. Especially Alcohol-intoxicated patients are not able to present any history of the disease. More over a urinary bladder rupture should be considered by patients with alcohol intoxication and without any traumatic event or known urological diseases like it is presented in our case.

Keywords: Urinary bladder, rupture, atraumatic, alcohol, free fluid

1. INTRODUCTION

Urinary bladder rupture is a rare life-threatening event (1). Especially patients with alcohol intoxication are unable to provide a clear medical history. Physical examination often shows an acute abdominal

pain. Under these circumstances the diagnosis of a urinary bladder rupture requires a high index of suspicion (2).

2. PRESENTATION OF CASE

After a long party night with consumption of alcohol a 42-years old man wakes up with severe abdominal pain. Physical examination shows signs of peritonitis especially in the lower abdominal part. Ultrasound detects free intraperitoneal fluid. The CT scan of the Abdomen shows perihepatic fluid. Blood creatinine-level was elevated (2,04mg/dl). The Level of the blood infection parameters were normal.
With the diagnosis of acute abdomen without any radiological signs of perforation we performed a laparotomy. Preoperatively an indwelling catheter is inserted into the patient's bladder via the urethra and a macrohematuria occurs. Intraoperatively a 3x2 cm rupture of the superior wall is seen. The bladder defect is closed in 2 layers with polyglactin 910 (Vicryl 3-0) using a simple interrupted suture technique. After the operation the patient is received to the ICU. The drunken patient could not remember any traumatic event which causes the rupture.

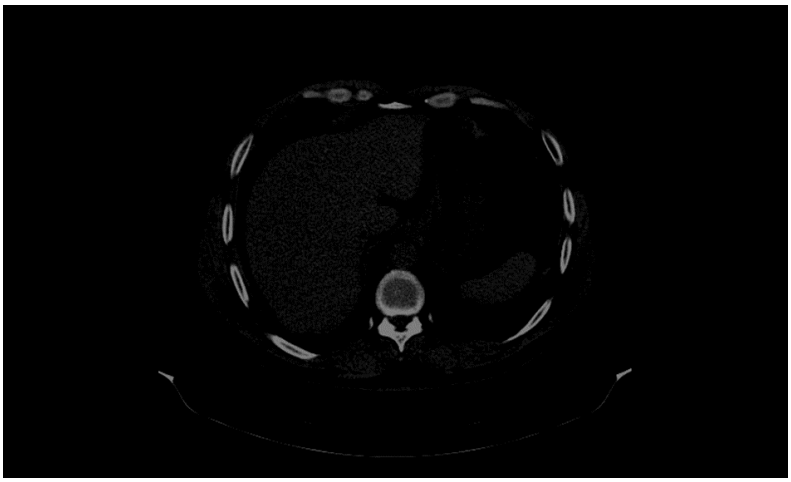

3. DISCUSSION

Urinary bladder rupture has a high mortality (47%) often due to late diagnosis (3). Spontaneous rupture of the urinary bladder is often associated with malignant disease, bladder outflow obstruction and neurogenic bladder (4, 5). Alcohol-intoxicated patients are often challenging cases in the emergency room. A clear history of the disease is not presented. In our case the patient had no history of trauma or any known urological diseases. It is possible as reported in a few earlier cases that urinary retention in these cases may be due to rapid filling of the bladder secondary to the diuretic effect of alcohol. The distention of the urinary bladder may lead to an atonic decompensated bladder which becomes stretched and thinner. As the dome of the urinary bladder is the weakest point within the bladder wall, over-distension and thinning of the dome eventually lead to bladder rupture. Moreover, nausea and vomiting might lead to enhanced intra-abdominal pressure and higher probability of spontaneous bladder rupture (6, 7).Symptoms of spontaneous bladder rupture can be non-specific. Most patients present with complain of lower abdominal pain, dysuria, difficulty voiding, hematuria inability to void and symptoms of an acute abdomen, as presented in our case (8).

Intraperitoneal bladder rupture can lead to sepsis and carry a higher mortality than extraperitoneal injuries. All of these injuries should be treated with prompt surgical exploration through a midline laparotomy incision and associated abdominal injuries should be excluded. Extraperitonel injuries can be managed successfully with a conservative strategy (9, 10). In case of a ruptured bladder with urine leakage into the peritoneal cavity 'reversed autodialysis' can occur, in which urea and creatinine diffuse back into the bloodstream via the peritoneum. This causes clinical signs of pseudorenal

failure, with raised concentrations of creatinine and urea. In case of ascites withe elevated blood creatinine levels a rupture of the urinary bladder should be considered (11, 12).

4. CONCLUSION

Spontaneous rupture of the urinary bladder is a rare cause for acute abdominal pain with a high mortality because of delayed diagnosis. Especially Alcohol-intoxicated patients are not able to present any history of the disease. More over a urinary bladder rupture should be considered by patients with alcohol intoxication and without a traumatic event or known urological diseases like it is presented in our case.

CONSENT (WHERE EVER APPLICABLE)

"All authors declare that 'written informed consent was obtained from the patient (or other approved parties) for publication of this case report and accompanying images. A copy of the written consent is available for review by the Editorial office/Chief Editor/Editorial Board members of this journal."

REFERENCES

1. Festini G, Gregorutti S, Reina G, Bellis GB. Isolated intraperitoneal bladder rupture in patients with alcohol intoxication and minor abdominal trauma. Annals of emergency medicine. 1991;20(12):1371-2.
2. Daignault MC, Saul T, Lewiss RE. Bedside ultrasound diagnosis of atraumatic bladder rupture in an alcohol-intoxicated patient: a case report. Critical ultrasound journal. 2012;4(1):9.
3. Hansen HJ, Eldrup J. Spontaneous rupture of the urinary bladder--a late complication to radiotherapy. Case report. Scandinavian journal of urology and nephrology. 1989;23(4):309-10.
4. Abu Mahfouz I, Sayer T, Phillips C. Conservative management of spontaneous rupture of the urinary bladder. International urogynecology journal. 2011;22(5):629-31.
5. Haddad FS, Pense S, Christenson S. Spontaneous intraperitoneal rupture of the bladder. Le Journal medical libanais The Lebanese medical journal. 1994;42(3):149-54.
6. Crawford R, Oliver TRW, Abboudi H, Shah S. Spontaneous rupture of the bladder during vomiting. BMJ case reports. 2017;2017.
7. Muneer M, Abdelrahman H, El-Menyar A, Zarour A, Awad A, Al-Thani H. Spontaneous Atraumatic Urinary Bladder Rupture Secondary to Alcohol Intoxication: A Case Report and Review of Literature. The American journal of case reports. 2015;16:778-81.
8. Kivlin D, Ross C, Lester K, Metro M, Ginsberg P. A Case Series of Spontaneous Rupture of the Urinary Bladder. Current urology. 2015;8(1):53-6.
9. Corriere JN, Jr., Sandler CM. Management of the ruptured bladder: seven years of experience with 111 cases. The Journal of trauma. 1986;26(9):830-3.
10. Kong JP, Bultitude MF, Royce P, Gruen RL, Cato A, Corcoran NM. Lower urinary tract injuries following blunt trauma: a review of contemporary management. Reviews in urology. 2011;13(3):119-30.
11. Matsumura M, Ando N, Kumabe A, Dhaliwal G. Pseudo-renal failure: bladder rupture with urinary ascites. BMJ case reports. 2015;2015.
12. Raeymaeckers S, Tosi M, Van Bael K, Brussaard C, De Mey J. [A patient with high creatinine levels but no renal failure: reversed autodialysis in a patient with a ruptured bladder]. Nederlands tijdschrift voor geneeskunde. 2016;160:A9424.